



Lacaziosis in Bottlenose Dolphins (*Tursiops truncatus*) in the Indian River Lagoon, Florida, USA

Authors: Durden, Wendy Noke, Leger, Judy St., Stolen, Megan, Mazza, Teresa, and Londono, Catalina

Source: Journal of Wildlife Diseases, 45(3) : 849-856

Published By: Wildlife Disease Association

URL: <https://doi.org/10.7589/0090-3558-45.3.849>

BioOne Complete (complete.BioOne.org) is a full-text database of 200 subscribed and open-access titles in the biological, ecological, and environmental sciences published by nonprofit societies, associations, museums, institutions, and presses.

Your use of this PDF, the BioOne Complete website, and all posted and associated content indicates your acceptance of BioOne's Terms of Use, available at www.bioone.org/terms-of-use.

Usage of BioOne Complete content is strictly limited to personal, educational, and non - commercial use. Commercial inquiries or rights and permissions requests should be directed to the individual publisher as copyright holder.

BioOne sees sustainable scholarly publishing as an inherently collaborative enterprise connecting authors, nonprofit publishers, academic institutions, research libraries, and research funders in the common goal of maximizing access to critical research.

Lacaziosis in Bottlenose Dolphins (*Tursiops truncatus*) in the Indian River Lagoon, Florida, USA

Wendy Noke Durden,^{1,3} Judy St. Leger,² Megan Stolen,¹ Teresa Mazza,¹ and Catalina Londono¹ ¹ Hubbs-SeaWorld Research Institute, 6295 Sea Harbor Drive, Orlando, Florida 32821-8043, USA; ² SeaWorld San Diego, 500 SeaWorld Drive, San Diego, California 92109, USA; ³ Corresponding author (email: wnoke@hswri.org)

ABSTRACT: The objective of this study was to document the presence of the fungal granulomatous skin disease lacaziosis in stranded Indian River Lagoon (IRL) bottlenose dolphins (*Tursiops truncatus*). From 1 January 2007 through 31 December 2007, stranded dolphins from the northern part of the IRL were thoroughly examined, and appropriate tissue samples were collected. The intralesional fungal agent (*Lacazia loboi*) was identified histologically in three bottlenose dolphins. Histologically, lacaziosis has been previously documented in IRL dolphins inhabiting the southern portion of the lagoon. Our findings suggest that the disease occurs throughout the lagoon. Enhanced monitoring of the prevalence of lacaziosis in dolphins throughout the IRL is needed to assess changes in population health.

Key words: Bottlenose dolphin, Indian River Lagoon, lacaziosis, *Lacazia loboi*, *Tursiops truncatus*.

Lacaziosis is a chronic granulomatous skin disease that is caused by the yeast-like organism, *Lacazia loboi* (formerly: *Loboa loboi*) that is yet to be cultured. The pathogen seems to be the phylogenetic sister taxon to the dimorphic onygenal pathogen *Paracoccidioides brasiliensis* (Herr et al., 2001). Although little is known about the epidemiology of the disease, it is suspected that the causal agent is a saprobic, hydrophilic pathogen (Ajello, 1998; Pradinaud, 1998). The disease has two known hosts, humans and dolphins. Positive identification of the organism is based on the unique morphology exhibited in lesions in both species. The use of additional diagnostics, including Western blot analysis and polymerase chain reaction can be useful in identifying and classifying *L. loboi* (Haubold et al., 1998; Herr et al., 2001;

Mendoza et al., 2008); however, these advanced methodologies support the usefulness of characteristic morphology of *L. loboi* to effectively identify the pathogen. Lacaziosis is considered zoonotic, with one documented case of an aquarium worker contracting the disease from an infected dolphin (Symmers, 1983). In humans, the disease causes nodular parakeleoidal lesions that typically occur on the ears and extremities of the individual. The disease is endemic to the Latin American countries, although there have been a few anomalous cases in North America in patients that had traveled to endemic areas (Burns et al., 2000; Elsayed et al., 2004). Transmission in both humans and dolphins is thought to be facilitated by trauma, injuries, or abrasions to the skin serving as portals of entry for the organism and may be correlated with immunodeficiency (Bossart, 1984; Pecher and Fuchs, 1988; Funchs et al., 1990; Reif et al., 2006, 2008; Xavier et al., 2006). In dolphins, the disease is found to occur on the head, flippers, flukes, dorsal fin, and peduncle (Caldwell et al., 1975; Dudok Van Heel, 1977) and has been documented along the coasts of the Gulf of Mexico, South America, and the coasts of Florida (Migaki et al., 1971; De Vries and Laarman, 1973; Caldwell et al., 1975; Bossart, 1984; Cowan, 1993; Simões-Lopes and Paula, 1993). The lesions are generally limited to the skin and present as a chronic proliferative and ulcerated dermatitis and cellulitis.

The Indian River Lagoon (IRL) is a shallow estuary system that extends approximately 220 km along the east coast of

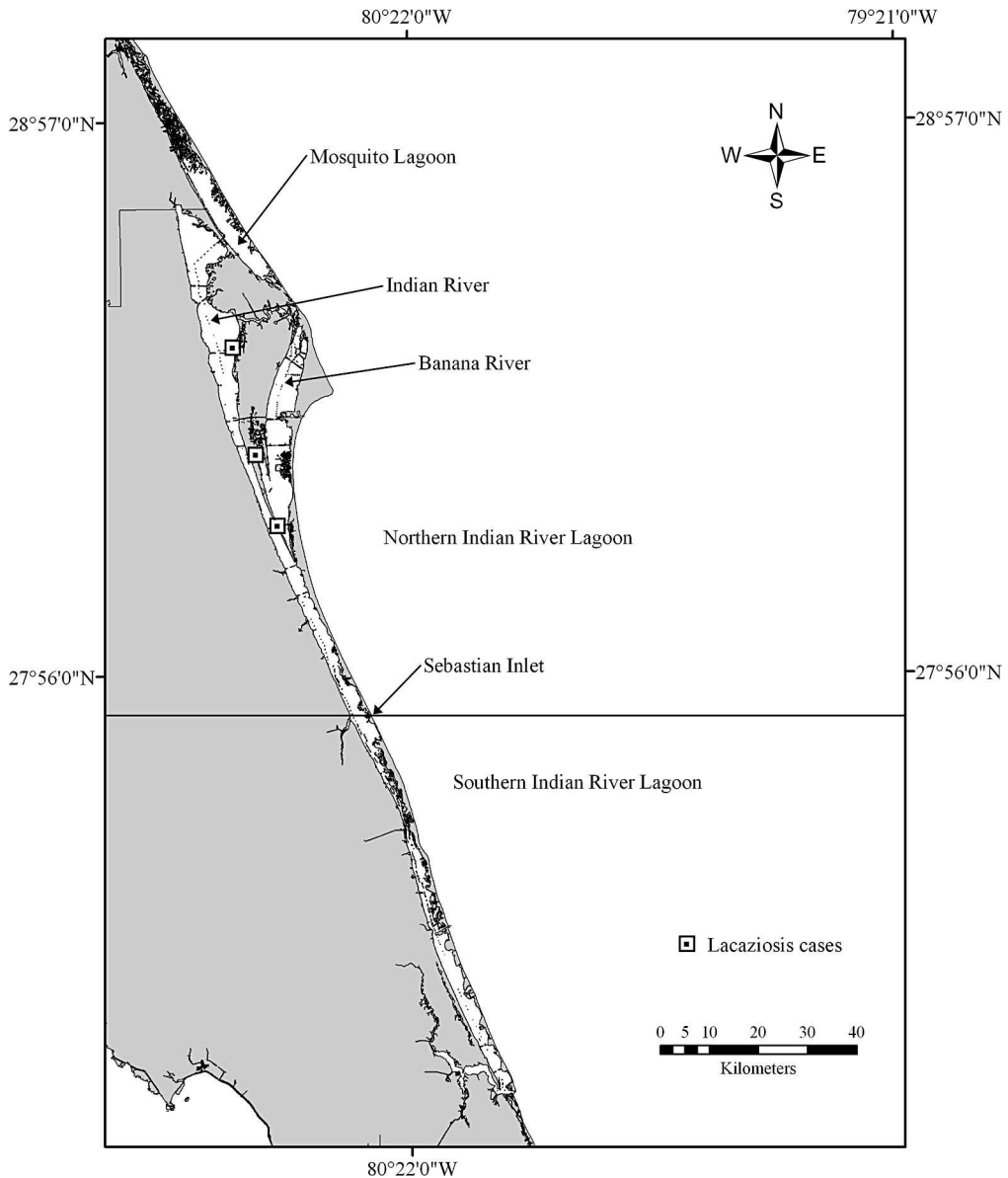


FIGURE 1. Map of the Indian River Lagoon, Florida, USA, and stranding locations for lacaziosis cases in the present study. Northern and southern lagoon is defined as north and south of Sebastian Inlet (arrow).

central Florida, USA (Mulligan and Snelson, 1983; Fig. 1). Although the estuary is open to the Atlantic Ocean at five inlets, the term “river” is a misnomer because there is no consistent flow pattern or gradient and the majority of water fluctuation is caused by wind currents (Mulligan and Snelson, 1983; Smith, 2001). The closed nature of the lagoon makes it

susceptible to an influx of terrestrial pollutants (Woodward-Clyde, 1994). In fact, it is suspected that diminishing seagrass coverage and loss of species diversity are related to contaminant accumulation and declining water quality (Virnstein et al., 1983; Sigua et al., 2000). In recent years, increased IRL dolphin mortality (Stolen et al., 2007) as well as

reports suggesting that the population is immune compromised (Bossart et al., 2003) have caused a growing concern for the health of Indian River Lagoon dolphins. This has resulted in efforts to assess the overall health of the population (Goldstein et al., 2006). The objective of this study was to document the presence of lacaziosis in IRL dolphins inhabiting the northern reaches of the lagoon.

From 1 January 2007 through 31 December 2007, all live, fresh dead, or moderately decomposed (Geraci and Lounsbury, 2005) bottlenose dolphins that were recovered stranded within the northern Indian River Lagoon (Fig. 1) were examined. Three bottlenose dolphins that exhibited advanced decomposition (Geraci and Lounsbury, 2005) were not included in the study. Total body length was measured as straight line length from the tip of the rostrum to the fluke notch (Norris, 1961). Sex was determined by external examination and internal examination of gonads. Teeth were extracted for age estimation, decalcified, sectioned using a freezing microtome, and stained with hematoxylin using standard methods (Myrick et al., 1983). Ages were estimated by counting the growth layer groups in the teeth (Hohn et al., 1989). All thickened, ulcerated, or irregular skin lesions were sampled via full thickness biopsy and preserved in 10% neutral-buffered formalin. Skin samples were paraffin embedded, sectioned at 3–5 μm , and stained with hematoxylin and eosin and/or periodic acid Schiff and examined. Because the organisms have a characteristic morphology but have yet to be cultured, diagnosis was based on identifying a granulomatous dermatitis or cellulitis containing the *L. loboi* organisms. Thorough necropsies were conducted on dead animals, and tissue samples for histologic evaluation were collected, preserved, and processed using standardized procedures (Geraci and Lounsbury, 2005). Attempts were made to determine a cause of death for all animals.

In total, 33 IRL dolphins were examined during the study period. Three (9%) of the animals examined had raised, nodular lesions on the pectoral flippers, head, and lateral trunk. The first case stranded on 11 February 2007. This adult male (250-cm) bottlenose dolphin (Hubbs-0717-Tt) was stranded alive in Merritt Island, Florida, along the eastern shore of the Indian River (28°12.526'N, 80°38.442'W) and died on-site shortly afterward. The animal was emaciated and had multifocal pale areas of skin discoloration covering much of its body. Grossly the animal had chronic mandibular misalignment due to a healed fracture in the right ramus. The dolphin had extremely worn teeth and was estimated to be 22 yr old. An area of granulomatous thickening was present at the cranial and ventral aspect of the mandible. Histologically, this was an area of chronic fibrosis and inflammation without intralesional organisms. The left shoulder joint and atlanto-occipital joints demonstrated chronic and active arthritis with a marked, irregular and multinodular thickening of the joint capsule and erosion of the articular surfaces. The animal had unilateral otitis media in the left ear and had several trematodes (presumptively *Nasitrema* sp.) in necrotic, hemorrhagic tissue around the left ear. There was a 6-cm \times 12-cm area of granulomatous thickening that was opaque, nodular, and ulcerated along the leading edge of the right pectoral flipper (Fig. 2A). In addition, multiple chronic conditions were present including hepatic periportal fibrosis, mild verminous pneumonia, and mild and multifocal fibrosing cardiomyopathy. The cause of death was determined to be emaciation and debilitation from the multiple chronic conditions.

On 6 June 2007, a free-swimming bottlenose dolphin (Hubbs-0738-Tt) was captured and relocated from a small retention pond in Merritt Island, Florida (28°20.37'N, 80°41.14'W) where the animal had been trapped for more than a week. The adult female (234 cm) had

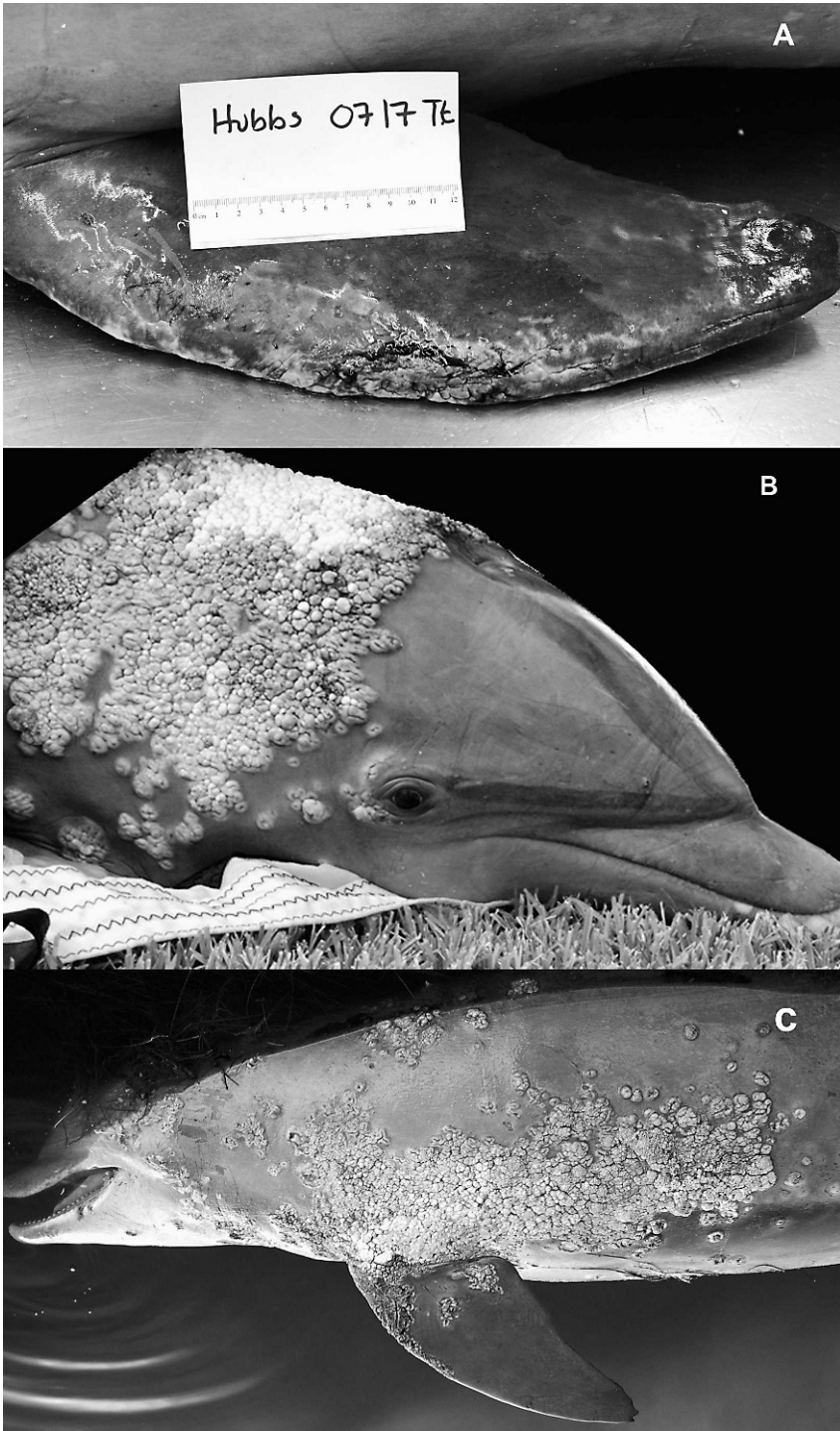


FIGURE 2. A. Case 1: Lacaziosis along leading edge of the right pectoral flipper of a live stranded bottlenose dolphin (Hubbs-0717-Tt). B. Case 2: A live stranded Indian River Lagoon, Florida, USA, with extensive lacaziosis circumscribing the head (Hubbs-0738-Tt). C. Case 3: Extensive lacaziosis covering the left lateral aspect of a dead stranded Indian River Lagoon dolphin (Hubbs-0744-Tt).

extensive cutaneous lesions on the left and right lateral and dorsal aspects of the cervical region, caudal to the eyes and blowhole, surrounding the head laterally and extending caudally 28 cm (Fig. 2B). Isolated lesions were also present on the dorsal fin. Lesions were opaque, nodular and sometimes ulcerated granulomatous thickenings. Before release, multiple skin biopsies were collected from the left lateral cervical region and preserved in 10% neutral-buffered formalin. Hematologic evaluation included a complete blood count and serum chemistry evaluation, and all values were within the normal range. On 2 July 2007, the dolphin was recovered dead approximately 5.4 km from the release site. Although autolysis precluded histologic evaluation of the tissues, the presumed cause of death was a large fish lodged in the esophagus. This animal was estimated to be 32 yr old.

On 3 July 2007, a dead adult (270-cm) male bottlenose dolphin (Hubbs-0744-Tt) stranded in Titusville, Florida (28°32.18'N, 80°43.96'W). Although the animal was moderately decomposed, the granulomatous thickening and extensive verrucose, nodular skin lesions were apparent caudal to blowhole on the head, along the left lateral aspect of the cervical region and along the thorax extending from the insertion of the left pectoral flipper to the base of the dorsal fin and on the left pectoral flipper (Fig. 2C). This animal was determined to be 27 yr old. Due to the state of decomposition and the lack of overt gross findings, the specific cause of death was not determined for this animal.

Histologic examination of skin from the proliferative regions in all three cases revealed multifocal, well circumscribed, patchy areas of histiocytic granulomatous dermatitis. Granulomas contained a mix of fibrous connective tissue and lymphocytes, plasma cells, macrophages, and multinucleate giant cells. Contained within these areas were thick-walled, globose cells that were approximately 10 μ m in diameter and were connected by narrow necks

(Fig. 3). Histologic findings are consistent with the morphologic diagnosis of multifocal granulomatous dermatitis with the intralesional fungal agent *L. loboi*.

Lacaziosis in bottlenose dolphins is endemic to the southeastern US waters. Many of the published accounts have come from the IRL and east coast dolphins (Caldwell et al., 1975; Bossart, 1984; Bossart et al., 2003; Reif et al., 2006). Anecdotal reports have documented the disease throughout the lagoon for decades (Caldwell et al., 1975; Odell, pers. comm.). More recently, Reif et al. (2006) examined 75 free-swimming IRL dolphins for lacaziosis. The study concluded that lacaziosis exhibited geographic variation with no cases seen in the northern portions (Fig. 1) compared with 30% of the animals in the southern portion exhibiting the disease. Based on photographic analysis, another study estimated disease prevalence at 6.8% throughout the lagoon and 4.9% in our study area, the northern part of the IRL (Murdoch et al., 2008). Based on histologic examination, our study documented lacaziosis prevalence to be nearly twice the photographic estimate for the northern portion of the lagoon (3/33 or 9%). Live animal resighting data for two of our cases confirmed that these animals were resident to the northern portion of the IRL (Mazzoil, pers. comm.)

Lacaziosis has been found to occur in older and possibly immune-compromised animals (Bossart, 1984; Reif et al., 2006, 2008); therefore, it is not surprising that animals in this study were relatively old (22–32 yr) with multiple chronic conditions present in some cases. Bottlenose dolphins from the Indian River Lagoon have been found to live up to 35 yr (Stolen et al., 2002). Studies on IRL dolphin health have found high concentrations of mercury (Durden et al., 2007), a toxic element that can compromise immune health (Moszczynski, 1997), and lingual and genital papillomas that may be related to immune dysfunction (Bossart, 2007).

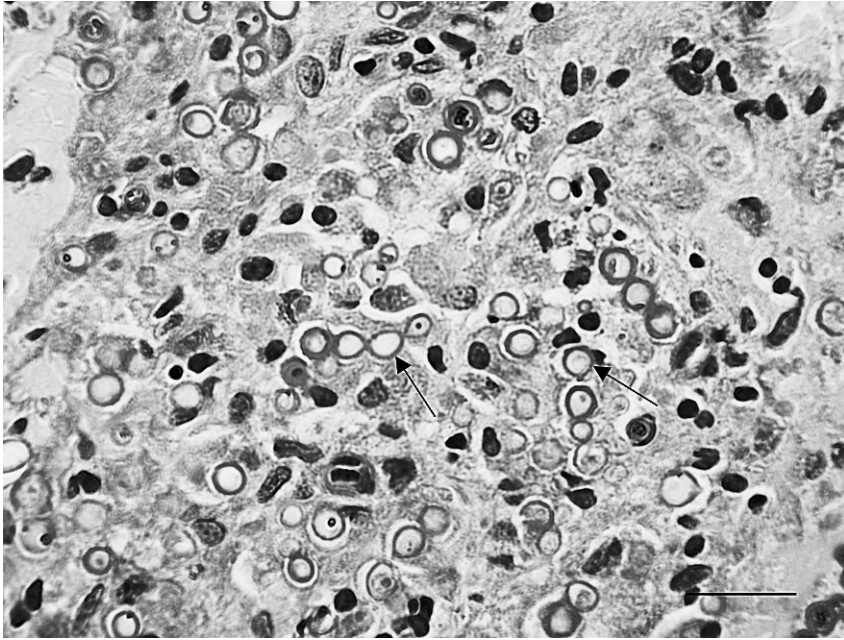


FIGURE 3. Photomicrograph of skin tissue from a bottlenose dolphin (Hubbs-0717-Tt) with lacaziosis. Note the globose cells (9–12 μm in diameter) (arrows) that are connected by narrow necks. PAS stain. 60 \times . Scale=30 μm .

The apparent diminished health of these animals coupled with the stagnant nature of the ecosystem may contribute to the presence of this apparently endemic disease. Future studies are warranted to determine the prevalence of the disease over time and its relation to the age, overall health status, and immunologic status of the population.

We thank HSWRI volunteers, Sea-World Animal Care staff, and L. Croft for assistance in sample collection. We thank D. Odell for helpful suggestions and manuscript review, E. Howells for assistance, and M. Mazzoil for providing sighting histories for the animals. Samples were collected under a National Marine Fisheries Service Letter of Agreement. This project was supported under the Prescott award NA06NMF4390138 from the National Oceanic and Atmospheric Administration, US Department of Commerce. The statements, findings, conclusions and recommendations are those of the authors and do not necessarily reflect

the views of the National Oceanic and Atmospheric Administration or the Department of Commerce.

LITERATURE CITED

- AJELLO, L. 1998. Ecology and epidemiology of hydrophilic infectious fungi and parafungi of medical mycological importance: A new category of pathogens. *In* Topley and Wilson's microbiology and microbial infections, medical mycology, Vol. 4. 9th Edition, L. Ajello and R. J. Hay (eds.). Arnold, London, UK, pp. 67–73.
- BOSSART, G. D. 1984. Suspected acquired immunodeficiency in an Atlantic bottlenosed dolphin with chronic-active hepatitis and lobomycosis. *Journal of the American Veterinary Medical Association* 185: 1413–1414.
- . 2007. Emerging diseases in marine mammals: From dolphins to manatees. *Microbe* 2: 544–547.
- , R. MEISNER, R. VARELA, M. MAZZOIL, S. D. MCCULLOCH, D. KILPATRICK, R. FRIDAY, E. MURDOCH, B. MASE, AND R. H. DEFRAN. 2003. Pathologic findings in stranded Atlantic bottlenose dolphins (*Tursiops truncatus*) from the Indian River Lagoon, Florida. *Florida Scientist* 66: 226–238.
- BURNS, R. A., J. S. ROY, C. WOODS, A. A. PADHYE, AND D. W. WARNOCK. 2000. Report of the first human

- case of lobomycosis in the United States. *Journal of Clinical Microbiology* 38: 1283–1285.
- CALDWELL, D. K., M. C. CALDWELL, J. C. WOODARD, L. AJELLO, W. KAPLAN, AND H. M. McCLURE. 1975. Lobomycosis as a disease of the Atlantic bottle-nosed dolphin (*Tursiops truncatus* Montagu, 1821). *American Journal of Tropical Medicine and Hygiene* 24: 105–114.
- COWAN, D. F. 1993. Lobo's disease in a bottlenose dolphin (*Tursiops truncatus*) from Matagorda Bay, Texas. *Journal of Wildlife Diseases* 29: 488–489.
- DE VRIES, G. A., AND J. J. LAARMAN. 1973. A case of Lobo's disease in the dolphin *Sotalia guianensis*. *Aquatic Mammals* 1: 26–33.
- DUDOK VAN HEEL, W. H. 1977. Successful treatment in a case of lobomycosis (Lobo's disease) in *Tursiops truncatus* (Mont.) at the dolfinarium, Harderwijk. *Aquatic Mammals* 5: 8–15.
- DURDEN, W. N., M. K. STOLEN, D. H. ADAMS, AND E. D. STOLEN. 2007. Mercury and selenium concentrations in stranded bottlenose dolphins from the Indian River Lagoon system, Florida. *Bulletin of Marine Science* 81: 37–54.
- ELSAYED, S., S. M. KUHN, D. BARBER, D. L. CHURCH, S. ADAMS, AND R. KASPER. 2004. Human case of lobomycosis. *Emerging Infectious Diseases* 10: 715–718.
- FUNCHS, J., R. MILBRADT, AND S. A. PECHER. 1990. Lobomycosis (keloidal blastomycosis): Case reports and overview. *Cutis* 46: 227–234.
- GERACI, J. R., AND V. L. LOUNSBURY. 2005. Marine mammals ashore: A field guide for strandings. 2nd Edition. National Aquarium in Baltimore, Inc., Baltimore, MD, 371 pp.
- GOLDSTEIN, J. D., E. REESE, J. S. REIF, R. A. VARELA, S. D. McCULLOCH, R. H. DEFRAN, P. A. FAIR, AND G. D. BOSSART. 2006. Hematologic, biochemical, and cytologic findings from apparently healthy Atlantic bottlenose dolphins (*Tursiops truncatus*) inhabiting the Indian River Lagoon, Florida, USA. *Journal of Wildlife Diseases* 42: 447–454.
- HAUBOLD, E. M., J. F. ARONSON, D. F. COWAN, M. R. MCGINNIS, AND C. R. COOPER. 1998. Isolation of fungal rDNA from bottlenose dolphin skin infected with *Loboa lobo*. *Medical Mycology* 36: 263–267.
- HERR, R. A., E. J. TARCHA, P. R. TABORDA, J. W. TAYLOR, L. AJELLO, AND L. MENDOZA. 2001. Phylogenetic analysis of *Lacazia lobo* places this previously uncharacterized pathogen within the dimorphic Onygenales. *Journal of Clinical Microbiology* 39: 309–314.
- HOHN, A. A., M. D. SCOTT, R. S. WELLS, J. C. SWEENEY, AND A. B. IRVINE. 1989. Growth layers in teeth from known-age, free-ranging bottlenose dolphins. *Marine Mammal Science* 5: 315–342.
- MENDOZA, L., A. F. F. BELONE, R. VILELA, M. REHTANZ, G. D. BOSSART, J. S. REIF, P. A. FAIR, W. N. DURDEN, J. ST. LEGER, L. R. TRAVASSOS, AND P. S. ROSA. 2008. Use of sera from humans and dolphins with lacaziosis and sera from experimentally infected mice for Western blot analyses of *Lacazia lobo* antigens. *Clinical and Vaccine Immunology* 15: 164–167.
- MIGAKI, G., M. G. VALERIO, B. IRVINE, AND F. M. GARNER. 1971. Lobo's disease in an Atlantic bottle-nosed dolphin. *Journal of the American Veterinary Medical Association* 159: 578–582.
- MOSZCZYNSKI, P. 1997. Mercury compounds and the immune system: A review. *International Journal of Occupational and Environmental Health* 10: 247–258.
- MULLIGAN, T. J., AND F. F. SNELSON, JR. 1983. Summer season population of epibenthic marine fishes in the Indian River Lagoon system, Florida. *Florida Scientist* 46: 250–276.
- MURDOCH, M. E., J. S. REIF, M. MAZZOIL, S. D. McCULLOCH, P. A. FAIR, AND G. D. BOSSART. 2008. Lobomycosis in bottlenose dolphins (*Tursiops truncatus*) from the Indian River Lagoon, Florida: Estimation of prevalence, temporal trends, and spatial distribution. *EcoHealth* 5: 289–297.
- MYRICK, A. C., A. A. HOHN, P. A. SLOAN, M. KIMURA, AND D. D. STANLEY. 1983. Estimating age of spotted and spinner dolphins (*Stenella attenuata* and *Stenella longirostris*) from teeth. NOAA Technical Memorandum, Report NOAA-TM-NMFS-SWFC-30. Southwest Fisheries Center, National Marine Fisheries Service, La Jolla, California, 17 pp.
- NORRIS, K. S. 1961. Standardized methods for measuring and recording data on the smaller cetaceans. *Journal of Mammalogy* 42: 471–476.
- PECHER, S. A., AND J. FUCHS. 1988. Cellular immunity in lobomycosis (keloidal blastomycosis). *Allergologia et Immunopathologia* 16: 413–415.
- PRADINAUD, R. 1998. *Lacazia lobo*. In Topley and Wilson's microbiology and microbial infections, Vol. 4, L. Collier, A. Balows, and M. Sussman (eds.). Oxford University Press, New York, NY, pp. 585–594.
- REIF, J. S., M. S. MAZZOIL, S. D. McCULLOCH, R. A. VARELA, J. D. GOLDSTEIN, P. A. FAIR, AND G. D. BOSSART. 2006. Lobomycosis in Atlantic bottlenose dolphins from the Indian River Lagoon, Florida. *Journal of the American Veterinary Medical Association* 228: 104–108.
- , M. M. PEDEN-ADAMS, T. A. ROMANO, C. D. RICE, P. A. FAIR, AND G. D. BOSSART. 2008. Immune dysfunction in Atlantic bottlenose dolphins (*Tursiops truncatus*) with lobomycosis. *Medical Mycology* 4: 1–11.
- SIGUA, G. C., J. S. STEWARD, AND W. A. TWEEDALE. 2000. Water quality monitoring and biological integrity assessment in the Indian River Lagoon, Florida: Status, trends and loadings (1988–

- 1994). *Environmental Management* 25: 199–209.
- SIMÔSE-LOPES, P. C., AND G. S. PAULA. 1993. The first case of lobomycosis in a bottlenose dolphin from southern Brazil. *Marine Mammal Science* 9: 329–331.
- SMITH, N. P. 2001. Seasonal-scale transport patterns in a multi-inlet coastal lagoon. *Estuarine, Coastal and Shelf Science* 52: 15–28.
- STOLEN, M. K., D. K. ODELL, AND N. B. BARROS. 2002. Growth of bottlenose dolphins (*Tursiops truncatus*) from the Indian River Lagoon system, Florida, USA. *Marine Mammal Science* 18: 348–357.
- , W. N. DURDEN, AND D. K. ODELL. 2007. Historical synthesis of bottlenose dolphin (*Tursiops truncatus*) stranding data in the Indian River Lagoon from 1977–2005. *Florida Scientist* 70: 45–54.
- SYMMERS, W. 1983. A possible case of Lobo's disease acquired in Europe from a bottle-nosed dolphin (*Tursiops truncatus*). *Bulletin of the Exotic Pathology Society* 76: 777–784.
- VIRNSTEIN, R. W., P. S. MIKKELSON, K. D. CAIRNS, AND M. A. COPONE. 1983. Seagrass beds versus sand bottoms. The importance of their associated benthic invertebrates. *Florida Scientist* 46: 363–383.
- WOODWARD-CLYDE CONSULTANTS. 1994. Final Report. Physical features of the Indian River lagoon. IRL. National Estuary Program (IRLNEP). Melbourne, Florida. Project No. 92F274C. Tampa, FL.
- XAVIER, M. B., M. M. R. FERREIRA, J. A. S. QUARESMA, AND A. C. DE BRITO. 2006. HIV and lacaziosis, Brazil. *Emerging Infectious Diseases* 12: 526–527.

Received for publication 4 April 2008.