

## **MEDIAL ARTERIAL SCLEROSIS IN CAPTIVE BEAVERS, *Castor canadensis* Kuhl. 1**

Author: DIETERICH, ROBERT A.

Source: Bulletin of the Wildlife Disease Association, 5(2) : 115-116

Published By: Wildlife Disease Association

URL: <https://doi.org/10.7589/0090-3558-5.2.115>

---

BioOne Complete ([complete.BioOne.org](https://complete.BioOne.org)) is a full-text database of 200 subscribed and open-access titles in the biological, ecological, and environmental sciences published by nonprofit societies, associations, museums, institutions, and presses.

Your use of this PDF, the BioOne Complete website, and all posted and associated content indicates your acceptance of BioOne's Terms of Use, available at [www.bioone.org/terms-of-use](https://www.bioone.org/terms-of-use).

Usage of BioOne Complete content is strictly limited to personal, educational, and non - commercial use. Commercial inquiries or rights and permissions requests should be directed to the individual publisher as copyright holder.

---

BioOne sees sustainable scholarly publishing as an inherently collaborative enterprise connecting authors, nonprofit publishers, academic institutions, research libraries, and research funders in the common goal of maximizing access to critical research.

**MEDIAL ARTERIAL SCLEROSIS IN CAPTIVE BEAVERS, *Castor canadensis* Kuhl.<sup>1</sup>**

Medial arterial sclerosis is a descriptive term referring to a hardening or induration of the vessels of the arterial system. The exact cause of such induration is often uncertain, and various theories have been advanced in an attempt to explain the process (Symposium on Atherosclerosis, Publication, 338, National Academy of Sciences & National Research Council, Washington, D.C.). This paper deals with two cases of medial arterial sclerosis in one male and one female beaver approximately two and one-half years old, which had been in captivity for two years. These animals were maintained in such a way as to have access to an outside pen with a pool as well as to an inside, heated enclosure. They

were fed cuttings of aspen, *Populus tremuloides* Michx., and Purina Lab Chow.

Both animals had had chronic abscesses, involving the area of the head of one and the abdominal region of the other. They did not respond well to treatment over a considerable period of time, and the lesions recurred when treatment was discontinued. One animal died on 6 June 1968, and the second on or about 10 August 1968. At necropsy, the abscesses were found to be limited to the subcutaneous tissues. In both animals the mesenteric arteries were firm and very prominent (Fig. 1). When transected, the arteries remain distended and their walls macroscopically appeared to be calcified. Most of the arterial system was so affected. Macroscopically, most of the internal organs appeared to be normal, but the kidneys were shrunken and pitted on the surface.

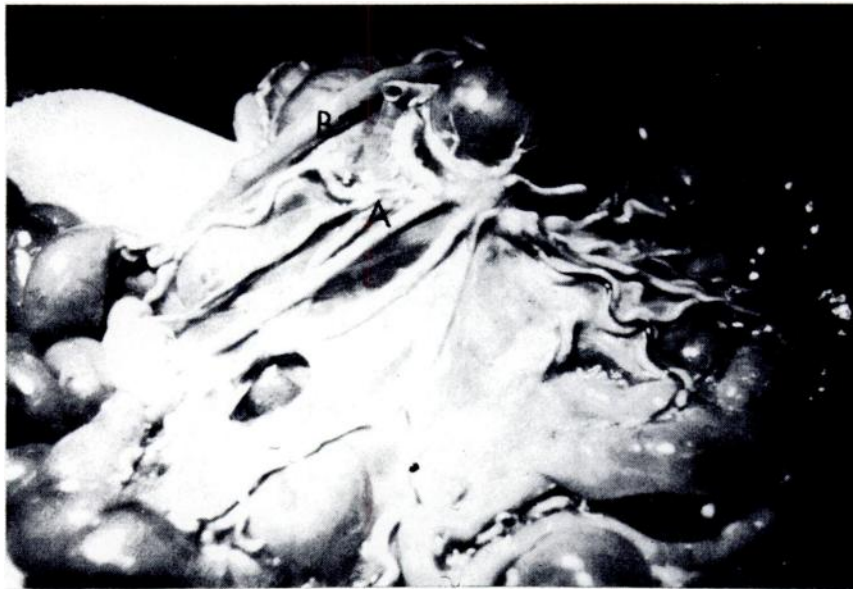

FIGURE 1. Gross lesions of arterial sclerosis in beaver. Note distended mesenteric arteries (A) and the firm, calcified sectioned artery (B).

<sup>1</sup>Supported in part by NIH Grant GM 10402. Publication No. 98.

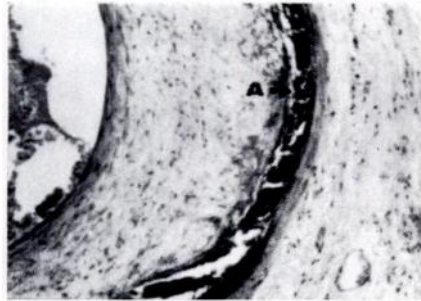


FIGURE 2. Photomicrograph of calcification in media of mesenteric artery of beaver. (A)

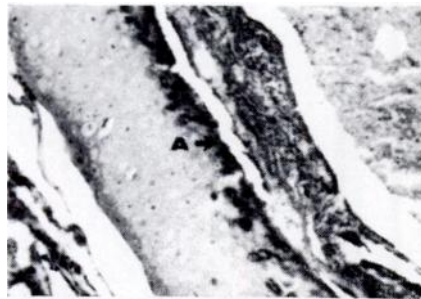


FIGURE 3. Calcium deposition in submucosa of the bronchi in beaver lung. (A)

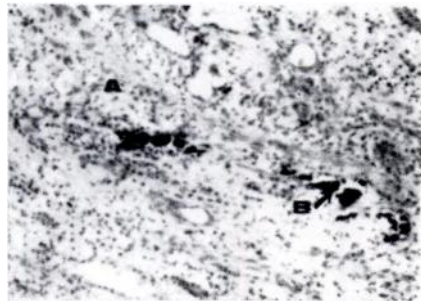


FIGURE 4. Photomicrograph of sectioned beaver kidney demonstrating scarring lesions from interstitial nephritis (A) and areas of calcification. (B)

Microscopically, sections of all arteries examined had diffuse and severe fibrosis and calcification of the tunica media (Fig. 2). The cartilage of the bronchi also had sclerotic changes (Fig. 3). The arterial lesions resembled those seen in the healing stages of periarteritis nodosa and in Monckelberg's medial sclerosis. The kidneys of both animals had multiple foci of interstitial nephritis which contained mineralized areas (Fig. 4).

The etiology of the medial arterial sclerosis in the two cases is not clear. A possible explanation is that chronic nephritis led to an accumulation of phosphorus in the blood because of impaired ability to excrete these ions. Increased phosphorus in the blood may lead to changes in metabolism of calcium, which in turn might have caused the calcification observed in these beavers. However, the two conditions might not have been related, and the sclerotic changes could have been a result of nutritional imbalance in combination with aging.

#### Acknowledgement

The author acknowledges the assistance of the Armed Forces Institute of Pathology in the preparation of this manuscript.

ROBERT A. DIETERICH

*Institute of Arctic Biology  
University of Alaska  
College, Alaska 99701*

January 18, 1969