

## **The Fringed Tapeworm (*Thysanosoma actinioides*) as a Parasite of the Rocky Mountain Elk in Yellowstone National Park\***

Authors: JACOBSON, RICHARD H., and WORLEY, DAVID E.

Source: Bulletin of the Wildlife Disease Association, 5(2) : 95-98

Published By: Wildlife Disease Association

URL: <https://doi.org/10.7589/0090-3558-5.2.95>

---

BioOne Complete ([complete.BioOne.org](https://complete.BioOne.org)) is a full-text database of 200 subscribed and open-access titles in the biological, ecological, and environmental sciences published by nonprofit societies, associations, museums, institutions, and presses.

Your use of this PDF, the BioOne Complete website, and all posted and associated content indicates your acceptance of BioOne's Terms of Use, available at [www.bioone.org/terms-of-use](https://www.bioone.org/terms-of-use).

Usage of BioOne Complete content is strictly limited to personal, educational, and non - commercial use. Commercial inquiries or rights and permissions requests should be directed to the individual publisher as copyright holder.

---

BioOne sees sustainable scholarly publishing as an inherently collaborative enterprise connecting authors, nonprofit publishers, academic institutions, research libraries, and research funders in the common goal of maximizing access to critical research.

# The Fringed Tapeworm (*Thysanosoma actinioides*) as a Parasite of the Rocky Mountain Elk in Yellowstone National Park\*

RICHARD H. JACOBSON and DAVID E. WORLEY,  
*Veterinary Research Laboratory, Montana State University,*

and

KENNETH R. GREER,  
*Montana Fish and Game Department*

Received January 28, 1969

## Abstract

Post-mortem examination of 181 elk (*Cervus canadensis nelsoni*) from the northern Yellowstone Park herd in 1967-68 revealed that 41% were infected with *Thysanosoma actinioides*. Infections occurred in all age classes of animals from seven areas in the Yellowstone, Gardner and Lamar drainages in the northern section of the Park.

Prevalence of the parasite was higher in calves and yearlings than in mature elk. Infections varied from 1 to 16 worms per animal, with an average intensity of 4.3 in 75 elk. Worms were confined to the first 6.2 feet of the small intestine, with no distinct habitat preference apparent within this area. Little evidence of *T. actinioides* or gross lesions associated with its presence was found in the liver or bile ducts of elk examined 20 to 40 minutes after death.

## Introduction

Although *Thysanosoma actinioides* has been reported from the Rocky Mountain elk (*Cervus canadensis nelsoni*) in Wyoming, Montana and Alberta<sup>4,9,11</sup>, limited information is available on the prevalence and distribution of this tapeworm in an indigenous elk herd. From January, 1967 through March, 1968, 181 elk were necropsied for biological studies on the northern Yellowstone Park herd. Thus, an opportunity was presented for studies on the biology of the fringed tapeworm in a native elk herd which occupies a range depleted through continuous use by wild ruminants for many years.

---

\* Contribution from the Montana Veterinary Research Laboratory, Agricultural Experiment Station, Bozeman, Montana 59715. Paper No. 950 journal series, and Federal Aid in Wildlife Restoration, Montana Project W-83-R.

### Materials and Methods

A total of 181 elk was examined for the presence of *Thysanosoma*. Elk were live-trapped from seven areas of the northern winter range<sup>11</sup> during January through March, 1967, and December, 1967 through March, 1968. Forty-two animals were taken from the Pebble Creek - Soda Butte area in the eastern portion of the range. Forty-seven animals originated in the Mt. Everts - Gardiner area in the western section of the range, and 92 elk were trapped in the centrally located Slough Creek - Crystal-Frog Rock region.

Live animals were transported to a slaughterhouse for necropsy. The liver, bile ducts and approximately the first 12 feet of the small intestine distal to the pyloric valve were opened and examined for tapeworms within 20 to 40 minutes after death. The location of the worms in the intestine was recorded as a specific distance from the pylorus in 19 animals. Worms were relaxed in tap water at 4 C for 8 to 12 hours prior to fixation in alcohol-formalin-acetic acid solution.

A size comparison was made between these specimens from elk and *Thysanosoma* from domestic sheep and moose collected by the authors in similar range country in southern Montana and northern Wyoming. Only specimens that relaxed with relative uniformity were compared.

### Results

The fringed tapeworm was observed in 41% (75/181) of the elk examined. Sixty-nine percent of 42 elk from the eastern section of the winter range harbored *Thysanosoma*, whereas 43% of 47 animals from the western area were similarly infected. Of 92 elk examined from the central district, 28% were positive. Tapeworm incidence showed a marked decrease in older age classes of elk: 51% of 128 calves and yearlings were infected, whereas 15% of 48 adult elk (2½ years and older) were positive.

Infections varied from 1 to 16 worms per animal, with an average intensity of 4.3 worms in 75 elk. Of 181 animals examined, tapeworms were observed in the bile ducts in only one elk. Distribution of worms in

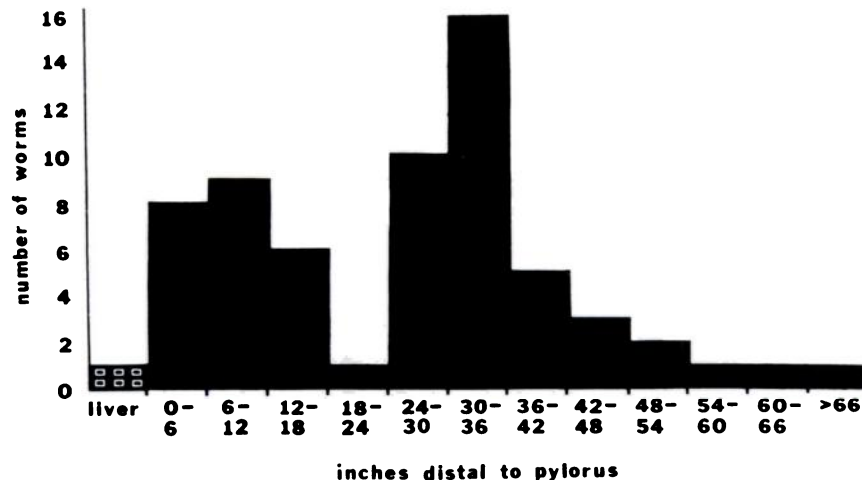


FIGURE 1. Distribution of *Thysanosoma actinioides* in the small intestine of elk.

TABLE 1. *Dimensions of Thysanosoma actinioides from elk, sheep, and moose.*

	No. Animals	No. Specimens	Length		Width	
			Mean	Range	Mean	Range
Elk	32	63	108 mm	55 - 202 mm	8.7 mm	6.0 - 13.0 mm
Domestic Sheep	9	21	252 mm	122 - 332 mm	7.3 mm	4.5 - 9.0 mm
Moose	1	2	—	160 - 164 mm	9.0 mm	—

the intestine indicated that the portion of the duodenum 30 to 36 inches distal to the pylorus was inhabited by more worms than any other area (Figure 1). With the exception of the segment of the intestine 18 to 24 inches posterior to the pylorus, worm distribution was relatively uniform in the first 30 inches of the intestine. Worm concentrations distal to the 36-inch portion decreased in proportion to the distance from the pylorus. The maximum distance worms were found from the pylorus was 74 inches. In individual animals, there apparently was no correlation between the total worm burden and distribution of tapeworms in the intestine.

Comparative measurements of *Thysanosoma* from elk, domestic sheep and moose are listed in Table 1. *Thysanosoma* from domestic sheep in Montana were 2.3 times as long as specimens from elk and about 1.6 times as long as worms from moose. The mean maximum width of elk specimens was 16% larger than the width of domestic sheep specimens.

#### Discussion

The incidence of tapeworm infections in elk from the central part of the Yellowstone Park winter range was 28%. Since most of the adult animals examined came from this vicinity, the lower infection rate in these elk could be explained on the basis of a higher average age for this group of animals. The incidence of tapeworm infections in calves and yearlings from the central area was 41%, compared with infection rates of 69% and 44% in animals from the other two portions of the range. These figures indicate that infection rates were relatively uniform for the younger age groups of elk from three areas used by the northern Yellowstone herd.

The pathologic changes associated with *Thysanosoma actinioides* in sheep have been described by Allen and Kyles<sup>2</sup>. The bile ducts become dilated, thickened and occasionally occluded. The bile may be turbid and the duct wall inflamed and hyperemic. Our data indicate that in elk, the fringed tapeworm has a greater affinity for the first 5 feet of the small intestine than for the liver or bile ducts. The absence of gross lesions in the liver or associated ducts of elk would tend to support this conclusion. In addition, livers of 250 elk examined during a previous phase of the Yellowstone elk biological studies were all grossly negative for *Thysanosoma*. The extent of intestinal infections in these animals was not determined.

In order to determine whether or not worm dimensions were influenced by a "crowding effect" such as that described for rodent cestodes by Read<sup>10</sup>, measurements of tapeworms from elk infected with one to three worms were compared with specimens from animals having four or

more worms. The mean worm length was 117.6 mm in animals infected with one to three worms, as compared with 111.1 mm for infections of four or more worms per animal. In heavy infections of *Thysanosoma*, i.e. four or more worms, the mean maximum width of the worms was 0.2 mm less than for worms from light infections. In domestic sheep, the trend was reversed. When four or more *Thysanosoma* were present in one animal, the worms were about 20 mm longer than in lighter infections. Thus, no consistent relationship emerged between worm burden and worm dimensions which was applicable to both hosts.

Additional comparisons were made of the incidence of fringed tapeworms in elk and domestic sheep, in an effort to estimate the relative susceptibility of these two hosts. Composite data from several studies<sup>1,2,5,7,8,9</sup> indicated that the overall incidence of *T. actinioides* was 32% in a series of approximately 2000 sheep originating in six western states. This compares with an overall incidence of 41% in 181 elk examined during the present study. Although many factors may influence infection rates in a given host population, the overall similarity in the incidence of fringed tapeworms in the two species suggests that both animals are common hosts for this parasite in some areas of the western United States.

#### Acknowledgements

The cooperation of Yellowstone National Park personnel in obtaining animals used in this study, and the assistance of the Ricks Packing Company in providing necropsy facilities, is gratefully acknowledged.

#### Literature Cited

1. ALLEN, R. W. and P. K. JACKSON. 1953. Evaluation of di-phenthan-70 in removing fringed tapeworms from sheep. *Vet. Med.*, 48: 352-354.
2. ALLEN, R. W. and P. M. KYLES. 1950. The pathologic changes associated with *Thysanosoma actinioides*. *J. Parasitol.* 36 (6, Sect. 2), Suppl. p. 45.
3. BOISVENUE, R. J. and J. C. HENDRIX. 1967. Location of adult fringed tapeworms, *Thysanosoma actinioides*, in sheep. Program and Abstracts, 42nd Ann. Meet. Am. Soc. Parasitol., p. 31.
4. FLOOK, DONALD R. 1967. A study of the apparent unequal sex ratio of wapiti. Ph.D. Thesis. University of Alberta, Edmonton, Alberta. Sept. 1967, 213 pp.
5. GASSNER, F. X. and F. THORP, Jr. 1940. Studies on *Thysanosoma actinioides*. *Am. J. Vet. Res.*, 1: 36-43.
6. HONESS, R. F. and K. B. WINTER. 1956. Diseases of wildlife in Wyoming. Wyoming Game and Fish Comm., 279 pp.
7. KELLEY, G. W., L. HARRIS, M. A. ALEXANDER and L. S. OLSEN. 1960. Hygromycin B for removing *Thysanosoma actinioides*, fringed tapeworms from feedlot lambs. *J. Am. Vet. Med. Assoc.*, 136: 505-507.
8. OLSEN, O. W. 1943. An evaluation of medicaments, with special reference to teniatol for removing fringed tapeworms (*Thysanosoma actinioides*) from the livers of sheep. *Am. J. Vet. Res.*, 14: 616-620.
9. OLSEN, O. W. and R. W. ALLEN. 1945. Tests with carbon tetrachloride, hexachlorethane, and tetrachlorethylene, for removing the fringed tapeworm of sheep. *Proc. Helm. Soc. Wash.* 12(2): 2.
10. READ, C. P. 1951. The "crowding effect" in tapeworm infections. *J. Parasitol.* 37: 174-178.
11. RUSH, W. M. 1932. Northern Yellowstone elk study. Montana Fish and Game Comm., 131 pp.