



## **ASPERGILLOSIS IN CAPTIVE HERRING GULLS 1**

Authors: FRIEND, MILTON, and TRAINER, DANIEL O.

Source: Bulletin of the Wildlife Disease Association, 5(3) : 271-275

Published By: Wildlife Disease Association

URL: <https://doi.org/10.7589/0090-3558-5.3.271>

---

BioOne Complete ([complete.BioOne.org](https://complete.BioOne.org)) is a full-text database of 200 subscribed and open-access titles in the biological, ecological, and environmental sciences published by nonprofit societies, associations, museums, institutions, and presses.

Your use of this PDF, the BioOne Complete website, and all posted and associated content indicates your acceptance of BioOne's Terms of Use, available at [www.bioone.org/terms-of-use](https://www.bioone.org/terms-of-use).

Usage of BioOne Complete content is strictly limited to personal, educational, and non - commercial use. Commercial inquiries or rights and permissions requests should be directed to the individual publisher as copyright holder.

---

BioOne sees sustainable scholarly publishing as an inherently collaborative enterprise connecting authors, nonprofit publishers, academic institutions, research libraries, and research funders in the common goal of maximizing access to critical research.

**ASPERGILLOSIS IN CAPTIVE HERRING GULLS<sup>1</sup>**

MILTON FRIEND and DANIEL O. TRAINER

*Department of Veterinary Science,  
University of Wisconsin, Madison.***Abstract**

Aspergillosis was diagnosed as the cause of mortality during an epizootic in which 32 of 140 captive herring gulls (*Larus argentatus*) died. The cause of disease was attributed to the individual or cumulative stresses of capture, transportation, confinement, and a nutritional deficiency allowing subclinical levels of *Aspergillus fumigatus* fungi present in the gulls at the time of capture to produce overt disease.

**Introduction**

Naturally occurring aspergillosis has been reported for various species of wild mammals and birds including free living gulls.<sup>2,4,5,7,8,9,10,15</sup> The bibliography of avian mycosis by Chute, O'Meara and Barden<sup>3</sup> lists more than 100 reports of aspergillosis among birds. The variety of species, geographical locations, and chronology of these reports attests to the ubiquitous

nature of the organisms and frequency of occurrence of the disease. These accounts generally describe individual isolated cases or epizootics attributed to a primary source of infection such as decaying organic matter or moldy feed. This paper described the development of an epizootic resulting from a possible carrier state.

**Case History**

During the period of July 8-13, 1966, a total of 146 flightless first-year herring gulls (*Larus argentatus*) were captured by University of Wisconsin Department of Wildlife Ecology personnel for use as experimental birds in a pesticide study. These gulls were captured on four islands, Hat, Jack and the Two Sisters, located off Door County, Wisconsin, in Green Bay. One hundred and forty of the gulls survived transfer to the State Game Farm at Poynette, Wisconsin and were distributed in groups of five into 12 x 12 foot covered outdoor pens and maintained on a diet of alewives (*Pomdobus pseudo-harengus*).

By July 17, anorexia and lameness were evident in some of the gulls. The first death occurred on July 18 and by July 20 many of the birds appeared sick and signs of respiratory distress were

evident. Mortality occurred almost daily from July 22 through the first week of August and then continued sporadically until August 28, when the 32nd and final death occurred. Gulls collected from all four islands were involved in the die-off (Table 1).

**Findings**

Necropsies were done at the University of Wisconsin Department of Veterinary Science on 12 of the gulls that succumbed in captivity. In seven of these birds, multiple white to cream colored small (2-5 mm.) plague-like lesions were detected along the intestinal tract. Similar lesions were sparsely scattered throughout the lungs and on the pericardial sac of some of the gulls. No other significant gross lesions were observed. Selected tissues from these birds were fixed in 10 percent formalin and histo-

<sup>1</sup> Published with the approval of the Wisconsin Experimental Station Director as Veterinary Science paper No. 608.

TABLE 1. Mortality among captive herring gulls from islands in Green Bay, Wisconsin.

Island	No. Captured	No. Died	% Mortality
Hat	41	10	24.4
Jack	32	3	9.4
Two Sisters	73	19	26.0

logical slides prepared and stained with Haemotoxylin-Eosin as well as Gridley's stain, the latter being a differential stain for fungi.<sup>14</sup> Microscopic examination of these tissues disclosed mycotic structures characteristic of aspergilli.<sup>1</sup>

Ten, live captive gulls were selected for further study. Half were selected because they appeared sick, the other half were chosen as normal birds. Characteristic signs of the disease-suspected gulls were drooping wings and a general unthriftiness as evidenced by a ruffled appearance of the feathers. Two gulls had rales, one a cheesy exudate about the tongue and bill, and another had a similar exudate present about the nares. Trachial swabs from all 10 gulls were streaked on Sabouroud's agar and incubated at room temperature.<sup>11</sup>

*Aspergillus fumigatus* was isolated and identified from five of the 10 birds cultured; four of the isolates came from gulls considered sick and the fifth from a "normal" pen mate. Species identification was based on cultural characteristics and microscopic examination of colonies.<sup>11</sup> These identifications were confirmed by Dr. K. B. Raper at the Department of Bacteriology, University of Wisconsin, Madison.

Two of the gulls from which positive cultures were obtained were killed and necropsied. Intestinal plaques were observed in one of these birds similar to those seen in seven of the original 12 birds which had died and been examined. In addition, plaques were present in the air sacs of this bird. No gross lesions were detected in the other gull, but histological examination of tissues from both birds stained with Gridley's stain revealed hyphal elements characteristic of aspergilli.

A more detailed histological examination of representative tissues from dead gulls was made by Dr. Lars Karstad of the Department of Avian Pathology and Wildlife Diseases, University of Guelph, Ontario. Gulls from which *A. fumigatus* had been isolated had well developed fungal lesions (nodules of necrosis) in the air sacs, lungs, and on the serosa of the intestines. The predominant feature of these lesions was necrosis, with very little reaction other than a pouring in of plasma proteins and granulocytes (Figures 1 and 2).

#### Discussion and Conclusions

There are at least two theories concerning the epizootiology of avian aspergillosis. (1) The ubiquity of the organism suggests that birds, including gulls, may be carriers of the fungi but do not develop overt disease unless stimulated by a decreased resistance of the host elicited by some stress such as an infectious disease, a toxicant, or malnutrition. Threlfall,<sup>15</sup> a proponent of such a hypothesis, theorized that the stress of capture "unmasks" the disease. He also reported young herring gulls are extremely susceptible to aspergillosis and difficult to raise in captivity. (2) Most investigators believe that clinical aspergillosis is the result of a primary exposure where the concentration of spores inhaled exceeds the resistance threshold of the host.<sup>12</sup>

Although the second hypothesis is more widely accepted, evidence gathered during this outbreak suggests that the first theory was true and that the gulls were suffering from a low level chronic infection that escaped detection until reduced vigor of the host allowed overt manifestation of disease to develop.

The acquisition of *A. fumigatus* during captivity was not likely. The gulls were held in large outdoor pens with dirt floors and abundant growing green vegetation. No deposits of litter or uneaten food were present. Frozen alewives was the entire diet offered the gulls and uneaten fish were removed daily and replaced with new fish. No stratum for the buildup of pathogenic aspergilli was evident in the pens. All of the pathogenic

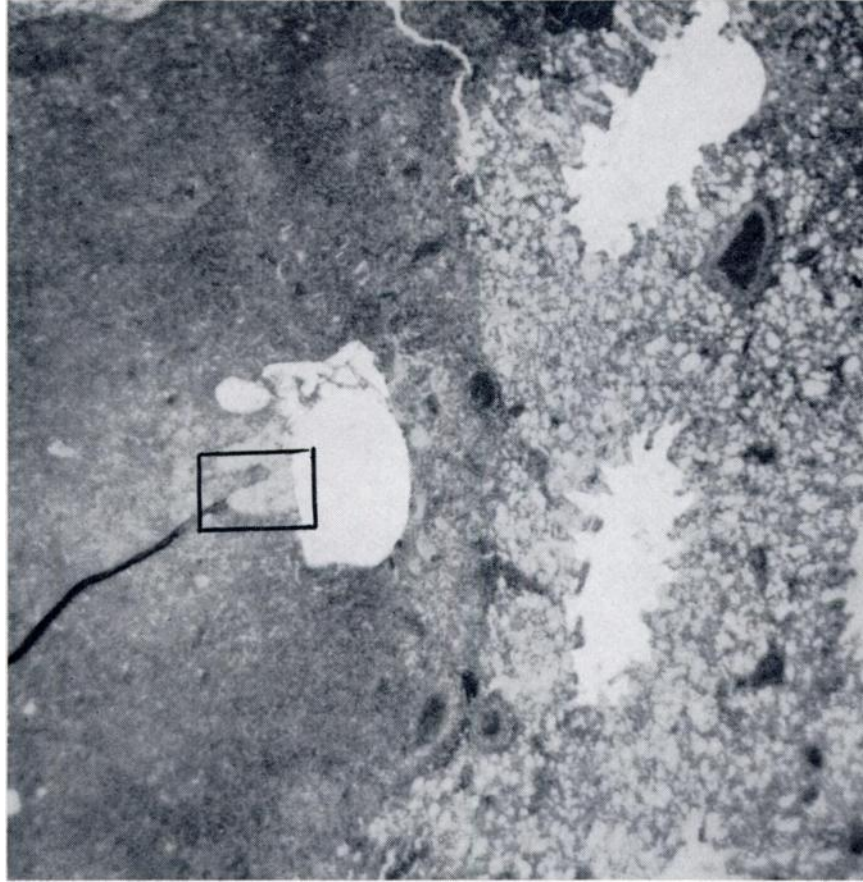


FIGURE 1. *Hematoxylin and eosin-stained section of lung of a herring gull. Necrotic tissue is on the left, more normal lung tissues on the right.*

aspergilli, including *A. fumigatus*, have been found in the soil, but they do not generally constitute a hazard as such in this habitat but rather provide conidia as the inoculum for more favorable substrates such as moldy hay and straw or organic matter compost.<sup>1</sup>

If the source of infection was the feed or within the pens, a larger number of deaths and a trend towards grouping of deaths in specific pens might have been expected. This did not occur. The non-communicability of aspergillosis<sup>12</sup> was illustrated by the failure to obtain posi-

tive cultures from four of five "healthy" birds caged with sick birds.

Although aspergillosis was considered the causative agent responsible for the death of most of these gulls, circumstantial evidence indicates that a combination of factors may have contributed to the mortality. It was thought that a thiamine deficiency due to the exclusive feeding of alewives developed within a week after the confinement of the gulls. The enzyme thiaminase exists in fresh fish and is capable of destroying thiamine.<sup>13</sup> In chickens, thiamine deficiency usually

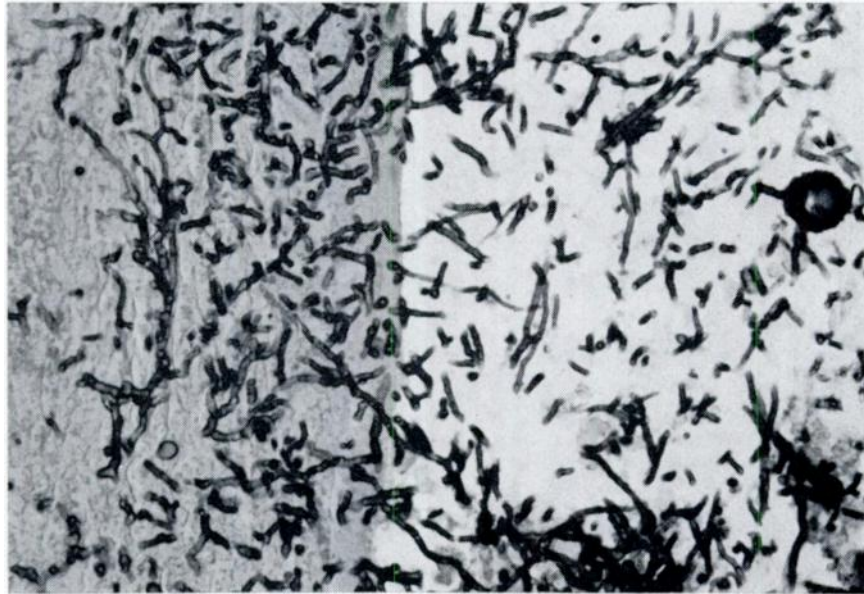


FIGURE 2. Gridley-stained section showing an area such as that in the squared-off portion of figure 1. Hyphae of *Aspergillus* are present in an air space and penetrating necrotic tissues. A fruiting head of *Aspergillus* is also present.

appears in mature birds approximately three weeks after being placed on a thiamine-deficient diet; in young birds the occurrence is more rapid. Initial signs are anorexia followed by weight loss, ruffled feathers, leg weakness and an unsteady gait. Oral administration of vitamin B<sub>1</sub> results in response within a few hours.<sup>13</sup> All of these signs were observed in the gulls.

On August 5, the diet was supplemented with beef and vitamin additives, resulting in immediate recovery of most of the sick birds. Some deaths continued to occur for a short period of time and may have been due to anorexia and the fact that diet supplements for these birds would obviously be of no value. Thiamine deficiency may have been involved in the five fatalities where no gross lesions were seen.

It is concluded that this epizootic resulted from a natural infection of *A.*

*fumigatus* which was being carried in the gulls and was brought to a clinical climax by the individual or cumulative stresses of capture, transportation, confinement, and a nutritional deficiency.

Other instances of clinical aspergillosis which appeared to involve the influence of other factors have also been observed in this laboratory. Severe lesions of aspergillosis appeared in 4 of 37 Canadian geese, *Branta canadensis*, examined during a mid-winter, laboratory confirmed lead poisoning die-off in the vicinity of Horicon Marsh during 1966-1967. In another instance a single Canadian goose from a semi-wild flock at the Kellogg Bird Sanctuary was found dead and when examined had a heavy infestation of the parasite *Syngamus brantae*, in addition to severe gross lesions of aspergillosis. This mortality also occurred during mid-winter. Numerous cases of aspergillosis in captive birds of a variety

of species have been observed and in many of these instances the husbandry practiced eliminates feed and litter as the source of infection, while the stress of captivity or an apparently unrelated injury such as a broken bone appears to be the "triggering" factor leading to overt disease.

#### Literature Cited

1. AUSTWICK, P. K. C. 1965. Pathogenicity. In: Raper, K. B. and D. I. Fennell, *The Genus Aspergillus*. Williams and Wilkins Co., Baltimore.
2. BEAUDETTE, F. R. 1945. Aspergillosis and parasitism in a gull. *Bird-Banding* 16: 99-101.
3. CHUTE, H. L., D. C. O'MEARA and E. S. BARDEN. 1962. A bibliography of avian mycosis. *Miscell. Publ.* 655, Maine Agric. Expt. Station, Orono.
4. COWAN, I. McT. 1945. Aspergillosis in the thayer gull. *Murrelet*. 24: 29.
5. DAVIS, W. A. and L. S. McLUNG. 1940. Aspergillosis in wild herring gulls. *J. Bacteriol.* 40: 321-323.
6. GREEN, R. G., W. E. CARLSON and C. A. EVANS. 1942. The inactivation of vitamin B<sub>1</sub> in diets containing whole fish. *Jour. Nutr.* 23: 165-174.
7. HERMAN, C. M. and G. BOLANDER. 1943. Fungus disease in a glaucous-winged gull. *Condor* 45: 160-161.
8. HERMAN, C. M. and M. N. ROSEN. 1947. Another outbreak of fungus disease in gulls. *Condor* 49: 212.
9. McDIARMID, A. 1955. Aspergillosis in freelifving wild birds. *J. Comp. Path. and Therapeutics* 65: 246-249.
10. POULDING, R. H. 1952. Five cases of aspergillosis in immature gulls. *Ibis* 94: 364-366.
11. RAPER, K. B. and D. I. FENNELL. 1965. *The Genus Aspergillus*. Williams and Wilkins Co., Baltimore.
12. ROSEN, M. N. 1964. Aspergillosis in wild and domestic fowl. *Avian Diseases* 8(1): 1-6.
13. SCOTT, M. L. and L. C. NORRIS. 1965. Vitamins and Vitamin Deficiencies. In: Biester, H. E. and L. H. Schwarte, *Diseases of Poultry*. Iowa State Press, Ames.
14. THOMPSON, S. W. 1966. *Selected Histochemical and Histopathological Methods*. Charles C. Thomas, Springfield.
15. THRELFALL, W. 1967. Diseases and pathological conditions of the Herring Gull (*Larus argentatus* Pontopp.) excluding helminth infestations. *Bull. Wildlife Disease Assoc.* 3: 62-67.