

TESTICULAR TUMORS OF YELLOW PERCH, *Perca flavescens* (Mitchill)

Authors: BUDD, JOAN, and SCHRODER, J. D.

Source: Bulletin of the Wildlife Disease Association, 5(3) : 315-318

Published By: Wildlife Disease Association

URL: <https://doi.org/10.7589/0090-3558-5.3.315>

BioOne Complete (complete.BioOne.org) is a full-text database of 200 subscribed and open-access titles in the biological, ecological, and environmental sciences published by nonprofit societies, associations, museums, institutions, and presses.

Your use of this PDF, the BioOne Complete website, and all posted and associated content indicates your acceptance of BioOne's Terms of Use, available at www.bioone.org/terms-of-use.

Usage of BioOne Complete content is strictly limited to personal, educational, and non - commercial use. Commercial inquiries or rights and permissions requests should be directed to the individual publisher as copyright holder.

BioOne sees sustainable scholarly publishing as an inherently collaborative enterprise connecting authors, nonprofit publishers, academic institutions, research libraries, and research funders in the common goal of maximizing access to critical research.

TESTICULAR TUMORS OF YELLOW PERCH, *Perca flavescens* (Mitchill)

JOAN BUDD and J. D. SCHRODER

*Department of Pathology
Ontario Veterinary College
Guelph, Ontario*

Abstract

In each of three successive years male yellow perch (*Perca flavescens*) examined from South Bay, Lake Huron were found to have testicular tumors. From a total of 2630 males examined 190 were tumor-bearing. Similar tumors were observed also in yellow perch from Lakes Erie and Ontario.

There are few reports of testicular tumors in fish. In their comprehensive review of tumors in fish Schlumberger and Lucké³ noted a report by Plehn of a cystic fibrosarcoma in the testicle of the crucian carp and one by Johnstone of a presumed lymphosarcoma fused with the testis in a herring. Nigrelli and Jakowska² described a spermatocytoma involving the urogenital system in the African lungfish. Wessing⁷ described a tumor of guppies which metastasized to the testis in some cases.

Several large neoplasms from yellow perch were submitted to the Ontario Veterinary College diagnostic laboratory for histopathological examination during the years 1964 and 1965. When it was evident that each submission was a large growth on the gonad, interest was aroused in the prevalence of these neoplasms in the yellow perch population, therefore, beginning in 1966 the yellow perch catch from the experimental fishery in South Bay, Lake Huron was examined at the Ontario Department of Lands and Forests, Fisheries Research Station on South Bay.

Yellow perch taken either in gill nets, using gangs of 1 to 5 inch mesh, or in pound nets with 4 to 6 inch mesh were brought in to the laboratory in the forenoon and were examined as soon as possible. Some fish were dead, but many were alive when landed.

From May to September, 2239 fish were examined, 1497 of which were males (Table 1). Male perch generally ranged from 150 cm to 270 cm fork length with the majority being in the 170-230 cm range.

Each fish was examined for gross lesions using routine necropsy procedures. To detect the smaller lesions a 3X magnifying lamp was used. One hundred of the males examined (6.7%) had what appeared grossly to be abnormal areas on the gonad. Tissues with suspected lesions were fixed in 10% buffered formalin. Lesions as small as 1 mm in diameter and up to 65x35 mm were detected. Usually these were single, involving only one testicle. There appeared to be no common location from anterior to posterior but the growths were usually on the dorso-lateral aspect of a testicle. Often, except with larger lesions, one testicle seemed to be normal and functional even when the tumor bearing part was under-developed in comparison. When large lesions were present both testes were small and undeveloped. No metastasis was noted.

The neoplasms, somewhat shiny in appearance in comparison with the surrounding testicle, were creamy white, firm areas or nodules, either partly embedded in the testicle or protruding from its surface, depending on the diameter

TABLE 1. Occurrence of Tumors in Yellow Perch

Year	Fish Examined		% Testicular Infection	
	Total	No. Males	Tumors	tion
1966	2239	1497	100	6.7
1967	911	833	51	6.1
1968	387	300	39	13.0
Total	3537	2630	190	7.2

of the nodule. The larger lesions were somewhat ovoid, always firm and in only one or two cases showed any sign of necrosis centrally. Blood vessels were sometimes visible near the surface. They did not appear to be encapsulated, and were rarely pedunculated. Males containing large nodules appeared to have distended abdomens, resembling ripe females prior to spawning (Figure 1). Otherwise there was no external indication that a tumor was present.

Histopathology

Small lesions, with surrounding testicular tissue, and sections of the larger lesions were embedded in paraffin, sectioned, mounted on glass slides and stained with hematoxylin and eosin.

In the smallest tumors a wedge of abnormal tissue was evident in the otherwise normal testicular tissue (Figure 2). This was presumed to be an early stage in the growth of the tumor. This wedge consisted of elongated spindle shaped cells with indistinct outline and elongated pleomorphic nuclei, in thickened,

rather dense bands or swirls, often showing laterally a few compressed tubules containing spermatozoa. Larger tumors contained similar whorled elongated cells with areas between of more vesicular type cells. Some of the nuclei in these swirls appeared to be aligned in a palisade arrangement, but this was not seen in the majority of the sections. In some tumors the tissue was more dense than in others. Mitosis was evident in varying degrees in all sections. The number and diameter of the blood vessels varied but these were not a prominent feature.




FIGURE 1. Large gonadal tumor of male yellow perch, showing distended abdomen

This soft tissue tumor of mesenchymal origin has proved difficult to differentiate as to cell type. It appears to be a connective tissue tumor, possibly of nerve sheath or smooth muscle origin. To date, differential stains using Masson's, Van Gieson's and periodic acid Schiff me-

thods' have failed to help in making a definitive diagnosis. It appears to be non malignant. Further studies are being carried on in an attempt to classify the tumor more specifically. Results of this study will be the subject of a second paper.

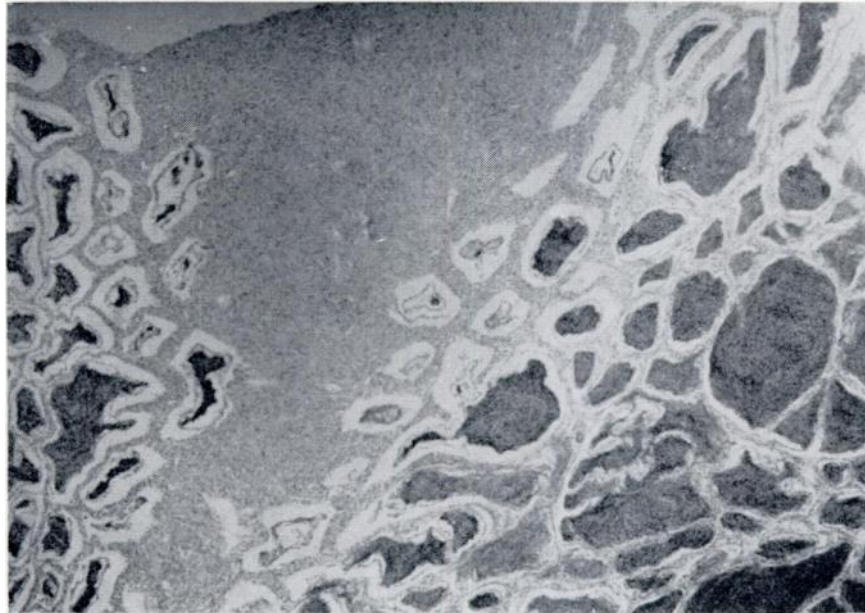


FIGURE 2. *Early tumor surrounded by normal tubules filled with ripe sperm in a yellow perch testis*

Discussion

Continued sampling of the catch of yellow perch from South Bay, has resulted in the collection of 190 testicular tumors from 2630 males (Table 1). Although no comparison has been made with the frequency of occurrence of tumors in yellow perch populations in other lakes, specimens examined indicate that male yellow perch from both Lakes Erie and Ontario bear tumors identical in all respects with those described from

yellow perch in South Bay, Lake Huron.

This tumor prevalence is comparable with that of the epidermal papillomas in free living marine populations of certain pleuronectid fish, as reported by Wellings et al.^{5,6}

Schlumberger's⁷ report of the eight to ten percent infection rate of nerve sheath tumors in goldfish was from a more confined population in a lagoon.

Acknowledgments

The authors gratefully acknowledge the assistance of the directors and personnel of the Ontario Department of Lands and Forests, Fisheries Research Station at South Bay, Lake Huron, without whose cooperation this work could not have been accomplished. Appreciation is expressed also to Dr. A. Dechtiar and Mr. Keith Marshall for extra specimens they collected.

References

1. LILLIE, R. D. 1948. Histopathologic Technique. Blakiston Co., Toronto.
 2. NIGRELLI, R. F. and SOPHIE JAKOWSKA. 1953. Spontaneous neoplasms in fishes. VII. A spermatocytoma and renal melanoma in an African Lungfish, (*Protopterus annectens* (Owen)). Zoologica. 38: 109-112.
 3. SCHLUMBERGER, H. G. and B. LUCKE. 1948. Tumors of fishes, amphibians and reptiles. Cancer Res. 8: 657-754.
 4. SCHLUMBERGER, H. G. 1952. Nerve sheath tumors in an isolated goldfish population. Cancer Res. 12: 890-899.
 5. WELLINGS, S. R., R. G. CHUINARD and M. BENS. 1965. A comparative study of skin neoplasms in four species of pleuronectid fishes. Ann. N.Y. Acad. Sci. 126: 479-501.
 6. WELLINGS, S. R., R. A. COOPER and R. G. CHUINARD. 1966. Skin tumors of pleuronectid fishes in Puget Sound, Washington. Bull. W.D.A. 2: 68.
 7. WESSING, A. 1959. A malignant virus-caused tumor in ornamental tropical fishes. Naturwissenschaften. 46: 517-518. Excerpta Medica 16: 868 (original not seen).
-