

AIR SAC PARASITES OF THE GENUS *Serratospiculum* IN FALCONS

Authors: WARD, F. PRESCOTT, and FAIRCHILD, DAVID G.

Source: Journal of Wildlife Diseases, 8(2) : 165-168

Published By: Wildlife Disease Association

URL: <https://doi.org/10.7589/0090-3558-8.2.165>

The BioOne Digital Library (<https://bioone.org/>) provides worldwide distribution for more than 580 journals and eBooks from BioOne's community of over 150 nonprofit societies, research institutions, and university presses in the biological, ecological, and environmental sciences. The BioOne Digital Library encompasses the flagship aggregation BioOne Complete (<https://bioone.org/subscribe>), the BioOne Complete Archive (<https://bioone.org/archive>), and the BioOne eBooks program offerings ESA eBook Collection (<https://bioone.org/esa-ebooks>) and CSIRO Publishing BioSelect Collection (<https://bioone.org/csiro-ebooks>).

Your use of this PDF, the BioOne Digital Library, and all posted and associated content indicates your acceptance of BioOne's Terms of Use, available at www.bioone.org/terms-of-use.

Usage of BioOne Digital Library content is strictly limited to personal, educational, and non-commercial use. Commercial inquiries or rights and permissions requests should be directed to the individual publisher as copyright holder.

BioOne is an innovative nonprofit that sees sustainable scholarly publishing as an inherently collaborative enterprise connecting authors, nonprofit publishers, academic institutions, research libraries, and research funders in the common goal of maximizing access to critical research.

AIR SAC PARASITES OF THE GENUS *Serratospiculum* IN FALCONS

F. PRESCOTT WARD and DAVID G. FAIRCHILD
Biomedical Laboratory, Edgewood Arsenal, Maryland 21010

Abstract: Nematodes of the genus *Serratospiculum* are common and usually innocuous inhabitants of the air sacs of several species of falcons. However, the abdominal and thoracic air sacs of a prairie falcon (*Falco mexicanus*) that died in respiratory distress were filled with hundreds of adult parasites. Illnesses in a peregrine (*Falco peregrinus tundrius*) and another prairie falcon, tentatively diagnosed as serratospiculiasis, were successfully treated with thiabendazole given orally. Embryonated ova were found in the feces of 8 of 73 falcons representing five species.

INTRODUCTION

Air sac parasites of the genus *Serratospiculum* have been reported often in falcons from many parts of the world.^{1,2,7,9,10} The parasites have frequently been found incidentally at necropsy.^{1,9} Although they have been described as innocuous organisms even when present in large numbers,³ the authors of one study assumed that heavy air sac infections of *S. amaculata* were major contributing causes in the deaths of five prairie falcons (*Falco mexicanus*).²

This report describes the lesions in a prairie falcon that probably died due to the air sac parasites, and discusses signs, diagnosis, and therapy of serratospiculiasis in two other falcons. The occurrence of typical embryonated ova and other parasite eggs in fecal specimens from 73 wild and captive falcons is also tabulated.

Case 1

A female prairie falcon, about 18 months old, was captured in New Mexico. She appeared to be in excellent health and plumage, but her feces were brown and watery. About 2 weeks after capture, the falcon's respiration became accelerated, and she refused food. She died within 2 days. At necropsy the thoracic and abdominal air sacs contained tangles of hundreds of large nematodes, later identified as *S. amaculata*. Numerous embryonated ova were seen when a fecal specimen was examined microscopically; the mean dimensions of eleven ova were

52 μ x 30 μ . The anterior portion of the proventriculus was covered with a thick, yellow, adherent material. Representative tissues from most organs were fixed in 10% neutral buffered formalin, embedded in paraffin, sectioned at 6 μ , and stained with hematoxylin and eosin.

Other than mild congestion and edema, no lesions were seen in the lungs. The lesion in the proventriculus was an ulcer in the epithelium covered with caseous exudate. Material which appeared to be degenerated parasite larvae, often surrounded by some calcification, was interspersed throughout the exudate. Other tissues were normal.

Case 2

An immature female peregrine falcon (*Falco peregrinus tundrius*) was captured during the autumn migration on the Maryland coast. She appeared healthy, and a fecal specimen collected shortly after capture did not contain parasite ova. Her diet consisted almost exclusively of entire fresh pigeon carcasses. Four months after capture, her appetite suddenly decreased and she regurgitated several hours after each feeding. On the 3rd day of illness, a flat yellow plaque (about 5 mm in diameter) appeared on the right side of the pharynx. The plaque was removed easily, and the underlying epithelium appeared to be intact.

The lesion and the history seemed

typical of trichomoniasis, but no protozoa were seen when the plaque and saliva were examined microscopically. However, this material did contain many embryonated ova (Figure 1). The feces contained a few trematode ova, a few capillarid ova, and many embryonated ova (mean dimensions, $51\mu \times 34\mu$). The falcon was treated orally with a single dose of thiabendazole* at a dosage of 40 mg/lb, and recovered uneventfully. About 20 months later, only one capillarid ovum was observed in direct microscopic examination of several slides of feces from this bird.

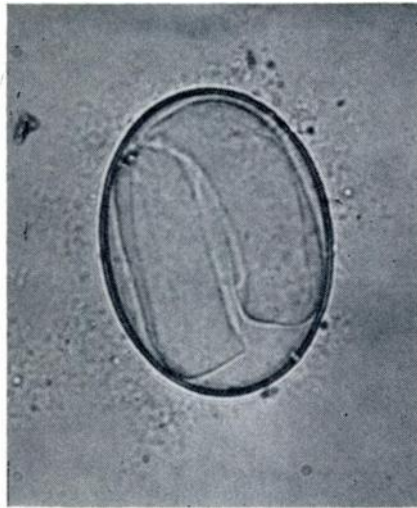


FIGURE 1. Parasite ovum typical of *Serratospiculum* sp. in saliva from a peregrine falcon.

Case 3

A male and a female prairie falcon were taken from the nest. After nearly 5 months on a diet of fresh pigeon carcasses, both birds suddenly began vomiting, eating less, and losing weight. Yellow plaque-like lesions appeared in the mouth and pharynx of both birds. They were treated with two trichomonocidal drugs

by the owner for more than a week with no response. The female escaped, but the male was presented for examination.

No trichomonads or ova were seen in a mouth scraping examined microscopically. The feces contained countless embryonated ova averaging $54\mu \times 35\mu$. The bird was treated orally with thiabendazole at a dosage of 40 mg/lb, and began to eat normally and gain weight within 48 hours. Two weeks later, a few embryonated ova were seen in another fecal specimen, and the dose of thiabendazole was repeated.

INCIDENCE OF EMBRYONATED OVA IN FALCONS

During a 5 year period, fecal specimens were obtained from 73 falcons of seven species. Parasite ova were concentrated by mixing feces with a saturated solution of sodium nitrate; tapeworm segments were observed grossly. Results are shown in Table 1. Eight falcons, including three discussed earlier in this report, had embryonated ova either typical of the genus *Serratospiculum* or spirurid parasites. In one immature prairie falcon the ova were slightly smaller ($45\mu \times 30\mu$) than those from the previous cases. This bird was later necropsied, and several spirurids collected from the proventriculus were identified as *Hartertia* sp.⁷

Embryonated ova from a wild adult peregrine falcon fell into two distinct size groups ($55\mu \times 43\mu$ and $50\mu \times 30\mu$), suggesting infections with more than one species producing this type of egg. Ova from the lanner, lugger, and merlins were not measured.

DISCUSSION

Based on literature accounts^{2,6} and the cases seen in this study, serratospiculiasis is probably not an innocuous infection. The clinical syndrome could involve respiratory difficulty due to pathologic changes in lungs and air sacs,² or gastro-

*Thiabendazole®, Sheep and Goat Wormer, Merck & Co., Inc., Rahway, New Jersey.

TABLE 1. Occurrence of Parasite Ova in Fecal Specimens from Falcons.

Species	Captive or Wild	Adult or Immature	No. of Falcons	Trematode Ova	Cestode Segments	Ascarid Ova	Capillariid Ova	Embryonated Ova		Proportion of Group Parasitized
								Capillariid	Embryonated	
Peregrine	Wild	Adult	3	2	1	0	2	1	0	3/3
Peregrine	Wild	Immature	24	0	0	0	1	0	0	1/24
Peregrine	Captive	Adult	8	0	1	0	0	0	0	1/8
Peregrine	Captive	Immature	19	3	8	1	2	1	1	9/19
Prairie	Captive	Adult	1	0	0	0	0	1	1	1/1
Prairie	Captive	Immature	7	0	0	0	0	2	2	2/7
Gyr Falcon ^a	Captive	Adult	2	0	1	0	0	0	0	1/2
Lanner ^b	Captive	Adult	4	1	0	0	0	1	1	2/4
Lugger ^c	Captive	Unknown	1	0	0	0	0	1	1	1/1
Indian Merlin ^d	Captive	Immature	2	2	0	0	0	1	1	2/2
Kestrel ^e	Wild	Unknown	1	0	0	0	0	0	0	0/1
Kestrel	Captive	Immature	1	1	0	0	0	0	0	1/1

^a *Falco rusticolus*^b *Falco biarmicus*^c *Falco jugger*^d *Falco chicquera*^e *Falco sparverius*

intestinal signs possibly due to invasion or irritation of the proventricular mucosa by larvae or ova. In one case," the incidental discovery of air sac parasites in a peregrine could have been related to an unexplained "ulceration of the lining membrane of the thoracic portion of the gullet which had perforated to produce pericarditis."

A clinical diagnosis of serratospiculiasis could be based on radiographic evidence of parasites in the abdominal or thoracic air sacs, the occurrence of embryonated ova in the mouth, especially if associated with small plaque-like lesions, a history of respiratory distress or signs of gastrointestinal upset, and finding typical embryonated ova in the feces.

Measurements appear to be valuable in differentiating *Serratospiculum* ova from those of spirurid parasites of the gastrointestinal tract. For example, dimensions of ova from Case 1 ($52\mu \times 30\mu$), Case 2 ($51\mu \times 34\mu$), and Case 3 ($54\mu \times 35\mu$) were similar to Wehr's measurements ($54\mu \times 29\mu$), and fall within the range given by Bigland, *et al.*² ($45\text{-}57\mu \times 30\text{-}35\mu$). Also, ova of several spirurids have thicker shells than *Serratospiculum* sp.¹⁰

Although the efficacy of thiabendazole in killing adult parasites or larvae could not be determined in this study, use of the drug coincided with clinical improvement in two cases of suspected serratospiculiasis.

LITERATURE CITED

1. BAIN, O., and G. VASSILIADES. 1969. Cycle evolutif d'un Dicheilonematinae, *Serratospiculum tendo*, Filaire parasite du faucon. Ann. Parasitol. Hum. Comp. 44: 595-604.
2. BIGLAND, C. H., S-K. LIU, and MARY LOU PERRY. 1964. Five cases of *Serratospiculum amaculata* (Nematoda: Filarioidea) infection in prairie falcons (*Falco mexicanus*). Avian Dis. 8: 412-419.
3. COOPER, J. E. 1969. Some diseases of birds of prey. Vet. Record 84: 454-457.
4. COOPER, J. E. 1969. Two cases of pox in recently imported peregrine falcons (*Falco peregrinus*). Vet. Record 85: 683-684.
5. EZZAT, M. A., and G. TADROS. 1958. Contribution to the helminth fauna of Belgian Congo birds. Ann. Mus. Congo Belge, Tervuren, Zool. 69: 1-81.
6. JEFFERIES, D. J., and I. PRESST. 1966. Post-mortems of peregrines and lanners with particular reference to organochlorine residues. British Birds. 59: 49-64.
7. SKRJABIN, K. I. 1954. *Key to Parasitic Nematodes*, Vol. IV. Izdatyelstvo Akademii Nauk SSSR, Moscow.
8. WARD, F. P., D. G. FAIRCHILD, and JEANNE V. VUICICH. 1970. Pulmonary aspergillosis in prairie falcon nest mates. J. Wildl. Dis. 6: 80-83.
9. WEHR, E. E. 1938. New genera and species of the nematode superfamily Filarioidea. I. *Serratospiculum amaculata*, n. sp. Proc. Helminth. Soc. Wash. 5: 59-60.
10. YORKE, W., and P. A. MAPLESTONE. 1962. *The Nematode Parasites of Vertebrates*. Pages 427-428. Hafner Publishing Company, New York.

Received for publication December 14, 1971