



HERPESVIRUS INFECTION IN THE BLACK RAT (*Rattus rattus*)

Author: Munday, B. L.

Source: Journal of Wildlife Diseases, 9(2) : 133-135

Published By: Wildlife Disease Association

URL: <https://doi.org/10.7589/0090-3558-9.2.133>

BioOne Complete (complete.BioOne.org) is a full-text database of 200 subscribed and open-access titles in the biological, ecological, and environmental sciences published by nonprofit societies, associations, museums, institutions, and presses.

Your use of this PDF, the BioOne Complete website, and all posted and associated content indicates your acceptance of BioOne's Terms of Use, available at www.bioone.org/terms-of-use.

Usage of BioOne Complete content is strictly limited to personal, educational, and non - commercial use. Commercial inquiries or rights and permissions requests should be directed to the individual publisher as copyright holder.

BioOne sees sustainable scholarly publishing as an inherently collaborative enterprise connecting authors, nonprofit publishers, academic institutions, research libraries, and research funders in the common goal of maximizing access to critical research.

HERPESVIRUS INFECTION IN THE BLACK RAT (*Rattus rattus*)

B. L. MUNDAY, Mt. Pleasant Laboratories, P.O. Box 46, Launceston South, Tasmania 7250, Australia.

Abstract: A condition characterized by hepatomegaly, splenomegaly and pulmonary echymoses was found in a wild black rat. The disease was successfully transmitted to laboratory rats and mice by intraperitoneal, intranasal and intracerebral inoculations. Microscopy indicated that the condition was probably caused by a herpesvirus.

INTRODUCTION

In discussing the occurrence of a herpes-like viral infection in a prairie falcon Ward *et al.*¹ mentioned that similar conditions have been described in owls, chickens, parrots, pigeons and chinchillas. Also McCully *et al.*² and Hinze³ have isolated herpesviruses from wild African elephants and cottontail rabbits.

It is the purpose of this communication to record a herpetic infection in a wild black rat (*Rattus rattus*).

MATERIALS AND METHODS

On 2/3/72 a dead, male black rat was forwarded to the laboratory accompanied by a report that a number of dead rats had been found in the vicinity of the dairy on a farm in north-eastern Tasmania.

A necropsy was performed and the following procedures were carried out:—

1. Heart blood, liver and spleen samples were sown on sheep blood and McConkey agar plates which were incubated at 37 C for 48 hours.
2. Brain, liver, spleen, kidney and lung tissues were fixed in 10% buffered formal-saline, sectioned at 5 μ and stained with haematoxylin and eosin (H & E) and periodic-acid Schiff (PAS).
3. Liver was ground to about a 10% suspension with antibiotic saline (100 units penicillin, 10 μ g streptomycin per ml), strained through glass wool and injected intraperitoneally into mice, hooded Wistar rats and a guinea pig at a dose rate of 0.1 ml per ani-

mal. In subsequent passages the intracerebral and intranasal routes also were used.

4. Fresh and frozen material was forwarded to the Commonwealth Scientific and Industrial Research Organization's Animal Health Laboratory, Parkville, Victoria for virological examination.

RESULTS

No bacteria were isolated on aerobic culture.

Gross lesions in the rat consisted of numerous pulmonary echymoses 1-2 mm in diameter, hepatomegaly with focal necrosis (lesions approx. 0.5 mm in diameter) and splenomegaly.

Microscopic lesions were characterized by necrosis, giant cell formation and the presence of Cowdry type-A inclusion bodies. Liver changes consisted of scattered foci of hepatocellular necrosis surrounded by a zone containing giant cells, proliferating Kupffer cells and a few neutrophils. Inclusion bodies were present in the nuclei of the giant cells and in some of the hepatocytes at the edge of the lesion (Fig. 1). In the spleen there was evidence of extensive haemorrhage, depletion of lymphocytes and giant cell formation; inclusion bodies were found in the nuclei of the giant cells. Haemorrhage was also a feature of the pulmonary lesions and a few giant cells were present close to the branches of the pulmonary artery; inclusion bodies were present also in swollen alveolar cells. Apart from disseminated foci of haemorrhage there were no significant brain lesions. No significant lesions

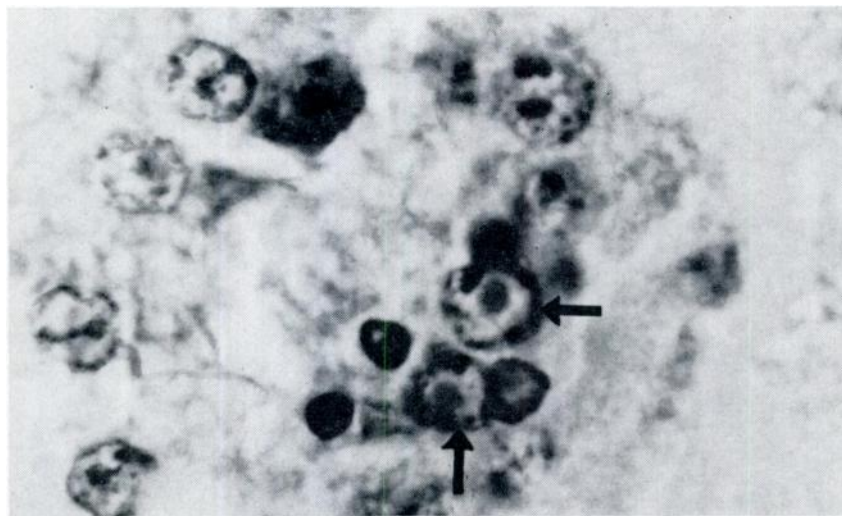


FIGURE 1. Hepatocytes of *Rattus rattus* showing Cowdry type-A inclusion bodies (arrows).

were detected in the pancreas or kidneys.

The infection was successfully transmitted to laboratory rats and mice which died at 5 to 10 days after inoculation. Lesions in the experimental animals were essentially the same as in the original rat, but some variation did occur according to the route of inoculation, e.g., the animals dosed intranasally had severe pneumonitis. It was of particular interest that no obvious spread occurred to rats, mice, guinea pigs or rabbits which were kept in close proximity to the cages housing the experimental animals.

The Victorian workers (W. Snowdon and J. E. Petersen, pers. comm.) reported that a cytopathogenic agent was isolated in tissue culture (BHK 21 cells). Preliminary studies of this agent's effects on tissue cultures, its physical and chemical properties and its morphology under the electron microscope have suggested that the agent is a herpesvirus. These workers also found that the isolate would produce disease in rats and mice, but not in rabbits.

DISCUSSION

Pseudorabies is not known to occur in Tasmania nor were the lesions in the black rat typical of this disease nor of cytomegalovirus infection.² Despite the fact that a number of herpes-like diseases have been recorded in domestic and wild animals, this particular condition does not appear to have been described, even in laboratory rats.¹ However, it is possible that the haemorrhagic pneumonia of mice (*Mus musculus*) described by Ryan and Jones⁷ could have been the same condition. Unfortunately, these authors did not investigate the disease beyond attempting isolation of bacteria. A number of native murids are found in Tasmania, of which the velvet-furred rat (*Rattus lutreolus*) and the long-tailed rat (*Pseudomys higginsi*) are known to occur in the region where the dead animal was found.^{3,4} It is possible that a latent infection in these species might have spread to the introduced black rat and produced overt disease.

Acknowledgements

Mr. R. Berwick, Ringarooma provided the original specimen and Dr. R. W. Mason, Mt. Pleasant Laboratories assisted with the animal inoculations.

LITERATURE CITED

1. COTCHIN, E., and F. J. C. ROE. 1967. *Pathology of Laboratory Rats and Mice*. Blackwell Scientific Publications, Oxford and Edinburgh.
2. DORMAN, D. C. 1972. Herpesviruses. *Virology and Virus Diseases*. Proceedings No. 16 of Courses for Veterinarians. The Post-graduate Committee in Veterinary Science, University of Sydney pp. 243-256.
3. GREEN, R. H. 1967. The murids and small dasyurids in Tasmania. Parts 1 and 2. *Rec. Queen Vict. Mus.*, No. 28, 19 pp.
4. GREEN, R. H. 1967. The murids and small dasyurids in Tasmania. Parts 3 and 4. *Rec. Queen Vict. Mus.*, No. 32, 19 pp.
5. HINZE, H. C. 1971. New member of the herpesvirus isolated from wild cottontail rabbits. *Infection and Immunity* 3: 350-354.
6. McCULLY, R. M., P. A. BASSON, J. G. PIENAAR, B. J. ERASMUS, and E. YOUNG. 1971. Herpes nodules in the lung of the African elephant (*Luxodonata africana* (Blumenback, 1797)). *Onderstepoort J. vet. Res.* 38: 225-236.
7. RYAN, G. E., and E. L. JONES. 1972. A Report on the Mouse Plague in the Murrumbidgee and Coleambally Irrigation Areas, 1970. New South Wales Government Printer, 60 pp.
8. WARD, F. P., D. G. FAIRCHILD, and JEANNE V. VUICICH. 1971. Inclusion body hepatitis in a prairie falcon. *J. Wildl. Dis.* 7: 120-124.

Received for publication August 7, 1972
