

Capillaria hepatica (NEMATODA: TRICHURIDAE) IN A COYOTE (Canis latrans)

Authors: WOBESER, G., and ROCK, T. W.

Source: Journal of Wildlife Diseases, 9(3) : 225-226

Published By: Wildlife Disease Association

URL: <https://doi.org/10.7589/0090-3558-9.3.225>

The BioOne Digital Library (<https://bioone.org/>) provides worldwide distribution for more than 580 journals and eBooks from BioOne's community of over 150 nonprofit societies, research institutions, and university presses in the biological, ecological, and environmental sciences. The BioOne Digital Library encompasses the flagship aggregation BioOne Complete (<https://bioone.org/subscribe>), the BioOne Complete Archive (<https://bioone.org/archive>), and the BioOne eBooks program offerings ESA eBook Collection (<https://bioone.org/esa-ebooks>) and CSIRO Publishing BioSelect Collection (<https://bioone.org/csiro-ebooks>).

Your use of this PDF, the BioOne Digital Library, and all posted and associated content indicates your acceptance of BioOne's Terms of Use, available at www.bioone.org/terms-of-use.

Usage of BioOne Digital Library content is strictly limited to personal, educational, and non-commercial use. Commercial inquiries or rights and permissions requests should be directed to the individual publisher as copyright holder.

BioOne is an innovative nonprofit that sees sustainable scholarly publishing as an inherently collaborative enterprise connecting authors, nonprofit publishers, academic institutions, research libraries, and research funders in the common goal of maximizing access to critical research.

Capillaria hepatica (NEMATODA: TRICHURIDAE) IN A COYOTE (*Canis latrans*)

G. WOBESER, Department of Veterinary Pathology, Western College of Veterinary Medicine, University of Saskatchewan, Saskatoon, Saskatchewan, Canada

T. W. ROCK, Fisheries & Wildlife Branch, Department of Natural Resources, Saskatoon, Saskatchewan

Abstract: *Capillaria hepatica* (Bancroft, 1893) infection was diagnosed on the basis of histopathology in a juvenile female coyote (*Canis latrans*) from southern Saskatchewan. This is the first report of *C. hepatica* from this host and the second record of this parasite from a wild carnivore.

Capillaria hepatica (Bancroft, 1893) is primarily a parasite of rodents but has been reported from many species of mammals¹ including the house cat,² the domestic dog³ and one wild carnivore, the spotted skunk (*Spilogale putorius*).⁶ At least ten *bona fide* cases have been reported in humans.¹

CASE REPORT

On July 10, 1971, an apparently normal juvenile female coyote (*Canis latrans*) was collected near Eyebrow, Saskatchewan, as part of a study on the species.

The intact animal was frozen. Subsequently at necropsy, numerous randomly distributed white serpentine tracts, 1.0-2.0 mm wide, were observed within the hepatic parenchyma. Portions of liver were fixed in 10 percent neutral buffered formalin, embedded in paraffin, sectioned at 5 μ and stained with hematoxylin and eosin.

Microscopically, the hepatic lesions were found to consist of a granulomatous reaction composed of fibrous tissue with histiocytes, lymphocytes and occasional plasma cells surrounding groups of bipolar, operculate ova and calcified debris (Fig. 1). The mean dimensions of ten ova were 54.1 x 30.7 μ . Masses of ova appeared to be randomly distributed

throughout the hepatic parenchyma. No recognizable portions of adult parasites were seen.

DISCUSSION

This is apparently the first report of *C. hepatica* infection in the coyote. *C. hepatica* was not detected in three other juvenile and two adult coyotes collected from the same area during 1971, nor in 11 coyotes of all ages from other areas of the province examined during 1971 and 1972. *C. hepatica* infection has not been recognized in any of 1553 Saskatchewan dogs necropsied in the diagnostic laboratory, Department of Veterinary Pathology, Western College of Veterinary Medicine, between February 1, 1966 and November 1, 1972.

Ova present in the liver of host animals are non-infective, requiring exposure of several weeks duration to the external environment for maturation.^{4,7} Subsequent ingestion of these ova by a mammal results in hepatic infection. The life span of adult *C. hepatica* in the livers of rodents has been reported to be from 28 to 60 days.^{8,7} If a similar life span occurs in the coyote, initial infection in this case (estimated age 8 weeks) must have occurred early in life, since no intact adult worms were detected either grossly or in several histologic sections of the liver.

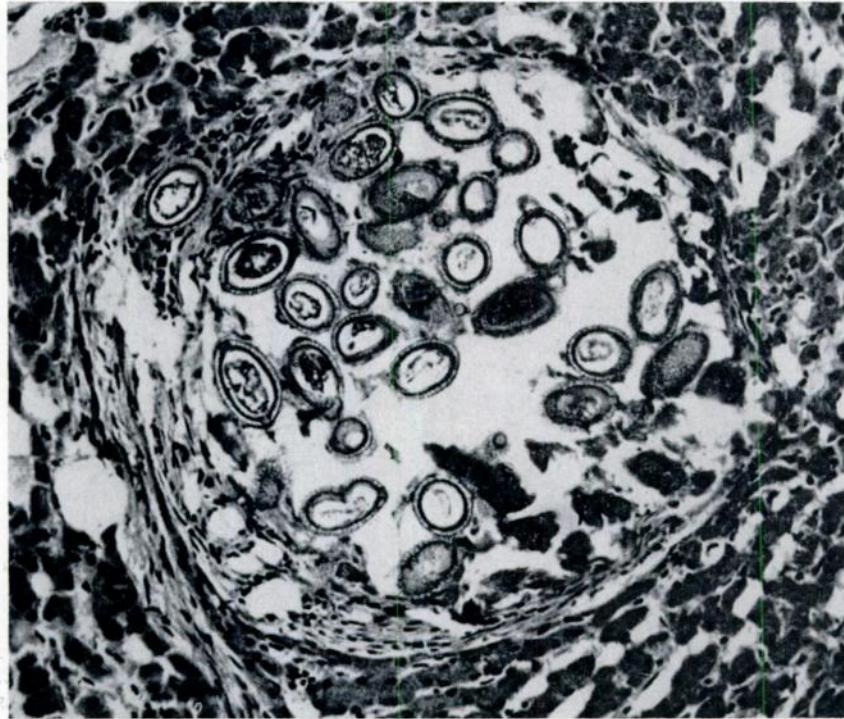


FIGURE 1. Coyote liver. Bipolar operculate ova of *C. hepatica* and calcified debris surrounded by small amount of fibrous tissue and a few lymphoid cells. Hematoxylin and eosin X 210.

LITERATURE CITED

1. AREAN, M. 1971. Capillariasis p. 666-676 In R. A. MARCIAL-ROJAS *Pathology of Protozoal and Helminthic Diseases*. Williams-Wilkins Co., Baltimore.
2. BAYLIS, H. A. 1931. On the structure and relationship of the nematode *Capillaria (Hepticola) hepatica* Bancroft. *Parasit.* 23: 533-534.
3. BECK, J. W. and M. BERVERLY-BURTON. 1968. The pathology of *Trichuris*, *Capillaria* and *Trichinella* infections. *Helminth. Absts.* 37: 1-26.
4. FREEMAN, R. S. and K. A. WRIGHT. 1960. Factors concerned with the epizootiology of *Capillaria hepatica* (Bancroft, 1893) (Nematode) in a population of *Peromyscus maniculatus* in Algonquin Park, Canada. *J. Parasit.* 46: 373-382.
5. LAYNE, J. N. and C. E. WINEGARNER. 1971. Occurrence of *Capillaria hepatica* (Nematode: Trichuridae) in the spotted skunk in Florida. *J. Wildl. Dis.* 7: 256-257.
6. OLSON, O. W. 1962. *Animal Parasites: Their Biology and Life Cycles*. Burgess Publ. Co. Minneapolis. 346 p.
7. WRIGHT, K. A. 1961. Observations on the life cycle of *Capillaria hepatica* (Bancroft, 1893) with a description of the adult. *Can. J. Zool.* 39: 167-181.
8. WRIGHT, W. H. 1930. *Hepaticola hepatica* in dogs. *J. Parasit.* 17: 54-55.

Received for publication 23 January 1973