

Armillifer brumpti 1 (PENTASTOMIDA) IN A BOA IN CANADA

Authors: SLOCOMBE, J. OWEN D., and BUDD, JOAN

Source: Journal of Wildlife Diseases, 9(4) : 352-355

Published By: Wildlife Disease Association

URL: <https://doi.org/10.7589/0090-3558-9.4.352>

BioOne Complete (complete.BioOne.org) is a full-text database of 200 subscribed and open-access titles in the biological, ecological, and environmental sciences published by nonprofit societies, associations, museums, institutions, and presses.

Your use of this PDF, the BioOne Complete website, and all posted and associated content indicates your acceptance of BioOne's Terms of Use, available at www.bioone.org/terms-of-use.

Usage of BioOne Complete content is strictly limited to personal, educational, and non - commercial use. Commercial inquiries or rights and permissions requests should be directed to the individual publisher as copyright holder.

BioOne sees sustainable scholarly publishing as an inherently collaborative enterprise connecting authors, nonprofit publishers, academic institutions, research libraries, and research funders in the common goal of maximizing access to critical research.

*Armillifer brumpti*¹ (PENTASTOMIDA) IN A BOA IN CANADA

J. OWEN D. SLOCOMBE and JOAN BUDD²

Abstract: A tree boa (*Sanzania madagascariensis*) developed a fatal respiratory disease 3 months after importation from Madagascar. Twelve adult pentastomids, *Armillifer brumpti* Giglioli 1922, and numerous pentastomid ova were found in the lung and air sac. Chronic irritation of the lung by the parasite and a bacterial infection probably caused death. A literature search indicated that this is the first recorded observation of *A. brumpti* in the Americas, and that *Armillifer* species have not been found in native American snakes.

HISTORY

An Ontario resident purchased three Madagascar tree boas (*Sanzania madagascariensis*) from a dealer in San Francisco. The boas came from the Island of Madagascar, probably in late February, 1971, with a shipment of imported animals. The boas arrived in Canada on March 4, 1971 via San Francisco and Philadelphia. The snakes received laboratory reared rodents as their sole diet after their arrival in North America.

CLINICAL SIGNS

In mid-May 1971, thick mucus was observed in the mouth of one of the snakes. By late May, the snake was lethargic, anorectic, dyspneic and was taken to a veterinarian. Culture from a throat swab yielded bacteria of the genera *Aeromonas*, *Proteus* and *Pseudomonas*, which proved sensitive to chlorhexidine diacetate*, neomycin and sulfachloropyridazine**. Two daily doses (125 mg each) of the latter were administered orally, and the snake was isolated. Tenacious and yellowish to dark brown mucus con-

tinued to be evident and increased in amount. The snake appeared to improve; it was more active, difficult to restrain and breathing was less laboured. Despite continuous antibiotic therapy, the snake died on June 12, 1971. The other snakes in the colony were feeding well and were presumed to be healthy. A necropsy was performed at the Ontario Veterinary College, one day after death.

POST MORTEM FINDINGS

The general body condition was fair. The entire length of the trachea contained small quantities of brownish, tenacious mucus. The pleural surface of the lung was distended by dark red consolidated areas giving the impression of lobules. Pale areas were visible on the cut surface, and the lumen of the lung contained dark red masses of blood, mucus, and necrotic tissue (Figure 1). Histologically, the bronchial septa was oedematous and many of the infundibula were occluded by a mass consisting of necrotic cellular debris, hemorrhage, mucus, and strands of fibrin-like material. Bacteria were present in the cellular

¹ Specimens have been forwarded to the American Museum of Natural History, and the Paris Museum Collections.

² Department of Pathology, Ontario Veterinary College, University of Guelph, Guelph, Ontario, Canada N1G 2W1.

* Hibitane—Ayerst Laboratories, Montreal.

** Vetsulid—E. R. Squibb & Sons Ltd., Montreal.

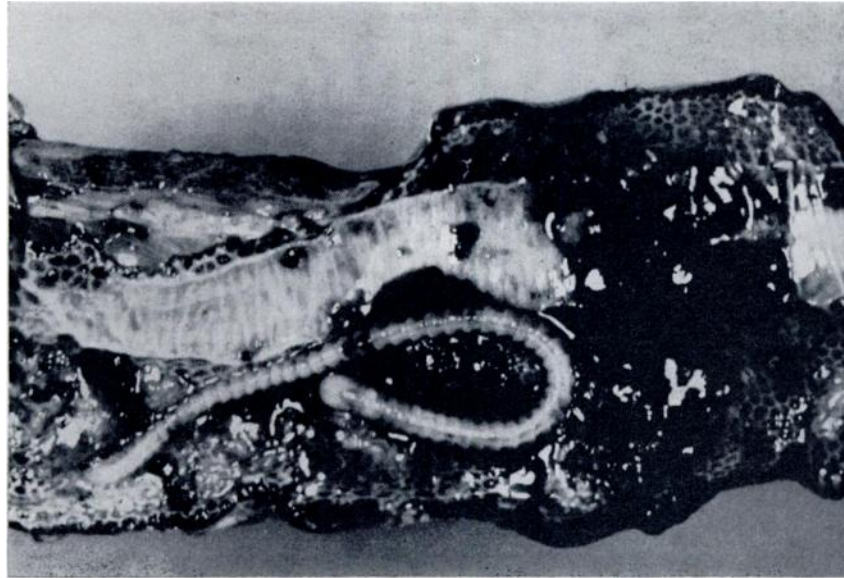


FIGURE 1. *Armillifer brumpti* in the lung of the boa (1.25X).

debris and there was blood and pigment in some areas. On the surface of some septa the epithelium was missing and mononuclear cells were present in the submucosa. Eosinophilic granulocytes were prominent in all areas. The walls of the air sac were opaque and thickened by a caseous mass adherent to the epithelial surface. The adherent mass contained degenerate epithelial cells, eosinophilic granulocytes, erythrocytes, bacteria and strands of fibrin. The liver and kidney were darker than normal. Microscopically large amounts of black pigment were present in Kupffer cells throughout the liver, but there was no evidence of bacteria, nor of an inflammatory response. Yellowish brown pigment was present in the tubular epithelial cells of the kidney but there was no evidence of nephritis. Examination of other organs revealed no significant changes. A *Pseudomonas* species was isolated from the lung.

The necrotic material in both the lung and air sac contained numerous pentastomid eggs, which were thick-shelled, oval, approximately $140 \times 130 \mu$, and contained an embryo with rudimentary

arthropod-like legs (Figures 2, 3). Twelve adult pentastomids, *Armillifer brumpti* Giglioli 1922 were found unattached in the air sac and lung. These parasites had conspicuous annular rings over the length of the body (Figure 1), were yellowish white, and 60-80 mm in length.

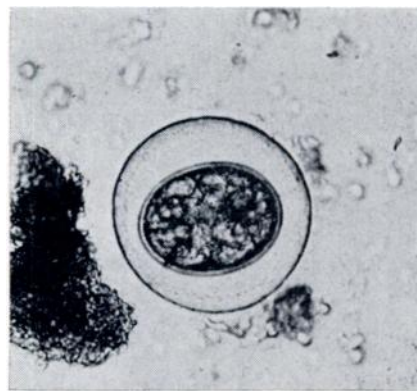


FIGURE 2. An egg, approximately $130 \times 140 \mu$, from the necrotic material of the lung.

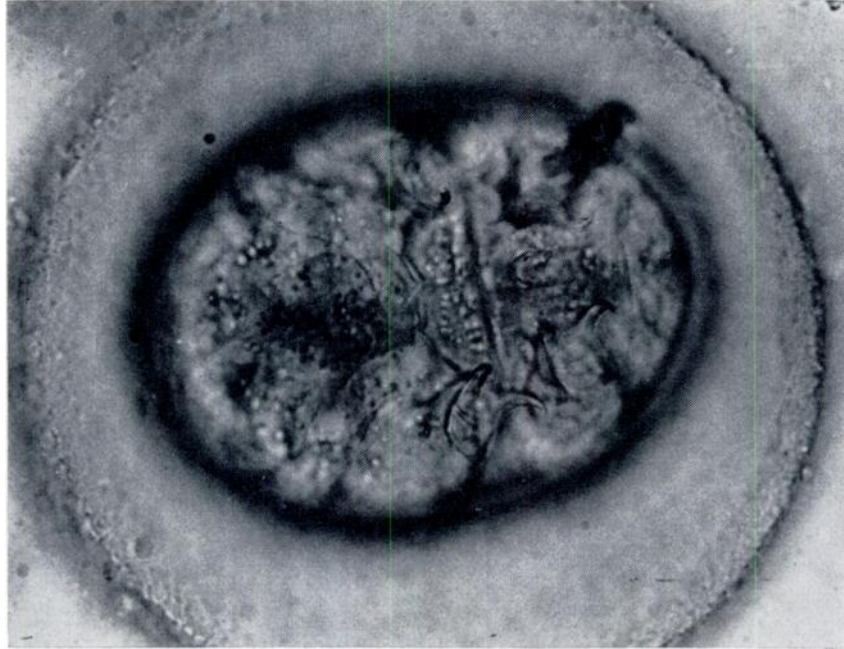


FIGURE 3. An egg, highly magnified (400 x) showing the rudimentary legs of the embryo.

DISCUSSION

Pentastomids have both arthropod and annelid characteristics and share a common ancestry with the Annelida and Arthropoda.¹¹ Adult pentastomes are worm-like and are found principally in the respiratory tract of reptiles. In snakes, the parasites are found in the lung or air sac distal to the lung, but they often escape and wander through the coelom.⁹ The eggs can be found either in the sputum or feces of snakes. When the eggs are consumed by one of several mammalian intermediate hosts, they hatch to larva which have arthropod-like features and which burrow through the gut wall to the abdominal cavity, mature to nymphs, and become encysted and attached to the viscera. Snakes become infected when they prey upon an infected intermediate host. The nymphs excyst in the intestine of the snake, and migrate by various routes to the respiratory tract.⁹ Diagnosis of an infection can be made by identifying in the feces or sputum the characteristic thick-shelled eggs contain-

ing an embryo with rudimentary legs. There is no known treatment.

Armillifer species occur principally in Asia and Africa,^{2,7,10} although *A. armillatus* was found in an imported gaboon viper (*Bitis gabonica*) in the New York Zoological Park.⁵ More commonly, pentastomids of the genera *Porocephalus* and *Kiricephalus* have been found in snakes in the Americas.^{3,6} These genera have annulated bodies, but lack the conspicuous rings of *Armillifer*.^{10,11} *Armillifer brumpti* was described first from an unknown host in Madagascar,⁴ and subsequently from *Boa madagascariensis*, and *Corallus madagascariensis*.⁹ However, the taxonomic position of this pentastomid is still debatable, since the species name of *Gigliolella brumpti* has also been proposed.¹

Little is known about the effects of pentastomids in the lungs of snakes. It is thought that the adults destroy and impair the function of the lung producing a chronic disease, can occlude the trachea,¹² and can perforate the lung pro-

ducing hemorrhage.³ *Armillifer* species in African snakes have been found tenaciously adherent to the lung tissue and difficult to remove, and found to cause considerable hypersecretion of mucus, blockage, and perforation of the lung.² In this tree boa, the pentastomids were found unattached at the time of necropsy, which was some 24 hours after death. The causes of death were probably the chronic irritation of the parasites and a bacterial infection. *Pseudomonas aeruginosa* is known to cause septicaemia and death in snakes.⁶

Since the boa was fed only laboratory reared rodents, and *Armillifer* species have not been found in native American snakes, these pentastomids quite likely were imported into Ontario with their host. The importation of exotic animals

with their peculiar parasites always presents a potential hazard for the indigenous animal populations. New parasites are often highly pathogenic to their hosts. These parasites may also be biological vectors for and carry bacteria, viruses, or other etiologic agents of exotic diseases. Under the conditions in which the boa was housed, there appeared to be little prospect that the pentastomid ova shed by the snake would reach an intermediate host rodent on the premises. However, the disposal of contaminated bedding material from the snake's box in household garbage, and thence to a landfill area which was inhabited by mice or rats, conceivably could result in the parasite finally reaching a free-living native snake, with unknown consequences to the new host.

Acknowledgements

The authors acknowledge the cooperation of Dr. J. T. Self, University of Oklahoma, in the identification of *Armillifer brumpti*. Mrs. Diane Gaherty, Toronto, who submitted the boa for post mortem examination and kindly supplied the history, and Dr. J. D. Schroder, Ontario Veterinary College, and Dr. T. Wilson, Ontario Ministry of Agriculture and Food, for assistance with the histopathology.

LITERATURE CITED

1. CHABOUD, A. G. et MARIE-THERESE CHOQUET. 1954. Nymphs du Pentastome *Giglolella* (n. gen) *brumpti*. Chey Un Lemuren. Revista di Parasitologia 25: 230-236.
2. FANTHAM, H. B. and A. PORTER. 1950. The endoparasites of certain South African snakes together with some remarks on their structure and effects of their host. Proc. Zool. Soc. Lond. 120: 599-647.
3. FANTHAM, H. B. and A. PORTER. 1953-1954. The endoparasites of some North American snakes and their effects on the Ophidia. Proc. Zool. Soc. Lond. 123: 867-898.
4. GIGLIOLI, G. 1922. *Armillifer brumpti* N. Sp., Nouvelle espece de Linguatulide de Madagascar. Bull. de la Soc. de Path. Exot. 15: 565-572.
5. HERMAN, C. M. 1938. Parasites obtained from animals in the collection of the New York Zoological Park during 1938. Zoologica. 24:481-485.
6. HEYMONS, R. U. H. and G. VITZTHUM. 1936. Bietrage Zur Systematik der Pentastomiden. Zietschr. Parasitenkunde. 8: 1-104.
7. HILL, H. R. 1934. The occurrence of linguatulids in Pythons. Bull. So. Calif. Acad. Sciences. 33: 117-122.
8. PAGE, L. A. 1966. Diseases and infections of snakes: A Review. Bull. Wild. Dis. Assoc. 2: 111-126.
9. REICHENBACH-KLINKE and E. ELKAN. 1965. *The Principal Diseases of Lower Vertebrates*. Academic Press, New York.
10. SAMBON, L. W. 1922. A synopsis of the family Linguatulidae. J. Trop. Med. Hyg. 24: 391-428.
11. SELF, T. J. 1969. Biological relationships of the Pentastomida; A bibliography on the Pentastomida. Exp. Parasitol. 24: 63-119.
12. TELFORD, S. R. 1971. Parasitic diseases of reptiles. J. Am. vet. med. Ass. 159: 1644-1652.

Received for publication 9 May 1973