



DISEASE COMPLEXITY IN A DECLINING ALASKAN MUSKOX (OVIBOS MOSCHATUS) POPULATION

Authors: Afema, Josephine A., Beckmen, Kimberlee B., Arthur, Stephen M., Huntington, Kathy Burek, and Mazet, Jonna A. K.

Source: Journal of Wildlife Diseases, 53(2) : 311-329

Published By: Wildlife Disease Association

URL: <https://doi.org/10.7589/2016-02-035>

BioOne Complete (complete.BioOne.org) is a full-text database of 200 subscribed and open-access titles in the biological, ecological, and environmental sciences published by nonprofit societies, associations, museums, institutions, and presses.

Your use of this PDF, the BioOne Complete website, and all posted and associated content indicates your acceptance of BioOne's Terms of Use, available at www.bioone.org/terms-of-use.

Usage of BioOne Complete content is strictly limited to personal, educational, and non - commercial use. Commercial inquiries or rights and permissions requests should be directed to the individual publisher as copyright holder.

BioOne sees sustainable scholarly publishing as an inherently collaborative enterprise connecting authors, nonprofit publishers, academic institutions, research libraries, and research funders in the common goal of maximizing access to critical research.

DISEASE COMPLEXITY IN A DECLINING ALASKAN MUSKOX (*OVIPOS MOSCHATUS*) POPULATION

Josephine A. Afema,¹ Kimberlee B. Beckmen,^{2,5} Stephen M. Arthur,^{2,4} Kathy Burek Huntington,³ and Jonna A. K. Mazet¹

¹ Wildlife Health Center, One Health Institute, School of Veterinary Medicine, University of California, 1089 Veterinary Medicine Drive, Davis, California 95616, USA

² Alaska Department of Fish and Game, Division of Wildlife Conservation, 1300 College Road, Fairbanks, Alaska 99701, USA

³ Alaska Veterinary Pathology Services, 23834 The Clearing Drive, Eagle River, Alaska 99577, USA

⁴ Current address: US Fish and Wildlife Service, Arctic National Wildlife Refuge, 101 12th Avenue, Room 236, Fairbanks, Alaska 99701, USA

⁵ Corresponding author (email: kimberlee.beckmen@alaska.gov)

ABSTRACT: The muskox (*Ovibos moschatus*) population inhabiting the eastern North Slope (ENS) of Alaska, US declined dramatically during 1999–2006, whereas populations in western Alaska (WA) were stable or increasing. To understand morbidity and mortality factors contributing to the decline, Alaska Department of Fish and Game conducted pathologic investigations of carcasses from 2005 until 2008. Additionally, archived sera from both ENS and WA muskoxen collected during 1984–92, before the documented beginning of the ENS decline; sera collected during 2000, near the beginning of the decline; and contemporary sera (from live capture–release, adult females) collected during 2006, 2007, and 2008 were analyzed to determine whether prevalence of antibody to potential pathogens differed in the two areas or changed over time. The pathogens investigated were those that were believed could cause lameness or poor reproduction or adversely affect general health. Furthermore, trace mineral levels, hemograms, and gastrointestinal parasites were evaluated in live adult females captured 2006–08. Pathologic investigations identified several comorbid conditions, including predation, polyarthritis caused by or consistent with *Chlamydophila* spp. infection, hoof lesions, copper deficiency, contagious ecthyma, verminous pneumonia, hepatic lipidosis suggestive of negative energy balance, and bacterial bronchopneumonia due to *Trueperella pyogenes* and *Bibersteinia trehalosi*. Pathogens suspected to be newly introduced in the ENS muskox population on the basis of serologic detection include bovine viral diarrhea, respiratory syncytial virus, *Chlamydophila* spp., *Brucella* spp., *Coxiella burnetii*, and *Leptospira* spp., whereas parainfluenza virus-3 antibody prevalence has increased in the WA population. Although multiple disease syndromes were identified that contributed to mortality and, in combination, likely limited the ENS muskox population, further holistic investigations of disease agents, trace mineral status, and nutritional factors in conjunction with intensive demographic and environmental analyses would provide a better understanding of factors that influence Alaskan muskox populations.

Key words: Alaska, *Chlamydophila*, muskoxen, pathology, polyarthritis, serology, trace minerals, wildlife disease.

INTRODUCTION

Muskoxen (*Ovibos moschatus*) were rare and restricted to certain parts of Alaska, US before they disappeared in the late 19th or early 20th century. Suggested explanations for the disappearance include adverse climatic conditions, fluctuations in food availability, competition for resources, and hunting (Lent 1999). To restore muskoxen to Alaska, 31 muskoxen were brought from Greenland to the University of Alaska, Fairbanks, and subsequently released on Nunivak Island off

the western coast of Alaska in 1935 and 1936 (Fig. 1). Descendants of these animals were translocated to different parts of Alaska, including 64 muskoxen released into the eastern North Slope (ENS) in 1969–70 and 36 muskoxen released into Seward Peninsula in 1970, followed by another 35 animals in 1977. Similarly, 36 muskoxen were released into Cape Thompson in 1970, followed by 34 muskoxen in 1977 (Gunn et al. 2013). Annual surveys in ENS indicated that the muskox population increased between 1970 and 1995, stabilized at approximately 650–800 animals

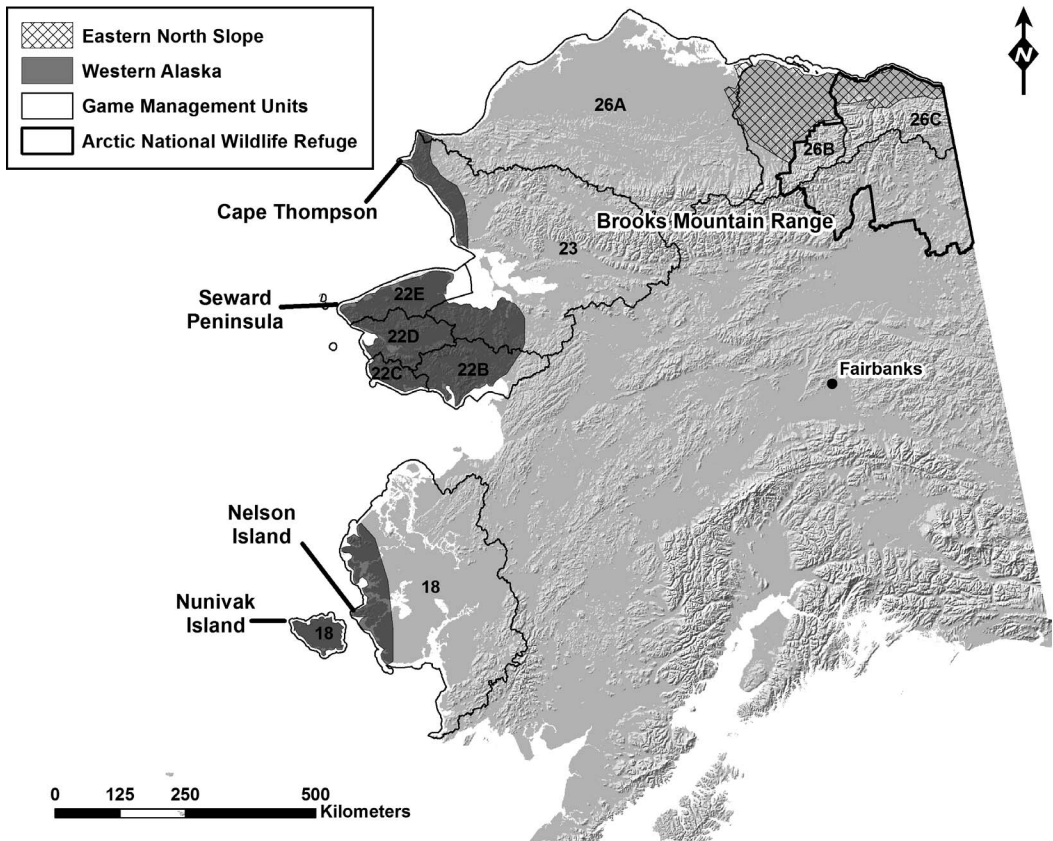


FIGURE 1. Alaska Game Management Units with muskoxen (*Ovibos moschatus*) populations (number and subunit letter designation) sampled. The eastern North Slope population range is cross-hatched, and the western Alaska, USA population range is shaded in dark gray.

during 1995–98, then declined rapidly through 2006 (Reynolds 1998a; Lenart 2011). Calf recruitment evidently declined and predation losses increased during the 1990s (Reynolds 1998a; Reynolds et al. 2002). However, to our knowledge, no observed climatic, anthropogenic, or other environmental influences provided a plausible explanation for these changes or the observed population decline. Conversely, the muskox meta-population on Seward Peninsula in western Alaska (WA) increased rapidly to 2,700 animals by 2007 (Gunn et al. 2013); this population continued to increase through at least 2009 (Gorn 2011). During this period, muskoxen on Nunivak Island were hunted to maintain a stable population, the population on Nelson Island was increasing, and the population on Cape Thompson also grew, although more

slowly than other restored populations in Alaska (Gunn et al. 2013).

Previous studies have shown that muskox population dynamics are influenced by nutritional conditions, weather, predation, and dispersal (Reynolds 1998b; Reynolds et al. 2002). Nutritional compromise of adult female muskoxen associated with low food abundance and deep snow and evidenced by low serum copper was thought to cause poor calf production and limited herd numbers (Barboza and Reynolds 2004). Disease also influences muskox populations. For example, *Yersinia pseudotuberculosis* serotype 1B accounted for at least 69% of deaths among 67 carcasses and 53 skeletal remains recovered from Banks Island, Canada, in 1986 (Blakley et al. 2000). Also, between 2004 and 2012, major disease outbreaks occurred in the

musko population on Dovre Mountain plateau, Norway. In 2004, this population experienced a severe contagious ecthyma (CE) outbreak (Vikøren et al. 2008), and in 2006, a multifactorial outbreak of pneumonia occurred during extreme weather events and caused mortality of up to 26% (Ytrehus et al. 2008, 2015). In 2012, *Mycoplasma ovipneumoniae* was the primary cause of a severe pneumonia outbreak (Handeland et al. 2014). Recently, *Erysipelothrix rhusiopathiae* was identified as a significant cause of mortality (Kutz et al. 2015) in Canadian muskoxen.

Other conditions of concern that may affect muskox populations include rangiferine brucellosis because it occurs in sympatric arctic caribou (*Rangifer tarandus granti*) herds and causes reproductive failure and joint lesions (Neiland et al. 1968), although it is rarely reported in muskoxen (Gates et al. 1984; Forbes 1991; Tomaselli et al. 2016). Additionally, *Chlamydophila* spp. (CLA) causes multiple clinical manifestations in domestic ruminants, such as pneumonia, polyarthritis, abortion, and infertility, that could affect population dynamics (Kaltenboeck et al. 2005). Furthermore, parasitic infestations or comorbidities could exacerbate existent health conditions, resulting in poor disease outcomes. For instance, gastrointestinal parasite infestations occur in arctic ungulates (Kutz et al. 2001, 2004). Notably, *Umingmakstrongylus pallikuukensis*, a lung nematode, infects muskoxen and may have contributed to a 50% decline in the population in Canada (Kutz et al. 2004), although other organisms are under consideration as causal and contributory. Similarly, *Teladorsagia boreoarcticus*, a nematode that causes severe abomasal disease, has been observed in muskoxen in Canada (Kutz et al. 2004).

In response to concerns over the ENS muskox population decline, in 2005, the Alaska Department of Fish and Game (ADFG) initiated a preliminary assessment of the occurrence and prevalence of a variety of diseases and parasites, as well as the nutritional status of muskoxen with regard to important trace minerals. This study included pathologic investigations of muskox carcasses

recovered during routine aerial population surveillance. Pathologic examinations were continued until 2008 to establish primary and contributing causes of death. Archived and contemporary sera were tested for selected pathogens, and serologic prevalences were compared during and before the period of decline in both the decreasing ENS muskox population and the increasing WA population. Additionally, hematology, fecal parasites, and trace mineral status were examined to understand factors that may affect the health and population status of Alaskan muskoxen.

MATERIALS AND METHODS

Study area

Sampling was conducted in the ENS area, which had experienced a population decline, and the WA area, where the population was stable or increasing. For the purposes of this study, ENS comprised the Arctic coastal plain north of the Brooks Range mountains in northeastern Alaska, including the Arctic National Wildlife Refuge, all of state Game Management Unit 26B, and the eastern portion of Game Management Unit 26A, and WA comprised the Seward Peninsula, Cape Thompson, Nunivak Island, and Nelson Islands in coastal western Alaska (Fig. 1).

Carcass collection and pathology

Between 2005 and 2008, 13 intact carcasses, and 23 partial remains of muskoxen were recovered by the field staff (helicopter pilot, wildlife biologists, and veterinarian) of ADFG while conducting aerial surveillance of muskoxen. The history, carcass condition, and postmortem examinations of the remains are shown in Table 1. Carcasses were recovered a few to several days after death, except for a lethargic and limping calf that was euthanized. When carcasses could not be transported intact to the laboratory, gross postmortem examinations were performed in the field, and partial remains such as available limbs and organs (thoracic pluck, liver, kidneys, etc.) were collected for further examination and sampling. Predation, scavenging, autolysis, and carcasses frozen in place limited the ability to perform complete postmortem examinations for definitive diagnoses. Formalin-fixed tissues were processed routinely for histopathologic evaluation by a veterinary pathologist. Samples to be examined by immunohistochemistry (IHC) for CLA and *Mycoplasma bovis* antigens were submitted to Iowa State University, Veterinary

TABLE 1. Factors causing or contributing to morbidity and mortality in 36 muskoxen (*Ovibos moschatus*) from the eastern North Slope (ENS) and western Alaska (WA), USA, September 2005–May 2008. — = no data; Cu = copper; ppm = parts per million.

| Animal ID | Date found | History and carcass condition | Age category ^a | Sex ^b | Location | Major postmortem findings | Factors contributing to morbidity or mortality |
|-----------|----------------|---|---------------------------|------------------|----------|---|--|
| 2005-163 | November 2005 | Found limping, lethargic; euthanized; frozen for 5 d before postmortem examination | Calf | F | ENS | Bilateral polyarthritis of carpi, hock, right humeroscapular joint synovitis, thick yellow fluid, <i>Chlamydophila</i> detected by immunohistochemistry, <i>Mycoplasma bovis</i> not detected; liver Cu: 6.27 ppm | Euthanasia following polyarthritis due to <i>Chlamydophila</i> spp., marginal liver Cu |
| 2006-093 | April 2006 | Found dead with dam and brown bear feeding | Calf | F | ENS | Bite to spine with complete separation of thoracic and lumbar spine; no significant histopathologic findings | Bear predation |
| 2006-094 | April 2006 | Found dead with neonate and brown bear feeding on carcass; only left rear leg and part of front leg presented for pathology | Adult | F | ENS | Chronic polyarthritis of left stifle and carpus characterized by papillary hyperplasia of synovium, cartilage ulceration with pannus formation, eburnation | Bear predation, polyarthritis |
| 2006-121 | June 2006 | None, left rear distal leg presented | Unk | F | ENS | Chronic hyperplastic dermatitis with marked orthokeratotic hyperkeratosis | Papillomavirus or parapoxvirus |
| 2006-122 | June 2006 | None, distal part of right front leg presented | Juvenile | Unk | ENS | Chronic hyperplastic dermatitis, orthokeratotic hyperkeratosis | Unknown |
| 2006-123 | September 2006 | Frozen complete carcass submitted for postmortem examination | Calf | F | ENS | Intussusception at midjejunum with sections of necrotic tissue and rumen has large amounts of adult guard hair; fibrin and nephron thrombi and suppurative thrombophlebitis | Intussusception |
| 2006-166 | September 2006 | Found dead and brown bear feeding on carcass | Adult | M | ENS | Hoof wall proliferation and ridge lesions (Fig. 2a, b), joint cartilage erosion, osteochondritis; liver Cu: 4.1 ppm | Predation, hoof wall lesions, Cu deficiency |
| 2007-078 | April 2007 | Found dead, refrigerated for 2 d before postmortem examination | Calf | M | ENS | Weak calf; hepatic cysts, vacuolar hepatopathy, bronchointerstitial pneumonia, lung atelectasis; most tissues have immature appearance | Weak calf, premature |

TABLE 1. Continued.

| Animal ID | Date found | History and carcass condition | Age category ^a | Sex ^b | Location | Major postmortem findings | Factors contributing to morbidity or mortality |
|-----------|----------------|--|---------------------------|------------------|----------|---|---|
| 2007-081 | May 2007 | Found dead, fox scavenging, partial carcass frozen and submitted | Juvenile | M | ENS | Fibrosuppurative bronchopneumonia, <i>Bibersteinia trehalosi</i> and <i>Trueperella pyogenes</i> cultured from lung, but culture negative for <i>M. bovis</i> ; intralesional foreign (plant) material suggestive of aspiration pneumonia; proliferative and ulcerative dermatitis with intralesional intracytoplasmic inclusion bodies, pseudoepitheliomatous hyperplasia suggestive of parapoxvirus | Acute and severe bronchopneumonia |
| 2007-082 | April 2007 | Radio-collared cow found dead, remains not examined postmortem | Adult | F | ENS | Not submitted for postmortem examination | Bear predation |
| 2007-123 | June 2007 | Found dead, refrigerated for postmortem examination | Adult | F | ENS | Mild hoof wall overgrowth and crack, arthritis, cartilage necrosis; liver Cu: 16.6 ppm; severe vacuolar hepatopathy, intramyofiber <i>Sarcocystis</i> spp. | Necrotizing, suppurative arthritis with cartilage necrosis, marginal Cu |
| 2007-084 | April 2007 | Formalin-fixed tissues presented | Calf | Unk | ENS | — | Weak calf |
| 2007-200 | September 2007 | Shot in skull by hunter | Juvenile | F | ENS | Not submitted for histopathology | Illegal gunshot by hunter |
| 2008-044 | May 2008 | Dam killed by grizzly bear | Fetus | F | ENS | Subcutaneous hemorrhage on skull, no significant lesions on other tissues | Fetal death secondary to maternal death by predation |
| 2008-045 | May 2008 | Found dead, possibly killed by bear | Adult | F | ENS | Partial remains examined grossly but autolyzed, histopathology not done | Possible bear predation |
| 2008-054 | May 2008 | Killed by bears, partial remains submitted for pathology | Adult | F | ENS | Hemorrhages to heart, pulmonary atelectasis and hemorrhage | Bear predation |
| 2008-055 | May 2008 | Killed by bears, partial remains submitted for pathology | Adult | F | ENS | Hoof overgrowth and cracks, elbow joint cartilage ulcer, verminous bronchointerstitial pneumonia | Bear predation, hoof lesions |

TABLE 1. Continued.

| Animal ID | Date found | History and carcass condition | Age category ^a | Sex ^b | Location | Major postmortem findings | Factors contributing to morbidity or mortality |
|-----------|------------|--|---------------------------|------------------|----------|--|---|
| 2008-056 | May 2008 | Killed by bears, partial remains submitted for pathology | Adult | F | ENS | Hoof overgrowth, chronic multifocal splaying and cracking | Bear predation, hoof lesions |
| 2008-092 | July 2008 | Found dead and partially scavenged leg submitted for pathology | Calf | Unk | WA | Chronic fistulous tract | Inconclusive |
| 2008-026 | April 2008 | Observed "feeble," found dead shortly thereafter | Old adult | F | ENS | Necrotizing, caseous and fibrinopurulent arthritis and tenosynovitis of carpi; degenerative myopathy, severe <i>Sarcocystis</i> in heart and skeletal muscles; hepatocellular atrophy, hoof overgrowth, worm/broken teeth; adequate liver Cu: 94.4 ppm | Advanced age, emaciation, osteoarthritis/tenosynovitis |
| 2008-028 | April 2008 | Dam killed by bears | Fetus | F | ENS | Normal fetus, no significant lesions | Fetal death secondary to maternal death by predation |
| 2008-029 | April 2008 | Pregnant female killed by bear | Adult | F | ENS | Crushing bite wound to maxilla, hepatocellular vacuolar degeneration | Bear predation |
| 2008-030 | April 2008 | Killed by bear, only section of bone was submitted | — | F | ENS | No significant lesions | Bear predation |
| 2008-033 | April 2008 | Dystocia, breech | Adult | F | WA | Verminous pneumonia, hepatocellular vacuolar degeneration | Dystocia, verminous pneumonia, hepatocellular vacuolar degeneration |
| 2008-034 | April 2008 | Breech fetus | Fetus | F | WA | Acute necrotizing and suppurative bronchopneumonia with intraleisional bacteria | Breech fetus, bronchopneumonia |
| 2008-035 | April 2008 | Killed by poacher, autolyzed, head/leg/heart submitted | Adult | M | ENS | <i>Sarcocystis</i> in heart muscles | Illegal kill |

TABLE 1. Continued.

| Animal ID | Date found | History and carcass condition | Age category ^a | Sex ^b | Location | Major postmortem findings | Factors contributing to morbidity or mortality |
|-----------|------------|--|---------------------------|------------------|----------|--|--|
| 2008-041 | May 2008 | Pregnant cow killed by bear; lung, liver, and leg submitted | Adult | F | ENS | Hepatocellular vacuolar degeneration, <i>Sarcocystis</i> in skeletal muscles | Bear predation, <i>Echinococcus</i> , hepatic lipidosis during pregnancy |
| 2008-042 | May 2008 | Fetus of 2008-041, dam killed by bear | Fetus | M | ENS | No significant findings | Fetal death secondary to maternal death by predation |
| 2008-043 | May 2008 | Found dead, abdominal viscera scavenged, weighed only 7 kg | Fetus | M | ENS | No significant findings in major organs, neuronal changes in brain | Parturient death possibly due to hypoxemia |
| 2008-044 | May 2008 | Fetus of 2008-045, dam killed by bear | Fetus | F | ENS | No significant findings in major organs, organs appear normal | Fetal death secondary to maternal death by predation |
| 2008-045 | May 2008 | Pregnant cow killed by bear, autolyzed leg, heart, liver, and lung submitted | Adult | F | ENS | Organs too autolyzed for histology, good bone marrow (87% fat) | Bear predation, toe of one hoof missing |
| 2008-046 | May 2008 | Lactating cow killed by bear; leg, heart, and lung submitted | Adult | F | ENS | Hoof overgrowth, epidermal hyperplasia with orthokeratotic hyperkeratosis | Bear predation, possible contagious ecthyma |
| 2008-047 | May 2008 | Dystocia, advanced autolysis | Fetus | F | WA | Advanced autolysis, small thymus, pale muscles | Breech fetus, died most likely due to maternal death |
| 2008-048 | May 2008 | Abandoned calf, dehydration, starvation | Calf | F | ENS | Lymphoid depletion, hepatocellular vacuolar degeneration, dehydration, starvation | Arthritis, suspect <i>Chlamydia</i> , dehydration/starvation |
| 2008-053 | May 2008 | Found moribund, died the next day, tissues autolyzed | Adult | M | ENS | Congested lungs, overgrown hooves, <i>Sarcocystis</i> sp. in skeletal muscles; liver Cu: 70.88 ppm | Fractured tooth |

^a Calf ≤ 12 mo, juvenile = 12 mo–2 yr, adult ≥ 2 yr; Unk = unknown.

^b F = female; M = male; Unk = unknown.

TABLE 2. Serologic and microbiologic assays used to test Alaskan muskox (*Ovibos moschatus*) samples and laboratories where samples were processed.^a — = not applicable.

| Pathogens | Test | Titer | Sensitivity and specificity, test details ^b | Reference ^b | Laboratory where test performed ^b |
|---|---|-------|--|-------------------------|---|
| Blue tongue virus | Agar gel immunodiffusion assay | — | Widely used, moderate sensitivity, not highly specific, semiquantitative | Afshar et al. 1987 | WSVL |
| Bovine viral diarrhea virus 1 | Serum neutralization | 128 | NVSL strain NADL (ATCC VR-534) genotype 1, cytopathic | — | WSVL |
| <i>Brucella suis</i> serovar 4 ^c | Buffered <i>Brucella</i> antigen card test | — | IDEXX Corp., Portland, Maine, USA | OIE 2016a | University of Alaska, Institute of Arctic Biology, Fairbanks, Alaska, USA |
| | Card test | — | BBL microbiology systems, Cockeysville, Maryland, USA | OIE 2016a | Environmental Health Laboratory, Anchorage, Alaska, USA |
| <i>Chlamydophila</i> spp. | Complement fixation test | 10 | Widely used, recommended by OIE, specificity 83–98.1%, sensitivity 68.8–91.4% | Sachse et al. 2009 | NVSL |
| Contagious ecthyma | Complement fixation test | 20 | — | Zarnke et al. 1983 | NVSL |
| Epizootic hemorrhagic disease | Agar gel immunodiffusion assay | — | Veterinary Diagnostic Technology Inc., Wheat Ridge, Colorado, USA | Pearson and Jochim 1979 | WSVL |
| Infectious bovine rhinotracheitis | Serum neutralization | 32 | Relevant diagnostic test, moderate sensitivity, NVSL Colorado strain | Ackermann et al. 1990 | WSVL |
| <i>Leptospira interrogans</i> | Modified agglutination test | — | All strains obtained from NVSL, starting dilution 1:100 | NVSL SOP-BI-0038 | WSVL |
| Malignant catarrhal fever | Competitive enzyme-linked immunosorbent assay | — | Simple, high sensitivity and specificity (95%), binding >3 SDs compared with negative control sera considered positive | Li et al. 2001 | Washington State University, Pullman, Washington, USA |
| <i>Neospora caninum</i> ^c | Competitive enzyme-linked immunosorbent assay | — | Inhibition of >30% considered positive, Immunlon, Thermo Scientific, Milford, Massachusetts, USA | Stieve et al. 2010 | University of Tennessee, Knoxville, Tennessee, USA |
| Parainfluenza virus type 3 | Hemagglutination inhibition | 8 | — | — | NVSL |
| | Serum neutralization | 128 | NVSL Reisinger SF-4 strain | — | WSVL |
| <i>Coxiella burnetii</i> | Complement fixation test | 100 | — | OIE 2016b | NVSL |
| Respiratory syncytial virus | Serum neutralization | 32 | NVSL strain A51908 (ATCC VR-794) | — | WSVL |

TABLE 2. Continued.

| Pathogens | Test | Titer | Sensitivity and specificity, test details ^b | Reference ^b | Laboratory where test performed ^b |
|--------------------------|-----------------------------|-------|--|------------------------|--|
| <i>Toxoplasma gondii</i> | Modified agglutination test | 100 | Formalin-fixed tachyzoites antigen, bioMérieux Laboratory Reagents, Marcy-l'Etoile, France | Patton et al. 1990 | University of Tennessee, Knoxville, Tennessee, USA |

^a Tests were conducted at diagnostic laboratories in-house utilizing National Veterinary Services Laboratory-standardized protocols and reagents unless indicated otherwise.

^b WSVL = Wyoming State Veterinary Laboratory, Laramie, Wyoming, USA; NVSL = National Veterinary Services Laboratory, Ames, Iowa, USA; OIE = Office International des Epizooties.

^c Serum samples positive on card tests were evaluated by western blot at Louisiana State University Agricultural Center, Baton Rouge, Louisiana, USA.

Diagnostic Laboratory (Ames, Iowa, USA). Swabs, tissues, fluids, and aspirates obtained from carcasses for bacterial culture and virology were sent to Washington Animal Disease Diagnostic Laboratory (WADDL; Pullman, Washington, USA) and Wyoming State Veterinary Laboratory (WSVL; Laramie, Wyoming, USA), respectively.

Live animal sampling

During 2006, 2007, and 2008, blood, serum, fecal samples, and vaginal and conjunctival swabs were collected from live capture-and-release adult female muskoxen from the affected population in ENS and, for comparison, the Seward Peninsula (WA). Capture protocols were approved by the Division of Wildlife Conservation Animal Care and Use Committee (protocols 04-011, 06-08, 08-01). Muskoxen ($n=38$) were darted from a helicopter using either carfentanil citrate (Zoopharm, Laramie, Wyoming, USA) and xylazine hydrochloride or a combination of medetomidine, ketamine hydrochloride (Zoopharm), and Telazol® (tiletamine hydrochloride and zolazepam hydrochloride, Fort Dodge Laboratories, Fort Dodge, Iowa, USA). Blood was collected by cephalic venipuncture into ethylenediaminetetraacetic acid and serum separator evacuated tubes for hematology and serology. Blood was kept cool up to 8 h until processed by centrifugation; serum was separated and stored in cryopreservation vials at -40 C until shipped for testing after the capture season (autumn and spring). Vaginal and conjunctival swabs were stored in dry sterile vials and frozen at -20 C until shipped to the diagnostic laboratories for processing. Fecal samples were collected digitally from the rectum, placed in Whirl-Pak bags (Nasco, Modesto, California, USA) and refrigerated until examination.

Serology and microbiology

Archived sera collected in 1984–92 and 2000 and contemporary sera from 2006 to 2008 were tested for antibodies to bovine viral diarrhea virus; *Brucella* spp.; CLA; *Coxiella burnetii*; epizootic hemorrhagic disease virus; infectious bovine rhinotracheitis virus; *Leptospira interrogans* serovars Canicola, Grippotyphosa, Hardjo, Ictero-haemorrhagiae, and Pomona; parainfluenza virus type 3; and respiratory syncytial virus. Archived sera had been evaluated for antibodies to bluetongue virus, CE virus, and ovine-associated malignant catarrhal fever virus. Only contemporary sera were available for screening for antibodies to *Neospora caninum* and *Toxoplasma gondii*. Sera were sent to various laboratories and processed using assays presented in Table 2. The number of serum samples evaluated for each pathogen varied depending on availability. Serum samples were grouped into four categories according to location and period of collection: ENS before the population decline (1984–92), ENS during the decline period (2000 and 2006–08), and nonaffected areas (WA) before and during the decline period. Vaginal and conjunctival swabs from adult females were tested by PCR and enzyme-linked immunosorbent assay (ELISA) for CLA at Nebraska Veterinary Diagnostic Laboratory (Lincoln, Nebraska, USA) and at WADDL.

Trace minerals

When available, liver samples from dead animals were analyzed by inductively coupled mass spectroscopy for copper, iron, manganese, molybdenum, selenium, and zinc levels. Similarly, trace mineral levels in live capture-release female muskoxen were assessed by testing blood for

selenium and serum for copper, iron, manganese, molybdenum, and zinc.

Fecal parasite examinations

Fecal samples were processed by standard flotation and Baermann techniques and examined for helminth eggs and larvae at WSVL or WADDL. Parasites were identified to genus when possible on the basis of size, color, shape, and contents of the ova.

Statistical analysis

Point estimates and confidence intervals of prevalences for each pathogen and parasite were provided for the time periods and locations. Analyses were conducted using R package Hmisc function `binconf` (Harrell 2015). Because samples were taken over protracted time periods and sometimes processed using different methods of analysis, we did not compare statistically but instead provide descriptive statistics on which to base your own conclusions. The mean, median, SD, and range of hemograms and trace minerals were computed and compared where appropriate. Population means of hemogram results were compared in StatsDirect 2.8.0 (StatsDirect Ltd., Altrincham, UK) using unpaired *t*-tests (when a two-tailed *F*-test was not significant and we could assume equal variances), or Mann-Whitney *U*-tests when variances were unequal.

RESULTS

Postmortem findings

Major pathologic findings and suspected or confirmed causes of death are presented in Table 1. Mortality was classified as probable predation when a brown bear (*Ursus arctos*) was present at the scene or there was evidence of massive antemortem hemorrhage and bite wounds consistent with bear predation. Predation contributed to 42% of deaths in the carcasses examined; however, some cases classified as predation may have been judged to be so as the result of scavenging, and not all observed predation deaths were sampled for this analysis. Preexisting conditions were identified in five carcasses classified as predation events as evidenced by hoof lesions (Fig. 2a, b), polyarthritis, bronchopneumonia, hepatocellular vacuolar degeneration, and *Sarcocystis* spp. in cardiac or skeletal muscles.

Gross and histopathologic lesions of polyarthritis without evidence of predation was the primary lesion in a female calf found abandoned in ENS and euthanatized in 2005. Carpal and tarsal joints were externally grossly distended with a thick fibrinohemorrhagic exudate. Articular cartilage erosions and thickening of the joint capsules with red, edematous, synovial membranes were evident (Fig. 3). *Chlamydophila* spp. antigen was detected by IHC of synovial cells of one of the six affected joints. This pathogen was also suspected to have caused necrotizing suppurative arthritis of the elbow joint in an adult female, but IHC of the joint cartilage and capsule for CLA was inconclusive, possibly because of a lack of suitable synovium samples. Other cases of polyarthritis were documented (Table 1), but culture of joint fluid and IHC of the articular surfaces, capsules, and synovia of affected joints were negative for CLA and *M. bovis*.

Bronchopneumonia was an important finding, was often found with other conditions, and likely contributed significantly to mortality in only one case (2007-081, Table 1) where aspiration of plant material into the lungs could have predisposed to infection with *Trueperella pyogenes* and *Pasteurella trehalosi*, causing acute severe fibrinosuppurative bronchopneumonia and consolidation of the cranioventral right lung. In addition to causing pneumonia, *T. pyogenes* caused septicemia with peritonitis, omphalitis, hepatitis, and enteritis in a calf. Notable pathologic findings in calves included maternal abandonment resulting in dehydration and starvation, premature birth, and jejunal intussusception. Noteworthy findings in pregnant females were hepatocellular vacuolar degeneration and dystocia.

Serology

We detected evidence of exposure to all pathogens of interest except for bluetongue virus, infectious bovine rhinotracheitis virus, and *T. gondii* (Table 3). Prevalence of antibodies to CLA was relatively high in WA during both periods; in contrast, prevalence

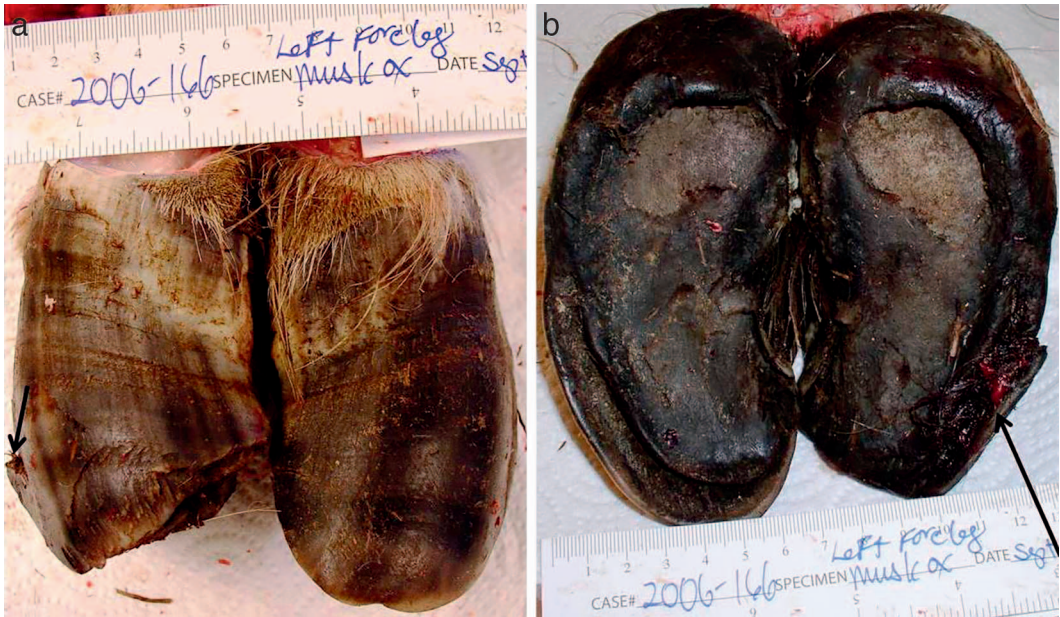

FIGURE 2. Dorsal (a) and plantar (b) views of postmortem hoof lesions in a muskox (*Ovibos moschatus*) with deficient liver copper stores. Arrows indicate severe hoof wall separation from the laminae. Ruler in centimeters.

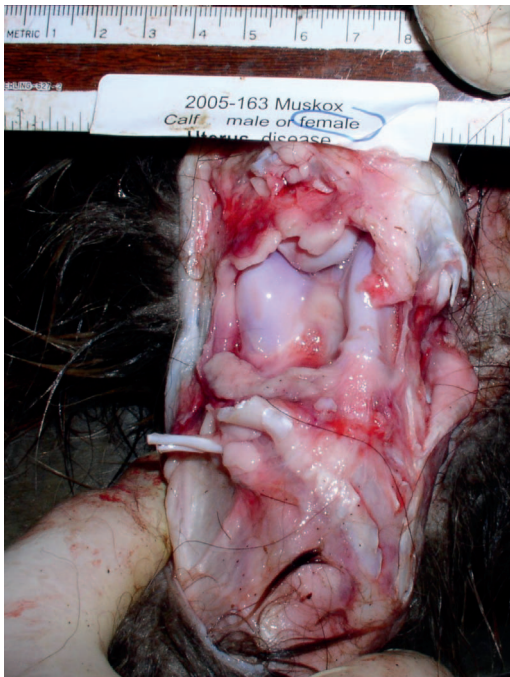

FIGURE 3. Synovitis positive for *Chlamydophila* sp. on immunohistochemistry staining, in a swollen hock joint of a copper-deficient muskox (*Ovibos moschatus*) calf that displayed lameness before euthanasia. Ruler in centimeters.

was low in ENS and was only detected during the decline period. Antibodies against *Brucella suis* serovar 4 and bovine viral diarrhea virus were detected in ENS only during the decline period, but not from WA during either period. *Coxiella burnetii* was detected at low prevalence from both areas during the decline period. Because of specimen availability and funding sources, only archived sera were tested for CE, and antibodies were detected in ENS but not from WA.

Microbiology

Both populations had evidence of CLA infection by PCR—however, at different times of the year. In ENS, CLA was detected in 7 of 11 vaginal swabs collected in March and July 2007 (during the calving season) and none of 10 swabs collected in October 2007 (noncalving season). In contrast, in WA, CLA was detected in vaginal swabs from female muskoxen captured during October 2008 (Table 4). Vaginal and conjunctival swabs were also analyzed by ELISA; however, all results were negative, even in situations for which PCR results were positive.

TABLE 3. Serologic data for selected pathogens in muskoxen (*Ovibos moschatus*) from the eastern North Slope (ENS) and western Alaska (WA), USA, during the ENS predecline period (1984–92) and ENS decline period (2000, 2006–08). — = no data; CI = confidence interval.

| Pathogen or disease | ENS (1984–92, 2000) | | ENS (2006–08) | | WA (1984–92, 2000) | | WA (2006–08) | |
|-----------------------------------|------------------------|------------------|------------------|------------------|-----------------------|------------------------------|-----------------|-----------------------------|
| | n | % (95% CI) | n | % (95% CI) | n | % (95% CI) | n | % (95% CI) |
| Blue tongue virus | 39 | 0.0 (0.0–9.0) | 0 | — | 71 | 0.0 (0.0–5.1) | 0 | — |
| Bovine viral diarrhea virus 1 | 37 | 0.0 (0.0–9.4) | 21 | 9.5 (2.7–28.9) | 71 | 0.0 (0.0–5.1) | 26 | 0.0 (0.0–12.9) |
| <i>Brucella suis</i> serovar 4 | 33 | 0.0 (0.0–10.4) | 34 | 11.8 (4.7–26.6) | 43 | 0.0 (0.0–8.2) | 25 | 0.0 (0.0–13.3) |
| <i>Chlamydomphila</i> spp. | 39 | 0.0 (0.0–9.0) | 34 | 5.9 (1.6–19.1) | 37 | 24.3 (13.4–40.1) | 26 | 10.7 (3.7–27.2) |
| Contagious ecthyma | 22 | 13.6 (4.7–33.3) | 0 | — | 43 | 0.0 (0.0–8.2) | 0 | — |
| Epizootic hemorrhagic disease | 39 | 2.6 (0.13–13.2) | 3 | 0.0 (0.0–56.1) | 71 | 0.0 (0.0–5.1) | 10 | 0.0 (0.0–27.8) |
| Infectious bovine rhinotracheitis | 41 | 0.0 (0.0–8.6) | 21 | 0.0 (0.0–15.4) | 71 | 0.0 (0.0–5.1) | 26 | 0.0 (0.0–12.9) |
| <i>Leptospira</i> (5 serovars) | 2 | 0.0 (0.0–65.8) | 18 | 5.6 (0.28–25.8) | 43 | 14.7 (1.3–15.4) ^a | 25 | 8.0 (2.2–25.0) ^b |
| Malignant catarrhal fever | 28 | 89.3 (72.8–96.3) | 6 | 100 (61.0–100) | 27 | 100 (87.5–100) | 0 | — |
| <i>Neospora caninum</i> | 14 | 7.1 (0.4–31.5) | 31 | 6.5 (1.8–20.7) | 0 | — | 25 | 0.0 (0.0–13.3) |
| Parainfluenza virus type 3 | 41 | 36.6 (23.6–51.9) | 17 | 29.4 (13.3–53.1) | 79 | 0.0 (0.0–4.6) | 25 | 80.0 (60.9–91.1) |
| <i>Coxiella burnetii</i> | 23 | 0.0 (0.0–14.3) | 17 | 5.9 (0.3–27.0) | 56 | 0.0 (0.0–6.4) | 25 | 4.0 (0.2–19.5) |
| Respiratory syncytial virus | 38 | 0.0 (0.0–9.2) | 21 | 4.8 (0.2–22.7) | 58 | 0.0 (0.0–6.2) | 26 | 0.0 (0.0–12.9) |
| <i>Toxoplasma gondii</i> | 0 | — | 13 | 0.0 (0.0–22.8) | 0 | — | 25 | 0.0 (0.0–13.3) |

^a Antibodies to *Leptospira interrogans* serovar Canicola.

^b Antibodies to *L. interrogans* serovar Icterohaemorrhagiae and *L. interrogans* serovar Pomona.

Trace minerals

Trace mineral concentrations in serum and blood from live-captured adult females and in livers of dead muskoxen are given in Tables 5 and 6, respectively. Muskox liver range (Puls 1994) and published muskox values (Salisbury et al. 1992; Puls 1994; Blakley et al. 2000;

Barboza et al. 2003) are included for comparison. Generally, copper, iron, molybdenum, and zinc levels in serum of live adult female muskoxen in both areas were similar. Blood selenium levels in ENS were low compared with WA, and manganese levels in animals from both areas were below adequate when compared with sheep (*Ovis aries*; Puls 1994).

TABLE 4. Prevalence of *Chlamydomphila* spp. in conjunctival and vaginal swabs of adult female muskoxen (*Ovibos moschatus*) captured from the eastern North Slope and western Alaska, USA, 2006–08. — = no data.

| Matrix | Test | Eastern North Slope | | Western Alaska | |
|-------------------|-----------------------------------|---------------------|--------------------------------|----------------|--------------------------------|
| | | n | % (95% Confidence interval) | n | % (95% Confidence interval) |
| Conjunctival swab | PCR | 10 | 0.0 (0.0–27.8) | 28 | 10.7 (3.7–27.2) |
| Conjunctival swab | Enzyme-linked immunosorbent assay | 9 | 0.0 (0.0–29.9) | 9 | 0.0 (0.0–29.9) |
| Vaginal swab | PCR | 21 | 33.3 (17.2–54.6) | 30 | 10.0 (3.5–25.6) |
| Vaginal swab | Enzyme-linked immunosorbent assay | 0 | — | 29 | 0 |

TABLE 5. Trace mineral levels (parts per million wet weight) in serum and blood (selenium) of adult female muskoxen (*Ovibos moschatus*) captured from the eastern North Slope and western Alaska, USA, in 2006–08. — = no data.

| Trace mineral | n | Eastern North Slope | | | Western Alaska | | | | Banks Island, Canada ^a | |
|---------------|----|---------------------|------------------------|-----------|----------------|--------|-----------|-------------|-----------------------------------|------------------------------|
| | | Median | Mean±SD | Range | n | Median | Mean±SD | Range | Males (n=10), Mean±SD | Females (n=9), Mean±SD |
| Copper | 20 | 0.96 | 0.98±0.21 | 0.69–1.74 | 15 | 0.87 | 0.91±0.16 | 0.76–1.45 | 0.79±0.01 | 0.67±0.22 |
| Iron | 20 | 1.93 | 1.98±0.47 | 1.14–2.93 | 15 | 1.92 | 1.94±0.24 | 1.58–2.33 | — | — |
| Manganese | 20 | 0.003 | 0.10±0.18 ^a | 0.00–0.61 | 15 | 0.007 | 0.04±0.10 | 0.005–0.354 | — | — |
| Molybdenum | 20 | 0.025 | 0.02±0.01 | 0.01–0.03 | 15 | 0.025 | 0.03±0.00 | 0.03–0.03 | — | — |
| Selenium | 16 | 0.245 | 0.24±0.05 | 0.15–0.34 | 16 | 0.400 | 0.39±0.09 | 0.21–0.54 | — | — |
| Zinc | 20 | 0.82 | 0.87±0.15 | 0.67–1.24 | 15 | 0.51 | 0.55±0.24 | 0.33–1.39 | 0.91±0.19 | 0.77±0.17 |

^a Barboza et al. 2003.

Although mean liver copper levels were marginal to adequate in both areas compared with Canadian muskoxen (Salisbury et al. 1992), the median liver copper was low from the ENS, and some animals were low enough to be deemed deficient. Liver molybdenum was low when compared with muskoxen from Victoria Island, Canada (Blakley et al. 2000). However, liver zinc was high compared with muskoxen from Victoria and Banks Islands (Salisbury et al. 1992; Barboza et al. 2003) and the range provided by Puls (1994). The mean and median liver selenium values were higher in WA than ENS samples, but both were higher than Canadian muskoxen.

Hemogram

Adult female muskoxen from ENS had higher total leukocyte counts ($P=0.013$, $t=2.69$, $df=24$), monocyte counts ($P=0.06$, $t=1.95$, $df=24$), and total eosinophil ($P<0.0001$, Mann-Whitney) and lower hematocrit ($P=0.013$, $t=2.68$, $df=24$) compared with those in WA (Table 7).

Fecal parasites

The prevalence of parasite stages and their likely identities based on Kutz et al. (2012) are detailed in Table 8. Infestation with more than one parasite was more common in ENS than WA. Parasites that occurred at high prevalence in ENS include *Protostrongylus* spp.,

small trichostrongylids, and *Nematodirinae*, whereas dorsal-spined larvae were detected in all feces from muskoxen in WA.

DISCUSSION

Wildlife population declines are often the result of complex combinations of interrelated mortality factors, including nutritional imbalances, disease agents, and adverse climatic and environmental conditions. Predation and human take can also be significant contributors to demographic changes. We identified several comorbidity conditions that could have contributed to mortality and limited ENS muskox population numbers.

Pathologic investigations were challenged by examination of incomplete carcasses, as well as carcasses that had undergone various degrees of autolysis, producing poor-quality samples. Nonetheless, these examinations revealed important findings. Preexisting conditions in animals apparently succumbing to predation included hoof abnormalities, polyarthritis, pneumonia, and pregnancy. When good-quality samples were available (e.g., euthanasia of the sick calf), a definitive diagnosis could be made, such as that of polyarthritis caused by CLA. Some cases of polyarthritis were suspected to have been caused by CLA or *Mycoplasma*; unfortunately, tests were inconclusive. *Chlamydophila* spp. can cause stiff gait, lameness, weakness,

TABLE 6. Trace mineral levels in liver (parts per million [ppm] wet weight) of muskoxen (*Ovibos moschatus*) found dead in the eastern North Slope and western Alaska, USA, 2005–08. All values have been adjusted to ppm for comparison. — = no data.

| Trace mineral | Eastern North Slope | | | | Western Alaska | | | |
|---------------|---------------------|--------|-----------|-----------|----------------|--------|-----------|-------------|
| | <i>n</i> | Median | Mean±SD | Range | <i>n</i> | Median | Mean±SD | Range |
| Copper | 22 | 24.7 | 38.9±33.4 | 2.2–102.2 | 3 | 41.7 | 51.6±46 | 11.7–101.5 |
| Iron | 22 | 202.6 | 354±362 | 16.7–1156 | 3 | 169 | 487.4±588 | 127–1,166.2 |
| Manganese | 22 | 2.2 | 2.4±1.3 | 0.2–1.5 | 3 | 1.7 | 1.7±1 | 0.7–2.7 |
| Molybdenum | 22 | 0.42 | 0.54±0.43 | 0.07–1.5 | 3 | 0.18 | 0.17±0.07 | 0.09–0.24 |
| Selenium | 21 | 0.4 | 0.41±0.14 | 0.15–0.84 | 3 | 0.9 | 1.2±1.2 | 0.14–2.5 |
| Zinc | 21 | 68.2 | 87.8±69.4 | 8.5–234 | 3 | 39.7 | 65.5±53.5 | 27.8–127 |

^a Puls 1994.

^b Blakley 1998.

^c Salisbury et al. 1992.

^d J. Blake and J. Rowell, pers. comm., in Salisbury et al. (1992).

abortion, retained placenta, infertility, and prenatal death in domestic ruminants (Kaltenboeck et al. 2005). This pathogen has also been implicated in polyarthritis, keratoconjunctivitis, and death in bighorn sheep (*Ovis canadensis*) in Yellowstone National Park, Wyoming, and may have predisposed individuals to predation (Meagher et al. 1992).

The high prevalence of CLA antibody in samples from WA during both periods suggests it has established host-pathogen balance in that population. On the other hand, detection of CLA from ENS only during the decline period is consistent with that of a

naïve population with recent pathogen introduction. Furthermore, the confirmation of CLA in the synovium of a polyarthritis case and detection in vaginal tissue of adult females suggests active disease and transmission in ENS. Also, detection of CLA in vaginal tissue of adult female muskoxen without demonstrable antibodies in their serum suggests antibodies are not always produced rapidly at detectable levels. It could also be that those antibody levels wane quickly—a situation similar to Alaskan caribou which, when sampled repeatedly over a 2-yr period, had transient antibody titers (K.B.B. unpubl.

TABLE 7. Hemogram for adult female muskoxen (*Ovibos moschatus*) from the eastern North Slope and western Alaska, USA, 2007–08.

| | Eastern North Slope (<i>n</i> =10) | | | Seward Peninsula, Western Alaska (<i>n</i> =16) | | |
|----------------------|-------------------------------------|---------|---------------|--|---------|-----------------|
| | Mean±SD | Median | Range | Mean±SD | Median | Range |
| Hematocrit (%) | 37.2±3.2 | 38.8 | 31.5–40.3 | 40.6±3.2 | 40.5 | 35.0–47.0 |
| Total protein (g/dL) | 7.4±0.5 | 7.4 | 6.8–8 | 6.2±0.8 | 6.0 | 5.6–9.0 |
| Total leucocytes/μL | 9,462.5±3,143.6 | 9,000 | 5,625–16,750 | 6,585.9±2,310.6 | 6,125 | 4,500–12,750 |
| Eosinophils/μL | 2,230.6±1,287.3 | 1,743.8 | 991.3–5,192.5 | 707±436.9 | 628.8 | 183.8–1,656.3 |
| Eosinophils (%) | 23.7±10.7 | 23 | 12–46 | 10.9±6 | 10.5 | 3.0–25.0 |
| Monocytes/μL | 1,212.3±636.3 | 1,187.5 | 607.5–2,847.5 | 830.5±366.1 | 735 | 428.8–1,725.0 |
| Monocytes (%) | 12.6±3.2 | 13 | 6–17 | 12.8±4.3 | 11.5 | 7.0–23.0 |
| Lymphocytes/μL | 3,055.4±1,382.9 | 2,827.5 | 1,590–5,527.5 | 2,227.2±887 | 2,040.6 | 1,286.2–4,600.0 |
| Lymphocytes (%) | 31.8±8 | 31.5 | 16–44 | 34±7.5 | 35.0 | 21.0–48.0 |
| Neutrophils/μL | 2,913.1±1,254.7 | 2,797.5 | 993.8–5,670 | 2,823.4±1,350.5 | 2,511.2 | 1,387.5–6,757.5 |
| Neutrophils (%) | 31.3±11.6 | 31 | 15–56 | 42.4±11.7 | 43.0 | 26.0–69.0 |

TABLE 6. Extended.

| Published ^a range | Victoria Island 1995 ^b | | Victoria Island 1989 ^c | | Banks Island 1985 ^d |
|---------------------------------|-----------------------------------|------------|-----------------------------------|-----------|--------------------------------|
| | Mean±SD | Range | Mean±SD | Range | Mean±SD |
| 22–114 | 16.52±1.02 | 3.81–45.1 | 66.5±23.4 | 21.4–119 | 28.9±17.8 |
| — | — | — | — | — | — |
| 2.30–4.88 | — | — | 3.21±0.52 | 2.3–4.88 | 3.8±0.5 |
| 2.6–6.0 | 1.10±0.007 | 0.51–1.84 | — | — | — |
| 0.04–0.27 | 0.082±0.005 | 0.016–0.11 | 0.1±0.07 | 0.04–0.27 | 0.26±0.02 |
| 19–58 | — | — | 28.1±6.94 | 18.8–57.9 | 35.3±8.1 |

data). The detection of low antibody titers to CLA in serum of adult female muskoxen from WA without detection of CLA in vaginal tissue from the same animals suggests these animals could have been infected but were no longer shedding CLA, or the bacteria might not have localized in the reproductive tract. Both PCR and ELISA were used to evaluate CLA in vaginal and conjunctival tissue. The ELISA failed to detect CLA in any of the samples, including those positive by PCR. The ELISA used here may have limited utility for screening muskox tissues for CLA, although neither assay has been validated for use in muskoxen.

Another condition that appeared to contribute to morbidity and mortality was verminous, bacterial, or aspiration pneumonia. Multifactorial pneumonia, including contributing pasteurellosis has caused mortality in Norwegian muskoxen during extreme weather events (Ytrehus et al. 2008), and recently, *M. ovipneumoniae* has been suggested as the primary cause of a severe pneumonia outbreak in Norwegian muskoxen (Handeland et al. 2014). In our study, culture and IHC of lung tissues with pneumonia that were negative for *M. bovis*, *T. pyogenes*, *P. trehalosi*, and lungworms (*Parelaphostrongylus odocoilei*) have also been identified as causes of pneu-

TABLE 8. Prevalence (%) of parasite stages in feces from adult female muskoxen (*Ovibos moschatus*) in eastern North Slope and western Alaska, USA, 2007–08.

| Egg or larval group ^a | Eastern North Slope (n=22) | | | Western Alaska (n=21) | | |
|--|----------------------------|------------|-------------------------|-----------------------|------------|-------------------------|
| | Positive samples | % Positive | 95% Confidence interval | Positive samples | % Positive | 95% Confidence interval |
| <i>Dictyocaulus</i> sp. ^b | 1 | 4.5 | 0.23–21.8 | 5 | 23.8 | 10.6–45.1 |
| <i>Eimeria</i> spp. | 0 | 0.0 | 0.0–14.9 | 5 | 23.8 | 10.6–45.1 |
| <i>Moniezia</i> sp. | 1 | 4.5 | 0.23–21.8 | 0 | 0.0 | 0.0–15.5 |
| <i>Nematodirinae</i> ^c | 19 | 86.4 | 66.7–95.3 | 6 | 28.6 | 13.8–49.9 |
| <i>Protostrongylus</i> spp. ^d | 20 | 90.9 | 72.2–97.5 | 0 | 0.0 | 0.0–15.5 |
| Small trichostrongylids ^e | 12 | 54.5 | 34.7–73.1 | 1 | 4.7 | 0.2–22.7 |
| Dorsal spine larvae ^f | 2 | 9.1 | 2.5–27.8 | 21 | 100.0 | 84.5–100 |

^a Parasite stage detected.

^b *Dictyocaulus eckerti* found in lungs postmortem in this study.

^c *Nematodirus* sp. and *Nematodirella* sp. adults previously identified.

^d *Protostrongylus stilesi* found in sympatric ungulates.

^e *Teladorsagia boreoarcticus* adults previously identified, *Ostertagia grueheri* and *Marshallagia* sp. in sympatric caribou.

^f *Parelaphostrongylus andersoni* infections and coinfections with *Varestrongylus eleguneniensis* sp. n., identified in sympatric ungulates.

monia-associated mortalities in Dall's sheep (*Ovis dalli dalli*) (Jenkins et al. 2007), and one lamb mortality was identified in a sheep population sympatric with ENS muskoxen (K.B.B. unpubl. data).

We record the first case of dystocia in free-ranging muskoxen. In wild ruminants, dystocias are rare and difficult to detect. The muskox fetus was in breech presentation, and the dystocia was most likely caused by malpresentation. However, concurrent findings of bacterial bronchopneumonia and low hepatic copper in the fetus (which should be at its highest at birth) and verminous pneumonia, septicemia, and low hepatic copper in the dam points toward a complex diagnosis, likely involving comorbidities. Also, finding hepatocellular vacuolar degeneration in pregnant females suggests these animals were in negative energy balance and could have had other toxicities (Cal et al. 2009).

Other indicators of complex interactions between nutritional status and diseases, leading to impaired health in this study, include hoof lesions that could be attributed to copper deficiency—a condition that can cause abnormal hoof keratinization and population declines (Flynn et al. 1977). Other trace mineral aberrations (elevated hepatic zinc and iron) could have exacerbated copper deficiency, since these minerals can be copper antagonists (Puls 1994). Average liver zinc levels in both areas were high when compared with muskoxen from Victoria Islands and Banks Island (Salisbury et al. 1992), and some individual levels were in the range considered toxic for sheep (Puls 1994). Hepatic storage of iron is reported to increase in sheep during copper deficiency, so detection of high liver iron in both areas could be further evidence of copper deficiency (Puls 1994).

The serum copper levels in adult females in both areas were above mean levels reported in copper-deficient free-ranging Alaskan muskoxen (Barboza and Reynolds 2004). Although the serum copper levels we observed in adult females may appear adequate because of homeostatic mechanisms, the liver stores may be inadequate for optimal reproduction and fetal growth. We also found evidence of

manganese and zinc deficiencies in both areas and low selenium in ENS. Manganese deficiency is associated with silent estrus, reduced reproductive performance, abortions, and weak calves. Selenium deficiency can cause reduced calf survival and reproductive performance (Flueck 1994). Copper deficiency and other trace mineral perturbations could be indicators of poor nutritional status in both ENS and WA muskox populations and could be affecting population health and reproduction.

Although Zarnke (1983) did not detect antibodies to *B. suis* serovar 4 in Alaskan muskoxen, recent exposure of ENS muskoxen to *B. suis* was an important finding of our study and that of Nymo et al. (2016). In contrast, WA muskoxen were negative despite exposure to the caribou herd with the highest *B. suis* serovar 4 antibody prevalence in Alaska and proximity to herds of infected reindeer (Dieterich et al. 1990). Rangiferine brucellosis has not been recognized as an important disease in muskoxen until recently, when a case was diagnosed concurrently with CE and lungworm in a hunter-harvested male (Tomaselli et al. 2016). In Alaskan caribou, it causes chronic infections that manifest as reproductive failure, abortions, lameness, metritis, bursitis, epididymitis, orchitis, and infertility (Neiland et al. 1968), warranting further evaluation in muskox populations.

We also report CE-like lesions in dead animals and low CE antibody prevalence in ENS muskoxen. Subsequently, we identified parapoxvirus by PCR and amplicon sequencing from interdigital or mucocutaneous lesions of one ENS and two WA muskoxen from the ENS population (M. Tryland pers. comm.), and a case was reported in Canada (Tomaselli et al. 2016). Considered a disease of domestic sheep and goats (*Capra aegagrus hircus*), CE occurred in an outbreak in muskoxen in Norway, where infected cows with udder and teat lesions refused to let calves suckle. Also, lesions on the lips and interdigits of calves might have contributed to decreased calf survival (Vikøren et al. 2008).

Blood cell counts and fecal parasite examinations are often used to evaluate the general

health status of animal populations. The ENS group had significantly higher total leukocyte, monocyte, and eosinophil counts than the WA group, strengthening concern about this population's overall health status and susceptibility to infectious diseases. Monocytosis occurs with chronic inflammation and is often caused by chronic bacterial infections, such as brucellosis and chlamydiosis (Weiss and Wardrop 2010). The eosinophilia was most likely due to high parasite prevalence and multiple parasitic infestations. High parasite loads, especially during stressful periods, could exacerbate other health conditions (Kutz et al. 2004).

Unlike muskox population declines documented elsewhere, the ENS population did not exhibit a sudden, large-scale die-off that could be attributed to adverse weather or a particular disease or nutritional limitation (e.g., Ytrehus et al. 2008; Kutz et al. 2015). Rather, considering all of the evidence collected during this study, we conclude that the ENS muskox population was adversely affected by complex nutritional and infectious disease dynamics resulting in comorbidity that also likely increased susceptibility to predation. We documented pathogens that have been newly detected in Alaskan muskoxen and are worthy of continued monitoring, especially considering the effects of global climate variability in the arctic region (Kutz et al. 2009). We most strongly recommend continued serologic surveillance and pathologic investigation of CLA, brucellosis, and CE. Furthermore, nutritional and trace mineral investigations should be expanded because of the evidence of copper deficiency and the possible relationship between poor nutrition and disease. It is likely that, for the ENS muskox population and other wildlife populations experiencing the complex stressors of our modern times, more significant health insights and well-informed management recommendations could be best realized through holistic investigations of disease agents, trace minerals status, and nutritional factors in conjunction with intensive demographic and environmental analyses.

ACKNOWLEDGMENTS

We thank biologists Patricia Reynolds, Perry Barboza, Tony Gorn, Lincoln Parrett, Richard Shideler, Jim Dau, Geoff Carroll, Elizabeth Lenart, Letty Hughes, Layne Adams, and Patrick Jones and technicians Patricia Del Vecchio, Christine Terzi, and Stephanie Crawford, University of Alaska Fairbanks and US Fish and Wildlife Service, for collecting samples and data. We are also grateful to pilots Troy Cambier, Chuck Redd, Rick Swisher, Marty Webb, Sandy Hamilton, Paul Zaczkowski, and Scotty Gibbens; toxicologists Todd O'Hara and Merl Reisbeck; and pathologists Cheryl Cross, John Blake, and Todd Cornish. Funding for this study was provided by Federal Aid in Support of Wildlife Restoration, ADFG Division of Wildlife Conservation, and the US Fish and Wildlife Service.

LITERATURE CITED

- Ackermann MS, Belak S, Bitsch V, Edwards S, Moussa A, Rockborn G, Thiry E. 1990. Round table on infectious bovine rhinotracheitis/infectious pustular vulvovaginitis virus infection diagnosis and control. *Vet Microbiol* 23:361–363.
- Afshar A, Thomas FC, Wright PF, Shapiro JL, Shettigara PT, Anderson J. 1987. Comparison of competitive and indirect enzyme-linked immunosorbent assays for detection of bluetongue virus antibodies in serum and whole blood. *J Clin Microbiol* 25:1705–1710.
- Barboza PS, Reynolds PE. 2004. Monitoring nutrition of a large grazer: Muskoxen on the Arctic Refuge. *Int Congr Ser* 1275:327–333.
- Barboza PS, Rombach EP, Blake JE, Nagy JA. 2003. Copper status of muskoxen: A comparison of wild and captive populations. *J Wildl Dis* 39:610–619.
- Blakley BR, Kutz SJ, Tedesco SC, Flood PF. 2000. Trace mineral and vitamin concentrations in the liver and serum of wild muskoxen from Victoria Island. *J Wildl Dis* 36:301–307.
- Cal L, Borteiro C, Benech A, Rodas E, Abreu MN, Cruz JC, Gonzalez-Montana JR. 2009. Histological changes of the liver and metabolic correlates in ewes with pregnancy toxemia. *Arq Bras Med Vet Zootec* 61:306–312.
- Dieterich RA, Morton JK, Raich SL. 1990. Reindeer health aide manual. *Agricultural and Forestry Experiment Station and Cooperative Extension Service, Miscellaneous Publication 90-4, CES 100H-00046*. University of Alaska, Fairbanks, Alaska, 77 pp. <http://reindeer.salrm.uaf.edu/resources/circulars/MP90-4.pdf>. Accessed November 2016.
- Flueck WT. 1994. Effect of trace elements on population dynamics: Selenium deficiency in free-ranging black-tailed deer. *Ecology* 75:807–812.
- Flynn AA, Franzmann W, Arneson PD, Oldemeyer JL. 1977. Indications of copper deficiency in a subpopulation of Alaskan moose. *J Nutr* 107:1182–1189.

- Forbes LB. 1991. Isolates of *Brucella suis* biovar 4 from animals and humans in Canada, 1982–1990. *Can Vet J* 32:686–688.
- Gates CC, Wobeser G, Forbes LB. 1984. Rangiferine brucellosis in a muskox, *Ovibos moschatus moschatus* (Zimmermann). *J Wildl Dis* 20:233–234.
- Gorn TS. 2011. Unit 22 muskoxen. In: *Muskoxen management report of survey inventory activities 1 July 2008–30 June 2010*, Harper P, editor. Alaska Department of Fish and Game, Project 16.0, Juneau, Alaska, pp. 16–47. https://www.adfg.alaska.gov/static/home/library/pdfs/wildlife/mgt_rpts/11_muskox.pdf. Accessed November 2016.
- Gunn A, Eamer J, Reynolds P, Sipko TP, Gruzdev AR. 2013. Muskoxen. In: *Arctic report card 2013*. National Oceanic and Atmospheric Administration, Washington, DC, pp 87–95. ftp://ftp.oar.noaa.gov/arctic/documents/ArcticReportCard_full_report2013.pdf. Accessed November 2016.
- Handeland K, Tengs T, Kokotovic B, Vikøren T, Ayling RD, Bergsjø B, Sigurethardottir OG, Bretten T. 2014. *Mycoplasma ovipneumoniae*—A primary cause of severe pneumonia epizootics in the Norwegian muskox (*Ovibos moschatus*) population. *PLoS One* 9:e106116.
- Harrell FE Jr. 2015. R package Hmisc version 3.17-1. Department of Biostatistics, Vanderbilt University School of Medicine, Nashville, Tennessee. <http://CRAN.R-project.org/package=Hmisc>. Accessed July 2016.
- Jenkins E, Veitch AM, Kutz S, Bollinger TK, Chirino-Trejo M, Elkin BT, West KH, Hoberg EP, Polley L. 2007. Protostrongylid parasites and pneumonia in wild thin horn sheep (*Ovis dalli*). *J Wildl Dis* 43:189–205.
- Kaltenboeck B, Hehnen HR, Vaglenov A. 2005. Bovine *Chlamydophila* spp. infection: Do we underestimate the impact on fertility? *Vet Res Commun* 29 (Suppl 1):1–15.
- Kutz SJ, Bollinger T, Branigan M, Checkley S, Davison T, Dumond M, Elkin B, Forde T, Hutchins W, Niptanatiak A, et al. 2015. *Erysipelothrix rhusiopathiae* associated with recent widespread muskox mortalities in the Canadian Arctic. *Can Vet J* 56: 560–563.
- Kutz SJ, Ducrocq J, Verocai GG, Hoar BM, Colwell DD, Beckmen KB, Polley L, Elkin BT, Hoberg EP. 2012. Parasites in ungulates of Arctic North America and Greenland: A view of contemporary diversity, ecology, and impact in a world under change. *Adv Parasitol* 79:113–136, 140–141.
- Kutz SJ, Hoberg EP, Nagy J, Polley L, Elkin B. 2004. “Emerging” parasitic infections in Arctic ungulates. *Integr Comp Biol* 44:109–118.
- Kutz SJ, Hoberg EP, Polley L. 2001. A new lungworm in muskoxen: An exploration in Arctic parasitology. *Trends Parasitol* 17:276–280.
- Kutz SJ, Jenkins EJ, Veitch AM, Ducrocq J, Polley L, Elkin B, Lair S. 2009. The Arctic as a model for anticipating, preventing, and mitigating climate change impacts on host-parasite interactions. *Vet Parasitol* 163:217–228.
- Lenart EA. 2011. Units 26B and 26C muskoxen management report. In: Harper P, editor. *Muskox management report of survey-inventory activities 1 July 2008–30 June 2010*. Alaska Department of Fish and Game, Juneau, Alaska, pp. 63–84. http://www.adfg.alaska.gov/static/home/library/pdfs/wildlife/mgt_rpts/11_muskox.pdf. Accessed November 2016
- Lent PC. 1999. *Muskoxen and their hunters: A history*. University of Oklahoma Press, Norman, Oklahoma, 324 pp.
- Li H, McGuire TC, Muller-Doblies DU, Crawford TB. 2001. Simpler, more sensitive competitive-inhibition ELISA for detection of antibody to malignant catarrhal fever viruses. *J Vet Diagn Invest* 13:361–364.
- Meagher M, Quinn WJ, Stackhouse L. 1992. Chlamydial-caused infectious keratoconjunctivitis in bighorn sheep of Yellowstone National Park. *J Wildl Dis* 28: 171–176.
- Neiland KA, King JA, Huntley BE, Skoog RO. 1968. The diseases and parasites of Alaskan wildlife populations. Some observations on brucellosis in caribou. *J Wildl Dis* 4:27–36.
- Nymo IH, Beckmen K, Godfroid J. 2016. Anti-brucella antibodies in moose (*Alces alces gigas*), muskoxen (*Ovibos moschatus*), and plains bison (*Bison bison bison*) in Alaska, USA. *J Wildl Dis* 52:96–99.
- OIE (Office International des Epizooties). 2016a. Brucellosis. Chapter 2.1.4. In: *OIE manual of diagnostic tests and vaccines for terrestrial animals*. <http://www.oie.int/international-standard-setting/terrestrial-manual/access-online/>. Accessed October 2016.
- OIE. 2016b. Q Fever. Chapter 2.1.16. In: *OIE manual of diagnostic tests and vaccines for terrestrial animals*, <http://www.oie.int/international-standard-setting/terrestrial-manual/access-online/>. Accessed October 2016.
- Patton, SP, Johnson, SS, Puckett K. 1990. Prevalence of *Toxoplasma gondii* antibodies in nine populations of dairy goats: Compared titers using modified direct agglutination and indirect hemagglutination. *J Parasitol* 76:74–77.
- Pearson JE, Jochim MM. 1979. Protocol for the immunodiffusion test for bluetongue. *Proc Ame Assoc Vet Diagn* 22:463–475.
- Puls R. 1994. *Mineral levels in animal health: Diagnostic data*, 2nd Ed. Sherpa International, Clearbrook, British Columbia, Canada, 356 pp.
- Reynolds PE. 1998a. Dynamics and range expansion of a reestablished muskox population. *J Wildl Manage* 62: 734–744.
- Reynolds PE. 1998b. *Ecology of a reestablished population of muskoxen in northeastern Alaska*. PhD Thesis, University of Alaska, Fairbanks, Alaska, 106 pp.
- Reynolds PE, Reynolds HV, Shideleer RT. 2002. Predation and multiple kills of muskoxen by grizzly bears. *Ursus* 13:79–84.

- Sachse K, Vretou E, Livingstone M, Borel N, Pospischil A, Longbottom D. 2009. Recent developments in the laboratory diagnosis of chlamydial infections. *Vet Microbiol* 135:2–21.
- Salisbury CDC, Fesser ACE, Macneil JD, Patterson JR, Adamczewski JZ, Flood PF, Gunn A. 1992. Trace metal and pesticide levels in muskoxen from Victoria Island, Northwest Territories, Canada. *Int J Environ Anal Chem* 48:209–215.
- Stieve E, Beckmen K, Kania SA, Widner A, Patton S. 2010. *Neospora caninum* and *Toxoplasma gondii* antibody prevalence in Alaska wildlife. *J Wildl Dis* 46:348–355.
- Tomaselli M, Dalton C, Duiganan PJ, Kutz S, van der Meer F, Kaffe P, Surujballi O, Turcotte C, Checkley S. 2016. Contagious ecthyma, rangiferine brucellosis, and lungworm infection in a muskox (*Ovibos moschatus*) from the Canadian Arctic, 2014. *J Wildl Dis* 52:719–724.
- Vikøren T, Lillehaug A, Akerstedt J, Bretten T, Haugum M, Tryland M. 2008. A severe outbreak of contagious ecthyma (orf) in a free-ranging muskox (*Ovibos moschatus*) population in Norway. *Vet Microbiol* 127:10–20.
- Weiss DJ, Wardrop KJ. 2010. *Schalm's veterinary hematology*, 6th Ed. Wiley-Blackwell Limited, Oxford, England, 1232 pp.
- Ytrehus B, Bretten T, Bergsjø B, Isaksen K. 2008. Fatal pneumonia epizootic in muskox (*Ovibos moschatus*) in a period of extraordinary weather conditions. *Ecohealth* 5:213–223.
- Ytrehus B, Davidson RK, Isaksen K. 2015. Single causative factor for severe pneumonia epizootics in muskoxen. *Ecohealth* 12:395–307.
- Zarnke RL. 1983. Serologic survey for selected microbial pathogens in Alaskan wildlife. *J Wildl Dis* 19:324–329.

Submitted for publication 8 February 2016.

Accepted 16 November 2016.