



**Mortality of Western Gulls (*Larus occidentalis*)
Associated with Botulism Type A in Coastal Southern
California, USA**

Authors: Rogers, Krysta H., Viera, Omar Gonzales, Uzal, Francisco A., Peronne, Lisa, and Mete, Asli

Source: Journal of Wildlife Diseases, 57(3) : 657-661

Published By: Wildlife Disease Association

URL: <https://doi.org/10.7589/JWD-D-20-00153>

BioOne Complete (complete.BioOne.org) is a full-text database of 200 subscribed and open-access titles in the biological, ecological, and environmental sciences published by nonprofit societies, associations, museums, institutions, and presses.

Your use of this PDF, the BioOne Complete website, and all posted and associated content indicates your acceptance of BioOne's Terms of Use, available at www.bioone.org/terms-of-use.

Usage of BioOne Complete content is strictly limited to personal, educational, and non - commercial use. Commercial inquiries or rights and permissions requests should be directed to the individual publisher as copyright holder.

BioOne sees sustainable scholarly publishing as an inherently collaborative enterprise connecting authors, nonprofit publishers, academic institutions, research libraries, and research funders in the common goal of maximizing access to critical research.

Mortality of Western Gulls (*Larus occidentalis*) Associated with Botulism Type A in Coastal Southern California, USA

Krysta H. Rogers,^{1,5} Omar Gonzales Viera,² Francisco A. Uzal,³ Lisa Peronne,⁴ and Aslı Mete² ¹Wildlife Investigations Laboratory, California Department of Fish and Wildlife, 1701 Nimbus Road, Suite D, Rancho Cordova, California 95670, USA; ²California Animal Health and Food Safety Laboratory System, University of California, Davis, 620 W Health Sciences Drive, Davis, California 95616, USA; ³California Animal Health and Food Safety Laboratory System, University of California, Davis, 105 W Central Avenue, San Bernardino, California 92408, USA; ⁴Wetlands and Wildlife Care Center, 21900 Pacific Coast Highway, Huntington Beach, California 92646, USA; ⁵Corresponding author (email: Krysta.Rogers@wildlife.ca.gov)

ABSTRACT: A mortality event involving at least 14 Western Gulls (*Larus occidentalis*) was observed on 10 October 2019 on Huntington State Beach, Orange County, California, US. Clinical signs of affected gulls included generalized weakness and difficulty standing and flying. Six additional Western Gulls with similar clinical signs were admitted for rehabilitation between 24 October and 7 November, including birds from Newport Beach and Laguna Beach, south of Huntington Beach. Eleven carcasses were submitted for postmortem examination, including nine gulls collected on 10 October from Huntington Beach, one collected on 24 October from Laguna Beach, and one collected on 6 November from Newport Beach. Six of seven gulls tested were positive for *Clostridium botulinum* toxin type A by mouse bioassay, including five collected on 10 October from Huntington Beach and one from Laguna Beach, approximately 23 km south, on 24 October, suggesting the toxin was available to scavenging birds for nearly 2 wk following the original exposure. Botulism type C, and less commonly type E, are most frequently documented in wild birds, including waterfowl and fish-eating birds, respectively. In contrast, botulism type A is the most common cause of foodborne botulism in humans, acquired from food contaminated with *C. botulinum* spores, but it has not previously been associated with mortality in free-ranging wild birds.

Key words: Botulism type A, *Clostridium botulinum*, *Larus occidentalis*, mortality event, Western Gull.

On 10 October 2019, staff from Wetlands and Wildlife Care Center (Huntington Beach, California, USA) were notified of several sick and dead gulls on Huntington State Beach, Orange County, California. On-site staff observed 14 Western Gulls (*Larus occidentalis*; hereafter, gulls) along the wrack line on a roughly 1-km stretch of beach south of the

Huntington Beach Pier (Fig. 1). Eight gulls were dead, four were moribund, and two appeared to be affected but evaded capture. Moribund gulls were unresponsive, with apparent paralysis of the wings, legs, neck, or a combination of these. Six additional gulls, found up to 23 km to the south, were admitted into rehabilitation with similar clinical signs between 24 October 2019 and 7 November 2019 (Fig. 1). Affected birds received supportive care including heat, intravenous fluids, and corticosteroids.

Eleven carcasses (A–K) were submitted to the California Department of Fish and Wildlife (CDFW) Wildlife Investigations Laboratory (WIL; Rancho Cordova, California, USA) for mortality investigation (Fig. 1). Nine gulls (A–I) were collected on 10 October from Huntington Beach, California, one was collected on 24 October from Laguna Beach, California (J), and one was collected on 6 November from Newport Beach, California (K). Gulls were aged as juveniles (2), subadults (5), and adults (4) based on plumage (Pierotti and Annett 1995). Ten were male, and one was female. Mean body mass was $1,002.5 \pm 26.6$ g (mean \pm SE) for the males (range 880–1,120 g; $n=8$) and 570 g for the one juvenile female; weight was not recorded for birds A and B.

Two carcasses (A–B) were submitted chilled to the California Animal Health and Food Safety Laboratory System (Davis, California, USA) for postmortem examination and diagnostic workup. Both birds were in fair postmortem condition and had adequate adipose reserves and well-developed muscles. Scant to moderate amounts of ground fish

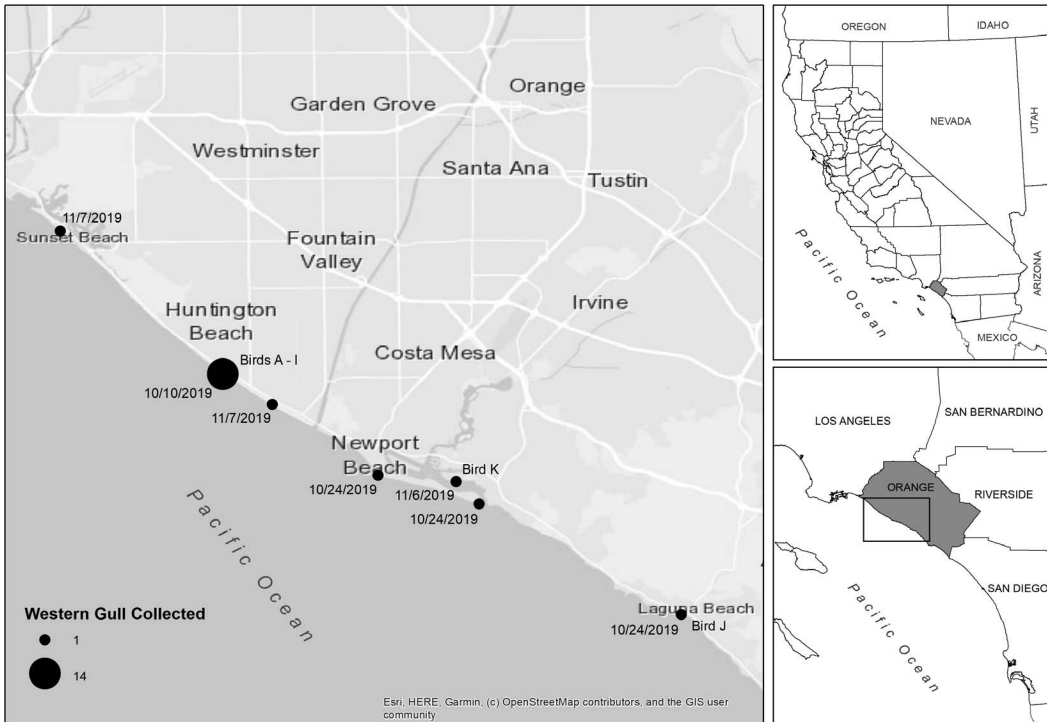


FIGURE 1. Locations and dates at which Western Gulls (*Larus occidentalis*) were collected during a botulism type A mortality event along the coast of Orange County, California, USA, October to November 2019. The Western Gulls received by California Animal Health and Food Safety Laboratory System for postmortem examination are designated birds A–K.

bones were in the ventriculus. Histopathology identified focal lymphocytes in the heart and liver, and moderate pneumoconiosis. Avian paramyxovirus-1, influenza A, and West Nile virus were not detected by PCR, and aerobic bacteria were not detected by culture. Brain cholinesterase was within acceptable limits (Hill 1988): 27 ppm (A) and 28 ppm (B). Liver tissue was tested for *Clostridium botulinum* toxin types C and A by mouse bioassay per the Centers for Disease Control and Prevention (CDC) guidelines (1998). Briefly, mice were inoculated with either liver extract and antitoxin C, liver extract and antitoxin A, or liver extract only (control). Mice inoculated with antitoxin C and the control died, while mice inoculated with antitoxin A survived, confirming the presence of botulinum toxin type A and ruling out all other toxin types including C and E.

Gross necropsy was performed on the remaining nine carcasses (C–K) at the WIL.

Prior to necropsy, the previously frozen carcasses were thawed at 4 C for 72 hr. Birds were in fair postmortem condition. Findings were similar for birds C–J, all male, including adequate adipose reserves and well-developed muscles, and scant to moderate amounts of ground fish bones in the ventriculus. Bird K was a juvenile female with no adipose reserves, atrophied muscles, and an extensive fungal infection throughout the lungs and air sacs. Liver tissue from birds C–E and J–K was submitted to California Animal Health and Food Safety Laboratory System for botulism testing; *C. botulinum* type A was confirmed in all birds except K by mouse bioassay as described for birds A–B.

Botulism is caused by a neurotoxin produced by *C. botulinum*, a sporulated Gram-positive anaerobic bacterium that is widespread in the environment. The spores persist for long periods in soil, wetland sediments, and animal tissues (Rocke and Bollinger

2007). Under appropriate conditions, spores may germinate, producing the botulinum toxin as a by-product. Eight different types of toxins have been identified, named A through H (Le Maréchal et al. 2016). Types C and E are most frequently involved in botulism cases in wild birds (Rocke and Bollinger 2007), while type A is the most common cause of foodborne botulism in humans (Fleck-Derderian et al. 2018). In the mortality event that we investigated, toxin type A was identified in six of the seven gulls tested (A–E, J), with as many as 20 involved in the mortality event; botulism type A has not previously been reported to cause death in free-ranging wild birds.

Botulism type C is most frequently reported in outbreaks involving wild waterbirds (Rocke and Bollinger 2007). Outbreaks have been reported worldwide and are often precipitated by warm to hot temperatures; abundant organic matter in the water providing substrate and anaerobic conditions for bacterial growth; and a susceptible population of birds that inadvertently ingests the toxin when feeding (Rocke and Bollinger 2007). Botulism type C outbreaks also have been identified in Herring Gulls (*Larus argentatus*) using landfills in Europe (Neimanis et al. 2007) and in domestic chickens and pheasants raised in captivity (Vadlamudi et al. 1959; Sato et al. 2016). Botulism type E is periodically reported in fish-eating birds such as pelicans, loons, and gulls in the Great Lakes, US, which acquire the toxin from affected fish (Brand et al. 1983).

In contrast, botulism type A is almost exclusively reported in humans after consuming contaminated food (Fleck-Derderian et al. 2018). Type A botulinum toxin was identified in 51% (44/86) of laboratory-confirmed outbreaks of foodborne botulism in humans evaluated 1920–2014 (Fleck-Derderian et al. 2018). These cases frequently involved improperly home-canned vegetables, fish, or meat, or improper food storage following preparation. The spores of *C. botulinum* type A are extremely heat-resistant, requiring temperatures above 100 C to be inactivated (CDC 1998). When food is improperly

prepared or stored, the spores can germinate, resulting in toxin production. Only rarely has type A botulism been diagnosed in animals, including backyard chickens eating from a compost pile (diagnosed by one of the authors, A.M.) and horses fed grass clippings (Ostrowski et al. 2012).

The source of the type A botulinum toxin for these gulls is unknown. The population size and range of Western Gulls are much smaller than those of other gull species, occurring only along the Pacific Coast from British Columbia, Canada, south to Baja California, Mexico (Pierotti and Annett 1995). Western Gulls are generalist predators, taking a variety of food items in marine and intertidal habitats as well as opportunistically scavenging human garbage (Cassell 2016). The digestive tract contents observed in the affected gulls did not point to an identifiable food item: a common finding in botulism cases. Botulinum toxin is absorbed through the small intestine; clinical signs can take between 4 and 36 hr to develop, and both the rate at which clinical signs develop and their severity are dependent upon the amount and type of toxin ingested (Rocke and Bollinger 2007). It is probable that the gulls were exposed the previous day or in the early morning, were roosting on the beach when the toxin took effect, and were deposited at the wrack line during high tide.

Various items are possible sources of the botulinum toxin, including human-food waste or discarded fishing bait left on the beach, in a trashcan, or on the fishing pier (Pierotti and Annett 1995). Additionally, Western Gulls have been observed at inland landfills, generally within 40 km of the coast (Cassell 2016). Three open-pit landfills are present in Orange County, located approximately 30–40 km inland from Huntington State Beach where the gulls were recovered. However, only toxin types B, C, and D are regularly detected at landfills (Ortiz and Smith 1994). Interestingly, male gulls more readily consume human-food waste, probably due to their larger body size and higher energy demands (Pierotti and Annett 1995). Ten of the 11 gulls received for examination were male, and botulinum

toxin type A was detected in all six males tested. The one juvenile female tested negative for botulism and was in poor nutritional condition with a fungal respiratory infection; her death was probably unrelated to the botulism event.

Botulinum toxins act by blocking nerve function in the peripheral nervous system, resulting in progressive weakness, flaccid paralysis of the skeletal muscles, and loss of respiratory function (CDC 1998; Rocke and Bollinger 2007). Clinical signs observed in these gulls were consistent with botulism (Neimanis et al. 2007). Of the 18 gulls admitted into rehabilitation between 10 October and 7 November 2019, only five recovered.

Fourteen Western Gulls were initially observed on Huntington State Beach on 10 October 2019, including birds A–E, which tested positive for type A botulinum toxin. Three gulls were admitted into rehabilitation with similar clinical signs on 24 October, including two from Newport Beach approximately 12 km south, and one, bird J, in which botulism was confirmed, from Laguna Beach roughly 23 km south. Another three gulls were admitted on 6–7 November 2019, two from Huntington Beach that tested positive for botulism and one, bird K, which tested negative for botulism, from Newport Beach. As such, the source of the toxin may have been present for at least 2 wk following the initial exposure, possibly exposing more scavenging birds than were detected. Birds with botulinum toxicity may be more susceptible to other types of mortality, including trauma and drowning, possibly resulting in undercounting of the total number of birds involved in the exposure event.

Confirming botulism in wild birds can be challenging. The mouse bioassay, the gold standard for botulism testing, requires inoculating blood or tissue from the affected bird into laboratory mice (Lindstrom and Korkeala 2006). The affected mice are then treated with antitoxin to identify the toxin type. In botulism outbreaks in waterfowl, a presumptive diagnosis is often made based on site conditions and clinical signs, as some birds may die from

a relatively small amount of toxin, resulting in a negative test (Rocke and Bollinger 2007). The mortality event that we investigated highlights the need to confirm botulism exposure and the toxin type. This mortality event involved an estimated 20 Western Gulls and was thus more easily detected. Incidents that involve relatively few individuals or that occur over a prolonged period are likely to go undetected.

We thank L. Nguyen with California State Parks and T. Giudici and T. Chen with CDFW for assisting with the mortality investigation. This work was funded by CDFW. The authors declare no conflict of interest.

LITERATURE CITED

- Brand CJ, Duncan RM, Garrow SP, Olson D, Schumann LE. 1983. Waterbird mortality from botulism type E in Lake Michigan: An update. *Wilson Bull* 95:269–275.
- Cassell AL. 2016. *Intercolony comparison of diets of Western Gulls in Central California*. Master's Thesis, San Jose State University. <https://doi.org/10.31979/etd.x89d-fj2b>. https://scholarworks.sjsu.edu/etd_theses/4681. Accessed June 2020.
- CDC (Centers for Disease Control and Prevention). 1998. Botulism in the United States, 1899–1996. In: *Handbook for epidemiologists, clinicians, and laboratory workers*. CDC, Atlanta, Georgia. <https://www.cdc.gov/botulism/pdf/bot-manual.pdf>. Accessed January 2021.
- Fleck-Derderian S, Shankar M, Rao AK, Chatham-Stephens K, Adjei S, Sobel J, Meltzer MI, Meaney-Delman D, Pillai SK. 2018. The epidemiology of foodborne botulism outbreaks: A systematic review. *Clin Infect Dis* 66 (Suppl 1):S73–S81.
- Hill EF. 1988. Brain cholinesterase activity of apparently normal wild birds. *J Wildl Dis* 24:51–61.
- Le Maréchal C, Woudstra C, Fach P. 2016. Botulism. In: *Clostridial diseases of animals*, Uzal, FA, Songer, JG, Prescott JF, Popoff MR, editors. Wiley Blackwell, Ames, Iowa, pp. 303–330.
- Lindstrom M, Korkeala H. 2006. Laboratory diagnostics of botulism. *Clin Microbiol Rev* 16:298–314.
- Neimanis A, Gavier-Widén F, Leighton F, Bollinger T, Rock T, Mörner T. 2007. An outbreak of type C botulism in Herring Gulls (*Larus argentatus*) in southeastern Sweden. *J Wildl Dis* 43:327–336.
- Ortiz NE, Smith GR. 1994. Landfill sites, botulism and gulls. *Epidemiol Infect* 112:385–391.
- Ostrowski SR, Kubiski SV, Palmero J, Reilly CM, Higgins JK, Cook-Cronin S, Tawde SN, Crossley BM, Yant P, Cazarez R, et al. 2012. An outbreak of equine botulism type A associated with feeding grass clippings. *J Vet Diagn Invest* 24:601–603.

- Pierotti RJ, Annett CA. 1995. Western Gull (*Larus occidentalis*) version 1.0. In: *Birds of the world*, Poole AF, Gill FB, editors. Cornell Laboratory of Ornithology, Ithaca, New York. <https://doi.org/10.2173/bow.wesgul.01>. Accessed June 2020.
- Rocke TE, Bollinger TK. 2007. Avian botulism. In: *Infectious diseases of wild birds*, Thomas NJ, Hunter DB, Atkinson CT, editors. Blackwell Publishing, Ames, Iowa, pp. 377–416.
- Sato Y, Wigle WL, Gallagher S, Johnson AL, Sweeney RW, Wakenell PS. 2016. Outbreak of type C botulism in commercial layer chickens. *Avian Dis* 60:90–94.
- Vadlamudi S, Lee VH, Hanson RP. 1959. Case report: Botulism type C outbreak on a pheasant game farm. *Avian Dis* 3:344–350.

Submitted for publication 21 August 2020.

Accepted 3 December 2020.