



## **Orbital actinomycotic mycetoma caused by *Streptomyces cinnamoneus***

Authors: Walton, Stuart, Martin, Patricia, Tolson, Carla, Plumridge, Susannah, and Barrs, Vanessa R

Source: Journal of Feline Medicine and Surgery Open Reports, 1(1)

Published By: SAGE Publishing

URL: <https://doi.org/10.1177/2055116915589836>

---

BioOne Complete ([complete.BioOne.org](http://complete.BioOne.org)) is a full-text database of 200 subscribed and open-access titles in the biological, ecological, and environmental sciences published by nonprofit societies, associations, museums, institutions, and presses.

Your use of this PDF, the BioOne Complete website, and all posted and associated content indicates your acceptance of BioOne's Terms of Use, available at [www.bioone.org/terms-of-use](http://www.bioone.org/terms-of-use).

Usage of BioOne Complete content is strictly limited to personal, educational, and non - commercial use. Commercial inquiries or rights and permissions requests should be directed to the individual publisher as copyright holder.

---

BioOne sees sustainable scholarly publishing as an inherently collaborative enterprise connecting authors, nonprofit publishers, academic institutions, research libraries, and research funders in the common goal of maximizing access to critical research.



# Orbital actinomycotic mycetoma caused by *Streptomyces cinnamoneus*

Stuart Walton<sup>1</sup>, Patricia Martin<sup>2</sup>, Carla Tolson<sup>3</sup>,  
Susannah Plumridge<sup>4</sup> and Vanessa R Barrs<sup>5</sup>

Journal of Feline Medicine and Surgery  
Open Reports  
1–5

© The Author(s) 2015  
Reprints and permissions:  
sagepub.co.uk/journalsPermissions.nav  
DOI: 10.1177/2055116915589836  
jfmsopenreports.com



## Abstract

**Case summary** An 18-month-old male neutered Ragdoll cat presented with an 8 week history of progressive unilateral right-sided mucopurulent nasal discharge and exophthalmos. Magnetic resonance imaging revealed a heterogeneous right retrobulbar mass and bilateral nasal cavity disease. Filamentous structures seen on cytology of retrobulbar and nasal biopsies were mistakenly identified as filamentous fungal hyphae. Subsequent investigations revealed that the cat had a retrobulbar actinomycotic mycetoma with invasion of the globe. The aetiological agent was identified on 16S recombinant DNA sequencing as *Streptomyces cinnamoneus*. After exenteration and chronic antimicrobial therapy the cat was alive and well 3 years after presentation.

**Relevance and novel information** This is the first report of a pathogenic role of *S cinnamoneus* in a cat. Orbital actinomycotic mycetomas in cats can resemble mycotic granulomas.

**Accepted:** 14 November 2014

## Case summary

An 18-month-old male neutered Ragdoll was referred to Veterinary Specialist Services, Underwood, Queensland, Australia, with an 8 week history of progressive unilateral right-sided mucopurulent nasal discharge and exophthalmos (right eye; OD). Previous treatment by the referring veterinarian included serial antimicrobial therapy and non-steroidal anti-inflammatories: clindamycin hydrochloride (Clinacin 15 mg q24h PO for 4 weeks; Intervet/Schering-Plough), enrofloxacin (Baytril 10 mg/kg q24h PO for 4 weeks; Bayer), amoxicillin-clavulanic acid (Amoxiclav 11 mg/kg q12h PO for 1 week; Apex) and meloxicam (Metacam 0.2 mg/kg SC; Boehringer-Ingelheim) followed by carprofen (Carprofen 2 mg/kg q24h PO; Apex) for 2 weeks. On physical examination at referral the cat had unilateral exophthalmos (OD) with prolapse of the nictitating membrane, conjunctival hyperaemia and periorbital soft-tissue swelling (Figure 1). The cat also had right-sided mucopurulent nasal discharge and an enlarged right submandibular lymph node. Airflow through both nares was assessed as being present on the basis of a positive slide condensation test. Vital signs, menace and pupillary light reflexes were normal. Mild discomfort was elicited on opening the mouth and on palpation of the globe (OD), which was resistant to retropulsion. A soft tissue

swelling was observed in the oral cavity in the right pterygopalatine fossa at the junction of the soft and hard palate and medial to M1 (Figure 1).

Abnormalities on haematology and serum biochemistry included a mild peripheral eosinophilia ( $1.2 \times 10^9/l$  [reference interval (RI)  $<1.1 \times 10^9/l$ ]), hyperglobulinaemia (56 g/l [RI 31–52 g/l]) and mild pre-renal azotaemia (urine specific gravity 1.043, creatinine 0.21 mmol/l [RI 0.08–0.20 mmol/l], total protein 89 g/l [RI 60–84 g/l]). Urinalysis was unremarkable. Serological testing for feline leukaemia virus (FeLV) antigen, feline immunodeficiency virus (FIV) antibody (IDEXX, SNAP FIV/FeLV

<sup>1</sup>Veterinary Specialist Services, The Springwood Centre, Underwood, QLD, Australia

<sup>2</sup>Faculty of Veterinary Science, University of Sydney, NSW, Australia

<sup>3</sup>Queensland Mycobacterium Reference Laboratory, Royal Brisbane and Women's Hospital, Herston, QLD, Australia

<sup>4</sup>Agnes Coast Vet Clinic, Agnes Water, QLD, Australia

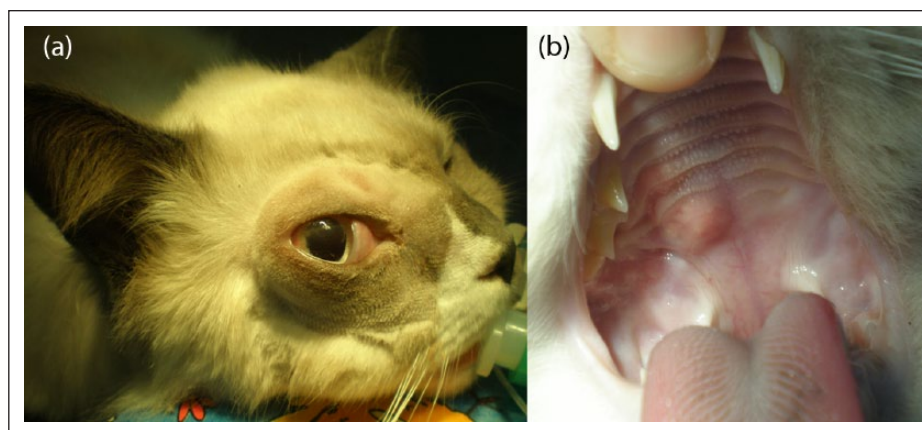
<sup>5</sup>Valentine Charlton Cat Centre, Faculty of Veterinary Science, University of Sydney, NSW, Australia

### Corresponding author:

Vanessa R Barrs BVSc(hons), MVetClinStud, FANCVSc (Feline Medicine), GradCertEd, Valentine Charlton Cat Centre, Faculty of Veterinary Science, University of Sydney, NSW, 2006 Australia  
Email: vanessa.barrs@sydney.edu.au



Creative Commons CC-BY-NC: This article is distributed under the terms of the Creative Commons Attribution-NonCommercial 3.0 License (<http://www.creativecommons.org/licenses/by-nc/3.0/>) which permits non-commercial use, reproduction and distribution of the work without further permission provided the original work is attributed as specified on the SAGE and Open Access page (<http://www.uk.sagepub.com/aboutus/openaccess.htm>).



**Figure 1** (a) Marked periorbital swelling, exophthalmos and prolapse of the nictitating membrane (OD), and (b) oral cavity swelling in the right pterygopalatine fossa at the junction of the soft and hard palate

Combo Test) and *Cryptococcus* antigen (latex cryptococcal antigen titre; Meridian Biosciences) was negative.

The cat was anaesthetised and underwent magnetic resonance imaging (MRI) of the head (0.25 T Esaote Vet; MR grande), including T1- and T2-weighted series (transverse and sagittal), as well as a T1-weighted series (transverse, sagittal and coronal), after administration of dimeglumine gadopententate (Magnevist 0.1 mmol/kg IV; Bayer). MRI findings included mild distortion to the contour of the right side of the face and a large, poorly defined heterogeneous, retrobulbar mass (37 mm × 19 mm × 20 mm) with irregular margins extending caudally to the medial aspect of the right ramus of the mandible. The mass was mildly hyperintense on the T2 sequence. A similar heterogeneous poorly defined mass was present in the left mid-caudal nasal cavity that extended caudally to involve the right nasal cavity. There was no evidence of involvement of the nasopharynx or neurocranium.

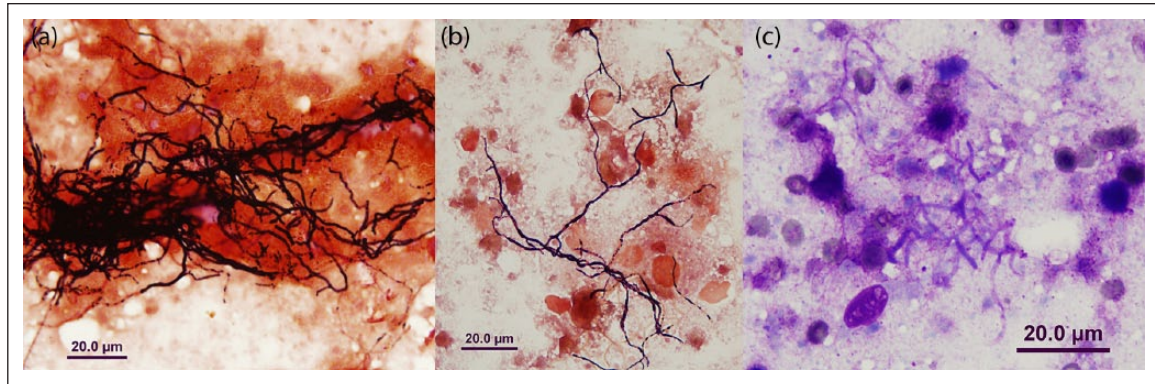
The nasopharynx was packed with sterile gauze swabs, and 3.5 Fr open-ended catheters were inserted into each ventral nasal meatus. The right and left nares were then flushed with 25 ml sterile saline while the cat was in ventral recumbancy. The swabs were then removed and samples of mucous and necrotic tissue were harvested. The soft tissue swelling adjacent to M1 was curetted and tissue biopsies were collected. Samples were submitted for cytology, histopathology and culture.

The cat was discharged from hospital pending pathology results. As the cat resided several hundred kilometres away from the referral centre, all further treatments were carried out by the referring veterinarian. Based on the cytology report from a commercial laboratory, a presumptive diagnosis of marked pleocellular inflammation with fungal infection was made. Uniform clumps of superficial epithelial and ciliated columnar epithelial

cells were associated with high numbers of inflammatory cells, degenerate neutrophils, eosinophils, macrophages and lymphocytes. Clumps of inflammatory cells were associated with mats of thin pigmented septate and branching filamentous structures, interpreted as fungal hyphae. While awaiting fungal culture results, treatment commenced with itraconazole (Sporanox 10 mg/kg q24h PO; Janssen-Cilag) and amphotericin B deoxycholate (AMB; Fungizone Bristol-Myers Squibb) by subcutaneous infusion three times a week (0.5 mg/kg in 350 ml of 0.45% NaCl with 2.5%). On histopathology, neutrophilic inflammation with inflammatory granulation tissue was identified. No fungal elements were identified with a periodic acid-Schiff stain and fungal culture was negative. Bacterial culture yielded a heavy growth of *Staphylococcus pseudintermedius*.

Two weeks later, the exophthalmos suddenly worsened and, the cat developed a miotic pupil (OD) and severe exposure keratitis. Menace, pupillary light and corneal reflexes were also absent. An exenteration of the right orbit was performed. On exploration the ventral aspect of the orbit was eroded and a discharging sinus was located rostrally. The orbit was lavaged with sterile saline then irrigated with a 1% voriconazole pluronic gel (BOVA compounding pharmacy). Itraconazole, but not AMB, was continued postoperatively. Orbital contents were submitted to the Veterinary Pathology Diagnostic Services Laboratory at the University of Sydney for histopathology and culture.

Crush preparations of the retrobulbar tissue were stained with modified Wright–Giemsa (Diff-Quik; Dade Behring) and Burke's modification of the Gram stain to reveal numerous tangles of wide gram-positive branching bacterial filaments and scattered macrophages in necrotic tissue (Figure 2). The tissue was cultured on sheep blood agar (Oxoid) at 37°C, aerobically, anaerobically and in 10% CO<sub>2</sub>, as well as on Sabouraud dextrose



**Figure 2** (a,b) Cytological preparations of excised retrobulbar tissue showing numerous tangles of wide-branching bacterial filaments in necrotic tissue that were gram positive (Burke's modification) and (c) stained with a modified Wright–Giemsa stain (Diff-Quik)

agar containing chloramphenicol and gentamicin at 28°C and 37°C. After incubation for 3 days, a heavy growth of 2.5 mm dull, cream-coloured colonies surrounded by a wide zone of complete haemolysis was evident on the blood agar plates incubated aerobically and in CO<sub>2</sub>. No growth occurred on the Sabouraud agar and the isolate did not grow anaerobically. Aerial hyphae were not apparent and the organism was not acid fast. The provisional identification was an aerobic actinomycete and the isolate was forwarded to the Queensland Mycobacterium Reference Laboratory for further identification.

The molecular identity of the isolate was determined by PCR and comparative gene sequence analysis of the 16S recombinant DNA (rDNA) region (primers BF – 5' AGAGTTGGATCCTGGCTCAG 3' and R2 – 5' CCTAGAGCTCTTTACG 3') and Basic Local Alignment Search Tool (BLAST) search (<http://www.ncbi.nlm.nih.gov/genbank/>). The resulting sequence had 100% homology with with known isolates of *Streptomyces cinnamoneus* (GenBank accession numbers AB184718.1, AB184716.1, AY999754.1 and AB184717.1). On histopathology there was a multifocal inflammatory infiltrate in the globe, eyelid and retrobulbar tissue, as well as necrotic foci in the globe. Neutrophils, eosinophils, macrophages and gram-positive filamentous bacteria were present in all tissues.

Antifungal therapy was ceased and the cat was treated with trimethoprim (TMP)/sulfadiazine (SDZ) (Tribrissen Schering-Plough) 30 mg/kg q24h PO, pending susceptibility results. The isolate was susceptible to clarithromycin, erythromycin, amoxicillin-clavulanic acid, imipenem and ceftiofur but resistant to marbofloxacin, clindamycin, trimethoprim sulfonamide and doxycycline. TMP/SDZ administration was stopped and erythromycin (Erymicin 200; Jurox) was commenced (15 mg/kg q12h SC) but discontinued after 24 h owing to lethargy and anorexia. The owners were unable to medicate the cat and the referring veterinarian administered

amoxicillin/clavulanic acid (40 mg/kg SC) and clarithromycin (125 mg PO) q24h for 1 month. During initial treatment the cat developed a reduced menace and pupillary light response in the remaining eye; however, exophthalmos was not noted. Three months after the cessation of treatment there was residual visual impairment in the left eye but the cat was otherwise clinically well.

Nine months after initial presentation, the cat represented to the referring veterinarian with a swelling at the previous surgery site. Under general anaesthetic 0.5 ml purulent fluid was aspirated from the site. Culture and sensitivity were negative. The cat was continued on amoxicillin/clavulanic acid (40 mg/kg SC) and clarithromycin (125 mg PO) q24h for a further month and the swelling resolved. Antimicrobial therapy was changed to azithromycin (Zithromax 125 mg) suspension orally q24h for 5 days, then twice weekly as a maintenance dose for 3 months. There was residual visual impairment in the remaining eye, with clinical signs of mydriasis, reduced menace and pupillary light responses remaining. At re-check 3 years after the initial presentation the residual visual impairment persisted but the cat was otherwise systemically well.

## Discussion

To our knowledge, this is the first report of *S cinnamoneus* infection in a cat. *S cinnamoneus*, a gram-positive, branching filamentous bacteria that belongs to the genus *Streptomyces* and order Actinomycetales, which also includes *Nocardia* and *Rhodococcus*, as well as the anaerobic/microaerophilic actinomycetes.<sup>1–10</sup> Mycetomas due to *Streptomyces* species are clinically indistinguishable from those due to *Actinomyces* species.<sup>11</sup> *Streptomyces* species infections are rarely reported in cats, with two reports describing subcutaneous mycetomas over the scapula in one cat, and affecting a hindlimb in another. The latter was identified as *Streptomyces griseus*.<sup>11,12</sup> Although



reported infrequently, *Streptomyces* species are a potential cause of serious human and animal infections.<sup>8,13</sup>

*Streptomyces* species are slow-growing saprophytes,<sup>6–8,10</sup> which are prevalent in tropical and subtropical regions.<sup>14</sup> Infection is usually established after there is a disruption of the subcutis or mucosa through abrasion or traumatic implantation.<sup>1,7,11,12</sup> The collagenase activity of *Streptomyces* species enables access into deeper tissues.<sup>15</sup> Immunosuppression due to FeLV or FIV, although not present in this case, is a risk factor for the establishment of infection.<sup>1</sup> Once established, infection spreads to adjacent tissues and an actinomycotic mycetoma is formed.<sup>6,7,16</sup> Soft tissue infections can progress to involve bone over time. Infection is usually characterised by tumefaction and draining sinuses with granules or grains.<sup>3</sup>

In this case, the underlying route of infection and precipitating factors were not identified. There was no evidence of dental disease on examination of the oral cavity under general anaesthesia or on MRI, and no foreign material was identified during nasal cavity lavage or orbital exenteration. Given the involvement of the nasal cavity and identification of a communication between the nasal cavity and orbit at surgery, the most likely route of infection was inhalational, possibly involving unidentified plant material, with subsequent invasion of the orbit. In retrospect, biopsy and histopathological examination of affected nasal mucosa may have been helpful. Currently, there are no standardised guidelines for the treatment of *Streptomyces* infections in humans or animals. Lengthy treatments with antimicrobials of up to a year have been described for infections in humans.<sup>7</sup> In this case, exenteration was indicated given the invasiveness, location and biological behaviour of the organism.

This case is interesting because the initial clinical presentation of nasal discharge, exophthalmos and oral cavity mass in the pterygopalatine fossa is similar to feline sino-orbital aspergillosis. Erroneous diagnosis of aspergillosis was made initially owing to the similar cytological appearance of *S. cinnamoneus* to filamentous fungi. *Streptomyces* species possess aerial hyphae that tend to form chains, and filaments that can be mistaken for fungal hyphae.<sup>8</sup> This resemblance is further strengthened by the presence of asexual spores,<sup>9</sup> once nutrients are depleted.<sup>17</sup> The organism was definitively identified in this case using DNA extracted from bacterial culture material and PCR and sequencing of the  $\gamma$  region of 16S rDNA, with comparison to a reference database (GenBank) using the BLAST algorithm. *Streptomyces* species have been identified previously by a characteristic gene signature for 23S and 16S rRNA.<sup>8,17</sup> In this case, the  $\gamma$  region of 16S rDNA was found to have 100% identity when compared with GenBank sequences of *S. cinnamoneus*. Minimal levels of DNA relatedness between strains have been previously described with values of genomic relatedness >80% corresponding to species-level relatedness.<sup>16</sup>

Most retrobulbar bacterial abscesses in cats are caused by mixed aerobic and anaerobic bacteria, with one study identifying *Pasteurella* species and *Bacteroides* species as the most common isolates.<sup>18</sup> Other infectious causes include fungi (*Cryptococcus* species, *Penicillium* species,<sup>19</sup> *Aspergillus* species,<sup>20–22</sup> *Blastomyces* species, *Coccidioides* species, phaeohyphomycoses)<sup>23</sup> and *Pythium insidiosum*.<sup>24</sup> Infections can result from underlying dental or nasal cavity disease, penetrating trauma or foreign body inoculation or haematogenous dissemination from a distant focus of infection.<sup>18</sup> Cats with bacterial retrobulbar abscesses typically present with acute-onset exophthalmos and pain on palpation of the globe and opening of the mouth.<sup>18,25</sup> By contrast, in this case the patient had progressive clinical signs over a chronic time course.

## Conclusions

Although neoplasia and fungal infections are the most common cause of chronic retrobulbar disease in cats,<sup>26–29</sup> this case report demonstrates that actinomycetes should also be considered a differential diagnosis for cats presenting with slowly progressive orbital disease.

**Acknowledgements** We would like to thank Dr Zoe Leonard for interpretation of the magnetic resonance imaging, and Associate Professor Mark Krockenberger for histopathological interpretation.

**Funding** The authors received no specific grant from any funding agency in the public, commercial or not-for-profit sectors for the preparation of this case report.

**Conflict of interest** The authors do not have any potential conflicts of interest to declare.

## References

- 1 Beale KM. **Nodules and draining tracts.** *Vet Clin North Am Small Anim Pract* 1995; 25: 887–900.
- 2 Grooters M. **Weird fungi: making sense of emerging and unusual mycoses.** Proceedings of the 21st Annual Forum of the American College of Veterinary Internal Medicine 2003 Charlotte, NC. USA.
- 3 Sharman MJ, Goh CS, Kuipers von Lande RG, et al. **Case Report: intra-abdominal actinomycetoma in a cat.** *J Feline Med Surg* 2009; 11: 701–705.
- 4 Rose CE, Brown JM and Fisher JF. **Brain abscess caused by *Streptomyces* infection following penetration trauma: case report and results of susceptibility analysis of 92 isolates of *Streptomyces* species submitted to the CDC from 2000–2004.** *J Clin Microbiol* 2008; 46: 821–823.
- 5 Thomovsky E and Kerl ME. **Actinomycosis and nocardiosis.** *Stand Care Emerg Med Crit Care* 2008; 10: 4–10.
- 6 Kapadia M, Rolston KVI and Han XY. **Invasive *Streptomyces* infections.** *Am J Clin Pathol* 2007; 127: 619–624.
- 7 Joseph NM, Harish BN, Sistla S, et al. ***Streptomyces* bacteraemia in a patient with actinomycotic mycetoma.** *J Infect Develop Ctries* 2010; 4: 249–252.

- 8 McNeil MM and Brown JM. **The medically important aerobic actinomycetes: epidemiology and microbiology.** *Clin Microbiol Rev* 1994; 7: 357–417.
- 9 Mossad SB, Tomford JW, Stewart R, et al. **Case report of *Streptomyces* endocarditis of a prosthetic aortic valve.** *J Clin Microbiol* 1995; 33: 3335–3337.
- 10 Dunne EF, Burman WJ and Wilson ML. ***Streptomyces* pneumonia in a patient with human immunodeficiency virus infection: case report and review of the literature on invasive streptomyces infections.** *Clin Infect Dis* 1998; 27: 93–96.
- 11 Lewis GE, Fidler WJ and Crumrine MH. **Mycetoma in a cat.** *J Am Vet Med Assoc* 1972; 161: 500–503.
- 12 Reinke SI, Ihrke PJ, Stannard AA, et al. **Actinomycotic mycetoma in a cat.** *J Am Vet Med Assoc* 1986; 189: 446–448.
- 13 Martin MC, Manteca A, Castillo ML, et al. ***Streptomyces albus* isolated from a human actinomycetoma and characterized by molecular techniques.** *J Clin Microbiol* 2004; 42: 5957–5960.
- 14 Holtz HA, Lavery DP and Kapila R. **Actinomycetales Infection in the acquired immunodeficiency syndrome.** *Ann Intern Med* 1985; 102: 203–205.
- 15 Harrington DJ. **Bacterial collagenases and collagen-degrading enzymes and their potential role in human disease.** *Infect Immun* 1996; 64: 1885–1891.
- 16 Quintana ET, Wierzbicka K, Mackiewicz P, et al. ***Streptomyces sudanensis* sp. nov., a new pathogen isolated from patients with actinomycetoma.** *Antonie Van Leeuwenhoek* 2008; 93: 305–313.
- 17 Schrempf H. **The family Streptomycetaceae, part II: molecular biology.** *Prokaryotes* 2006; 3: 605–622.
- 18 Wang AL, Ledbetter EC and Kern TJ. **Orbital abscess bacterial isolates and in vitro antimicrobial susceptibility patterns in dogs and cats.** *Vet Ophthalmol* 2009; 12: 91–96.
- 19 Peiffer RL, Belkin PV and Janke BH. **Orbital cellulitis, sinusitis and pneumonitis caused by *Penicillium* sp. in a cat.** *J Am Vet Med Assoc* 1980; 176: 449–451.
- 20 Barrs VR, Halliday C, Martin P, et al. **Sinonasal and sino-orbital aspergillosis in 23 cats: aetiology, clinicopathological features and treatment outcomes.** *Vet J* 2012; 191: 58–64.
- 21 Barachetti L, Mortellaro CM, Giancamillo MD, et al. **Bilateral orbital and nasal aspergillosis in a cat.** *Vet Ophthalmol* 2009; 12: 176–182.
- 22 Barrs VR, Beatty JA, Lingard AE, et al. **Feline sino-orbital aspergillosis: an emerging clinical syndrome.** *Aust Vet J* 2007; 85: 23.
- 23 Bernays ME and Peiffer RL. **Ocular infections with dematiaceous fungi in two cats and a dog.** *J Am Vet Med Assoc* 1998; 213: 507–509.
- 24 Bissonnette KW, Sharp NJ, Dykstra MH, et al. **Nasal and retrobulbar mass in a cat caused by *Pythium insidiosum*.** *J Med Vet Mycol* 1991; 29: 39–44.
- 25 Smith LN and Hoffman SB. **A case series of unilateral orbital aspergillosis in three cats and treatment with voriconazole.** *Vet Ophthalmol* 2010; 13: 190–203.
- 26 Attali-Soussay K, Jegou JP and Clerc B. **Retrobulbar tumours in dogs and cats: 25 cases.** *Vet Ophthalmol* 2001: 19–27.
- 27 Barrs VR, van Doorn TM, Houbraken J, et al. ***Aspergillus felis* sp. nov., an emerging agent of invasive aspergillosis in humans, cats, and dogs.** *PLoS One* 2013; 14.
- 28 Dennis R. **Use of magnetic resonance imaging for the investigation of orbital disease in small animals.** *J Small Anim Pract* 2000; 41: 145–155.
- 29 Armour MD, Broome M, Dell’Anna G, et al. **A review of orbital and intracranial magnetic resonance imaging in 79 canine and 13 feline patients (2004–2010).** *Vet Ophthalmol* 2011; 14: 215–226.