



Lumbosacral intraspinal extradural ganglion cyst in a cat

Authors: de Strobel, Francesca, Taeymans, Olivier, Rosati, Marco, and Cherubini, Giunio B

Source: Journal of Feline Medicine and Surgery Open Reports, 1(2)

Published By: SAGE Publishing

URL: <https://doi.org/10.1177/2055116915604875>

BioOne Complete (complete.BioOne.org) is a full-text database of 200 subscribed and open-access titles in the biological, ecological, and environmental sciences published by nonprofit societies, associations, museums, institutions, and presses.

Your use of this PDF, the BioOne Complete website, and all posted and associated content indicates your acceptance of BioOne's Terms of Use, available at www.bioone.org/terms-of-use.

Usage of BioOne Complete content is strictly limited to personal, educational, and non - commercial use. Commercial inquiries or rights and permissions requests should be directed to the individual publisher as copyright holder.

BioOne sees sustainable scholarly publishing as an inherently collaborative enterprise connecting authors, nonprofit publishers, academic institutions, research libraries, and research funders in the common goal of maximizing access to critical research.



Lumbosacral intraspinal extradural ganglion cyst in a cat

Francesca de Strobel¹, Olivier Taeymans², Marco Rosati³
and Giunio B Cherubini¹

Journal of Feline Medicine and Surgery
Open Reports
1–5

© The Author(s) 2015
Reprints and permissions:
sagepub.co.uk/journalsPermissions.nav
DOI: 10.1177/2055116915604875
jfmsopenreports.com



Abstract

Case summary A 16-year-old neutered female domestic shorthair cat was referred for chronic history of reluctance to jump, stiffness of the tail and lower back pain. Mild pelvic limb ataxia, reduced perianal reflex and lumbosacral discomfort were present on neurological examination. On magnetic resonance imaging, a well-defined rounded structure of 3 mm in diameter was identified on the right dorsal aspect of the epidural space at L7–S1, causing displacement of the cauda equina. The lesion was hyperintense to spinal cord parenchyma on T2-weighted images and hypointense on T1-weighted images, consistent with a fluid-filled structure. A Lumbosacral dorsal laminectomy was performed. A clear fluid-containing structure was identified between the right L7 nerve root and the cauda equina. Following surgical excision, histopathology confirmed the cystic nature of the lesion and revealed thick disorganised sheaths of fibrocollagenous tissue and flattened mesenchymal cells lining the luminal part of the cyst wall. A diagnosis of intraspinal ganglion cyst was made. The cat recovered uneventfully. Seven months after surgery euthanasia was performed for unrelated reasons; no neurological deficits were present.

Relevance and novel information This is the first reported case of intraspinal ganglion cyst in a cat. Intraspinal extradural cysts should be considered among other differential diagnoses for cats with lumbosacral myelopathy/radiculopathy.

Accepted: 17 August 2015

Case description

A 16-year-old neutered female domestic shorthair cat was referred for neurological examination after approximately 2 years of reduced exercise and 2 weeks of reluctance to jump, stiffness in tail movements and lower back discomfort. The cat was up to date with vaccinations and had always been an indoor cat. There was no history of trauma or previous illness, apart from chronic renal disorder, which had been controlled with benazepril.

General physical examination was unremarkable. On neurological examination mild pelvic limb ataxia, reduced perineal reflex and lumbosacral pain on palpation of the spine were present. The presumptive anatomical localisation was either to the caudal lumbar intumescence (L6–S3) or to the cauda equina. Differential diagnoses included a space-occupying lesion, such as neoplasia or a protruding disc, as well as vascular and infectious/inflammatory diseases.

A complete cell blood count revealed reduced red blood cell count $3.5 \times 10^{12}/l$ (reference interval [RI]

7.00–11.60), haemoglobin 5.8 g/dl (RI 9.0–14.0), haematocrit 0.170 l/l (RI 0.29–0.46) and lymphocytes $0.86 \times 10^9/l$ (RI 1.5–8.0). Serum biochemical abnormalities included increased urea 17.2 mmol/l (RI 6.0–10.0), creatinine 212 $\mu\text{mol}/l$ (RI 40–150), glucose 12.5 mmol/l (RI 4.3–6.6), cholesterol 5.0 mmol/l (RI 1.9–3.9) and creatine kinase 385 IU/L (RI 0–152). On analysis, urine was

¹Neurology and Neurosurgery Department, Dick White Veterinary Referrals Centre, Cambridge, UK

²Radiology Department, Dick White Veterinary Referrals Centre, Cambridge, UK

³Centre for Clinical Veterinary Medicine, Veterinary Faculty, Munich, Germany

Corresponding author:

Francesca de Strobel DVM, MRCVS, Neurology and Neurosurgery Department, Dick White Veterinary Referrals Centre, Station Farm, London Road, Six Mile Bottom, Cambridgeshire CB8 0UH, UK
Email: fds@dwr.co.uk



Creative Commons CC-BY-NC: This article is distributed under the terms of the Creative Commons Attribution-NonCommercial 3.0 License (<http://www.creativecommons.org/licenses/by-nc/3.0/>) which permits non-commercial use, reproduction and distribution of the work without further permission provided the original work is attributed as specified on the SAGE and Open Access page (<https://us.sagepub.com/en-us/nam/open-access-at-sage>).

poorly concentrated (specific gravity 1.016) and protein/creatinine ratio was increased 0.3 (RI <0.2). Further investigations for infectious diseases were not performed; however, given the history, the laboratory changes were more likely to be related to the chronic renal disorder.

The cat underwent magnetic resonance imaging (MRI) examination (Aperto, 0.4T; Hitachi Medical System) of the lumbosacral spine. A rounded structure at the level of the L7–S1 right epidural space, apparently arising from the right articular facet joint, was identified.

The lesion was well defined, hyperintense to spinal cord parenchyma on T2-weighted (T2W) images and hypointense on T1-weighted (T1W) images, did not exhibit contrast enhancement and was therefore compatible with a cyst-like structure (Figure 1). Significant displacement of the cauda equina dorsally and to the left was associated with the lesion. Furthermore, at the same vertebral level, the intervertebral disc (IVD) showed decreased signal intensity, and signs of degeneration with osteophytic reaction on the ventral edges of the vertebral bodies were present adjacent to the disc space.

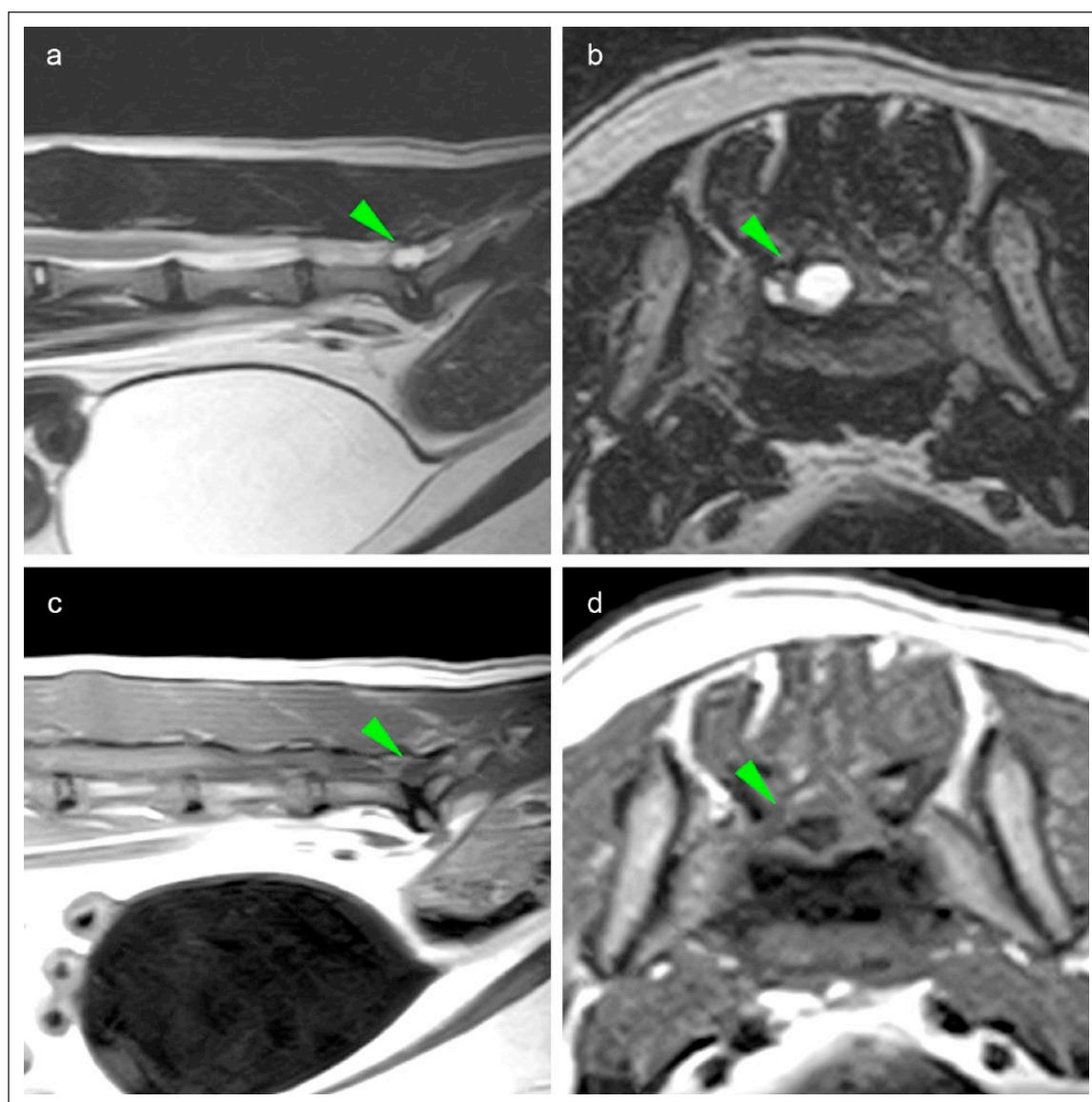


Figure 1 T2-weighted (T2W) and T1-weighted (T1W) (a, c) parasagittal and (b, d) transverse magnetic resonance images of the lumbosacral spine at the level of the lumbosacral joint. There is a T2W hyperintense and T1W hypointense well-circumscribed rounded lesion (arrowhead) in the vertebral canal craniodorsal to the L7–S1 intervertebral disc (IVD) and lateralised on the right side. The cyst-like structure extends dorsally, compressing and displacing the cauda equina dorsally and to the left. The lumbosacral IVD shows a decreased signal intensity, and signs of degeneration with osteophytic reaction on the ventral edges of the vertebral bodies.

Surgical excision of the cyst was performed. After premedication with methadone (Comfortan 0.2 mg/kg IV; Dechra) and dexmedetomidine (Dexdomitor 1 µg/kg IV; Orion Pharma), anaesthesia was induced with alfaxalone (Alfaxan 1 mg/kg IV; Jurox) and maintained with isoflurane (1.5–2.0%) in oxygen and mechanical ventilation, maintaining an end-tidal CO₂ of 33–35 mmHg. Compound sodium lactate solution (Hartmann's Lactated Ringers 5 ml/kg/h; Braun Vet Care) was administered throughout surgery. Intraoperative analgesia was provided by administration of alfentanil (Rapifen 0.00075–0.001 mg/kg/min; Janssen). Cefuroxime (Zinacef 20 mg/kg IV; GlaxoSmithKline) was administered once immediately before surgery. After L7–S1 dorsal laminectomy, a clear fluid-containing cyst-like structure of approximately 3 mm in diameter located between the right L7 nerve root and cauda equina was identified, corresponding with the reported MRI findings. The wall of the lesion was thin and fragile, and clear and colourless fluid leaked out prior to excision. The cyst protruded ventrally from the vertebral canal and appeared to be in contact with the ventral longitudinal ligament; no communication with the articular facet joint cavity was found. The cyst-like lesion was then entirely excised and samples of the wall were submitted for histological analysis. Preservative-free morphine (Morphine preservative free 0.1 mg/kg; Martindale Pharma) was splashed over the dura mater immediately prior to wound closure. Postoperative medications included buprenorphine (Vetergesic 0.02 mg/kg q6h IV; Ceva) and ketamine (Narketan constant rate infusion 0.2–0.3 mg/kg/h; Vétoquinol) for the first 12 h after surgery and gabapentin (10 mg/kg q8–12h; Summit Veterinary) for 2 months.

Histopathology revealed thick disorganised sheaths of fibrocollagenous tissue, collagen necrosis and infiltration of lymphohistiocytes and siderophages alongside more vascularised parts (Figure 2A). The luminal part of the wall was lined with flattened mesenchymal cells (Figure 2B). The lesion was therefore consistent with a cyst, with an intraspinal ganglion cyst being considered the most likely diagnosis, based on previous classification.^{1,2} The cat recovered uneventfully, showing rapid and progressive signs of improvement, and was discharged 3 days after surgery. At 1 month follow-up the cat was showing occasional episodes of discomfort and mild stiffness on pelvic limbs; no neurological deficits were present on neurological assessment performed 2 and 3 months later.

One month after surgery, the cat presented with suspected visual impairment and ophthalmological examination revealed the presence of bilateral retinal detachment and partial reattachment. Toxoplasma serology was negative and systemic hypertension was confirmed by measuring the systolic blood pressure using Doppler sphygmomanometry (mean reading 210 mmHg). Treatment with amlodipine (Amlodipine 0.625 mg/cat q24h; Summit Veterinary) was initiated, with improvement of the ocular condition and normalisation of the blood pressure 3 weeks later (mean reading 135 mmHg). Seven months after surgery, the cat was euthanased for acute deterioration of the renal condition. At that time, no neurological deficits were reported by the owner.

Discussion

Intraspinal cysts consist of degenerative non-meningeal extradural fluid-filled structures arising from periarticular joint tissue, and, less commonly, from the ligaments

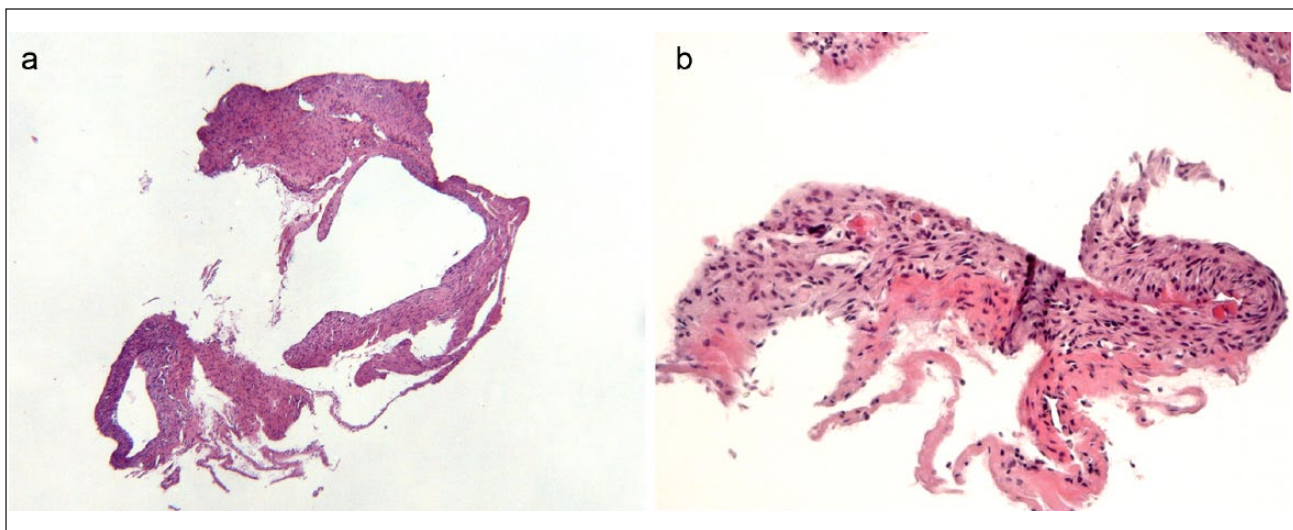


Figure 2 (a) Histological section of the ganglionic cyst, featuring bundles of variously thick fibrocollagenous tissue characterised by multiple clefts and resembling the wall of a cystic structure. Haematoxylin and eosin ($\times 2.5$). (b) Detail of the luminal portion of the cyst wall at higher magnification. Multiple layers of flattened mesenchymal cells intermingle with dense collagen fibres. Haematoxylin and eosin ($\times 10$)

of the vertebral canal or from the annulus of the IVD.^{1,2} Histologically, two types of intraspinal cysts have been recognised in humans: synovial cysts and ganglion cysts. Synovial cysts are the result of synovial outpouchings through weakened capsular tissue and have a synovium-like epithelial lining, whereas ganglion cysts arise from mucinous degeneration of periarticular connective tissue and contain myxoid material with a fibrous wall. It is unclear whether the two conditions are separate entities or if these may represent a same entity at different stages of development.³

Intraspinal cysts are rarely reported in veterinary medicine. Most of the cases describe synovial cysts in dogs,^{4–12} and a single case of multiple ganglion cysts has been reported in a German Shepherd dog.¹³ Intraspinal extradural cysts have never been reported in cats.

On cross-sectional imaging, it is not possible to distinguish between ganglion and synovial cysts as they both appear as extradural intraspinal structures, with variable signal characteristics/computed tomography attenuation depending on the cystic content.^{14,15} Indeed, cysts may contain synovial fluid, mucinous material, gas and variable amounts of protein and/or blood. The similar appearance to cerebrospinal fluid (isointense on T1W images and hyperintense on T2W images) encountered in the lesion described here is compatible with synovial fluid.¹⁵ The lack of cytological examination did not permit us to make further considerations about the specific nature of the fluid. In humans, calcification of the cyst wall is often seen;¹⁴ furthermore, contrast administration may result in rim enhancement of the cyst wall,³ as a possible result of hyperplastic connective tissue making up the wall. A well-defined circumferential enhancement of variable intensity has also been reported in dogs with synovial cysts;^{4,7,9,12} however, in the case described herein no areas of contrast uptake or calcification were detected.

The cause of the formation of intraspinal cysts is not clear, and four hypothesis have been described in humans: (1) extrusion of synovial fluid from a defect in the joint capsule; (2) myxoid degeneration and cyst formation in collagen (3) increased hyaluronic acid production of fibroblast or (4) non-specific proliferation of mesenchymal cells.^{16–19} The formation of intraspinal cysts is believed to be triggered either by traumatic or degenerative disease of the articular process, intervertebral ligaments or IVD.⁶ No history of trauma was present, and considering the advanced age of the cat, a degenerative aetiology may be speculated in this cat. MRI also showed evidence of other degenerative changes (spondylosis ventrally to vertebral bodies and IVD degeneration), further supporting this speculation. Spondylosis deformans is rarely associated with neurological signs and is often described as an idiopathic

finding; however, it has occasionally been associated with instability of the lumbosacral joint in dogs.²⁰ It might therefore be that some degree of instability may have predisposed to degenerative changes and subsequent cyst formation.^{6,11,12} Intraspinal cysts described in dogs have been reported to occur in the cervical, thoracolumbar and lumbosacral regions, with the majority of reports relating to the cervical region.^{4–12} In humans, cysts tend to occur at L4–L5,³ and it has been suggested that the increased joint motion present at this site may predispose to facet joint osteoarthritis and cyst formation. In analogy, L7–S1 has been reported to have the greatest mobility in dogs,²¹ and it is considered safe to assume the same for cats.

Clinically, extramedullary cysts of the vertebral canal generally result in slowly progressive signs, which can vary depending on the location of the cyst and can also be clinically silent depending on their size.²²

The standard treatment of a symptomatic intraspinal cyst in humans generally involves surgical excision of the cyst with a low recurrence of cyst formation;²³ the same positive results have been reported in dogs treated surgically, with a median follow-up of 9 months.^{4–12}

Conclusions

Intraspinal extradural cysts should be considered among other differential diagnoses for cats with lumbosacral myelopathy/radiculopathy. MRI is considered helpful in diagnosing and differentiating intraspinal cysts from other potential lesions. Surgical excision permits reaching a resolution of clinical signs in the short-term and is required to achieve definitive diagnosis in vitam following histology. Long-term prognosis is unknown.

Conflict of interest The authors declared no potential conflicts of interest with respect to the research, authorship, and/or publication of this article.

Funding The authors received no financial support for the research, authorship, and/or publication of this article.

References

- 1 Kjerulf TD, Terry DW, Jr and Boubelik RJ. **Lumbar synovial or ganglion cysts.** *Neurosurgery* 1986; 19: 415–420.
- 2 Onofrio BM and Mih AD. **Synovial cysts of the spine.** *Neurosurgery* 1988; 22: 642–647.
- 3 Hsu KY, Zucherman JF, Shea WJ, et al. **Lumbar intraspinal synovial and ganglion cysts (facet cysts). Ten-year experience in evaluation and treatment.** *Spine* 1995; 20: 80–89.
- 4 Levitski RE, Chauvet AE, Lipsitz D, et al. **Cervical myelopathy associated with extradural synovial cysts in 4 dogs.** *J Vet Intern Med* 1999; 13: 181–186.
- 5 Perez B, Rollan E, Ramiro F, et al. **Intraspinal cyst in a dog.** *J Am Anim Hosp Assoc* 2000; 36: 235–238.

- 6 Dickinson PJ, Sturges BK, Berry WL, et al. **Extradural spinal synovial cysts in nine dogs.** *J Small Anim Pract* 2001; 42: 502–509.
- 7 Forterre F, Kaiser S, Garner M, et al. **Synovial cysts associated with cauda equina syndrome in two dogs.** *Vet Surg* 2006; 35: 30–33.
- 8 Bley T, Lang J, Jaggy A, et al. **Lumbar spinal ‘juxtaarticular’ cyst in a Gordon setter.** *J Vet Med A Physiol Pathol Clin Med* 2007; 54: 494–498.
- 9 Penning V, Benigni L, Steeves E, et al. **Imaging diagnosis-degenerative intraspinal cyst associated with an intervertebral disc.** *Vet Radiol Ultrasound* 2007; 48: 424–427.
- 10 Sale CS and Smith KC. **Extradural spinal juxtafacet (synovial) cysts in three dogs.** *J Small Anim Pract* 2007; 48: 116–119.
- 11 Harris KP, Saveraid TC and Rodenas S. **Dorsolateral spinal cord compression at the C2-C3 junction in two Cavalier King Charles spaniels.** *Vet Rec* 2011; 169: 416.
- 12 Forterre F, Reves NV, Stahl C, et al. **Atlantoaxial synovial cyst associated with instability in a Chihuahua.** *Case Rep Vet Med* 2012; 2012: 1–4.
- 13 Webb AA, Pharr JW, Lew LJ, et al. **MR imaging findings in a dog with lumbar ganglion cysts.** *Vet Radiol Ultrasound* 2001; 42: 9–13.
- 14 Liu SS, Williams KD, Drayer BP, et al. **Synovial cysts of the lumbosacral spine: diagnosis by MR imaging.** *Am J Neuroradiol* 1989; 10: 1239–1242.
- 15 Fritz RC, Kaiser JA, White AH, et al. **Magnetic resonance imaging of a thoracic intraspinal synovial cyst.** *Spine* 1994; 19: 487–490.
- 16 Herrington JL, Jr and Edwards LW. **Ganglion cysts arising in unusual locations.** *Ann Surg* 1955; 142: 900–903.
- 17 Haase J. **Extradural cyst of ligamentum flavum L 4 – a case.** *Acta Orthop Scand* 1972; 43: 32–38.
- 18 Bhushan C, Hodges FJ III and Wityk JJ. **Synovial cyst (ganglion) of the lumbar spine simulating extradural mass.** *Neuroradiology* 1979; 18: 263–268.
- 19 Pendleton B, Carl B and Pollay M. **Spinal extradural benign synovial or ganglion cyst: case report and review of the literature.** *Neurosurgery* 1983; 13: 322–326.
- 20 Levine GJ, Levine JM, Walker MA, et al. **Evaluation of the association between spondylosis deformans and clinical signs of intervertebral disk disease in dogs: 172 cases (1999–2000).** *J Am Vet Med Assoc* 2006; 228: 96–100.
- 21 Smolders LA, Kingma I, Bergknut N, et al. **Biomechanical assessment of the effects of decompressive surgery in non-chondrodystrophic and chondrodystrophic canine multi-segmented lumbar spines.** *Eur Spine J* 2012; 21: 1692–1899.
- 22 Lowrie ML, Platt SR and Garosi LS. **Extramedullary spinal cysts in dogs.** *Vet Surg* 2014; 43: 650–652.
- 23 Epstein NE and Baisden J. **The diagnosis and management of synovial cysts: efficacy of surgery versus cyst aspiration.** *Surg Neurol Int* 2012; 3: 157–166.