



Successful subtotal orbitectomy in a cat with osteoma

Authors: Corgozinho, Katia B, Cunha, Simone CS, Siqueira, Ricardo S, and Souza, Heloisa JM

Source: Journal of Feline Medicine and Surgery Open Reports, 1(2)

Published By: SAGE Publishing

URL: <https://doi.org/10.1177/2055116915616402>

BioOne Complete (complete.BioOne.org) is a full-text database of 200 subscribed and open-access titles in the biological, ecological, and environmental sciences published by nonprofit societies, associations, museums, institutions, and presses.

Your use of this PDF, the BioOne Complete website, and all posted and associated content indicates your acceptance of BioOne's Terms of Use, available at www.bioone.org/terms-of-use.

Usage of BioOne Complete content is strictly limited to personal, educational, and non - commercial use. Commercial inquiries or rights and permissions requests should be directed to the individual publisher as copyright holder.

BioOne sees sustainable scholarly publishing as an inherently collaborative enterprise connecting authors, nonprofit publishers, academic institutions, research libraries, and research funders in the common goal of maximizing access to critical research.



Successful subtotal orbitectomy in a cat with osteoma

Katia B Corgozinho¹, Simone CS Cunha²,
Ricardo S Siqueira¹ and Heloisa JM Souza¹

Journal of Feline Medicine and Surgery
Open Reports
1–4

© The Author(s) 2015
Reprints and permissions:
sagepub.co.uk/journalsPermissions.nav
DOI: 10.1177/2055116915616402
jfmsopenreports.com



Abstract

Case summary A 14-year-old Siamese neutered male cat was evaluated for anorexia and a left periorbital mass. Skull radiographic findings showed a well-defined lesion resembling new compact bone formation without destruction. A subtotal orbitectomy was indicated. The tumor was removed intact with a normal tissue margin of at least 1 cm. There were no postsurgical complications. Histopathologic examination revealed an osteoma. The cat returned to normal appetite and activity 15 days after surgery. Six months after surgery, there were no gross signs of recurrence.

Relevance and novel information Periorbital tumors are infrequently diagnosed in companion animals and most are malignant. In this case, the diagnosis was orbital osteoma. The most commonly affected bone for osteoma in cats is the mandibular bone; few cases have been identified in orbital bones. Orbital surgery has the potential to be challenging owing to complex anatomy, difficult exposure and the tendency to bleed. Surgical complications are common. In this case, although the disease was advanced, subtotal orbitectomy was successfully performed.

Accepted: 11 October 2015

Introduction

Periorbital tumors are infrequently diagnosed in companion animals and most are malignant.^{1–5} Diagnosis is based on clinical signs, radiographic features and histological diagnosis. Orbital surgery has the potential to be challenging owing to complex anatomy, difficult exposure and a tendency to bleed.⁶ Surgical complications are common.^{2,6}

The aim of this study is to report a successful subtotal orbitectomy in a cat with orbital osteoma.

Case description

A 14-year-old Siamese neutered male cat was evaluated for anorexia and a left periorbital mass. The mass had a bony consistency on palpation (Figure 1). The left eye could not be visualized. A complete blood count (CBC) and serum chemistry profile were performed. The results from the CBC did not reveal any abnormality, and the only abnormal value on the biochemical panel was a mildly elevated creatinine level (2.5 mg/dl; reference interval 0.9–1.8 mg/dl). Skull radiographic findings showed a well-defined lesion resembling new compact bone formation without

destruction (Figure 2). In thoracic radiographs, there was no evidence of metastatic disease. Computed tomography was not performed owing to financial issues.

A subtotal orbitectomy was indicated. The cat was premedicated intramuscularly with acepromazine (0.03 mg/kg) and methadone (0.2 mg/kg) by subcutaneous injection 15 mins prior to induction. Anesthesia was induced with propofol (4 mg/kg) by intravenous injection and maintained with isoflurane. Methadone was given intramuscularly q6h for 24 h.

¹Department of Animal Clinical and Surgery, School of Veterinary Medicine, Universidade Federal Rural do Rio de Janeiro, Seropedica, Brazil

²Department of Animal Clinical and Reproduction, Universidade Federal Fluminense, Niterói, Brazil

Corresponding author:

Katia B Corgozinho DVM, PhD, Department of Animal Clinical and Surgery, School of Veterinary Medicine, Federal Rural University of Rio de Janeiro, BR 465, Km 7, Seropedica, RJ, 23890-000, Brazil
Email: katia.barao@gmail.com



Creative Commons CC-BY-NC: This article is distributed under the terms of the Creative Commons Attribution-NonCommercial 3.0 License (<http://www.creativecommons.org/licenses/by-nc/3.0/>) which permits non-commercial use, reproduction and distribution of the work without further permission provided the original work is attributed as specified on the SAGE and Open Access page (<https://us.sagepub.com/en-us/nam/open-access-at-sage>).

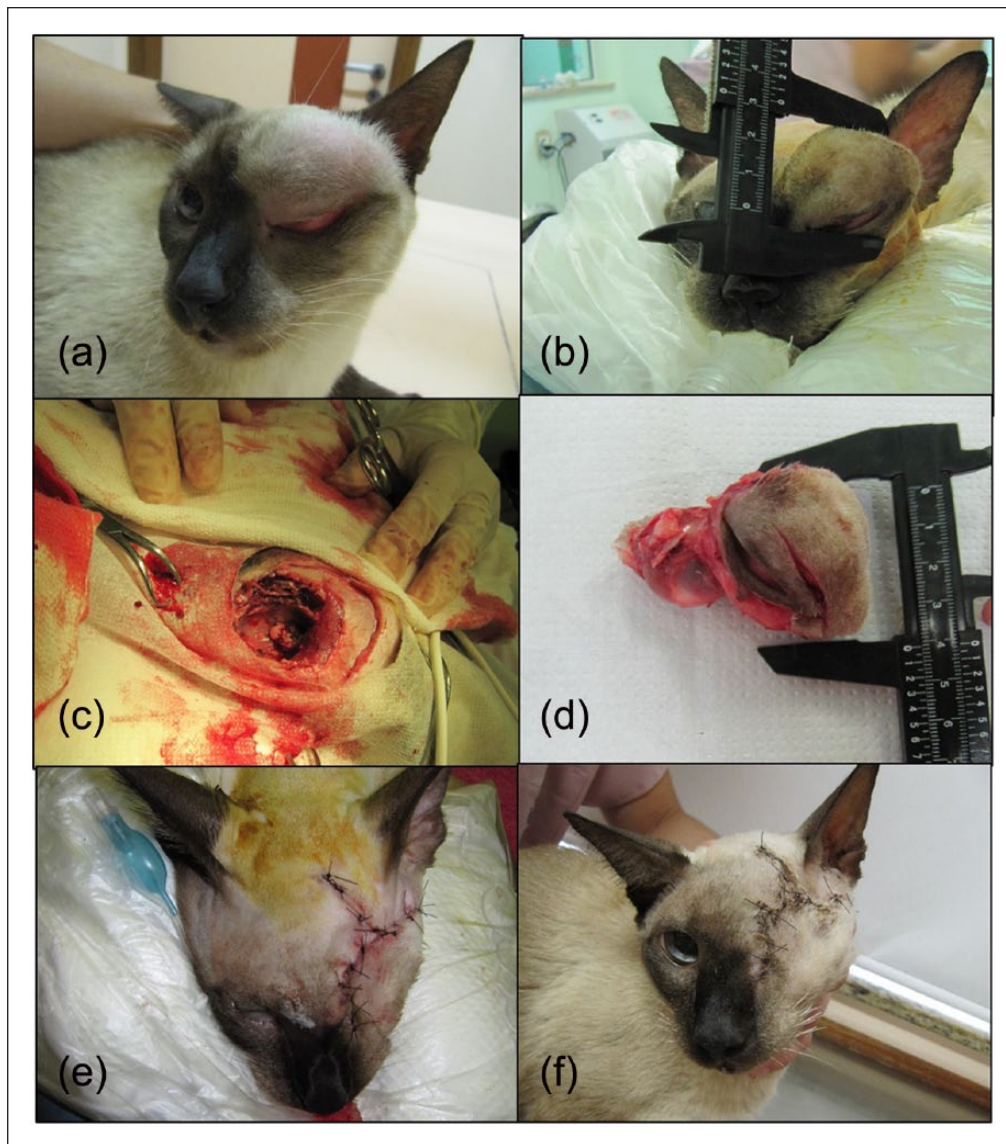


Figure 1 Siamese cat with an orbital osteoma. (a) A left periorbital mass that had a bony consistency. (b) The cat was anesthetized for orbitectomy. The mass was well-circumscribed and measured 3.2 cm in diameter. (c) Surgical defect after mass removal. (d) The eye was removed together with the osteoma. The left eye was localized caudal to the osteoma. (e) Closure of the surgical defect. (f) The cat 10 days postoperatively. The wound healed completely

The cat was positioned in ventral recumbency. The tumor was removed intact and surrounded by at least a 1 cm margin of normal tissue. It was a circular, well-defined mineral mass measuring 3.2 cm in diameter at the rostral aspect of the left orbit. An osteotomy of frontal bone combined with an osteotomy of maxilla and zygomatic bone were performed using an osteotome and mallet. Bony margins of the orbit were removed en bloc with the eye and structures within the orbit. Craniectomy was not necessary. The tumor did not extend into the oral cavity. The surgical defect was closed by two single-pedicle advancement flaps (dorsum of head and cheek) and apposition of subcutaneous tissues and skin. There were no postsurgical complications.

Histopathologic examination revealed an osteoma. Microscopically, the lump was ovoid and well-delineated from surrounding dermal connective tissue. The lesion was composed of numerous trabeculae consisting of both woven and lamellar bone, osteocytes of normal appearance being present in lacunae within the osseous matrix. Clear surgical margins were seen on all sections examined.

Amoxicillin (Amoxicilin; Medley) 15 mg/kg orally q12h for 10 days; dipyron 25 mg/kg orally q12h for 3 days; and tramadol (Dorless V; Agener) 2 mg/kg orally q12h for 7 days, were prescribed, and an Elizabethan collar was recommended. One week after surgery, the creatinine level was the same as before treatment. The

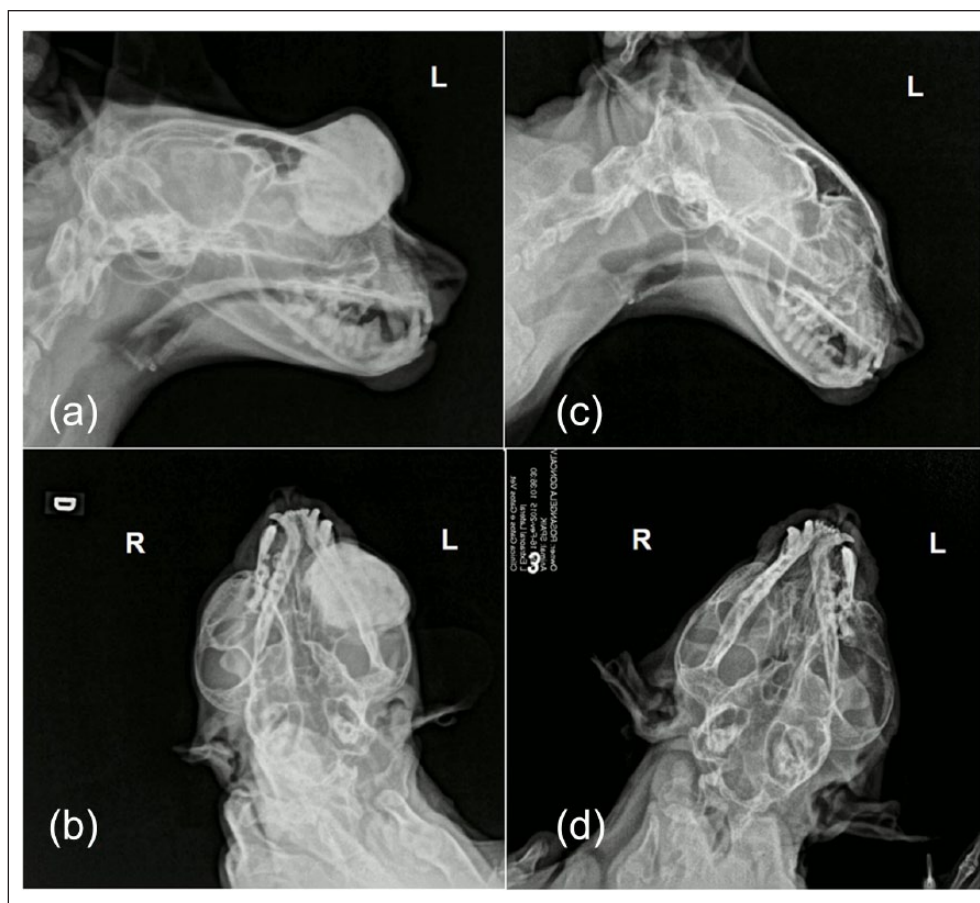


Figure 2 Radiographic features in the cat submitted to orbitectomy. (a) Lateral and (b) ventrodorsal radiographs before surgery. The mass was a well-circumscribed compact bone formation without destruction. Ten day postoperative (c) lateral and (d) ventrodorsal radiographs. The mass was removed completely

cat returned to normal appetite and normal activity 15 days after surgery. Six months after surgery, there were no gross signs of recurrence

Discussion

Six percent of all primary bone tumors commonly affect the skull of dogs and cats. They develop from intramembranous bone. Most are malignant.^{1,2,5,7} Sarcomas are the most common periorbital tumor in companion animals.² In this case, diagnosis was osteoma. Few cases of osteoma have been described in cats and they are rarely identified in the orbit.^{2,8} The most commonly affected bone is the mandible.⁸

Diagnosis for orbital osteoma is based on clinical signs (usually not painful on palpation), radiographic features (well-circumscribed, dense bony projections) and histological diagnosis (similar to reactive bone).⁴ The cat did not show pain of palpation, but it was anorexic. It is possible that the osteoma was causing discomfort while eating. Fifty days after surgery, appetite became normal.

Radiographic features were the same as reported in the literature.⁸ Orbital osteoma is a well-circumscribed,

dense bony projection. It is a compact bone formation without destruction and with continuous growth at a slow rate.⁸

Orbitectomy is a painful surgical procedure. Effective pain management generally involves a balanced or multimodal strategy using several classes of pain-modifying medications. Opioids are the most effective drug class for managing acute pain.⁹ The cat received injectable tramadol postoperatively. Tramadol produces good postoperative analgesia in cats.¹⁰ A fentanyl patch was the better option for this case; however, it was not available to be used in this cat. Fentanyl patches provide long-lasting analgesia and can be placed prior to surgery in order to be effective postoperatively. The majority of conditions that cause pain have an inflammatory component. Non-steroidal anti-inflammatory drugs (NSAIDs) are a mainstay for the management of chronic pain, as well as for perioperative use. NSAIDs are avoided in cats with renal dysfunction because an important side effect associated with NSAIDs is nephrotoxicity.⁹ The cat had a mildly elevated creatinine level, so NSAIDs were avoided.

Because animals are non-verbal and cannot self-report the presence of pain, appropriate pain management is required and includes several classes of pain-modifying medications.⁹

Treatment is surgical excision, which is usually curative. If the tumor remains static and asymptomatic it may be possible to consider no treatment but monitor it closely. Orbital surgery has the potential to be challenging owing to the complex anatomy, difficult exposure and a tendency to bleed.⁶ In this case, the osteoma was removed without difficulty and complication. The mass had clean surgical margins. Surgical complications like blindness in the contralateral eye, neurological signs, cardiopulmonary arrest, facial swelling, hemorrhage and dehiscence may develop after orbitectomy.² In this case, no postsurgical signs were observed. The osteoma was completely removed without complications and the cat's quality of life was subjectively better than before surgery.

Conclusions

Early intervention is recommended for cats with osteoma, as surgical excision of the mass may be curative. Advanced tumors can result in an unacceptable quality of life. Subtotal orbitectomy was a successful treatment in this case, even though the mass was advanced (3.2 cm in diameter). Surgery was curative. Orbitectomy is indicated to treat orbital osteoma in the cat.

Funding The authors received no financial support for the research, authorship, and/or publication of this article.

Conflict of interest The authors declared no potential conflicts of interest with respect to the research, authorship, and/or publication of this article.

References

- 1 Gilger BC, McLaughlin SA, Whitley RD, et al. **Orbital neoplasms in cats: 21 cases (1974–1990).** *J Am Vet Med Assoc* 1992; 201: 1083–1086.
- 2 O'Brien MG, Withrow SJ, Straw RC, et al. **Total and partial orbitectomy for the treatment of periorbital tumors in 24 dogs and 6 cats: a retrospective study.** *Vet Surg* 1996; 25: 471–479.
- 3 Lorimier LP. **Primary orbital melanoma without ocular involvement in a Balinese cat.** *Can Vet J* 2006; 47: 225–228.
- 4 Boston SE. **Craniectomy and orbitectomy in dogs and cats.** *Can Vet J* 2010; 51: 537–540.
- 5 Bell CM, Schwarz T and Dubielzig RR. **Diagnostic features of feline restrictive orbital myofibroblastic sarcoma.** *Vet Pathol* 2011; 48: 742–750.
- 6 Cho J. **Surgery of the globe and orbit.** *Top Companion Anim Med* 2008; 23: 23–37.
- 7 Groskopf BS, Dubielzig RR and Beaumont SL. **Orbital extraskelatal osteosarcoma following enucleation in a cat: a case report.** *Vet Ophthalmol* 2010; 13: 179–183.
- 8 Fiani N, Arzi B, Johnson EG, et al. **Osteoma of the oral and maxillofacial regions in cats: 7 cases (1999–2009).** *J Am Vet Med Assoc* 2011; 238: 1470–1475.
- 9 Epstein EM, Rodan I, Griffenhagen G, et al. **2015 AAHA/AAFP pain management guidelines for dogs and cats.** *J Feline Surg Med* 2015; 17: 251–272.
- 10 Evangelista MC, Silva RA, Cardozo LB, et al. **Comparison of preoperative tramadol and pethidine on postoperative pain in cats undergoing ovariohysterectomy.** *BMC Vet Res* 2014; 10: 252–259.