



## Medical management of gastrinoma in a cat

Authors: Lane, Michael, Larson, Jeanne, Hecht, Silke, and Tolbert, M Katherine

Source: Journal of Feline Medicine and Surgery Open Reports, 2(1)

Published By: SAGE Publishing

URL: <https://doi.org/10.1177/2055116916646389>

---

BioOne Complete ([complete.BioOne.org](http://complete.BioOne.org)) is a full-text database of 200 subscribed and open-access titles in the biological, ecological, and environmental sciences published by nonprofit societies, associations, museums, institutions, and presses.

Your use of this PDF, the BioOne Complete website, and all posted and associated content indicates your acceptance of BioOne's Terms of Use, available at [www.bioone.org/terms-of-use](http://www.bioone.org/terms-of-use).

Usage of BioOne Complete content is strictly limited to personal, educational, and non - commercial use. Commercial inquiries or rights and permissions requests should be directed to the individual publisher as copyright holder.

---

BioOne sees sustainable scholarly publishing as an inherently collaborative enterprise connecting authors, nonprofit publishers, academic institutions, research libraries, and research funders in the common goal of maximizing access to critical research.



# Medical management of gastrinoma in a cat

Michael Lane, Jeanne Larson, Silke Hecht and M Katherine Tolbert

*Journal of Feline Medicine and Surgery*  
*Open Reports*  
 1–7

© The Author(s) 2016  
 Reprints and permissions:  
[sagepub.co.uk/journalsPermissions.nav](http://sagepub.co.uk/journalsPermissions.nav)  
 DOI: 10.1177/2055116916646389  
[jfmsopenreports.com](http://jfmsopenreports.com)

This paper was handled and processed by the American Editorial Office (AAFP) for publication in JFMS Open Reports



## Abstract

**Case summary** A 7-year-old male castrated domestic short-haired cat was evaluated for a 4 week history of intermittent vomiting, ptyalism, lethargy and weight loss. Serum biochemistry revealed mild mixed hepatopathy. Abdominal ultrasonography identified multiple heterogeneous hepatic masses and a linear, hyperechoic focus with associated reverberation artifact in the wall of the stomach consistent with a gastric ulcer. Serum gastrin concentrations were markedly increased. Cytologic interpretation of a fine-needle aspirate of the hepatic masses was consistent with neuroendocrine neoplasia, and a diagnosis of gastrinoma was established. Deterioration of the cat's condition, despite at-home acid-suppressant therapy, led to hospitalization. The cat was initially stabilized with intravenous crystalloid fluid therapy, maropitant, pantoprazole and octreotide. A continuous radiotelemetric intragastric pH monitoring system was used to monitor the response of intragastric pH to therapy. Long-term therapy was continued with omeprazole (orally q12h), octreotide (subcutaneously q8h) and thrice-weekly toceranib administered orally. Toceranib therapy led to gastrointestinal upset and was discontinued. Gastric ulceration resolved within 8 weeks, and palliation of clinical signs was achieved for approximately 5 months.

**Relevance and novel information** Including this report, only six cases of feline gastrinoma have been reported in the veterinary literature. Little is known regarding non-surgical therapy, and octreotide has not been previously reported for medical management of feline gastrinoma. Results of intragastric pH monitoring and clinical improvement suggest that medical therapy using octreotide and proton pump inhibitors represents a novel therapeutic option for cats with gastrinoma where surgical excision is not feasible.

**Accepted:** 31 March 2016

## Case description

A 7-year-old male castrated domestic short-haired cat weighing 7.3 kg (14.6 lb) was presented to the University of Tennessee Small Animal Emergency Service for evaluation of chronic vomiting of non-digested food 30–60 mins after feeding. The cat reportedly showed consistent interest in food, but feeding led to ptyalism and vomiting. In addition, the cat had lost 0.45 kg (1 lb) of body weight in the prior month and did not have reported melena or change in stool consistency. A complete blood count was within reference intervals (RIs). Serum biochemistry abnormalities included increases in alkaline phosphatase at 86 IU/l (RI 13–71 IU/l), aspartate aminotransferase at 102 IU/l (RI 12–50 IU/l) and alanine aminotransferase at 234 IU/l (RI 32–110 IU/l). Abdominal ultrasound revealed a diffusely hyperechoic hepatic parenchyma with multiple heterogeneous, oval masses,

the largest of which measured approximately 2.2 cm × 3.5 cm and 1.4 cm × 1.1 cm, and were associated with the right liver. A linear, hyperechoic focus measuring approximately 0.8 cm in length was identified in the wall of the stomach near the pylorus and was characterized by indistinct wall layering, distal reverberation artifact and thickening of the gastric wall adjacent to the lesion

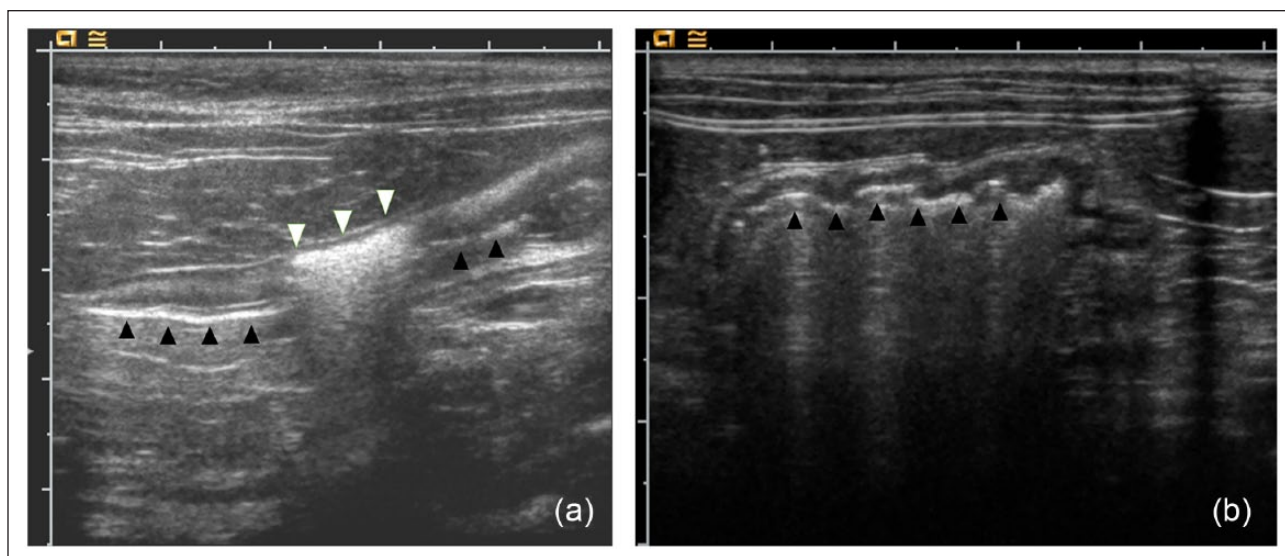
Department of Small Animal Clinical Sciences, College of Veterinary Medicine, University of Tennessee, Knoxville, TN, USA

### Corresponding author:

M Katherine Tolbert DVM, PhD, DACVIM, Department of Small Animal Clinical Sciences, College of Veterinary Medicine, University of Tennessee, 2407 River Drive, Knoxville, TN 37996, USA  
 Email: [mtolber2@utk.edu](mailto:mtolber2@utk.edu)



Creative Commons Non Commercial CC-BY-NC: This article is distributed under the terms of the Creative Commons Attribution-NonCommercial 3.0 License (<http://www.creativecommons.org/licenses/by-nc/3.0/>) which permits non-commercial use, reproduction and distribution of the work without further permission provided the original work is attributed as specified on the SAGE and Open Access pages (<https://us.sagepub.com/en-us/nam/open-access-at-sage>).



**Figure 1** Ultrasonographic images of the stomach of a cat with gastrinoma (a) before and (b) after 8 weeks of medical therapy with a proton pump inhibitor (q12h) and octreotide (q8h). The luminal aspect of the gastric wall is delineated by black arrowheads. The ulcer is indicated by white arrowheads and manifests as a linear hyperechoic defect in the gastric wall with reduced visibility of wall layers, distal reverberation artifact and mild thickening of the adjacent normal gastric wall

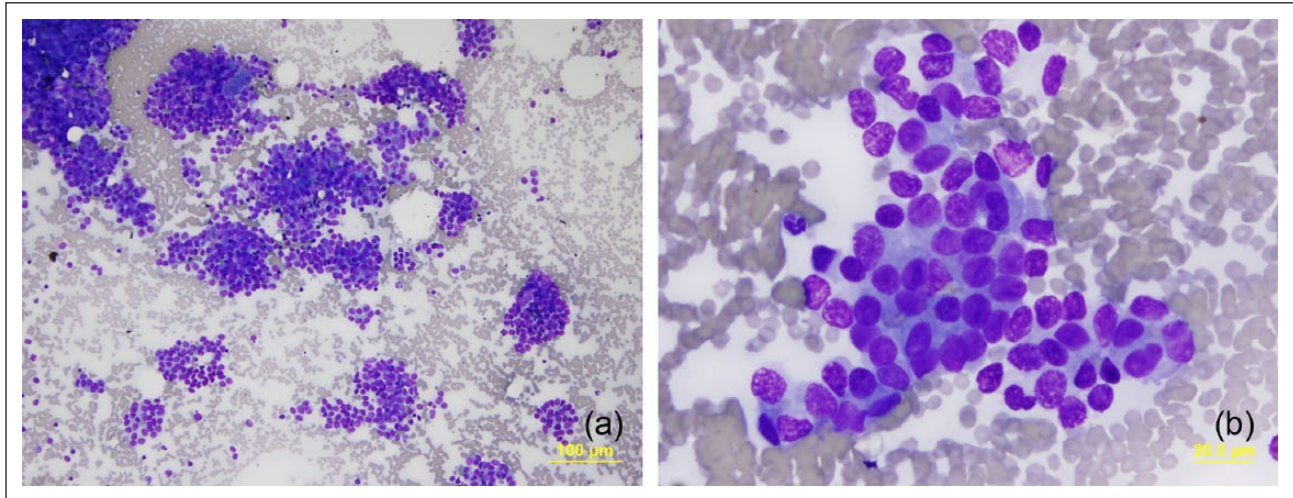
(Figure 1). Findings were most consistent with a gastric ulcer,<sup>1</sup> with suspected neoplastic lesions within the hepatic parenchyma. Sampling of the liver masses was recommended.

Owing to the presence of gastric ulceration, medications prescribed included sucralfate suspension (41 mg/kg [18.6 mg/lb] orally q8h) for 30 days and the proton pump inhibitor (PPI) omeprazole (0.68 mg/kg [0.3 mg/lb] orally q24h) for 30 days. One week later, a fine-needle aspirate of the hepatic mass was obtained under ultrasound guidance. The aspirate sample was poor in cellularity and was suggestive of hepatic lipidosis. The cat appeared to be improving at home and had a normal appetite, and therefore it was treated as an outpatient with continued administration of sucralfate and omeprazole. Recommendations were made to the owners for either repeated fine-needle aspiration or surgical biopsy of the liver masses. Although the cat experienced intermittent inappetence in the days immediately following re-examination, its condition reportedly improved; therefore, the owners discontinued all medications within 10 days.

Three weeks later, following recurrence of vomiting, inappetence and severe lethargy, the owners resumed administration of the medications and elected to pursue further evaluation. Abdominal ultrasonography revealed several new masses throughout the liver. The previously described liver masses were also found to have increased in size. Little normal hepatic parenchyma was observed. The previously described gastric ulcer was unchanged with no evidence of healing. Cytologic evaluation of fine-needle aspirates from several of the

hepatic masses revealed moderately sized epithelial cells present in clusters, packets and occasional linear or acinar-like arrangements on a background of blood. The cells, which were cuboidal to low columnar with a round nucleus, stippled chromatin and a small amount of light blue cytoplasm, were consistent with a neuroendocrine tumor (Figure 2). Owing to the persistent gastric ulcer, the cat was prescribed omeprazole at an increased frequency (0.68 mg/kg [0.31 mg/lb] orally q12h). Given the suspicion of a metastatic neuroendocrine tumor and the presence of non-healing gastric ulceration, serum was obtained 3 days later for measurement of gastrin concentrations, which were found to be markedly increased at 491 ng/l (RI <10–39.5 ng/l).<sup>2</sup> Although administration of omeprazole is associated with a subsequent increase in gastrin levels, the marked increase in gastrin concentrations in this case far exceeded those typically seen in dogs receiving omeprazole.<sup>3</sup> In addition, gastrin concentrations were markedly increased compared with values reported in normal cats and cats with hypergastrinemia secondary to severe azotemia.<sup>4</sup> Hypergastrinemia, the presence of a gastric ulcer, and documentation of multifocal neuroendocrine masses in the liver led to the presumptive diagnosis of gastrinoma (Zollinger–Ellison syndrome), though a pancreatic mass could not be identified on ultrasound.

Further deterioration in the cat's condition necessitated hospitalization with intravenous (IV) crystalloid therapy, pantoprazole (1 mg/kg [0.45 mg/lb] IV q12h), maropitant (1 mg/kg [0.45 mg/lb] IV q24h) and somatostatin analog (octreotide) therapy (2 µg/kg [0.9 mg/lb] SC q8h for 2 doses, 4 µg/kg [1.8 µg/lb] for two doses and



**Figure 2** Photomicrographs of smear preparations from fine-needle aspiration of metastatic lesions in the liver of a cat with gastrinoma at (a)  $\times 100$  and (b)  $\times 500$  magnification. Cellularity is high, consisting mostly of moderately sized epithelial cells that are present in clusters, packets and occasional linear or acinar-like arrangements, on a background of blood and a few free nuclei from ruptured cells. The cells are cuboidal to low columnar, with a round nucleus, stippled chromatin and a small amount of light blue cytoplasm. They are fairly uniform in size, with occasional cells having a larger nucleus. No hepatocytes are noted.

10  $\mu\text{g}/\text{kg}$  [4.5  $\mu\text{g}/\text{lb}$ ] q8h thereafter). In addition, 48 h continuous gastric pH monitoring was performed to evaluate the cat's intragastric pH response to therapy for severe hypergastrinemia.

A pH monitoring capsule (Bravo pH monitoring system; Given Imaging) was administered orally using a syringe-style pet piller (JorVet Pet Piller; Jorgensen Labs). The cat was hospitalized in the intensive care unit. Its condition improved rapidly with resolution of ptyalism within 2 h of hospitalization and return of a consistent appetite within 15 h. Radiographs obtained during day 2 of hospitalization confirmed that the capsule remained in the stomach.

Results of pH monitoring on day 1 indicated pH  $\geq 3.0$  was achieved for 89% of the day,  $\geq 4.0$  for 57% of the day,  $\geq 5.0$  for 46% of the day and  $\geq 6.0$  for 31% of the day. During day 2, a pH  $\geq 3.0$  was achieved for 100% of the day,  $\geq 4.0$  for 99% of the day,  $\geq 5.0$  for 85% of the day and  $\geq 6.0$  for 17% of the day (Figures 3 and 4). These values were consistent with our  $\geq 3.0$  pH goal for treatment of gastroduodenal ulcerations. Intravenous pantoprazole was discontinued, and oral omeprazole was prescribed once the cat was eating readily. The cat was discharged following 48 h pH monitoring and was reported to have a normal appetite and energy level at home. Omeprazole (1 mg/kg [0.45 mg/lb] orally q12h) and octreotide (10  $\mu\text{g}/\text{kg}$  [4.5  $\mu\text{g}/\text{lb}$ ] SC q8h) were prescribed indefinitely. Continued therapy with octreotide and omeprazole resulted in complete palliation of clinical signs. In addition, the original site at which ultrasonographic findings were consistent with gastric ulceration was repeatedly identified by the original ultrasonographer, and

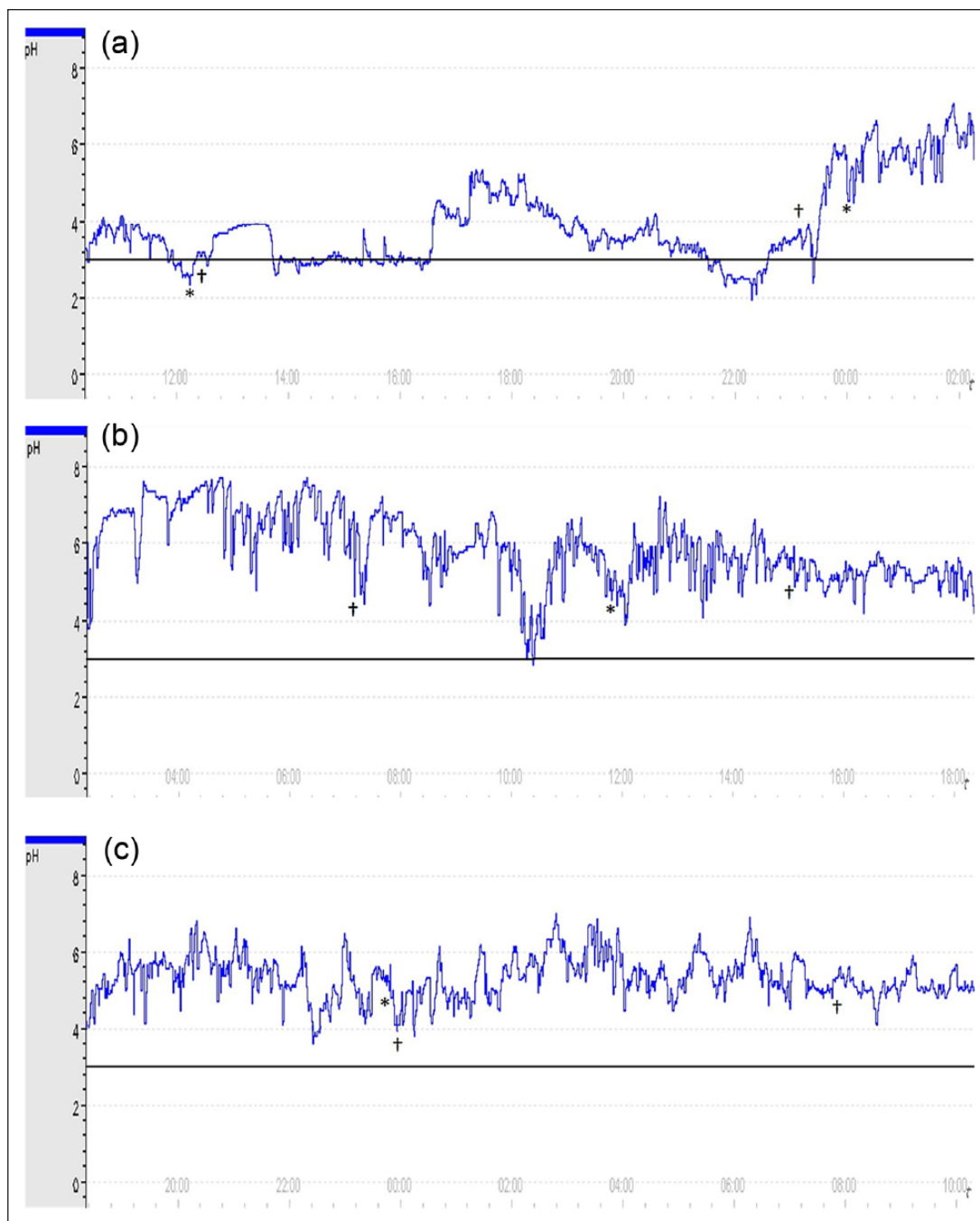
abnormalities were improved within 1 week. Complete resolution of the ulcer was seen within 8 weeks (Figure 1b). Owing to the persistent growth of the hepatic masses on subsequent ultrasonographic imaging, therapy with toceranib was pursued (2.38 mg/kg [1.1 mg/lb] orally q48h). Toceranib was discontinued after 1.5 months because of anorexia, despite a reduction in dosing frequency (2.38 mg/kg [1.1 mg/lb] three times weekly). Overall, clinical signs were well controlled for 5 months (7 months from the time of initial presentation), when acute recurrence of nausea, poor appetite and lethargy led to a decision by the owners to euthanize the cat. A necropsy was not performed.

## Discussion

Gastrinomas are rare, gastrin-secreting, non-beta islet cell tumors of neuroendocrine origin; these tumors lead to hypergastrinemia, gastric hyperacidity and, consequently, peptic ulceration. The overall incidence of gastrinoma is unknown. In people, the incidence is estimated to be between 1 and 3 per million per year.<sup>5</sup> To our knowledge, only 34 canine cases and six feline cases, including this one, have been reported in the veterinary literature.<sup>6,7</sup>

For dogs and cats diagnosed with gastrinoma, surgical debulking is recommended in an attempt to reduce gastrin secretion, although, as with the cat reported here, up to 70% of cases will have visible metastases at the time of initial diagnosis.<sup>8</sup> Survival times for dogs and cats with gastrinoma are typically  $<8$  months,<sup>8</sup> though survival for up to 18 months was reported in cats with gastrinoma using a combination of surgical debulking

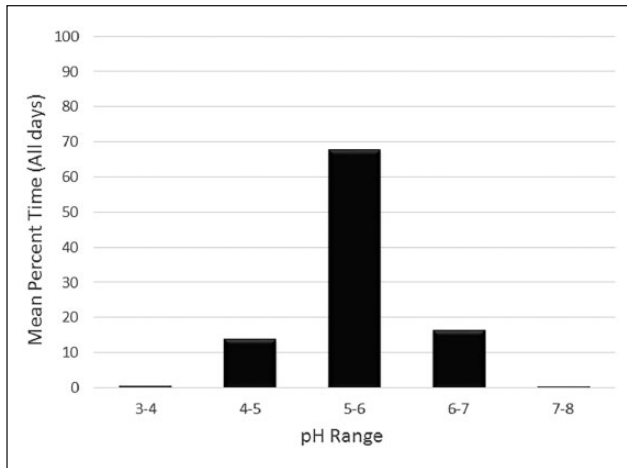




**Figure 3** Gastric pH in a cat with gastrinoma during the (a) first 16 h, (b) second 16 h and (c) third 16 h of hospitalization for treatment of gastroduodenal ulceration. Asterisks (\*) represent time of administration of pantoprazole, and daggers (†) represent administration of octreotide. The target pH ( $\geq 3.0$ ) is indicated by the horizontal solid line; the target was achieved for 89% of the first 24 h and for 100% of the second 24 h. Note that the cat received 3 days of at-home, twice-daily omeprazole administration prior to hospitalization and intragastric pH monitoring

and gastroprotectants.<sup>9</sup> Surgical excision was not recommended for the cat in this report owing to multifocal hepatic irregularities presumed to represent significant metastatic disease. Given the severity of clinical signs associated with the condition, medical therapy was attempted.

Somatostatin analogs, considered a cornerstone of medical treatment in people with gastrinoma,<sup>5,10</sup> have been described for use in diagnosis and treatment of gastrinoma in dogs.<sup>7,11</sup> This is the first report to describe the use of somatostatin analog therapy for the treatment of feline gastrinoma. Early studies indicated that



**Figure 4** Mean time (%) that gastric pH was within each pH range throughout a 48 h monitoring period in a cat with a naturally occurring gastric ulceration treated with pantoprazole (q12h) and octreotide (q8h). pH <3.0 did not occur during the monitoring period

somatostatin analogs have a dose-dependent effect on inhibition of gastric acid secretion in healthy cats;<sup>12</sup> however, individual analogues have different specificities for somatostatin receptors (SSTRs) involved in the inhibition of insulin, growth hormone, glucagon and gastrin.<sup>12</sup> While expression of specific SSTRs in feline gastrinoma remains to be elucidated, a previous study suggested that SSTR2 mediates inhibition of gastrin and histamine secretion in people, dogs and rats, whereas SSTR3 and SSTR5 agonists have no significant effects on gastrin secretion.<sup>13</sup> Recently, the somatostatin analogs octreotide and pasireotide were evaluated for use in cats with hypersomatotropism.<sup>14,15</sup> Octreotide has high affinity for SSTR2 and SSTR5, and is reported to have antitumor activity against neuroendocrine tumors in people.<sup>16</sup> Octreotide administration (5 µg/kg [2.27 µg/lb]) IV bolus) resulted in lowered plasma growth hormone, adrenocorticotrophic hormone and cortisol concentrations, and a slight increase in plasma glucose.<sup>14</sup> Pasireotide, which has a higher binding affinity for SSTR1, SSTR3 and SSTR5, significantly decreased insulin-like growth factor-1 concentrations (when dosed at 0.03 mg/kg [0.01 mg/lb] SC q12h).<sup>15</sup> Neither somatostatin analog has been evaluated for use in cats with gastrinoma, but previous studies in dogs and other species suggest that octreotide may have greater specificity than pasireotide to antagonize gastrin secretion in cats.<sup>13</sup> Gastrointestinal disturbances have been reported in people being treated with octreotide,<sup>10</sup> and mild diarrhea has been reported in a small proportion of cats treated with pasireotide.<sup>15</sup> However, the cat described herein displayed no detectable ill effects, despite prolonged dosage administration at 10 µg/kg q8h. Further dose escalation was not attempted.

Toceranib, a tyrosine kinase inhibitor, has also not been evaluated for use in feline gastrinoma. Given reports of clinical benefit in dogs with neuroendocrine tumors,<sup>17</sup> and reports in people indicating that tyrosine kinase inhibitors improved objective response rate, progression-free survival and overall survival in patients with advanced neuroendocrine tumors, this therapy was pursued.<sup>18</sup> Unfortunately, the cat in this report developed persistent anorexia, despite a dose reduction while being treated with toceranib. Several recent reports have identified anorexia as the most common side effect seen in tumor-bearing cats treated with toceranib, although in most cases anorexia appears to be mild and can be ameliorated with a temporary drug cessation or dose reduction.<sup>19,20</sup>

Medical management of gastrinoma also requires addressing the patient's gastric hyperacidity.<sup>21</sup> A continuous intragastric telemetric pH monitoring capsule was used in this case to monitor the response of the cat's intragastric pH to octreotide and acid suppressant therapy. Use of the pH monitoring capsule has been previously described in studies evaluating the effect of gastric acid suppressants in healthy dogs and cats.<sup>22–25</sup> No published studies have used this technology in a cat with an acid-related disease. The pH monitoring capsule is designed to be placed under endoscopic guidance using a preassembled catheter delivery device. Traditionally, a location is identified for placement, and then an external suction device is applied to allow for a spring-loaded pin to secure the capsule to the gastroesophageal mucosa. In this study, we administered a pH monitoring capsule orally to the cat to continuously monitor the response of gastric pH to the prescribed therapies. The ability to administer the capsule orally will enable less invasive therapeutic monitoring of gastric pH in cats with gastric erosions and ulcerative disease. Furthermore, allowing for natural passage of the capsule might aid in prevention of complications associated with endoscopic removal of the capsule.<sup>26</sup>

Gastric pH is closely associated with acid-related mucosal injury and healing in people. In vitro and in vivo findings in people with peptic ulcers have suggested that an acidic environment activates plasminogen and inhibits adequate platelet aggregation and fibrin clot formation, leading to delayed healing.<sup>27,28</sup> It is believed that plasmin-mediated fibrinolysis and acid-dependent proteases lead to clot degradation and subsequent re-bleeding. For medical treatment of esophageal mucosal erosion and duodenal ulceration in people, optimal healing has been shown to occur when a gastric pH of  $\geq 3.0$  is maintained for approximately 75% of the day.<sup>29,30</sup> This goal has been accepted in human medicine as the minimal target for acid suppression in patients with gastric acid-induced tissue injury. More aggressive pH goals have been established to promote hemostasis and healing of bleeding

peptic ulcers.<sup>31,32</sup> Thus, acid-suppressant therapy is recommended for the treatment of people with acid-related disorders and, in particular, patients with peptic ulcers.<sup>28</sup> Ideal intragastric conditions for hemostasis in cats might be similar to those of people; however, it is unknown whether therapeutic goals established for people can be extrapolated to other species. Because no intragastric pH goals exist for the treatment of gastrointestinal ulceration in cats, we chose a target intragastric pH of  $\geq 3.0$  for  $\geq 75\%$  of the day at the onset of therapy. This goal was exceeded on both days during which intragastric pH was monitored. Because PPI and octreotide therapy were administered simultaneously during the period of intragastric pH monitoring, it was not possible to observe the impact of each individual therapy on intragastric pH in this case.

## Conclusions

Owing to the paucity of feline gastrinoma cases in the veterinary literature, little is known regarding the most appropriate management of the condition in cats, particularly in cases that are not amenable to surgical excision. Preliminary evidence from this case suggests that medical management using octreotide therapy (q8h), as well as PPI therapy (q12h), is feasible and provides palliation of clinical signs and peptic ulceration associated with gastrinoma in cats. However, because of the simultaneous administration of these therapies, it is unclear whether octreotide provides a clinical advantage over PPI therapy alone. This case serves as a platform for further study of the most effective medical therapy for cats with gastrinoma and other causes of acid-related tissue injury.

**Acknowledgements** We thank Dr Deanna Schaefer for her assistance in the diagnosis of this case.

**Conflict of interest** The authors declared no potential conflicts of interest with respect to the research, authorship, and/or publication of this article.

**Funding** The authors received no financial support for the research, authorship, and/or publication of this article.

## References

- Penninck D, Matz M and Tidwell A. **Ultrasonography of gastric ulceration in the dog.** *Vet Radiol Ultrasound* 1997; 38: 308–312.
- Ruhnke I, Suchodolski JS, Schwierk VM, et al. **Analytical validation of a commercially available immunoassay for serum gastrin concentration in cats.** *J Vet Intern Med* 2010; 24: 753.
- Parente NL, Bari Olivier N, Refsal KR, et al. **Serum concentrations of gastrin after famotidine and omeprazole administration to dogs.** *J Vet Intern Med* 2014; 28: 1465–1470.
- McLeland SM, Lunn KF, Duncan CG, et al. **Relationship among serum creatinine, serum gastrin, calcium-phosphorus product, and uremic gastropathy in cats with chronic kidney disease.** *J Vet Intern Med* 2014; 28: 827–837.
- Li ML and Norton JA. **Gastrinoma.** *Curr Treat Options Oncol* 2001; 2: 337–346.
- Ward CR. **Gastrointestinal endocrine disease.** In: Ettinger SJ and Feldman EC (eds). *Textbook of veterinary internal medicine*. 7th ed. St Louis, MO: Elsevier Saunders, 2010, pp 1857–1864.
- Kim S, Hosoya K, Takagi S, et al. **Treatment of gastrin-secreting tumor with sustained-release octreotide acetate in a dog.** *J Am Anim Hosp Assoc* 2015; 51: 407–412.
- Bailey DB and Paige RL. **Tumors of the endocrine system.** In: Withrow SJ, Vail D and Page R (eds). *Withrow and MacEwen's small animal clinical oncology*. 4th ed. St Louis, MO: Elsevier Saunders, 2007, pp 583–609.
- Liptak JM, Hunt GB, Barrs VRD, et al. **Gastroduodenal ulceration in cats: eight cases and a review of the literature.** *J Feline Med Surg* 2002; 4: 27–42.
- Shojamanesh H, Gibril F, Louie A, et al. **Prospective study of the antitumor efficacy of long-term octreotide treatment in patients with progressive metastatic gastrinoma.** *Cancer* 2002; 94: 331–343.
- Altschul M, Simpson KW, Dykes NL, et al. **Evaluation of somatostatin analogues for the detection and treatment of gastrinoma in a dog.** *J Small Anim Pract* 1997; 38: 286–291.
- Hirst BH, Conlon M, Coy DH, et al. **Comparison of the gastric exocrine inhibitory activities and plasma kinetics of somatostatin-28 and somatostatin-14 in cats.** *Regul Pept* 1982; 4: 227–237.
- Zaki M, Harrington L, McCuen R, et al. **Somatostatin receptor subtype 2 mediates inhibition of gastrin and histamine secretion from human, dog, and rat antrum.** *Gastroenterology* 1996; 111: 919–924.
- Slingerland LI, Voorhout G, Rijnberk A, et al. **Growth hormone excess and the effect of octreotide in cats with diabetes mellitus.** *Domest Anim Endocrinol* 2008; 35: 352–361.
- Scudder CJ, Gostelow R, Forcada Y, et al. **Pasireotide for the medical management of feline hypersomatotropism.** *J Vet Intern Med* 2015; 29: 1074–1080.
- Yamaguchi M, Yamada Y, Hosokawa Y, et al. **Long-term suppressive effect of octreotide on progression of metastatic gastrinoma with multiple endocrine neoplasia type 1: seven-year follow up.** *Intern Med* 2010; 49: 1557–1563.
- London C, Mathie T, Stingle N, et al. **Preliminary evidence for biologic activity of toceranib phosphate (Palladia) in solid tumours.** *Vet Comp Oncol* 2012; 10: 194–205.
- Raymond E, Dahan L, Raoul JL, et al. **Sunitinib malate for the treatment of pancreatic neuroendocrine tumors.** *N Engl J Med* 2011; 364: 501–513.
- Wiles V, Hohenhaus A, Lamb K, et al. **Retrospective evaluation of toceranib phosphate (Palladia) in cats with oral squamous cell carcinoma.** *J Feline Med Surg*. Epub ahead of print 11 January 2016. DOI: 1098612X15622237.
- Holtermann N, Kiupel M and Hirschberger J. **The tyrosine kinase inhibitor toceranib in feline injection site sarcoma: efficacy and side effects.** *Vet Comp Oncol*. Epub ahead of print 14 January 2016. DOI: 10.1111/vco.12207.

- 21 Brooks D and Watson GL. **Omeprazole in a dog with gastrinoma.** *J Vet Intern Med* 1997; 11: 379–381.
- 22 Tolbert MK, Bissett S, King A, et al. **Efficacy of oral famotidine and 2 omeprazole formulations for the control of intragastric pH in dogs.** *J Vet Intern Med* 2011; 25: 47–54.
- 23 Parkinson S, Tolbert MK, Messenger K, et al. **Evaluation of the effect of orally administered acid suppressants on intragastric pH in cats.** *J Vet Intern Med* 2015; 29: 104–112.
- 24 Tolbert MK, Odunayo A, Howell RS, et al. **Efficacy of intravenous administration of combined acid suppressants in healthy dogs.** *J Vet Intern Med* 2015; 29: 556–560.
- 25 Sutalo S, Ruetten M, Hartnack S, et al. **The effect of orally administered ranitidine and once-daily or twice-daily orally administered omeprazole on intragastric pH in cats.** *J Vet Intern Med* 2015; 29: 840–846.
- 26 Tolbert MK, Odunayo A and Craig LE. **Gastric perforation following endoscopic removal of a Bravo pH capsule in a cat.** *J Feline Med Surg* 2015; 17: 562–564.
- 27 Patchett SE, Enright H, Afdhal N, et al. **Clot lysis by gastric juice: an in vitro study.** *Gut* 1989; 30: 1704–1707.
- 28 van Rensburg CJ, Hartmann M, Thorpe A, et al. **Intragastric pH during continuous infusion with pantoprazole in patients with bleeding peptic ulcer.** *Am J Gastroenterol* 2003; 98: 2635–2641.
- 29 Bell NJ, Burget D, Howden CW, et al. **Appropriate acid suppression for the management of gastro-oesophageal reflux disease.** *Digestion* 1992; 51 Suppl 1: 59–67.
- 30 Burget DW, Chiverton SG and Hunt RH. **Is there an optimal degree of acid suppression for healing of duodenal ulcers? A model of the relationship between ulcer healing and acid suppression.** *Gastroenterology* 1990; 99: 345–351.
- 31 Nagita A, Amemoto K, Yoden A, et al. **Diurnal variation in intragastric pH in children with and without peptic ulcers.** *Pediatr Res* 1996; 40: 528–532.
- 32 van Rensburg CJ and Cheer S. **Pantoprazole for the treatment of peptic ulcer bleeding and prevention of rebleeding.** *Gastroenterology* 2012; 5: 51–60.