



## **Mycobacterial panniculitis caused by *Mycobacterium thermoresistibile* in a cat**

Authors: Vishkautsan, Polina, Reagan, Krystle L, Keel, M Kevin, and Sykes, Jane E

Source: Journal of Feline Medicine and Surgery Open Reports, 2(2)

Published By: SAGE Publishing

URL: <https://doi.org/10.1177/2055116916672786>

---

BioOne Complete ([complete.BioOne.org](https://complete.BioOne.org)) is a full-text database of 200 subscribed and open-access titles in the biological, ecological, and environmental sciences published by nonprofit societies, associations, museums, institutions, and presses.

Your use of this PDF, the BioOne Complete website, and all posted and associated content indicates your acceptance of BioOne's Terms of Use, available at [www.bioone.org/terms-of-use](https://www.bioone.org/terms-of-use).

Usage of BioOne Complete content is strictly limited to personal, educational, and non - commercial use. Commercial inquiries or rights and permissions requests should be directed to the individual publisher as copyright holder.

---

BioOne sees sustainable scholarly publishing as an inherently collaborative enterprise connecting authors, nonprofit publishers, academic institutions, research libraries, and research funders in the common goal of maximizing access to critical research.



# Mycobacterial panniculitis caused by *Mycobacterium thermoresistibile* in a cat

Polina Vishkautsan<sup>1</sup>, Krystle L Reagan<sup>1</sup>, M Kevin Keel<sup>2</sup> and Jane E Sykes<sup>3</sup>

Journal of Feline Medicine and Surgery  
Open Reports  
1–7

© The Author(s) 2016  
Reprints and permissions:  
sagepub.co.uk/journalsPermissions.nav  
DOI: 10.1177/2055116916672786  
jfmsopenreports.com

This paper was handled and processed by the American Editorial Office (AAFP) for publication in JFMS Open Reports



## Abstract

**Case summary** A domestic shorthair cat was evaluated for chronic, bilateral, ulcerative dermatitis affecting the inguinal region and lateral aspects of both pelvic limbs. Histopathologic examination of skin biopsies collected throughout the course of disease revealed chronic pyogranulomatous ulcerative dermatitis. Aerobic bacterial skin cultures yielded growth of a methicillin-resistant *Staphylococcus aureus* and *Corynebacterium amycolatum*. Upon referral the clinical findings were suggestive of a non-tuberculous *Mycobacterium* species infection. Previously obtained skin cultures failed to yield growth of mycobacterial organisms. A deep skin biopsy was collected and submitted for mycobacterial culture. At 5 weeks of incubation *Mycobacterium thermoresistibile* was isolated. In previous reports, *M thermoresistibile* has been isolated after 2–4 days of incubation, suggesting that this strain may have been a slower growing variant, or other factors (such as prior antimicrobial therapy) inhibited rapid growth of this isolate. The cat was hospitalized for intravenous antibiotic therapy, surgical debridement of wounds, vacuum-assisted wound closure therapy and reconstruction procedures. The wounds were ultimately primarily closed and the cat was discharged to the owner after 50 days of hospitalization. Seven months after hospitalization, the ulcerative skin lesions had healed.

**Relevance and novel information** To our knowledge, only two cases of *M thermoresistibile* panniculitis have been reported in cats. In the only detailed report of feline *M thermoresistibile* panniculitis, treatment was not attempted. The second case only reported detection of *M thermoresistibile* by PCR without a clinical description of the case. In our case report, severe chronic skin infection with *M thermoresistibile* was addressed using prolonged specific antibiotic therapy, surgical debridement and reconstructions, and treatment of secondary bacterial infections.

## Introduction

Mycobacteria that infect and cause disease in cats include tuberculous mycobacteria (*Mycobacterium bovis*, *Mycobacterium microti* and *Mycobacterium tuberculosis*); opportunistic, non-tuberculous mycobacteria (NTM), which include slow-growing species such as *Mycobacterium avium* and rapidly growing species such as *Mycobacterium fortuitum* and *Mycobacterium smegmatis*; and lepromatous mycobacteria, which are fastidious or unculturable species that cause nodular pyogranulomatous inflammatory lesions (feline leprosy syndrome).<sup>1</sup> The prevalence of mycobacterial infections in cats worldwide varies. Feline leprosy syndrome and NTM appear to be relatively common in Australia and parts of the USA, while tuberculosis (TB; due to *M bovis*), feline

leprosy syndrome and NTM are regularly diagnosed in New Zealand and the UK (*M bovis* and *M microti*).<sup>1</sup>

<sup>1</sup>Veterinary Medical Teaching Hospital, School of Veterinary Medicine, University of California-Davis, Davis, CA, USA

<sup>2</sup>Department of Pathology, Microbiology and Immunology, School of Veterinary Medicine, University of California-Davis, Davis, CA, USA

<sup>3</sup>Department of Medicine and Epidemiology, School of Veterinary Medicine, University of California-Davis, Davis, CA, USA

### Corresponding author:

Polina Vishkautsan DVM, DACVIM, Veterinary Medical Teaching Hospital, School of Veterinary Medicine, University of California-Davis, Davis CA 95616, USA  
Email: pvishkautsan@ucdavis.edu



Creative Commons Non Commercial CC-BY-NC: This article is distributed under the terms of the Creative Commons Attribution-NonCommercial 3.0 License (<http://www.creativecommons.org/licenses/by-nc/3.0/>) which permits non-commercial use, reproduction and distribution of the work without further permission provided the original work is attributed as specified on the SAGE and Open Access pages (<https://us.sagepub.com/en-us/nam/open-access-at-sage>).

Mycobacterial panniculitis refers to the clinical syndrome characterized by chronic infection of the subcutis and skin of cats by NTM. In cats, disease typically follows contamination of wounds. The bacterial species involved appear to have a predilection for adipose tissue.<sup>1</sup> Rapidly growing mycobacteria are a heterogeneous group of organisms that produce visible colonies on synthetic media within 5 days when cultured at room temperature. They are distributed ubiquitously in nature, and can be isolated commonly from soil and bodies of water.<sup>2</sup> Commonly isolated bacteria in this group include *M fortuitum*, *M smegmatis*, *Mycobacterium chelonae* and *Mycobacterium abscessus*.<sup>3</sup> *Mycobacterium thermoresistibile* is an NTM that is rarely reported in human and animal infections.<sup>2,4,5</sup> To our knowledge, only eight cases of human infection and three cases of feline infection have been reported in the literature.<sup>2,6-8</sup> Half of the infections in people occurred 3 months after surgery.<sup>2,4</sup> The three previously reported cases of *M thermoresistibile* infections in cats included two cats with skin infections,<sup>5,7</sup> and one with pneumonia.<sup>5,6</sup> One cat with *M thermoresistibile* panniculitis was reported from the Netherlands in 1985. That cat was euthanized immediately after diagnosis.<sup>7</sup> The other case of *M thermoresistibile* feline panniculitis was reported as part of a case series, where identification of infecting mycobacteria was performed using PCR on archived cytology slides. More details about this case were not described.<sup>5</sup> The cat with *M thermoresistibile* pneumonia was treated empirically with multiagent antibiotic therapy that consisted of doxycycline, rifampicin and clarithromycin.<sup>6</sup> That cat made a clinical recovery, despite the persistence of abnormal findings on thoracic radiographs, and antibiotics were discontinued after 1 year of treatment.<sup>6</sup> In humans with NTM, therapy of 3–24 months' duration is recommended.<sup>9</sup> Currently, no published recommendations exist for the treatment of *M thermoresistibile* infections for feline patients. Here we report a cat with severe mycobacterial panniculitis caused by *M thermoresistibile* and the approach to treatment of the infection. To our knowledge, this is the first report of this infection in companion animals in North America.

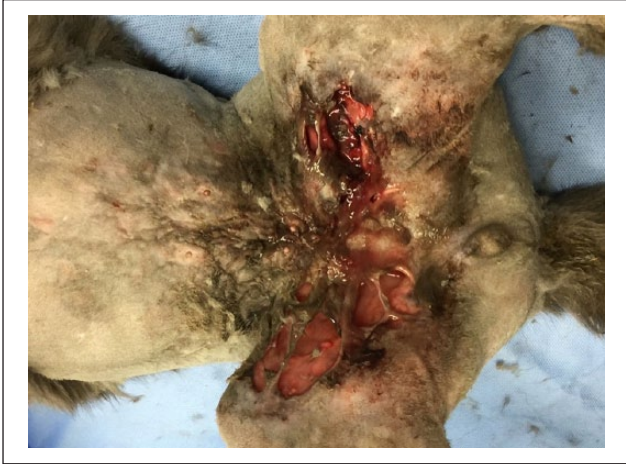## Case description

A 6-year-old, male, neutered, domestic shorthair cat was first evaluated by a referring veterinarian in January 2015 for an ulcerated skin wound in the inguinal area that was suspected to be a fight wound. The cat was treated with two injections of cefovecin over the subsequent 6 months. The ulcers waxed and waned in size and depth. In July 2015, a swab specimen was obtained from the affected skin. Aerobic and anaerobic bacterial culture yielded *Actinomyces* species, *Corynebacterium* species and *Pasteurella* species. Treatment with clavulanic

acid-amoxicillin (15 mg/kg PO q12h for 2 weeks) did not result in clinical improvement.

The cat was referred to the Dermatology Service at the University of California-Davis in August 2015 (7 months after original wound appearance). Histopathologic examination of a punch skin biopsy from the inguinal region at that time revealed severe, chronic, ulcerative, multifocal-to-coalescing, pyogranulomatous, deep dermatitis and panniculitis. No infectious organisms were evident on sections stained by hematoxylin and eosin stain, Brown and Brenn gram stain, Ziehl-Neelsen acid-fast stain, Grocott-Gomori's methenamine silver stain, periodic acid-Schiff stain and Giemsa stain. The cat was treated with marbofloxacin (4.6 mg/kg PO q24h) for suspected mycobacterial infection and oral amoxicillin (37 mg/kg PO q12h) for suspected secondary bacterial infection, pending the results of aerobic and anaerobic bacterial culture and susceptibility of a macerated skin biopsy specimen, fungal culture of the biopsy specimen and aerobic bacterial culture of a swab from a draining tract. Subsequently, culture of the skin biopsy yielded growth of small numbers of a *Corynebacterium* species, and culture of the draining tract yielded growth of *Corynebacterium amycolatum* and a methicillin-resistant *Staphylococcus aureus* (MRSA). The identity of *C amycolatum* was determined using matrix-assisted laser deionization-time of flight mass spectrometry and confirmed by 16S rRNA gene PCR and sequencing of the 574-base pair product. The *C amycolatum* isolate was susceptible to gentamicin, amikacin, chloramphenicol, clindamycin, doxycycline, erythromycin and trimethoprim sulfamethoxazole; had intermediate susceptibility to imipenem; and was resistant to amoxicillin-clavulanic acid and cefazolin. The minimum inhibitory concentration for enrofloxacin and marbofloxacin was  $\leq 0.25$   $\mu\text{g/ml}$  (no breakpoint available). The MRSA was susceptible to amikacin, chloramphenicol, clindamycin and trimethoprim sulfamethoxazole, and resistant to beta( $\beta$ )-lactams, fluoroquinolones, erythromycin and rifampin. Anaerobic and fungal culture yielded no growth. Given these results and continued clinical suspicion for mycobacterial panniculitis, fluoroquinolone treatment (marbofloxacin 4.6 mg/kg PO q24h) was recommended in combination with trimethoprim sulfamethoxazole (22 mg/kg PO q12h, dose listed for combined components of sulfamethoxazole and trimethoprim at a ratio of 5:1). An Elizabethan collar was placed to prevent the cat from licking its wounds.

The owner was not able to prevent the cat from removing the Elizabethan collar or to administer consistently the antibiotics at home, and so the cat was brought to the Internal Medicine Service for re-evaluation in October 2015 (9 months after original wound appearance and 2 months after the first evaluation by the Dermatology Service). At that time, the cat was admitted



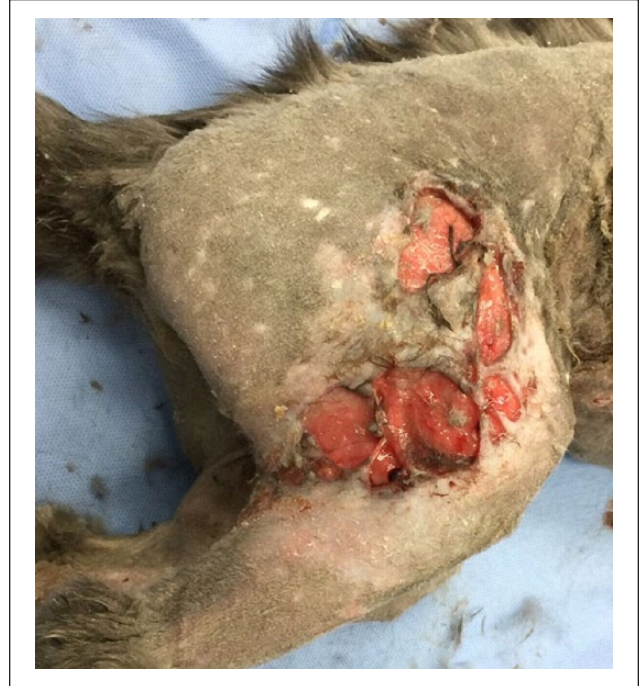**Figure 1** Inguinal region at time of hospitalization (October 2015) and prior to wound debridement

to the Veterinary Medical Teaching Hospital (VMTH) for wound care due to progression of lesions. On physical examination, the cat was alert and responsive and in good body condition (score 5/9) with normal vital signs. The cat was non-ambulatory and assessed to be painful in the pelvic limbs. Within the inguinal region there were deep skin wounds that were 25 cm × 15 cm. A large amount of purulent exudate discharged from the wounds. An ulcerated, 10 cm × 5 cm lesion with exudate and crusts was present on the lateral aspect of the right thigh.

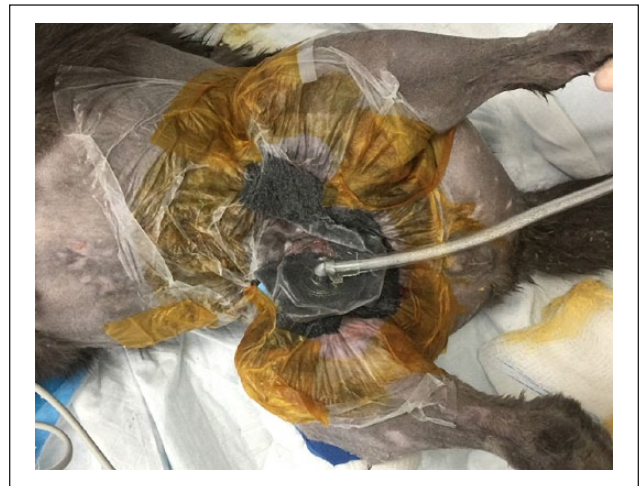A complete blood count showed mild normocytic normochromic anemia with a hematocrit of 26.3% (reference interval [RI] 30–50%). A serum chemistry panel showed mild hyperphosphatemia (7.1 mg/dl; RI 3.2–6.3 mg/dl), mild hyperglycemia of 198 mg/dl (RI 63–118 mg/dl) and a mildly increased creatine kinase concentration of 408 U/l (RI 73–260 U/l). The cat was negative for feline immunodeficiency virus antibodies and feline leukemia virus antigen (SNAP; IDEXX Laboratories). Aerobic bacterial blood cultures (two samples of 3 ml each, collected from each jugular vein) yielded no growth. Thoracic radiographs were unremarkable.

The cat's wounds were cleaned and debrided under general anesthesia (Figures 1 and 2). A vacuum-assisted wound closure device was used to treat the inguinal wounds, as previously described,<sup>10</sup> to assist with healing and skin apposition (Figure 3). The right lateral thigh wounds were debrided and treated with wet-to-dry bandaging. An esophagostomy tube was placed to facilitate administration of medications.

Histopathologic examination of a punch biopsy (6 mm in diameter) again revealed severe, chronic, multifocal, pyogranulomatous dermatitis and panniculitis and granulomatous lymphangitis (Figures 4 and 5). No infectious organisms were identified after staining with Ziehl–Neelsen acid-fast stain, Giemsa, Brown and Brenn gram stain and Grocott–Gomori's methenamine silver



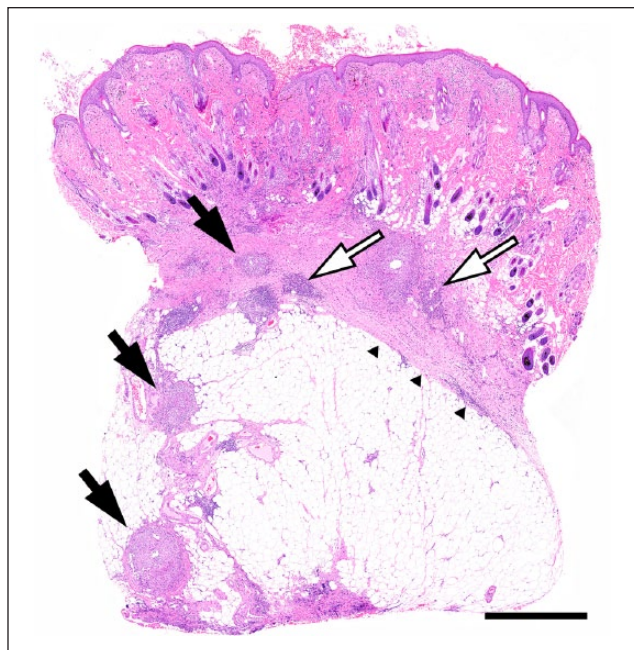
**Figure 2** Right lateral thigh at time of hospitalization (October 2015) and prior to wound debridement



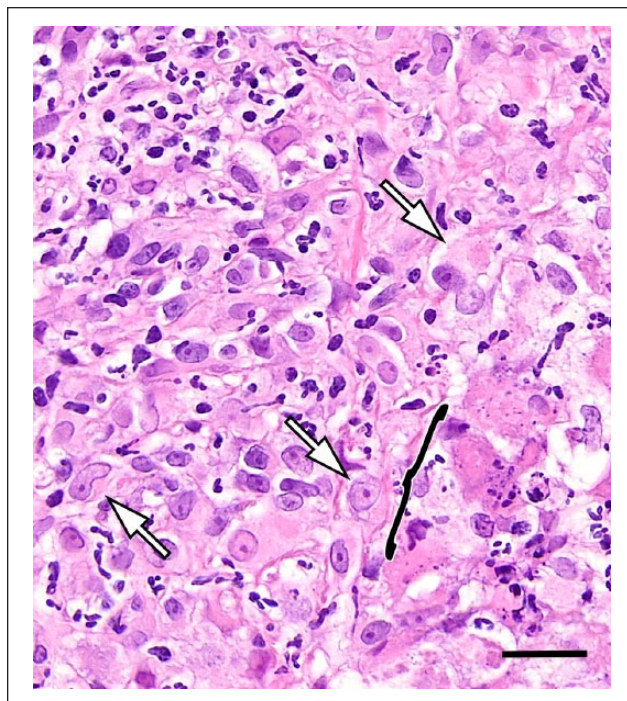
**Figure 3** Vacuum-assisted wound closure device applied after wound debridement (October 2015)

stain. Tissue PCR for a *M tuberculosis-bovis* complex (MTBC) organism was weakly positive after 40 cycles of PCR (cycle threshold [CT] values 36.57 for *Mycobacterium* species DNA and 20.91 for the housekeeping gene, with values <40 being positive). This assay detects the *rpoB* gene of *M bovis*, *Mycobacterium caprae*, *M tuberculosis* and *M microti*.

The skin biopsy specimens were also submitted to the VMTH microbiology laboratory for aerobic and anaerobic bacterial cultures and a fungal culture. A skin biopsy specimen was also submitted for mycobacterial culture



**Figure 4** Subgross image of histopathology slide prepared from one skin biopsy sample. Nodular foci of granulomatous inflammation (black arrows) are scattered throughout the deep aspect of the dermis and the panniculus adiposus. Some foci are more heavily populated by lymphocytes and plasma cells (open arrows). A band of immature connective tissue (arrowheads) subtends the deep aspect of the dermis, and is presumably a response to the chronic inflammation. Hematoxylin and eosin stain. Scale bar = 1 mm



**Figure 5** Detail of granulomatous infiltrates evident in biopsy samples. Epithelioid macrophages (arrows) were the dominant inflammatory cell type in most affected regions. Foci of necrotic tissue (bracket) with darkly stained eosinophilic cells, and cell debris were scattered throughout many regions of inflammation. Hematoxylin and eosin stain. Scale bar = 40  $\mu$ m

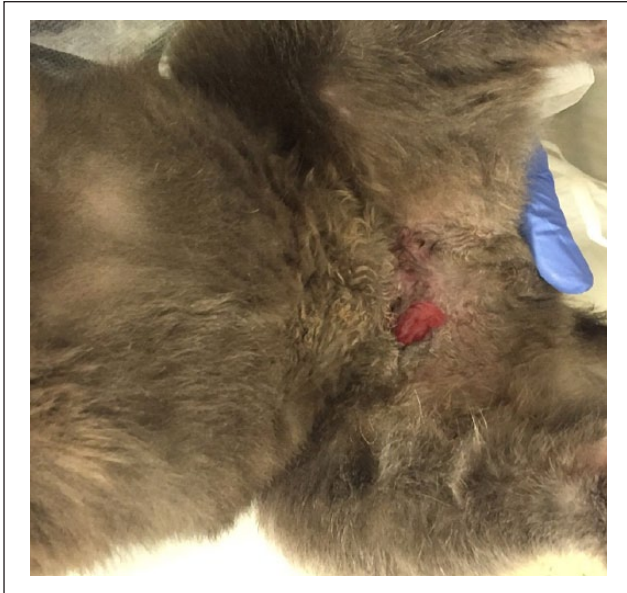and ribosomal RNA gene PCR for MTBC at Advanced Diagnostic Laboratory Services, National Jewish Health, Denver, CO. The MTBC PCR results were reported 3 days later as negative.

Pending the results of the tests listed above, the cat was treated with doxycycline monohydrate suspension (10 mg/kg q12h, followed by 5 ml water through the esophagostomy tube) and vancomycin (15 mg/kg IV q8h). The doxycycline was selected based on our previous success with doxycycline at this dose to treat mycobacterial panniculitis. Although a controversial choice, vancomycin was selected pending culture and susceptibility test results based on the history of isolation of MRSA and *C amycolatum*, the need for a parenteral antimicrobial drug, the severity of the lesions and concern for multidrug resistance in the light of the history of treatment with fluoroquinolones,  $\beta$ -lactams and trimethoprim sulfamethoxazole. Pain was managed with buprenorphine at 0.01 mg/kg intravenously every 4–6 h for the first 2 weeks of hospitalization and then via the sublingual route. Within several days of starting therapy the cat developed anorexia, apparent nausea, lethargy and acute elevations in the activity of serum liver enzymes (alanine aminotransferase 939 U/l [RI 27–101 U/l], aspartate aminotransferase 290 U/l [RI 17–58 U/l],

alkaline phosphatase 125 U/l [RI 14–71 U/l]) and an increase in serum bilirubin concentration (1.4 mg/dl [RI 0–0.2 mg/dl]). The hepatopathy was suspected to be an adverse reaction to doxycycline. Doxycycline treatment was discontinued and the hepatopathy resolved. In place of the doxycycline, treatment with pradofloxacin (7.5 mg/kg PO q24h) was initiated.<sup>11</sup>

The skin cultures performed at the University of California-Davis microbiology laboratory again yielded MRSA and *C amycolatum*. The MRSA was susceptible to gentamicin, amikacin, chloramphenicol, clindamycin, doxycycline, rifampin, trimethoprim sulfamethoxazole, daptomycin, vancomycin and linezolid but resistant to erythromycin and fluoroquinolones. The *C amycolatum* isolate was susceptible to chloramphenicol, doxycycline and vancomycin but resistant to aminoglycosides,  $\beta$ -lactams, clindamycin, erythromycin, trimethoprim sulfamethoxazole, fluoroquinolones, linezolid and rifampin. Treatment was therefore continued with parenteral vancomycin (for its activity against both the MRSA and *Corynebacterium* species isolates) and pradofloxacin (for presumed mycobacterial infection).

The vacuum-assisted wound closure system remained in place, in the inguinal area, for the first 2 weeks of hospitalization with wound evaluation and bandage



**Figure 6** Inguinal area 3 months after hospitalization (January 2016)

changes in both the inguinal area and the right lateral thigh every 2–3 days. Thirty days after admission, the wounds were closed in a staged manner involving two separate surgeries spaced 2 weeks apart. After hospitalization for 50 days, vancomycin was discontinued and the cat was discharged on oral pradofloxacin.

Four weeks after skin biopsy submission for mycobacterial culture in liquid medium, growth of *M thermoresistibile* was identified by the reference laboratory. The organism was identified using *rpoB* gene PCR sequencing. Antimicrobial susceptibility test results of *M thermoresistibile* became available 7 weeks from submission and the organism was reported to be susceptible to all antimicrobials tested (aminoglycosides, third-generation cephalosporins, imipenem, ciprofloxacin, moxifloxacin, doxycycline, clarithromycin, azithromycin, clavulanic acid–amoxicillin, trimethoprim sulfamethoxazole, clofazimine and linezolid).

Treatment with pradofloxacin was continued, but owing to the appearance of new wounds 3 weeks after discharge, clarithromycin (7 mg/kg PO q12h) and trimethoprim sulfamethoxazole (30 mg/kg PO q12h) were added to the antibiotic regimen. To overcome owner compliance concerns, the cat was housed at a medical boarding facility for 2 months. Dehiscence occurred at the surgical closure site in the inguinal region and was allowed to slowly heal by secondary intention (Figure 6). Sixteen months after original wound appearance and 7 months after hospitalization, the ulcerative skin lesions had healed completely and the cat had returned to normal activity. Several small firm subcutaneous nodules remained palpable on both sides of the abdominal body

wall which appeared to be slowly reducing in size and number.

## Discussion

Mycobacterial panniculitis in cats caused by non-tuberculous mycobacterial species has been well described in the literature.<sup>3,12</sup> One case report of *M thermoresistibile* pneumonia treatment exists in the literature. However, to the best of our knowledge, this is only the third report of mycobacterial panniculitis caused by *M thermoresistibile* in cats and the first report of attempted treatment of *M thermoresistibile* panniculitis.<sup>5,7</sup> The extent and severity of disease in this cat likely reflected a combination of delayed diagnosis and problems with owner compliance.

In human medicine it has been hypothesized that traumatic inoculation with *M thermoresistibile* present in soil results in local infection,<sup>2</sup> which may also have been the case in this cat with outdoor exposure. Mycobacterial infection was strongly suspected in this cat despite failure to isolate a mycobacterial species owing to clinical presentation and histopathology. The positive result on PCR for an MTBC organism in our laboratory was a concern because of the zoonotic potential of organisms belonging to this complex. However, the clinical presentation combined with the high CT value raised suspicion for a false-positive result, and upon discussion of the result with the laboratory, it was revealed that the primers used had the potential to amplify DNA from *Mycobacterium* species that do not belong to the MTBC. In previous reports, *M thermoresistibile* has been isolated after 2–4 days of incubation, suggesting that this strain may have been a slower-growing variant, or other factors (such as prior antimicrobial therapy) inhibited rapid growth of this isolate.

*M thermoresistibile* was first isolated from soil and house dust in Japan in 1966.<sup>9</sup> For many years *M thermoresistibile* was considered non-pathogenic, but in the past 20 years cases demonstrating its pathogenicity have been described in people and cats; cases have been reported from Asia, Europe and North America.<sup>2,4,9</sup> *M thermoresistibile* is also unusual in that it is thermotolerant, growing optimally at temperatures between 37°C and 52°C.<sup>6,8</sup> In people, reports of infection with *M thermoresistibile* have been associated with postsurgical infection (in a few of those implants were involved) in skin and lungs.<sup>2</sup> The majority of infected patients are immunocompromised, as is often true in other NTM infections in humans.<sup>2</sup> This, to our knowledge, is the first report of infection by *M thermoresistibile* in a cat in North America. It is possible that the paucity of previous reports of infections due to *M thermoresistibile* in cats may result from lack of full identification of the causative organism in some infections.

Two other bacterial species, *C amycolatum* and *S aureus*, were also isolated from the wounds of the cat in

this case report. Both are components of the normal flora of normal human and animal skin and mucous membranes.<sup>13,14</sup> However, they can also be pathogenic in some circumstances. In particular, *C amycolatum* is increasingly being recognized as an important pathogen of humans with multidrug resistance to commonly used antibiotics, although it is typically susceptible to vancomycin.<sup>13,15</sup> Over the course of the disease process, *C amycolatum* was isolated from the cat in this report four times, despite antimicrobial therapy, and likely contributed to the severity of the wounds in this cat. Given that *S aureus* can normally colonize cat skin,<sup>16</sup> the significance of the *S aureus* isolate was less clear, but it may also have played a role in secondary infection.

We ultimately chose pradofloxacin for long-term therapy of the mycobacterial infection, a third-generation fluoroquinolone licensed in the USA at a dose of 7.5 mg/kg for treatment of skin infections in the cat. Pradofloxacin possesses an extended spectrum of activity against gram-negative, gram-positive and anaerobic bacteria, as well as mycoplasma species and intracellular organisms (*Rickettsia* species and *Mycobacterium* species).<sup>11,17</sup> Specifically, pradofloxacin has demonstrated effective in vitro activity against rapid growing mycobacteria isolates.<sup>17</sup> Although *M thermoresistibile* was not tested for susceptibility for pradofloxacin, it was susceptible to moxifloxacin, a human fluoroquinolone that is the chemical equivalent of pradofloxacin.<sup>17</sup> The choice of vancomycin to address the secondary infections in this case was controversial given concerns about use of this antibiotic in animals. However, vancomycin was chosen because vancomycin is the drug of choice for MRSA and resistant *Corynebacterium* species infections in humans, both the MRSA and the multidrug-resistant *Corynebacterium* species isolates in this case had documented susceptibility, and no alternative single bactericidal antimicrobial could be identified that could be given parenterally with a wide therapeutic index. It is possible that a shorter duration of therapy might also have been sufficient, but given the multiple surgeries required and the extent and depth of the infected wounds, the decision was made to continue to treat until surgery had been completed and the cat could be discharged from the hospital.

## Conclusions

To our knowledge, this is the first case report of the treatment of *M thermoresistibile* panniculitis in a cat and the first report of infection with this organism in cats in North America. It is also the first report, to our knowledge, of cutaneous infection with *C amycolatum* in a cat. If clinical presentation is consistent with a mycobacterial infection, appropriate samples should be submitted for mycobacterium growth and identification, even if other bacterial species have been isolated from the

patient. Successful isolation of some mycobacterial species may require prolonged incubation at institutions with expertise in isolation of mycobacteria. Despite intensive wound management and combination therapy with antimicrobial drugs, in addition to efforts to ensure client compliance, resolution of severe mycobacterial panniculitis caused by *M thermoresistibile* may not be possible, although additional studies are required to support this observation.

## Acknowledgement

We wish to acknowledge the support and expertise that we received from the University of California-Davis Veterinary Medical Teaching Hospital Soft Tissue Surgery Service with regard to management of the case described in this report.

**Funding** The authors received no financial support for the research, authorship, and/or publication of this article.

**Conflict of interest** The authors declared no potential conflicts of interest with respect to the research, authorship, and/or publication of this article.

## References

- Gunn-Moore DA. **Feline mycobacterial infections.** *Vet J* 2014; 201: 230–238.
- Suy F, Carricajo A, Grattard F, et al. **Infection due to *Mycobacterium thermoresistibile*: a case associated with an orthopedic device.** *J Clin Microbiol* 2013; 51: 3154–3156.
- Malik R, Wigney DI, Dawson D, et al. **Infection of the subcutis and skin of cats with rapidly growing mycobacteria: a review of microbiological and clinical findings.** *J Feline Med Surg* 2000; 2: 35–48.
- Shojaei H, Heidarieh P, Hashemi A, et al. **Species identification of neglected nontuberculous mycobacteria in a developing country.** *Jpn J Infect Dis* 2011; 64: 265–271.
- Reppas G, Fyfe J, Foster S, et al. **Detection and identification of mycobacteria in fixed stained smears and formalin-fixed paraffin-embedded tissues using PCR.** *J Small Anim Pract* 2013; 54: 638–646.
- Foster SF, Martin P, Davis W, et al. **Chronic pneumonia caused by *Mycobacterium thermoresistibile* in a cat.** *J Small Anim Pract* 1999; 40: 433–438.
- Willemse T, Groothuis DG, Koeman JP, et al. ***Mycobacterium thermoresistibile*: extrapulmonary infection in a cat.** *J Clin Microbiol* 1985; 21: 854–856.
- Neonakis IK, Gitti Z, Kontos F, et al. ***Mycobacterium thermoresistibile*: case report of a rarely isolated mycobacterium from Europe and review of literature.** *Indian J Med Microbiol* 2009; 27: 264–267.
- Lim JM, Kim JH and Yang HJ. **Management of infections with rapidly growing mycobacteria after unexpected complications of skin and subcutaneous surgical procedures.** *Arch Plast Surg* 2012; 39: 18–24.
- Owen L, Hotston-Moore A and Holt P. **Vacuum-assisted wound closure following urine-induced skin and thigh muscle necrosis in a cat.** *Vet Comp Orthop Traumatol* 2009; 22: 417–421.

- 11 Lees P. **Pharmacokinetics, pharmacodynamics and therapeutics of pradofloxacin in the dog and cat.** *J Vet Pharmacol Ther* 2013; 36: 209–221.
- 12 Lloret A, Hartmann K, Pennisi MG, et al. **Mycobacterioses in cats: ABCD guidelines on prevention and management.** *J Feline Med Surg* 2013; 15: 591–597.
- 13 Chen X, Zhao X, Chen L, et al. **Vaginitis caused by *Corynebacterium amycolatum* in a prepubescent girl.** *J Pediatr Adolesc Gynecol* 2015; 28: e165–e167.
- 14 Cogen AL, Nizet V and Gallo RL. **Skin microbiota: a source of disease or defence?** *Br J Dermatol* 2008; 158: 442–455.
- 15 Sengupta M, Naina P, Balaji V, et al. ***Corynebacterium amycolatum*: an unexpected pathogen in the ear.** *J Clin Diagn Res* 2015; 9: DD01–DD03.
- 16 Davis JA, Jackson CR, Fedorka-Cray PJ, et al. **Carriage of methicillin-resistant staphylococci by healthy companion animals in the US.** *Lett Appl Microbiol* 2014; 59: 1–8.
- 17 Govendir M, Norris JM, Hansen T, et al. **Susceptibility of rapidly growing mycobacteria and *Nocardia* isolates from cats and dogs to pradofloxacin.** *Vet Microbiol* 2011; 153: 240–245.