



## **Surgical management of medial humeral epicondylitis, cubital synovial osteochondromatosis and humeroradial subluxation in a cat**

Author: Perry, Karen L

Source: Journal of Feline Medicine and Surgery Open Reports, 3(1)

Published By: SAGE Publishing

URL: <https://doi.org/10.1177/2055116917695053>

---

BioOne Complete ([complete.BioOne.org](http://complete.BioOne.org)) is a full-text database of 200 subscribed and open-access titles in the biological, ecological, and environmental sciences published by nonprofit societies, associations, museums, institutions, and presses.

Your use of this PDF, the BioOne Complete website, and all posted and associated content indicates your acceptance of BioOne's Terms of Use, available at [www.bioone.org/terms-of-use](http://www.bioone.org/terms-of-use).

Usage of BioOne Complete content is strictly limited to personal, educational, and non - commercial use. Commercial inquiries or rights and permissions requests should be directed to the individual publisher as copyright holder.

---

BioOne sees sustainable scholarly publishing as an inherently collaborative enterprise connecting authors, nonprofit publishers, academic institutions, research libraries, and research funders in the common goal of maximizing access to critical research.



# Surgical management of medial humeral epicondylitis, cubital synovial osteochondromatosis and humeroradial subluxation in a cat

Karen L Perry

*Journal of Feline Medicine and Surgery Open Reports*  
1–6

© The Author(s) 2017

Reprints and permissions:

sagepub.co.uk/journalsPermissions.nav

DOI: 10.1177/2055116917695053

journals.sagepub.com/home/jfmsopenreports

This paper was handled and processed by the American Editorial Office (AAFP) for publication in *JFMS Open Reports*



## Abstract

**Case summary** A 13-year-old domestic shorthair cat presented for evaluation of pain and difficulty ambulating. Orthopedic examination and CT facilitated a diagnosis of bilateral elbow synovial osteochondromatosis with medial humeral epicondylitis and concurrent osteoarthritis. Right humeroradial subluxation was evident on CT images, but no instability was evident preoperatively. Surgical treatment was elected, including external neurolysis of the ulnar nerve, removal of the areas of mineralization within the flexor carpi ulnaris muscle and medial arthrotomy to remove intra-articular mineralized bodies. Following closure, instability of the right elbow was noted with humeroradial subluxation necessitating placement of circumferential suture prostheses to provide satisfactory stability. Reassessment was performed 2, 6, 12, 24 and 40 weeks postoperatively and revealed maintenance of elbow stability and substantial improvement in mobility and comfort.

**Relevance and novel information** While humeroradial subluxation has been reported in association with medial humeral epicondylitis on post-mortem examination, associated clinically significant instability has not been documented previously. Surgeons should be aware of the potential for this complication and check elbow stability following surgery. Despite this complication, a favorable medium-term outcome was achieved for this cat.

**Accepted:** 24 January 2017

## Introduction

Radiographic and histologic evidence of medial humeral epicondylitis (MHE) has been reported in up to 10% of cats, based on post-mortem examination.<sup>1</sup> This condition is suspected to be caused by repeated trauma and overuse due to jumping from heights. Strain and traumatic avulsions of the tendons of origin of the flexor muscles lead to tendinosis, partial tearing and sometimes full thickness tears of the tendons.<sup>2</sup> Findings associated with MHE include chronic degeneration, mineralization and metaplastic new bone formation in the origin of the humeral head of the flexor carpi ulnaris muscle.<sup>1</sup> This condition also frequently results in flattening and displacement of the ulnar nerve, periosteal adhesions and epineurial fibrosis, as well as intra-articular mineralized bodies.<sup>1</sup>

In a post-mortem study of six cats with MHE, immediate post-mortem radiographs revealed mild-to-moderate subluxation of the humeroulnar or humeroradial joint in three cats.<sup>1</sup> It was postulated that the thickened and

partially mineralized joint capsule lead to subluxation of the humeral condyle and subsequent cartilage defects. However, in a more recent study involving clinically affected cats with MHE, there was no mention of subluxation affecting any cat.<sup>3</sup>

In this report, a case of MHE that did not respond satisfactorily to non-surgical management is described. However, following surgical removal of the mineralized fragments increased angles of pronation and

Department of Small Animal Clinical Sciences, Michigan State University, East Lansing, MI, USA

### Corresponding author:

Karen L Perry BVM&S, CertSAS, DipIECVS, FHEA, MRCVS, Michigan State University Veterinary Medical Center, 736 Wilson Road, East Lansing, MI 48824-1314, USA

Email: kperry@cvm.msu.edu



Creative Commons Non Commercial CC-BY-NC: This article is distributed under the terms of the Creative Commons

Attribution-NonCommercial 3.0 License (<http://www.creativecommons.org/licenses/by-nc/3.0/>) which permits non-commercial use, reproduction and distribution of the work without further permission provided the original work is attributed as specified on the SAGE and Open Access pages (<https://us.sagepub.com/en-us/nam/open-access-at-sage>).

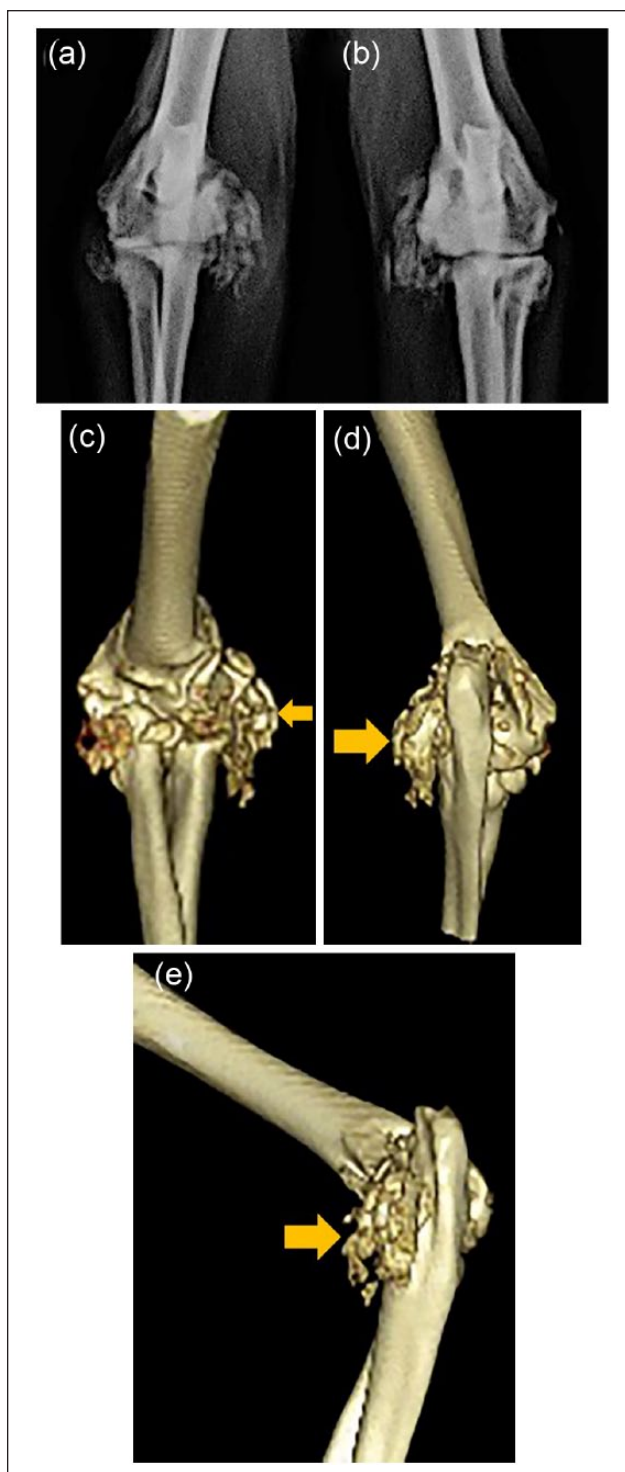
humero-radial subluxation were noted, necessitating placement of circumferential suture prostheses to provide satisfactory stability.

### Case description

A 13-year-old neutered female domestic shorthair cat presented for evaluation of generalized pain and difficulty ambulating. The cat had a history of osteoarthritis affecting multiple joints for 3 years, but the level of discomfort and mobility had deteriorated substantially over the past 4 months. The owners had noted a reluctance to go down stairs or jump down from heights. Inappropriate urination was occasionally reported and the cat no longer buried feces in the litter tray. The cat also often had to be carried to its food and water owing to a general reluctance to move. Meloxicam (0.05 mg/kg PO q 24h Metacam; Boehringer Ingelheim) and tramadol (3 mg/kg PO q 12h; Janssen Pharmaceuticals) had been started by the primary care veterinarian 3 months prior to presentation, and only resulted in a mild improvement in perceived comfort and mobility. A feline musculoskeletal pain index (FMPI)<sup>4</sup> completed by the owner at this initial visit gave a result of 27%.

On presentation, the cat was bright, alert and responsive, and a general physical examination was within normal limits, except for a mildly increased body condition score (6/9). Gait assessment was very difficult to perform as the cat was reluctant to move, and only a few steps at a time were achieved. This revealed that the cat walked very low to the ground with a short, choppy gait. A moderate bilateral thoracic limb lameness was evident, which was more severe on the right. Manipulation of both elbows elicited a marked pain response, particularly on flexion with simultaneous supination or pronation. A normal range of motion in pronation and supination was evident when performing Campbell's test based on angles of rotation previously described in cats,<sup>5</sup> but there was a moderate restriction in range of motion in flexion bilaterally and a mild restriction in range of motion in extension affecting the right elbow. A marked pain response was also evident upon palpation directly over the medial epicondyle bilaterally. Crepitus was palpable on manipulation of both elbows. Bilateral grade 2/4 medial patellar luxation was evident, as well as severe thickening of the left stifle and right tarsus, and moderate thickening of the left tarsus.

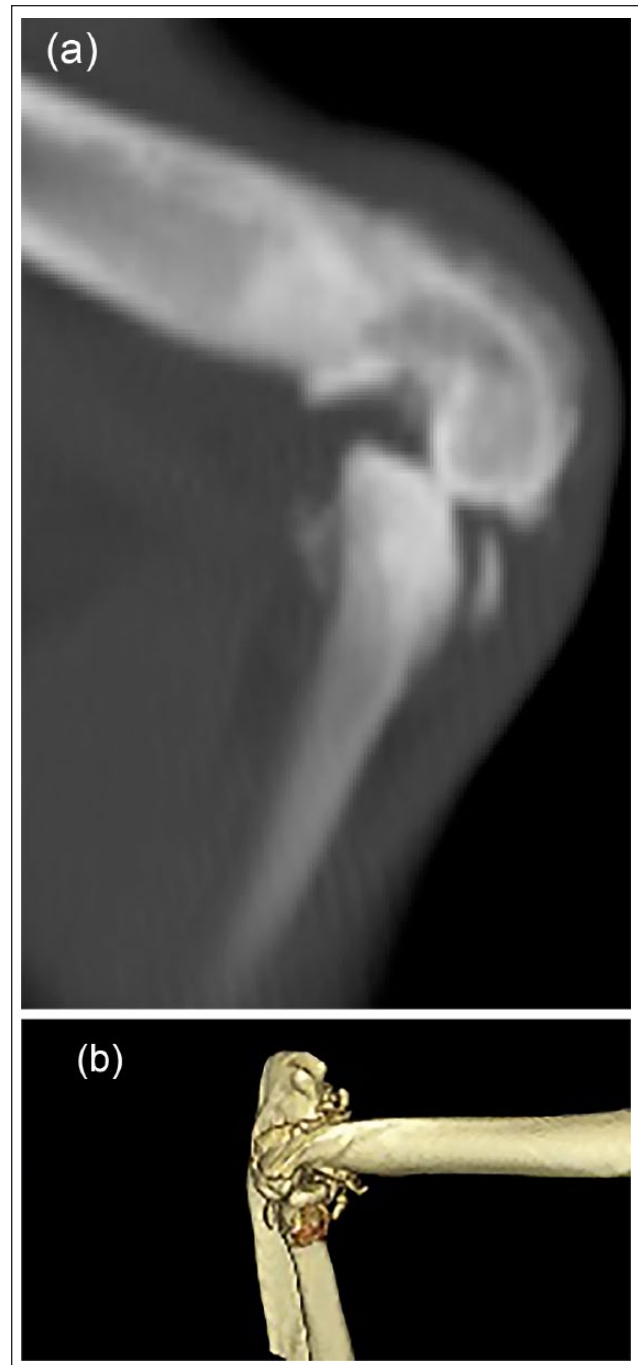
Under sedation, CT imaging of both elbows was performed. The pelvic limbs were also imaged, owing to the concomitant findings on physical examination. The CT images revealed large mineral attenuating synovial and periarticular foci surrounding both elbows. Large mineral fragments were noted in the medial flexor tendons, adjacent to the olecranon of the ulna bilaterally (Figure 1a–c). Mineral fragments were also noted proximal to the medial



**Figure 1** Preoperative craniocaudal radiographs of the (a) right and (b) left elbows performed prior to referral and three-dimensional reconstructions (c) craniocaudal, (d) caudocranial and (e) oblique orientations demonstrating the large mineral-attenuating synovial and periarticular foci surrounding both elbows. Particularly evident are the large mineral fragments in the medial flexor tendons (yellow arrows)

coronoid process of the ulna on the right. The right radius was mildly displaced craniolaterally in relation to the humerus, and there was humeroradial subluxation noted (Figure 2 a,b). There were mild subchondral cystic changes affecting the distal humerus bilaterally and the left proximal radius. Based on these findings a diagnosis of bilateral elbow synovial osteochondromatosis with MHE, right humeroradial subluxation and concurrent osteoarthritis was made. Regarding the pelvic limbs, synovial osteochondromatosis of the left stifle and both tarsi was diagnosed in addition to osteoarthritis in the right tarsus. Owing to the involvement of multiple joints, synoviocentesis of both elbows, both stifles and both hocks was performed. The volumes of fluid obtained were small and only sufficient for cytology; this revealed evidence of mild inflammatory change consistent with osteoarthritis.

Given the lack of satisfactory response to non-surgical management over the preceding 3 months, surgical management was considered justified for this cat. Under general anesthesia both elbows were prepared for aseptic surgery. The cat was positioned in dorsal recumbency, allowing access to the medial aspect of both elbows. Starting on the right side, a curvilinear skin incision was made just caudal to the medial epicondyle from the proximal extent of the tuber olecrani to the proximal third of the ulna. The incision continued along the same line through the superficial and deep antebrachial fascia. Retraction of the fascia revealed the medial epicondyle and associated musculature. The mineralized areas were identified to be primarily affecting the humeral head of the flexor carpi ulnaris muscle. These were causing deviation and compression of the ulnar nerve but without significant epineural fibrosis. External neurolysis was performed, detaching the nerve from all points of compression (Figure 3), and the nerve was re-situated in a bed free of scar tissue, as has been previously described.<sup>3</sup> As the epineurium was not severely thickened, internal neurolysis was not felt to be indicated. The extensive area of mineralization within the flexor carpi ulnaris muscle was then removed by blunt dissection (Figures 3 and 4). A medial elbow arthrotomy was performed caudal to the medial collateral ligament with care being taken to preserve this structure. It was noted that the joint capsule was severely thickened and partially mineralized. Two small (2 × 2 mm) intra-articular mineralized bodies were removed. Partial-thickness cartilage defects were noted affecting the medial coronoid process but the process itself appeared intact. The joint capsule was closed with simple interrupted sutures of 3/0 polydioxanone. With the carpus held in flexion, the remaining stump of the humeral head of the flexor carpi ulnaris muscle was reattached to the antebrachial fascia at the level of the medial epicondyle using an interlocking suture of the same material. Additional interrupted sutures were placed between the edges of the stump of

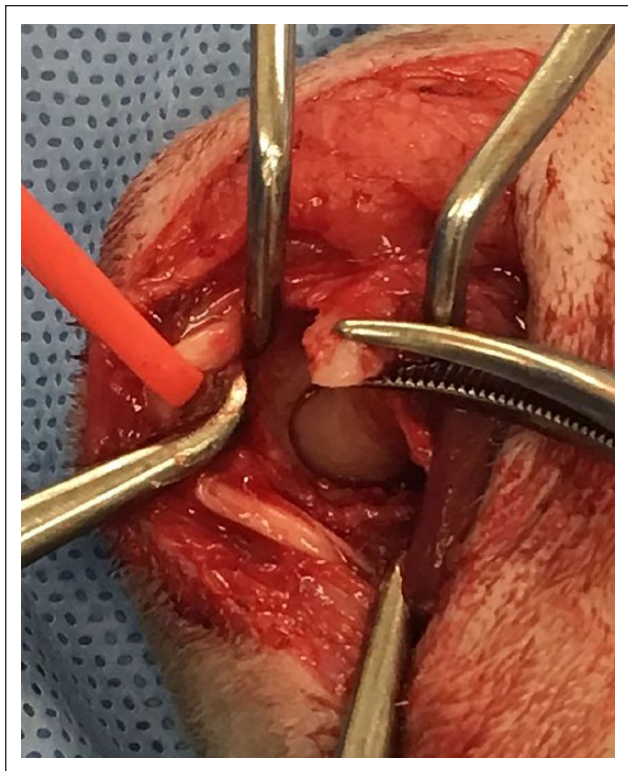


**Figure 2** Sagittal slice from a (a) CT scan and (b) three-dimensional reconstruction from CT scan showing displacement of the right radius craniolaterally in relation to the humerus

the humeral head and surrounding soft tissues, including the ulnar head of the flexor carpi ulnaris muscle.

Following this, the Campbell's test was performed and it was noted that there was an increased range of rotation in pronation with 100° of rotation possible and humeroradial subluxation palpable. This degree of

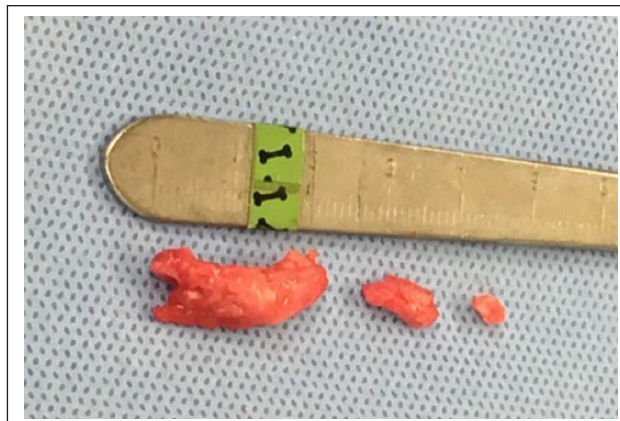




**Figure 3** Intraoperative photograph demonstrating ulnar nerve being retracted following external neurolysis. The extensive area of mineralization within the flexor carpi ulnaris muscle can also be seen within the tips of the forceps. This was then removed by blunt dissection

rotation was significantly increased when compared with normal ranges of pronation previously reported in cats,<sup>5</sup> and when compared with that noted preoperatively in this cat. The instability was more severe with the elbow joint held in flexion. The closure was modified removing some of the redundant joint capsule and imbricating the closure; while this improved the instability noted, the range of motion in pronation remained excessive. As has been reported by Farrell et al, a 2.0 mm drill bit was used to drill three bone tunnels:<sup>5,6</sup> one humeral transcondylar, one transradial and one transulnar. A double loop of four metric Prolene suture was placed through the humeral tunnel from lateral to medial and then through the radial tunnel from medial to lateral. This was secured using a self-locking knot. This procedure was then repeated for the ulnar tunnel using a single strand of the same suture secured using a half-hitch knot. Following this, the degree of rotation in pronation was considered to be within normal limits (52°) and routine closure followed.

A similar curvilinear medial approach was made to the left epicondyle and, as on the right side, external neurolysis of the ulnar nerve was performed, as well as removal of a large area of mineralization of the humeral head of the flexor carpi ulnaris. Exploratory arthrotomy



**Figure 4** Intraoperative photograph demonstrating areas of mineralization removed from both the humeral head of flexor carpi ulnaris muscle and within the elbow, adjacent to a measuring device

did not reveal any intra-articular mineralizations and there was no grossly apparent cartilage damage affecting the medial coronoid process. Closure was routine and no instability was apparent on Campbell's test following this.

Postoperative radiographs revealed removal of the large mineralized peri-articular fragments but with persistent synovial osteochondromatosis evidenced as residual mineral opacities over the proximal ulna, medial and lateral epicondyles. The bone tunnels were evident on the right side and congruity of the elbow joint was satisfactory. No carpal flexion bandage was applied as bilateral surgery had been performed. Strict cage confinement was enforced for 6 weeks and analgesic medication consisting of robenacoxib (1 mg/kg PO q24h Onsior; Elanco Animal Health) and gabapentin (5 mg/kg PO q8h; Henry Schein Animal Health). The robenacoxib was used as a pulse therapy, with 3 days on and 1 day off, for a total of 9 days, while the gabapentin was prescribed for 10 days.

At re-examination 14 days postoperatively the cat seemed subjectively more mobile in the consulting room, but a crouched thoracic limb stance and moderate bilateral thoracic limb lameness remained evident. The skin incisions had healed uneventfully and the sutures were removed. The range of motion of the left elbow was within normal limits, with no associated pain response. There was a mild restriction in flexion and extension affecting the right elbow, but the elbow was stable when Campbell's test was performed, with a normal range of rotation in both pronation and supination. There was no pain response upon palpation over the medial epicondyle on the left, while a mild pain response persisted on the right. Continued cage restriction and further courses of robenacoxib and gabapentin were prescribed at the same dosages as above for a further 10 days.

At 6 weeks postoperatively, the owner reported improvement in multiple aspects of the cat's behavior, including increased grooming, a return to covering its feces in the litter tray and an increased ability to rest comfortably. It was still being restricted to a cage but showed increased inclination to escape and had jumped up and down from the bed, which it had not been able to do for several months. No medication was being administered at this stage. The FMPI was repeated and showed substantial improvement to 67.5%. Gait assessment was easier during this visit as the cat was more mobile. A mild bilateral thoracic limb lameness persisted, but the crouched stance had markedly improved. There was no pain response upon palpation over the medial humeral epicondyle bilaterally and only a mild restriction in extension of the right elbow. Both elbows remained stable when Campbell's test was performed. A gradual return to more normal activity levels was advised with stepped access to heights being provided, to reduce ongoing impact on the elbows.

Twelve weeks postoperatively, the improvement reported at 6 weeks was sustained. The cat had been allowed full access to the house with stepped access to heights. The cat was able to get on and off high surfaces easily, and was reported to be much more active than prior to the surgery. The improvement in FMPI was also sustained with a score of 62.5%.

Six months postoperatively, the cat was reassessed owing to a perceived deterioration by the owner. The cat had become unwilling to go upstairs or jump up on to surfaces, although once lifted up it appeared comfortable to jump down. Repeat examination revealed no alteration in examination of the thoracic limbs since its previous visit, but discomfort was associated with examination of the right hock and a pain response apparent upon luxation of the left patella, which had not been noted previously. Repeat prescriptions of gabapentin and robenacoxib, at the same dosages as used previously, were provided and the deterioration was felt likely to be due to the concurrent pelvic limb conditions rather than the elbows. Over the following 4 months, occasional doses of robenacoxib and gabapentin were required to maintain comfort, but no long-term medications were given. Repeat assessment 10 months postoperatively when the cat was not receiving medication revealed the conditions to remain static, with a FMPI of 65%.

## Discussion

In a post-mortem study, subluxation of the humeroulnar and humeroradial joints has been reported in cats with MHE.<sup>1</sup> It was postulated in that study that the thickened and partially mineralized joint capsule in patients with chronic MHE may lead to subluxation of the humeral condyle. In that study, elbow instability was not detected on necropsy examination in any cat. There is a distinct

paucity of peer-reviewed clinical reports regarding MHE in cats, but in the one case series available,<sup>3</sup> no mention is made of humeroradial or humeroulnar subluxation. In the case detailed here, humeroradial subluxation was noted on CT images preoperatively. At this stage, no elbow instability was detected. However, following removal of the extensive area of mineralization within the flexor carpi ulnaris muscle, external neurolysis of the ulnar nerve and medial elbow arthrotomy to remove intra-articular fragments, increased angles of pronation and humeroradial subluxation were apparent.

The precise cause of the instability noted can only be speculated from this individual case report but is suspected to be multifactorial. The elbow is composed of three articulations, the ulnohumeral, radiohumeral and radioulnar joints. The bony architecture of these joints represents the most basic element of the stability of the elbow. The relationships of the bones provide a static restraint to cranio/caudal, varus/valgus and rotational motion. As was noted on the preoperative CT scan, the relationship between these bones was altered, likely secondarily to the thickened and mineralized joint capsule, which may have contributed to instability. While a traumatic cause for the subluxation cannot be entirely ruled out, this is considered less likely given the bilateral nature of the MHE, osteochondromatosis and osteoarthritis, and the lack of a reported history of trauma in an indoor cat.

Another important factor in the stability of the elbow is the function of the collateral ligaments. The collateral ligaments vary in cats with respect to dogs;<sup>7</sup> while they still consist of two parts each, their course and relative strength differ. The ulnar parts of both the medial and lateral collateral ligaments are broader than the radial parts. The ulnar parts of the collateral ligaments are taut throughout the range of motion, whereas the radial parts are lax in flexion, allowing an increased range of motion of the radial head. Farrell et al demonstrated the importance of the collateral ligaments for elbow joint stability in cats,<sup>5</sup> showing that compromise of the medial collateral ligament resulted in increased pronation, whereas compromise of the lateral collateral ligament resulted in increased supination. Luxation of the elbow joint was not possible in cats unless both collateral ligaments were impaired. It is feasible that the extensive thickening of the joint capsule in this case, secondarily to both the MHE and synovial osteochondromatosis, may have led to stretching of the overlying collateral ligaments. While every effort was made to spare the medial collateral ligament during the surgical approach, and this is considered unlikely, it remains possible that minor damage could have been incurred, which may also have contributed to the instability noted. While the instability was more severe in flexion, it was also apparent in elbow extension, indicating that both radial and ulnar components of the ligament were likely affected.

The remaining contributors to elbow stability include the joint capsule and the medial and lateral muscle groups, which act as dynamic stabilizers to supplement the static structures mentioned above. Removal of the extensive mineralization within the humeral head of the flexor carpi ulnaris necessarily compromised this structure, which may have contributed to the instability noted. The joint capsule was also incised during the surgical approach, which may have impacted on joint stability. Additionally, the mineralization removed on the right was extensive and prior to surgery extended peri-articularly, including crossing the humeroradial joint on the medial aspect. It is considered likely that this provided medial stability to the joint explaining why the instability was only noted following its removal.

Following this complication, stabilization was required and performed using a circumferential suture technique which has been previously described for use in traumatic elbow luxation in cats.<sup>5,6</sup> Other possibilities to stabilize the joint may have included external coaptation, placement of prosthetic collateral ligaments using synthetic suture or orthopedic wire, or use of a trans-articular external skeletal fixator. Circumferential sutures were elected in this case owing to the positive results reported in the previous literature,<sup>6</sup> and the consideration that the cat was unlikely to tolerate external means of stabilization well. Despite this complication, the cat experienced a significant improvement in comfort and mobility for the 10 months following surgery having been previously non-responsive to non-surgical management. There was no recurrence of the humeroradial instability during this time period. This supports the findings of Streubel et al, who documented that the surgical treatment of MHE is associated with an excellent outcome in the majority of cats.<sup>3</sup> Given the concomitant orthopedic conditions this particular cat suffered from, including severe bilateral elbow osteoarthritis, synovial osteochondromatosis affecting multiple joints, bilateral medial patellar luxation and osteoarthritis of the right tarsus, a return to normal function was never anticipated. The aim of the surgical procedure was to improve comfort and mobility, and facilitate control of ongoing discomfort with less intensive medical management. This was certainly achieved as documented by the reduced medication required and the improvements in FMPI scores.

The FMPI is a subjective owner-completed instrument developed to assess chronic feline degenerative joint disease (DJD)-associated pain.<sup>4</sup> The currently available version of the FMPI is comprised of 17 questions with a maximum score of 68. The questionnaire asks questions regarding the cat's ability to complete various activities compared with a normal adult cat without mobility impairment. It has been proven to be reliable

and repeatable in both normal cats and those suffering from DJD, and is also able to distinguish between normal cats and those with DJD.<sup>4</sup> The use of the FMPI to demonstrate the initial impairment and subsequent improvement of the cat in this report is therefore considered appropriate. In 2013, a previous design of this questionnaire was used to compare FMPI scores in a population of cats suffering from DJD-associated pain, and the median score in normal cats was 0% in comparison to 35% in cats with DJD-associated pain.<sup>4</sup> Comparison of these values demonstrates that the cat described herein was significantly affected by the joint disease, and that substantial improvement, albeit not to the level of a normal cat, was achieved postoperatively.

## Conclusions

Surgeons should be aware of this potential complication associated with surgery for chronic MHE and should carefully assess the stability of the operated elbow postoperatively. The outcome following surgery can remain positive even in these advanced and complex cases and therefore surgery should continue to be offered in cases that do not respond satisfactorily to non-surgical treatment.

**Funding** The authors received no financial support for the research, authorship, and/or publication of this article

**Conflict of interest** The authors declared no potential conflicts of interest with respect to the research, authorship, and/or publication of this article.

## References

- 1 Streubel R, Geyer H and Montavon PM. **Medial humeral epicondylitis in cats.** *Vet Surg* 2012; 41: 795–802.
- 2 Nirschl RP. **Prevention and treatment of elbow and shoulder injuries in the tennis player.** *Clin Sports Med* 1992; 21: 199–205.
- 3 Streubel R, Bilzer T, Grest P, et al. **Medial humeral epicondylitis in clinically affected cats.** *Vet Surg* 2015; 44: 905–913.
- 4 Benito J, Hansen B, DePuy V, et al. **Feline musculoskeletal pain index: responsiveness and testing of criterion validity.** *J Vet Intern Med* 2013; 27: 474–482.
- 5 Farrell M, Draffan D, Gemmill T, et al. **In vitro validation of a technique for assessment of canine and feline elbow joint collateral ligament integrity and description of a new method for collateral ligament prosthetic replacement.** *Vet Surg* 2007; 36: 548–556.
- 6 Farrell M, Thomson DG and Carmichael S. **Surgical management of traumatic elbow luxation in two cats using circumferential prostheses.** *Vet Comp Orthop Traumatol* 2009; 22: 66–69.
- 7 Vollmerhaus B, Roos H and Brugger S. **Anatomic fundamentals and species-specific movements of the elbow joint and proximal radioulnar joint of domestic cats.** *Tierarztl Prax* 1993; 21: 16.