



Bronchoscopic debulking of a feline tracheobronchial carcinoma and long-term outcome

Authors: Ruiz, Marina Dominguez, Grant, Jessica, and Hernandez, Juan

Source: Journal of Feline Medicine and Surgery Open Reports, 4(1)

Published By: SAGE Publishing

URL: <https://doi.org/10.1177/2055116918767706>

BioOne Complete (complete.BioOne.org) is a full-text database of 200 subscribed and open-access titles in the biological, ecological, and environmental sciences published by nonprofit societies, associations, museums, institutions, and presses.

Your use of this PDF, the BioOne Complete website, and all posted and associated content indicates your acceptance of BioOne's Terms of Use, available at www.bioone.org/terms-of-use.

Usage of BioOne Complete content is strictly limited to personal, educational, and non - commercial use. Commercial inquiries or rights and permissions requests should be directed to the individual publisher as copyright holder.

BioOne sees sustainable scholarly publishing as an inherently collaborative enterprise connecting authors, nonprofit publishers, academic institutions, research libraries, and research funders in the common goal of maximizing access to critical research.



Bronchoscopic debulking of a feline tracheobronchial carcinoma and long-term outcome

Marina Dominguez Ruiz¹, Jessica Grant² and Juan Hernandez^{1,3}

Journal of Feline Medicine and Surgery Open Reports
1–5

© The Author(s) 2018

Reprints and permissions:

sagepub.co.uk/journalsPermissions.nav

DOI: 10.1177/2055116918767706

journals.sagepub.com/home/jfmsopenreports

This paper was handled and processed by the European Editorial Office (ISFM) for publication in *JFMS Open Reports*



Abstract

Case summary This report describes a 10-year-old female spayed Russian Blue cat presented with a 5 month history of respiratory difficulty. Thoracic radiographs were suggestive of a central airway obstruction. Bronchoscopy revealed a broad-base mass in the region of the carina. Bronchoscopic debulking was performed using a urinary catheter. Histopathology confirmed the presence of a tracheobronchial carcinoma. Survival from diagnosis was 16 months (480 days), over which time the cat underwent three endoscopic debulking procedures in combination with doxorubicin chemotherapy.

Relevance and novel information To our knowledge, this is the first report of a tracheobronchial carcinoma in a cat treated by endoscopic debulking with a urinary catheter and adjuvant chemotherapy with long-term survival time. A review of interventional bronchoscopy performed in humans and in veterinary medicine is described.

Accepted: 26 February 2018

Introduction

Primary tracheal tumours are rare in cats.^{1–5} Lymphoma, squamous cell carcinoma and adenocarcinoma are the most commonly reported feline tracheal tumours.¹ In human medicine, optimal therapy for non-lymphomatous tracheal neoplasia is surgical resection and anastomosis; however, the viability of this option is often dictated by the size and location of the mass.^{6,7} Interventional bronchoscopy has been extensively described as a minimally invasive procedure for the diagnosis and treatment of central airway tumours, especially those resulting in central airway obstruction when surgery is not feasible.^{6,8} In cats, optimal therapy is not known. Previously described treatments include surgical resection, external radiation therapy, bronchoscopic debulking and administration of cytotoxic chemotherapy and tyrosine kinase inhibitor.^{2,4,5}

Case description

A 10-year-old, female spayed, Russian Blue cat (2.2 kg) was referred to the Veterinary Hospital Frégis with a 5 month history of progressively worsening increased respiratory effort and tachypnoea. The cat had been recently

vaccinated and dewormed, and lived strictly indoors. Empiric treatments with theophylline (20 mg/kg q24h PO for 5 months), terbutaline (0.2 mg/kg q12h PO for 5 months), dexamethasone (0.2 mg/kg q24h PO for 5 months) and ciclosporin (5 mg/kg q24h PO for 3 months) had resulted in only partial and transitory improvements.

On physical examination, the cat was alert, with a body condition score of 3/9. An increased respiratory rate (50 breaths per min) and an abnormal breathing pattern with both inspiratory and expiratory effort were observed. Wheezes and a bilateral decrease of

¹Veterinary Hospital Frégis, Arcueil, France

²Rutland House Referrals, St Helens, UK

³Internal Medicine Unit of Oniris, Nantes-Atlantic College of Veterinary Medicine and Food Sciences, Nantes, France

Corresponding author:

Juan Hernandez, DVM, MSc, DACVIM, DECVIM-CA Internal Medicine Unit of Oniris, Nantes-Atlantic College of Veterinary Medicine and Food Sciences, Atlanpole La Chantrerie, CS 40706, 44307 Nantes Cedex 3, France
Email: juan.hernandez@oniris-nantes.fr



Creative Commons Non Commercial CC BY-NC: This article is distributed under the terms of the Creative Commons

Attribution-NonCommercial 4.0 License (<http://www.creativecommons.org/licenses/by-nc/4.0/>) which permits non-commercial use, reproduction and distribution of the work without further permission provided the original work is attributed as specified on the SAGE and Open Access pages (<https://us.sagepub.com/en-us/nam/open-access-at-sage>).

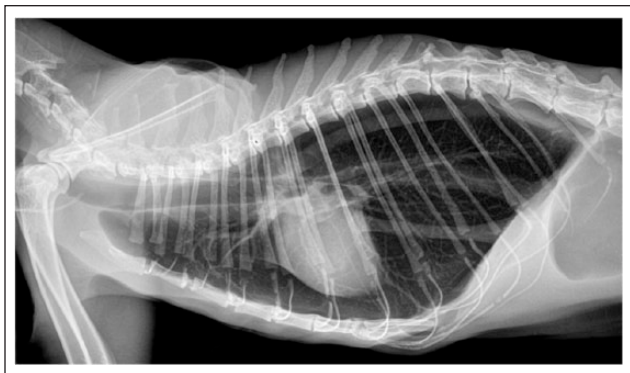


Figure 1 Right lateral thoracic radiograph showing a severe diffuse pulmonary hyperinflation, associated with a widening of trachea diameter and a tracheobronchial bifurcation disruption

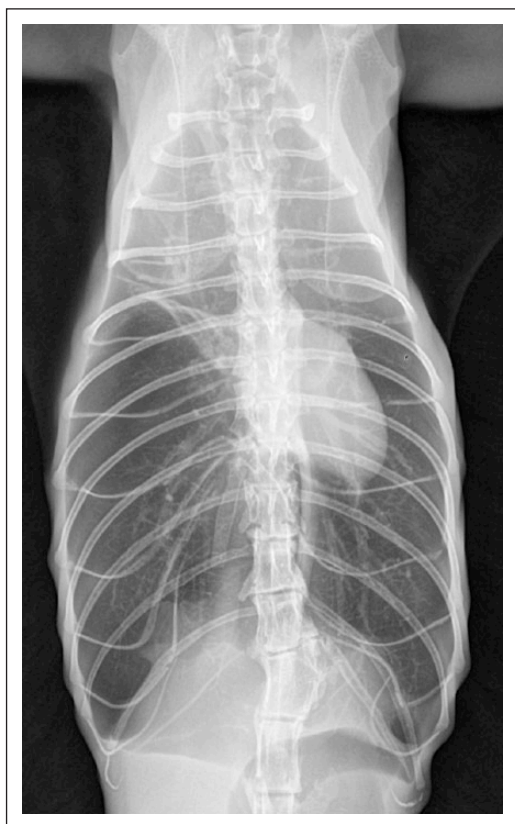


Figure 2 Ventrodorsal thoracic radiograph. Note the parallelism among the ribs due to important generalised pulmonary hyperinflation

bronchovesicular sounds were identified on thoracic auscultation. Thoracic radiographs showed a generalised pulmonary hyperinflation, associated with a tracheobronchial bifurcation disruption, most suggestive of a central airway obstruction (Figures 1 and 2).

Bronchoscopy was then performed under general anaesthesia. Diazepam (0.2 mg/kg IV) was used as a

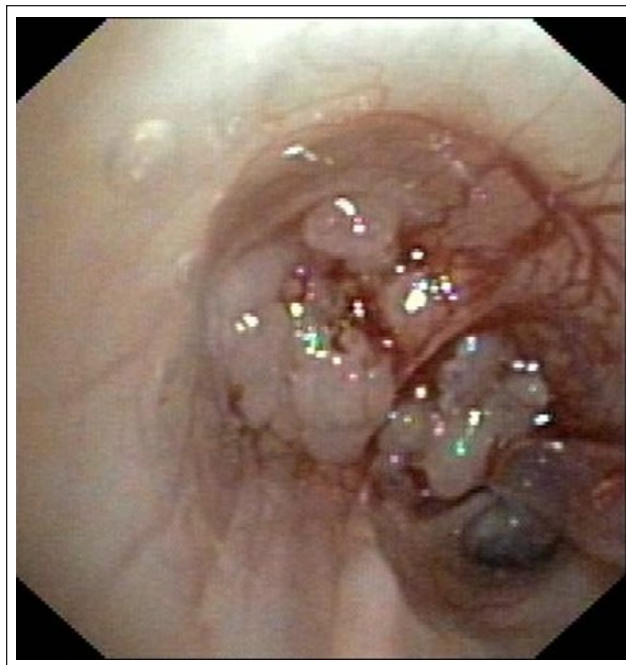

Figure 3 First bronchoscopy. A broad-based carina mass occluding approximately 90% of the airway lumen

premedication, and anaesthesia was induced and maintained with propofol boluses to effect (up to 4 mg/kg). Bronchoscopy was performed with a 5.5 mm diameter insertion tube (Video Endoscope BF-Q180; Olympus). An irregular, multi-lobulated, intraluminal broad-based mass in the region of the carina was identified, which was occluding approximately 90% of the airway lumen (Figure 3). First, a 3.3 mm semi-rigid urinary catheter was introduced through the centre of the mass to provide oxygen delivery. Surgical resection of the mass was not possible, owing to the size and its location on the carina. The mass was extremely friable, allowing it to be partially resected via aspiration using the lateral hole of the urinary catheter and aided by a surgical vacuum. After this procedure, the luminal diameter at the carina was restored to approximately 95% of the normal diameter (Figure 4), providing an immediate improvement in respiratory efforts. Dexamethasone (0.2 mg/kg IV) and buprenorphine (0.015 mg/kg IV) were administered after this procedure. The cat recovered unremarkably from anaesthesia, and was discharged the following day. Prednisolone was prescribed at home (2 mg/kg q24h PO, tapered over 4 weeks).

Histological examination from the tracheobronchial mass was consistent with a well-differentiated tracheobronchial adenocarcinoma. Adjuvant chemotherapy was then initiated using five three-weekly cycles of doxorubicin at a dose of 1 mg/kg via slow intravenous infusion. The cat remained asymptomatic for 1 year following the initial bronchoscopic resection, at which point the cat

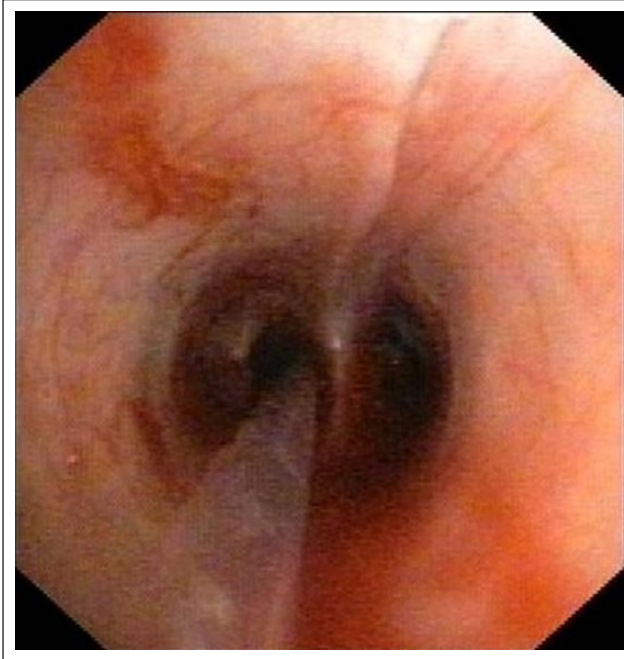


Figure 4 First bronchoscopy. Carina luminal diameter restored to approximately 95% of normal, after endoscopic aspiration of the mass

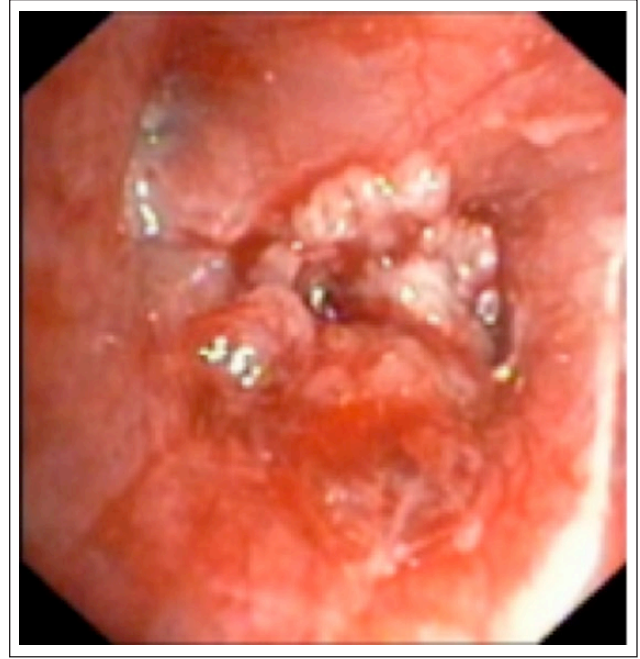


Figure 5 Second bronchoscopy. Relapse of right main bronchi obstruction by the tumour

relapsed with the same clinical signs that were seen on initial presentation. Thoracic radiographs were carried out at this time and pulmonary hyperinflation was again present and there was no evidence of metastatic disease. The second bronchoscopy showed a relapse of the tumour at the level of the right main bronchi where it was placed previously (Figure 5). A second bronchoscopic debulking of this mass was performed as previously described; however, only a partial resection was achieved (approximately 60% of the lumen was restored, leaving 40% of the mass) (Figure 6). A marked improvement in the cat's clinical signs was observed following the procedure and the cat was discharged the same day with oral prednisolone (same protocol used).

Three months later the cat represented again with severe respiratory distress. A relapse of the tumour in the carina was observed during the third bronchoscopy and a third endoscopic aspiration of the tumour was performed, restoring approximately 50% of the bronchial lumen. While the cat's clinical signs initially resolved the cat's respiratory signs returned 1 month later. Given the short time between the third procedure and relapse and the cat's poor long-term prognosis, the owners requested euthanasia.

Discussion

Primary tracheal neoplasms are uncommon in cats, dogs and humans.¹⁻⁵ In people, primary tracheal tumours account for 0.1–0.4% of all malignant diseases.⁹ There is some disagreement regarding the sex of cats most

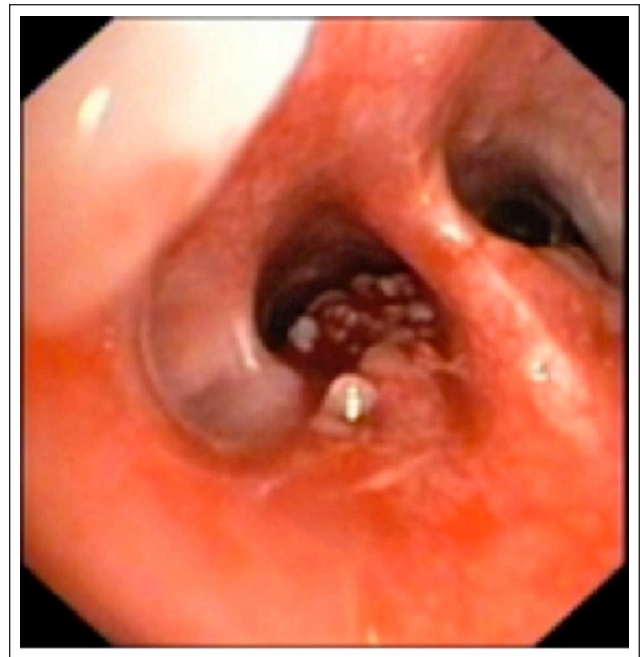


Figure 6 Second bronchoscopy. Carina lumen after partial endoscopic aspiration of the tumour

frequently diagnosed with tracheal tumours, with spayed females most commonly affected in one study,¹ whereas another study reported equal distribution between the sexes,³ and yet another showed an increased incidence in male cats.¹⁰ The median age of cats diagnosed with a

tracheal mass was 12.0 years (range 6–20 years).¹ This is consistent with that previously described (>8 years).^{3,10} In 2005, Jakubiak et al observed that Siamese cats were more likely to be diagnosed with lymphoma, whereas domestic longhair cats were more likely to be diagnosed with adenocarcinomas and lymphoma.¹ However, these breed correlations were based on a small number of cats and previous retrospective studies of tracheal masses have not identified a breed predisposition for the different tumour types.^{3,10}

The most common presenting complaints and clinical signs reported were respiratory difficulty (63%) and dysphonia (55.6%), the latter mainly seen when in the presence of laryngeal involvement as an extension from the proximal tracheal mass.^{1,2,11} Jakubiak et al found that soft tissue opacities on cervical radiographs were significant indicators of neoplasia.¹ In previous reports of tracheal masses in dogs and cats, radiographic findings had no correlation with a specific tumour type.^{3,10,12,13} It is widely recognised that further investigations, such as direct tracheobronchial examination or CT, should be performed in every case of a suspected airway obstruction. If a mass or abnormal-looking lesion is identified, a fine-needle aspiration and/or a biopsy are indicated. However, Janubiak et al reported five cases of misdiagnosis following cytological examination from fine-needle aspiration of tracheal masses as benign inflammation that subsequently changed to neoplastic disease upon further histological examination.¹

Optimal treatment for non-lymphomatous tracheal malignancies in human medicine involves surgical resection and anastomosis.⁷ Multimodal non-surgical treatment (radiotherapy, chemotherapy and cyclooxygenase 2 inhibitor) has been described in a feline tracheal adenocarcinoma leading to a long-term outcome (755 days).⁵ In this case, a surgical resection and anastomosis or radiotherapy was impossible owing to the particular location of the mass in the carina and the wide extent of the tumour.

In human medicine, 20–30% of patients with lung cancer experience central airway obstruction by invasion of the trachea, carina and/or main bronchi.⁸ During the past two decades, several relatively non-invasive and effective bronchoscopic interventions have replaced surgical excision for the treatment of symptomatic central airway obstruction in humans.⁶ Several techniques have been developed such as laser, brachytherapy, phototherapy, cryotherapy, electrocautery, balloon dilation and airway stenting.⁶ In veterinary medicine these techniques are in their infancy: only one dog with bronchial carcinoma treated by bronchoscopic electrocautery, and one case series of three cats with tracheal carcinoma treated by bronchoscopic debulking using cup biopsy forceps and a two-wire snare, have been described.^{2,14} In this case series of cats, only one had repeated endoscopic debulking allowing clinical remission for another 9 months.¹⁴

Survival times were variable in the studies published above with the dog surviving only 1 month post-diagnosis and the cats surviving 9 months, 6 months and 5 weeks, respectively.^{2,14} Given the excellent results observed in humans with tracheal tumours, laser therapy could be an effective technique for treating intra-luminal airway obstruction, although access to appropriate equipment, its cost and the small size of the feline respiratory tract could limit the implementation of this methodology.^{15,16}

Adjuvant chemotherapy to surgical resection is advised in the veterinary literature, to provide long-term control of the residual local disease and any distant metastasis.¹⁷

In this case, bronchoscopic aspiration of the tumour by a urinary catheter was well tolerated, minimally invasive, without important complications (mild haemorrhage) and affordable for clients. The cat survived 16 months after three endoscopic debulkings and adjuvant chemotherapy.

Conclusions

Bronchoscopic aspiration of a central airway obstruction by a urinary catheter is a relatively simple, non-invasive, safe and affordable means of palliating airway tumours in cats. Interventional bronchoscopy is an important tool for the diagnosis and treatment of human tracheobronchial tumours, and will probably be the case for veterinary medicine in the future.

Acknowledgements The authors thank Dr Eymeric Gomes for diagnostic imaging assistance.

Conflict of interest The authors declared no potential conflicts of interest with respect to the research, authorship, and/or publication of this article.

Funding The authors received no financial support for the research, authorship, and/or publication of this article.

References

- Jakubiak MJ, Siedlecki CT, Zenger E, et al. **Laryngeal, laryngotracheal, and tracheal masses in cats: 27 cases (1998–2003).** *J Am Anim Hosp Assoc* 2005; 41: 310–316.
- Queen EV, Vaughan MA and Johnson LR. **Bronchoscopic debulking of tracheal carcinoma in 3 cats using a wire snare.** *J Vet Intern Med* 2010; 24: 990–993.
- Carlisle CH, Biery DN and Thrall DE. **Tracheal and laryngeal tumors in the dog and cat: literature review and 13 additional patients.** *Vet Radiol* 1991; 32: 229–235.
- Drynan EA, Moles AD and Rasis AL. **Anaesthetic and surgical management of an intra-tracheal mass in a cat.** *J Feline Med and Surg* 2011; 13: 460–462.
- Azevedo C, Brawner W, Schleis Lindley S, et al. **Multimodal non-surgical treatment of a feline tracheal adenocarcinoma.** *JFMS Open Rep* 2017; 3: DOI: 10.1177/2055116916689630.

- 6 Brodsky JB. **Bronchoscopic procedures for central airway obstruction.** *J Cardiothorac Vasc Anesth* 2003; 17: 638–646.
- 7 Ahn Y, Chang H, Lim YS, et al. **Primary tracheal tumors: review of 37 cases.** *J Thorac Oncology* 2009; 4: 635–638.
- 8 Guibert N, Mazieres J, Lepage B, et al. **Prognostic factors associated with interventional bronchoscopy in lung cancer.** *Ann Thorac Surg* 2014; 97: 253–259.
- 9 Machiarini P. **Primary tracheal tumors.** *Lancet Oncol* 2006; 7: 83–91.
- 10 Saik JE, Toll SL, Deters RW, et al. **Canine and feline laryngeal neoplasia: a 10-year survey.** *J Am Anim Hosp Assoc* 1986; 22: 359–365.
- 11 Venker-van Haagen AJ. **Diseases of the larynx.** *Vet Clin North Am Small Anim Pract* 1992; 22: 1155–1172.
- 12 Costello MF, Keith D, Hendrick M, et al. **Acute upper airway obstruction due to inflammatory laryngeal disease in 5 cats.** *J Vet Emerg Crit Care* 2001; 11: 205–210.
- 13 Tasker S, Foster DJ, Corcoran BM, et al. **Obstructive inflammatory laryngeal disease in three cats.** *J Feline Med Surg* 1999; 1: 53–59.
- 14 Mosing M, Iff I and Moens Y. **Endoscopic removal of a bronchial carcinoma in a dog using one-lung ventilation.** *Vet Surg* 2008; 37: 222–225.
- 15 Tsukada H, Inoue H and Osada H. **Re-epithelialization after laser therapy of a stenotic artificial tracheal graft: a pilot experimental study.** *Surg Today* 2008; 38: 672–674.
- 16 Bartels KE. **Lasers in veterinary medicine – where have we been, and where are we going?** *Vet Clin North Am Small Anim Pract* 2002; 32: 495–515.
- 17 Clements DN, Hogan AM and Cave TA. **Treatment of a well differentiated pulmonary adenocarcinoma in a cat by pneumonectomy and adjuvant mitoxantrone chemotherapy.** *J Feline Med Surg* 2004; 6: 199–205.