



## **Lameness, generalised myopathy and myalgia in an adult cat with toxoplasmosis**

Authors: Butts, Daniel R, and Langley-Hobbs, Sorrel J

Source: Journal of Feline Medicine and Surgery Open Reports, 6(1)

Published By: SAGE Publishing

URL: <https://doi.org/10.1177/2055116920909668>

---

BioOne Complete ([complete.BioOne.org](https://complete.BioOne.org)) is a full-text database of 200 subscribed and open-access titles in the biological, ecological, and environmental sciences published by nonprofit societies, associations, museums, institutions, and presses.

Your use of this PDF, the BioOne Complete website, and all posted and associated content indicates your acceptance of BioOne's Terms of Use, available at [www.bioone.org/terms-of-use](https://www.bioone.org/terms-of-use).

Usage of BioOne Complete content is strictly limited to personal, educational, and non - commercial use. Commercial inquiries or rights and permissions requests should be directed to the individual publisher as copyright holder.

---

BioOne sees sustainable scholarly publishing as an inherently collaborative enterprise connecting authors, nonprofit publishers, academic institutions, research libraries, and research funders in the common goal of maximizing access to critical research.



# Lameness, generalised myopathy and myalgia in an adult cat with toxoplasmosis

Daniel R Butts  and Sorrel J Langley-Hobbs 

*Journal of Feline Medicine and Surgery Open Reports*  
1–6

© The Author(s) 2020

Article reuse guidelines:

sagepub.com/journals-permissions

DOI: 10.1177/2055116920909668

journals.sagepub.com/home/jfmsopenreports

This paper was handled and processed by the European Editorial Office (ISFM) for publication in *JFMS Open Reports*



## Abstract

**Case summary** A 2-year-old female neutered domestic shorthair cat presented with an 18-month history of intermittent lameness on all four limbs. The cat was markedly lame on all four limbs. There was alternation between toe-walking on the forelimbs with a hunched posture and using the dorsal aspect of the carpi to walk on. The cat would hiss repeatedly when walking and would lie down tentatively, appearing happier and less painful when lying. When not lying, the cat preferred to sit back on the hindlimbs and non-weightbear on the forelimbs (the so-called kangaroo stance). Physical examination detected pain on palpation of the calcaneus bone and Achilles tendon bilaterally, and general resentment to handling. Investigations revealed an elevated creatine kinase, a positive *Toxoplasma gondii* IgG titre, toxic neutrophilic inflammation within the Achilles tendon bursae, electromyography and nerve conduction velocity studies consistent with a diffuse muscular disease, and histopathology of the muscle consistent with a chronic and diffuse myopathy. Arthrocentesis samples and an antinuclear antibodies titre were normal. Prior treatment with meloxicam had been ineffective. A 6-week course of clindamycin was prescribed; an improvement was seen within 3 days and clinical resolution at 3 months. The cat remained clinically normal after 20 months.

**Relevance and novel information** To our knowledge, there have been no previously published reports of histopathologically confirmed myopathy as a result of *T gondii* in cats. This report suggests toxoplasmosis should be considered as a differential diagnosis in cats with myopathies or lameness in the absence of other causes.

**Keywords:** Toxoplasma; toxoplasmosis; protozoan infections; myositis; myalgia; bursitis

**Accepted:** 27 January 2020

## Introduction

*Toxoplasma gondii* is an obligate intracellular protozoan parasite that can infect virtually all warm-blooded animals.<sup>1</sup> Cats and other Felidae are the definitive hosts, while other animals act as intermediate hosts.<sup>1,2</sup> Infection can occur congenitally or via ingestion of infected tissue or sporulated oocysts passed by cats.<sup>3</sup> Following ingestion of sporulated oocysts, sporozoites excyst in the intestinal lumen and penetrate the intestinal cells.<sup>3</sup> Sporozoites divide into tachyzoites, which can multiply in almost any cell of the body, eventually encysting to become tissue cysts containing bradyzoites.<sup>3</sup>

Clinical findings in cats are varied, ranging from general signs such as lethargy, fever, inappetence, weight loss, vomiting and diarrhoea, to more specific respiratory, ocular or neurological manifestations.<sup>4</sup> Myocarditis

as a result of *T gondii* has also been reported in a cat.<sup>5</sup> Polymyositis as a result of toxoplasmosis is recognised in humans,<sup>6,7</sup> and is also reported in dogs.<sup>8,9</sup> *Toxoplasma gondii* has been described as a potential cause of myopathy in cats,<sup>4,10,11</sup> and has been identified histologically within skeletal muscle.<sup>12</sup> Lappin et al<sup>13</sup> reported muscle pain in 3/15 cats diagnosed with *T gondii*, although there was no histopathology confirming a myopathy in those cases. To our knowledge, there have been no previously

Langford Veterinary Services, University of Bristol, Bristol, UK

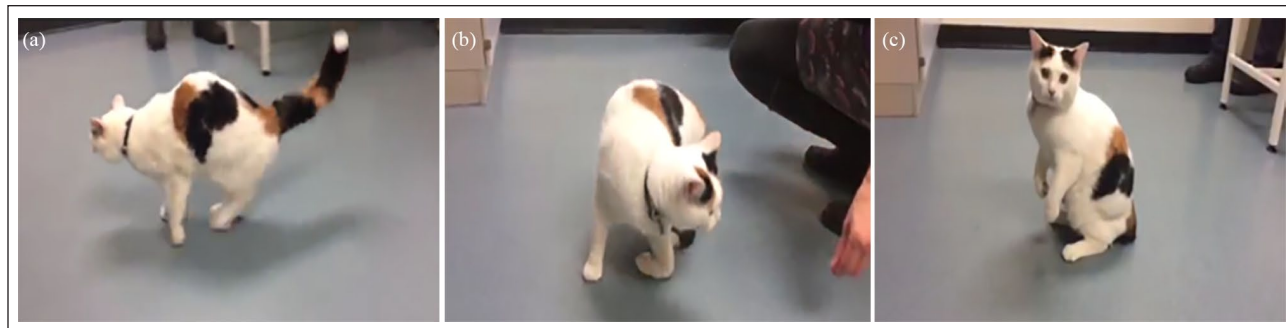### Corresponding author:

Daniel R Butts BVetMed(Hons), MRCVS, Langford Veterinary Services, Langford House, Langford, Bristol BS40 5DU, UK  
Email: mm19334@bristol.ac.uk



Creative Commons Non Commercial CC BY-NC: This article is distributed under the terms of the Creative Commons

Attribution-NonCommercial 4.0 License (<https://creativecommons.org/licenses/by-nc/4.0/>) which permits non-commercial use, reproduction and distribution of the work without further permission provided the original work is attributed as specified on the SAGE and Open Access pages (<https://us.sagepub.com/en-us/nam/open-access-at-sage>).



**Figure 1** (a) Toe-walking on the left forelimb with hunched posture. (b) Weightbearing on the dorsal aspect of the left carpus. (c) Sitting back on the hindlimbs and non-weightbearing on the forelimbs

published reports of histopathologically confirmed myopathy as a result of *T gondii* in cats.

### Case description

A 2-year-old female neutered domestic shorthair cat presented with a 6-month history of an intermittent bilateral forelimb lameness, an intermittent 'bunny-hopping' hindlimb gait, difficulty with use of stairs and jumping and occasional vocalisation suspected to be pain-related. The gait was worse following rest and improved with walking. Eighteen months prior to presentation, there had been a period of right hindlimb lameness followed by a period of left hindlimb lameness that later resolved. The cat had been in the owner's possession since the age of 12 weeks, had not left the UK, had outdoor access and was fed a complete commercial cat food. Meloxicam (0.05 mg/kg PO q24h [Metacam; Boehringer Ingelheim]) had been used intermittently for several months prior to presentation but with limited effect.

On initial presentation to the neurology department, there was a right forelimb lameness at rest, which improved with walking. A mild medial patellar luxation was palpable bilaterally. Neurological examination detected a normal gait with normal postural reactions, normal spinal reflexes, normal cranial nerve testing and no pain on spinal palpation. The cat was discharged with a further course of 0.05 mg/kg meloxicam PO q24h and restricted activity was advised.

On follow-up examination with the orthopaedic department 8 weeks later, the cat was markedly lame on all four limbs but particularly on the forelimbs. There was alternation between toe-walking on the forelimbs with a hunched posture and using the dorsal aspect of the carpi to walk on (Figure 1a,b). The cat would hiss repeatedly when walking and would lie down tentatively, appearing happier and less painful when lying down. When not lying down, the cat preferred to sit back on the hindlimbs and non-weightbear on the forelimbs (Figure 1c; so-called kangaroo stance). A source of pain could not be localised on the forelimbs, but there was a repeatable pain response to palpation around the

calcaneus bone and insertion of the Achilles tendon bilaterally. Differential diagnoses included a diffuse neuromuscular disease, an autoimmune disease such as systemic lupus erythematosus or polyarthritis, or an infectious disease such as toxoplasmosis.

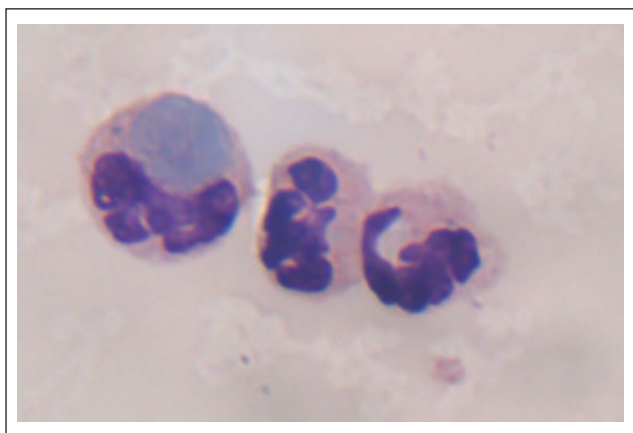
Haematology was unremarkable. Serum biochemistry revealed a mild elevation in creatine kinase (237 U/l; reference interval [RI] 50–150 U/l) but was otherwise unremarkable. Serology for feline leukaemia virus and feline immunodeficiency virus (FIV) was negative. Serology for antinuclear antibodies (ANA) and *T gondii* IgG and IgM were pending.

The cat was sedated with 5 µg/kg dexmedetomidine (Dexdomitor; Zoetis) intravenously (IV) and 0.02 mg/kg buprenorphine (Buprecare; Animalcare) IV with a top-up of propofol (Propoflo Plus; Zoetis) IV to effect. Radiographs of the elbows and antebrachii were unremarkable. Radiographs of the tarsi revealed a small spur of bone projecting distally from the plantar aspect of the flexor surface of the left calcaneus, slight undulation to the plantar surface of the proximal calcaneal tuberosity bilaterally, and mild soft tissue swelling over the point of the calcaneal tuberosity and distal calcaneus and Achilles tendon bilaterally. These changes were considered mild and non-specific. Arthrocentesis of the left stifle, left shoulder, left carpus and left tarsus was unremarkable. A sample of bursal fluid from the right Achilles tendon revealed neutrophilic inflammation with intracytoplasmic inclusions suspected to be lupus cells or Döhle bodies (Figure 2). Sedation was reversed with 50 µg/kg atipamezole (Antisedan; Zoetis) intramuscularly.

The cat was hospitalised prior to further investigations and received 0.02 mg/kg buprenorphine IV q6–8h and 0.05 mg/kg meloxicam PO q24h. There was no improvement with this treatment.

Anaesthesia was induced with propofol IV to effect, following a premedication of 0.2 mg/kg methadone (Methadyne; Jurox) IV and 5 µg/kg dexmedetomidine IV and was maintained with isoflurane (IsoFlo; Zoetis) and oxygen. Cefuroxime 20 mg/kg (Zinacef; GlaxoSmithKline) IV was provided perioperatively. Nerve conduction

velocity (NCV) studies of the left tibial motor nerve, left ulnar motor nerve and left tibial sensory nerves were within normal limits. All F wave latencies were within normal limits. Sensory nerve studies were also normal. Electromyography (EMG) of the left flexor carpi ulnaris, left biceps, left supraspinatus, left gastrocnemius, left cranial tibial and left middle gluteal muscles showed increased insertional activity. The left extensor carpi radialis longus, left deltoid and the left triceps muscle showed increased spontaneous activity. The left supraspinatus muscle showed increased insertional activity and slightly increased spontaneous activity. The left palmar interossei, left semimembranosus, left biceps femoris and left quadriceps muscles showed no evidence of electrical instability.



**Figure 2** Neutrophil containing a duck egg blue cytoplasmic inclusion (far left) seen on cytology of Achilles tendon bursal fluid (suspected to be a lupus cell or Döhle body)

NCV and EMG findings were consistent with a diffuse muscular disease, worse in the proximal thoracic limb and distal pelvic limb muscles. An axonopathy without secondary myelin disturbance was considered less likely. Results from the EMG are summarised in Table 1. A sample of fluid taken from the left Achilles tendon bursa was consistent with findings from the contralateral side: neutrophilic inflammation with intracytoplasmic inclusions suspected to be lupus cells or Döhle bodies. Biopsies were taken from the right infraspinatus, right triceps brachii, right extensor carpi radialis, right cranial tibialis and right gastrocnemius muscles and submitted for histopathology and *T gondii* PCR. The cat was discharged from hospital with 0.05 mg/kg meloxicam PO q24h while results were pending.

*T gondii* serology using an immunofluorescent antibody assay returned with a markedly elevated IgG titre of 1:1600 (RI <1:50) and borderline IgM titre of 1:25 (RI <1:25). ANA titre was negative. Clindamycin (Antirobe; Zoetis) was started at 19.2 mg/kg PO q12h and the course of 0.05 mg/kg meloxicam PO q24h continued. Histopathology of each muscle biopsy revealed a diffuse, chronic, moderate myopathy with some myofibre resorption. There was no evidence of *T gondii* DNA on PCR testing of the right triceps brachii muscle.

An improvement was seen within 3 days of starting the clindamycin. *T gondii* serology 2 weeks after starting the clindamycin revealed a markedly elevated IgG titre of 1:1600 and a mildly elevated IgM titre of 1:50.

The cat re-presented following a 6-week course of clindamycin. The owners reported an occasional forelimb lameness, but otherwise there had been significant improvement. The cat was more sociable, would play with the other in its home cat and had stopped vocalising.

**Table 1** Summary of the electromyography findings

| Side | Muscle                         | Nerve            | Root  | Insertional activity | Fibrillation | Positive sharp waves |
|------|--------------------------------|------------------|-------|----------------------|--------------|----------------------|
| Left | Palmar interossei              | Ulnar            | C8–T1 | Normal               | Normal       | Normal               |
| Left | Flexor carpi radialis          | Ulnar            | C8–T1 | <b>Increased</b>     | Normal       | Normal               |
| Left | Extensor carpi radialis longus | Radial           | C7–T1 | Normal               | <b>2+</b>    | <b>1+</b>            |
| Left | Triceps                        | Radial           | C7–T1 | Normal               | <b>1+</b>    | Normal               |
| Left | Deltoid                        | Axillary         | C7–8  | Normal               | <b>2+</b>    | Normal               |
| Left | Biceps                         | Musculocutaneous | C6–8  | <b>Increased</b>     | Normal       | Normal               |
| Left | Supraspinatus                  | Suprascapular    | C6–7  | <b>Increased</b>     | Normal       | Normal               |
| Left | Infraspinatus                  | Suprascapular    | C6–7  | <b>Increased</b>     | <b>1+</b>    | Normal               |
| Left | Plantar interossei             | Tibial           | L6–S2 | Normal               | <b>2+</b>    | Normal               |
| Left | Gastrocnemius                  | Tibial           | L6–S2 | <b>Increased</b>     | Normal       | Normal               |
| Left | Cranial tibial                 | Common peroneal  | L6–S2 | <b>Increased</b>     | Normal       | Normal               |
| Left | Semimembranosus                | Sciatic          | L6–S2 | Normal               | Normal       | Normal               |
| Left | Biceps femoris                 | Sciatic          | L6–S2 | Normal               | Normal       | Normal               |
| Left | Middle gluteal                 | Cranial gluteal  | L6–S1 | <b>Increased</b>     | Normal       | Normal               |
| Left | Quadriceps                     | Femoral          | L4–6  | Normal               | Normal       | Normal               |

Increased values in bold



On examination, the cat was walking relatively normally. There was no toe-walking, no walking on the dorsal aspect of the carpi and no sitting back on the hindlimbs. There was mild enlargement of the Achilles tendon bursae, more so on the right, with some resentment on palpation. An ophthalmological examination detected a small chorioretinal scar that could be compatible with a toxoplasmosis lesion; there was no evidence of active lesions and no ophthalmic nerve pathology. The clindamycin was stopped, and meloxicam continued at the same dose for a further 3 weeks. *T gondii* serology repeated 13 weeks after finishing the clindamycin revealed a positive IgG titre of 1:400 and a normal IgM titre of 1:20.

The cat was presented for a follow-up examination 20 months after the cessation of treatment. The owners reported there was full resolution of clinical signs 3 months from the start of the clindamycin. The cat had not received any medication since that time and there had been no recurrence of clinical signs. On examination, the gait was normal with no signs of lameness (see video 1 in the supplementary material). The cat could jump up and down from a chair and consultation table normally (see video 2 in the supplementary material). There was mild irregularity on palpation of the point of the calcaneus bilaterally, but no swelling of the Achilles tendon bursae and no patellar luxation. The remainder of the physical examination was unremarkable.

## Discussion

This case report describes the successful treatment of a young adult cat with a generalised myopathy suspected to be caused by toxoplasmosis. Differential diagnoses for acquired generalised myopathies in cats include immune-mediated polymyositis, infectious polymyopathy, hypokalaemic polymyopathy, vitamin E deficiency and hypernatremia secondary to hypodipsia.<sup>14</sup> Inherited myopathies in cats may be caused by muscular dystrophies, nemaline myopathy, myositis ossificans, myotonia congenita and glycogen storage diseases.<sup>14</sup> There has also been a report of three cases of polymyositis in 11 cats diagnosed with a thymoma.<sup>15</sup>

The standard diagnostic criteria for an inflammatory myopathy include the presence of compatible clinical signs, an elevated creatine kinase, EMG documenting muscle membrane instability and histopathological evidence of muscle inflammation.<sup>16</sup> A lack of identifiable cause is required to diagnose an immune-mediated polymyositis.<sup>17</sup> There are limited reports identifying infectious causes of myopathies in cats. Poonacha et al<sup>18</sup> described a case of myositis affecting the diaphragmatic, pectoral, intercostal and ventral abdominal wall muscles in a 6-month-old female cat; the myositis was identified on necropsy and *Clostridium chauvoei* and *Clostridium septicum* were detected on direct fluorescent antibody testing. Myopathy has also been identified

histopathologically in six adult cats infected experimentally with FIV.<sup>19</sup> Jokelainen et al<sup>12</sup> identified *T gondii* on immunohistochemical staining of skeletal muscle in two cats with generalised toxoplasmosis submitted for necropsy; one also had *T gondii* identified histologically. Muscle pain has been reported in 3/15 cats that were diagnosed with toxoplasmosis based on serology, clinical signs and response to clindamycin;<sup>13</sup> however, there was no histopathology performed on those cases to confirm a myopathy. In general, a myopathy does not appear to be a typical manifestation of toxoplasmosis in cats.<sup>20</sup> In contrast, myopathy is frequently associated with toxoplasmosis in dogs. Evans et al<sup>8</sup> detected positive serological *T gondii* titres in 16/51 dogs diagnosed with inflammatory myopathy, five of which recovered fully with clindamycin treatment alone. There are also many case reports of polymyositis associated with *T gondii* in the human literature.<sup>6,7,21</sup>

This case met the diagnostic criteria for an inflammatory myopathy as described by Podell;<sup>16</sup> the cat had an abnormal gait with lameness on all four limbs, an elevated creatine kinase, an EMG consistent with a diffuse muscular disease and histopathology consistent with a diffuse and chronic myopathy.

A tentative ante-mortem diagnosis of *T gondii* can be made based on: serological evidence of recent or active infection consisting of high IgM titres, or a four-fold or greater increase or decrease in IgG titres after treatment; exclusion of other aetiologies; and clinical improvement following an anti-*Toxoplasma* drug.<sup>3</sup>

Serology detected a borderline IgM titre but a strong positive IgG titre prior to treatment. Following treatment, the IgM titre was normal and the IgG titre decreased four-fold. IgM may appear earlier in the disease but declines more rapidly than IgG antibodies, which usually persist for life.<sup>22</sup> Therefore, a positive IgM is not necessary for diagnosis; a normal IgM with positive IgG can indicate either previous exposure or a current infection. Lindsay et al<sup>23</sup> described a case of spinal cord toxoplasmosis in a cat with a positive IgG titre of 1:512 but a normal IgM titre; *T gondii* was confirmed via identification on immunohistochemistry staining on post-mortem samples taken from the spinal cord containing ruptured protozoal cysts.

*T gondii* organisms were not identified on histopathology and PCR was negative; however, PCR was only performed on the right triceps brachii muscle biopsy. Montoya et al<sup>24</sup> have previously discussed the potential for a reduction in *T gondii* PCR sensitivity as a result of the low number of tissue cysts, sparsity of parasites and their focal distribution in the tissues. Similarly, Evans et al<sup>8</sup> did not identify any *T gondii* organisms on histopathology in five dogs they diagnosed with generalised myopathy as a result of *T gondii*.

With regard to the alternative differential diagnoses, systemic lupus erythematosus, polyarthritis and

neurological disease are unlikely given the negative ANA titre, unremarkable arthrocentesis samples and normal NCVs, respectively. The neutrophilic intracytoplasmic inclusions detected in the fluid from the Achilles tendon bursae are more likely to be Döhle bodies rather than lupus cells given the negative ANA titre. Döhle bodies are aggregates of endoplasmic reticulum and appear as grey-blue cytoplasmic precipitates; they are common in cats and are a type of neutrophilic toxic change associated with inflammation or infection.<sup>25</sup> To our knowledge, bursitis is not a feature of toxoplasmosis that has previously been reported in the veterinary or human literature.

A variety of treatment options exist for feline toxoplasmosis including clindamycin, trimethoprim-sulfonamide and azithromycin.<sup>3</sup> Clindamycin is the most commonly used treatment within the literature with successful outcomes reported for a variety of manifestations of the disease. Cuoç et al<sup>26</sup> used clindamycin to successfully treat 20/22 cats with ocular or neurological forms of *T gondii*. Simpson et al<sup>5</sup> reports its success in a case of a myocarditis suspected to be caused by *T gondii*. Dubey and Prowell<sup>27</sup> used it to successfully treat a cat with anorexia, lethargy, diarrhoea and respiratory difficulty associated with *T gondii*.

In this case, there was an improvement within 3 days of starting clindamycin and complete resolution of clinical signs 3 months following the initiation of therapy, which further supports the diagnosis. Meloxicam was used alongside clindamycin throughout the entirety of the course; however, there had been very limited, if any, improvement with the use of meloxicam alone for a prolonged period prior to starting the clindamycin. This case supports the use of clindamycin to treat a myopathy caused by *T gondii* in cats. Lappin et al<sup>13</sup> also reported resolution of *T gondii* with the use of clindamycin in the three cats exhibiting muscle pain. Clindamycin has also been used to successfully treat myopathies caused by *T gondii* in dogs.<sup>8</sup>

## Conclusions

This case met criteria supportive for the diagnosis of an inflammatory myopathy and that of toxoplasmosis. These criteria, in addition to the rapid improvement and eventual resolution of clinical signs following administration of clindamycin, are strongly supportive of toxoplasmosis as a cause for the myopathy. This case highlights the need to consider *T gondii* as a differential diagnosis in cases of myopathies in cats and toxoplasmosis should be considered as a differential diagnosis for lameness in cats in the absence of other causes.

**Conflict of interest** The authors declared no potential conflicts of interest with respect to the research, authorship, and/or publication of this article.

**Funding** The authors received no financial support for the research, authorship, and/or publication of this article.

**Ethical approval** This work involved the use of non-experimental animals only (owned or unowned), and followed internationally recognised high standards ('best practice') of individual veterinary clinical patient care. Ethical approval from a committee was not therefore needed.

**Informed consent** Informed consent (either verbal or written) was obtained from the owner or legal custodian of all animal(s) described in this work for the procedure(s) undertaken. For any animals or humans individually identifiable within this publication, informed consent for their use in publication (verbal or written) was obtained from the people involved.

**ORCID iDs** Daniel R Butts  <https://orcid.org/0000-0003-1564-1372>

Sorrel J Langley-Hobbs  <https://orcid.org/0000-0003-4397-5150>

## Supplementary material

The following files are available online: Video 1: The normal gait of the cat, with no signs of lameness, 20 months after the cessation of treatment for toxoplasmosis. Video 2: The normal jumping ability of the cat 20 months after the cessation of treatment for toxoplasmosis.

## References

- 1 Taylor M, Coop R and Wall R. **Parasites of dogs and cats.** In: Taylor M, Coop R and Wall R (eds). *Veterinary parasitology*. 4th ed. Chichester: Wiley Blackwell, 2016, pp 599–677.
- 2 Calero-Bernal R and Gennari S. **Clinical toxoplasmosis in dogs and cats: an update.** *Front Vet Sci* 2019; 6. DOI: 10.3389/fvets.2019.00054.
- 3 Dubey J, Lindsay D and Lappin M. **Toxoplasmosis and other intestinal coccidial infections in cats and dogs.** *Vet Clin North Am Small Anim Pract* 2009; 39: 1009–1034.
- 4 Dubey JP and Lappin MR. **Toxoplasmosis and neosporosis.** In: Greene CE (ed). *Infectious diseases of the dog and cat*. 4th ed. Philadelphia, PA: Elsevier Saunders, 2012, pp 806–827.
- 5 Simpson K, Devine B and Gunn-Moore D. **Suspected *Toxoplasma*-associated myocarditis in a cat.** *J Feline Med Surg* 2005; 7: 203–208.
- 6 Cuomo G, D'Abrosca V, Rizzo V, et al. **Severe polymyositis due to *Toxoplasma gondii* in an adult immunocompetent patient: a case report and review of the literature.** *Infection* 2013; 41: 859–862.
- 7 Hassene A, Vital A, Anghel A, et al. **Acute acquired toxoplasmosis presenting as polymyositis and chorioretinitis in immunocompetent patient.** *Joint Bone Spine* 2008; 75: 603–605.
- 8 Evans J, Levesque D and Shelton GD. **Canine inflammatory myopathies: a clinicopathologic review of 200 cases.** *J Vet Intern Med* 2004; 18: 679–691.
- 9 Suter M, Hauser B, Palmer D, et al. **Polymyositis–polyradiculitis due to toxoplasmosis in the dog: serology and tissue biopsy as diagnostic aids.** *Zentralbl Veterinarmed A* 1984; 31: 792–798.

- 10 Dickinson PJ and LeCouteur RA. **Feline neuromuscular disorders.** *Vet Clin North Am Small Anim Pract* 2004; 34: 1307–1359.
- 11 Taylor S. **Selected disorders of muscle and the neuromuscular junction.** *Vet Clin North Am Small Anim Pract* 2000; 30: 59–75.
- 12 Jokelainen P, Simola O, Rantanen E, et al. **Feline toxoplasmosis in Finland: cross-sectional epidemiological study and case series study.** *J Vet Diagn Invest* 2012; 24: 1115–1124.
- 13 Lappin M, Green C, Winston S, et al. **Clinical feline toxoplasmosis. Serological diagnosis and therapeutic management of 15 cases.** *J Vet Intern Med* 1989; 3: 139–143.
- 14 LeCouteur R. **Update on feline neuromuscular diseases.** *J Feline Med Surg* 2003; 5: 109–115.
- 15 Carpenter J and Holzworth J. **Thymoma in 11 cats.** *J Am Vet Med Assoc* 1982; 181: 248–251.
- 16 Podell M. **Inflammatory myopathies.** *Vet Clin North Am Small Anim Pract* 2002; 32: 147–167.
- 17 Volk H, Shihab N and Matiase K. **Neuromuscular disorders in the cat. Clinical approach to weakness.** *J Feline Med Surg* 2011; 13: 837–849.
- 18 Poonacha K, Donahue J and Leonard W. **Clostridial myositis in a cat.** *Vet Pathol* 1982; 19: 217–219.
- 19 Podell M, Chen E and Shelton GD. **Feline immunodeficiency virus associated myopathy in the adult cat.** *Muscle Nerve* 1998; 21: 1680–1685.
- 20 Dubey JP and Carpenter JL. **Histologically confirmed clinical toxoplasmosis in cats: 100 cases (1952–1990).** *J Am Vet Med Assoc* 1993; 203: 1556–1566.
- 21 Montoya J, Jordan R, Lingamneni S, et al. **Toxoplasmic myocarditis and polymyositis in patients with acute acquired toxoplasmosis diagnosed during life.** *Clin Infect Dis* 1997; 24: 676–683.
- 22 Montoya J. **Laboratory diagnosis of *Toxoplasma gondii* infection and toxoplasmosis.** *J Infect Dis* 2002; 185 Suppl 1: 73–82.
- 23 Lindsay S, Barrs V, Child G, et al. **Myelitis due to reactivated spinal toxoplasmosis in a cat.** *J Feline Med Surg* 2010; 12: 818–821.
- 24 Montoya A, Miro G, Mateo M, et al. **Detection of *Toxoplasma gondii* in cats by comparing bioassay in mice and polymerase chain reaction (PCR).** *Vet Parasitol* 2009; 160: 159–162.
- 25 Weiser G. **Interpretation of leukocyte responses in disease.** In: Thrall MA, Weiser G, Allison R, et al (eds). *Veterinary haematology and clinical chemistry*. 2nd ed. Oxford: Wiley Blackwell, 2012, pp 127–139.
- 26 Cuceş C, Ionaşcu I, Mocanu J, et al. **Neurological and ocular form of toxoplasmosis in cats.** *Sci Works C Vet Med* 2015; 61: 95–98.
- 27 Dubey J and Prowell M. **Ante-mortem diagnosis, diarrhoea, oocyst shedding, treatment, isolation, and genetic typing of *Toxoplasma gondii* associated with clinical toxoplasmosis in a naturally infected cat.** *J Parasitol* 2013; 99: 158–160.