



Subcutaneous herniation of fetuses after blunt force trauma in a cat

Authors: Collins-Webb, Alexandra G, Hanna, Ashley L, Mehrkens, Lea R, and VanderHart, Daniel J

Source: Journal of Feline Medicine and Surgery Open Reports, 6(2)

Published By: SAGE Publishing

URL: <https://doi.org/10.1177/2055116920946575>

BioOne Complete (complete.BioOne.org) is a full-text database of 200 subscribed and open-access titles in the biological, ecological, and environmental sciences published by nonprofit societies, associations, museums, institutions, and presses.

Your use of this PDF, the BioOne Complete website, and all posted and associated content indicates your acceptance of BioOne's Terms of Use, available at www.bioone.org/terms-of-use.

Usage of BioOne Complete content is strictly limited to personal, educational, and non - commercial use. Commercial inquiries or rights and permissions requests should be directed to the individual publisher as copyright holder.

BioOne sees sustainable scholarly publishing as an inherently collaborative enterprise connecting authors, nonprofit publishers, academic institutions, research libraries, and research funders in the common goal of maximizing access to critical research.



Subcutaneous herniation of fetuses after blunt force trauma in a cat

Alexandra G Collins-Webb¹ , Ashley L Hanna²,
Lea R Mehrkens¹ and Daniel J VanderHart³

Journal of Feline Medicine and Surgery Open Reports
1–4

© The Author(s) 2020

Article reuse guidelines:

sagepub.com/journals-permissions

DOI: 10.1177/2055116920946575

journals.sagepub.com/home/jfmsopenreports

This paper was handled and processed

by the American Editorial Office (AAFP)

for publication in *JFMS*



Abstract

Case summary A stray female domestic shorthair cat was presented to the emergency service after being hit by a car. The patient was recumbent and vocalizing, with a small wound over the right lateral thorax, and two palpably firm swellings in the right cervical and thoracic soft tissues. The patient was sedated and humanely euthanized to prevent further pain and suffering. Post-mortem whole-body radiographs and subsequent necropsy revealed abdominal wall rupture with herniation of two near-term fetuses within the subcutaneous tissues along the right ventrolateral thoracic wall and neck. Within the abdomen, the right uterine horn was ruptured and a third extra-luminal fetus was identified. The left uterine horn remained intact, containing a fourth fetus.

Relevance and novel information Rupture of the abdominal wall or diaphragm are well-known potential complications of blunt force trauma, such as motor vehicle accidents. While traumatic uterine rupture and diaphragmatic herniation of the gravid uterus have both been reported in the veterinary literature, abdominal wall rupture with subcutaneous fetal herniation is highly uncommon.

Keywords: Accidents; traffic; radiography; abdominal wall; hernia; fetus; subcutaneous tissue

Accepted: 30 June 2020

Case description

A female domestic shorthair cat was presented by a ‘good samaritan’ after being hit by a car. No further medical history was available, and as the patient had no microchip or collar, it was presumed to be unowned. The patient was recumbent and vocalizing in pain, with firm swellings over the right cervical and ventrolateral thoracic regions, and a small wound over the right lateral thorax. An intravenous cephalic catheter was placed and the patient was administered 3ml propofol (10mg/ml) and 3ml Beuthanasia (pentobarbital sodium and phenytoin sodium [390mg/ml, 50mg/ml]; Virbac) as per veterinarian discretion for humane euthanasia of injured and suffering patients lacking identification.

Whole body radiographs were performed post mortem (Figure 1). Estimated to be within 11 days of parturition,¹ four mineralized fetuses were present: two in the peritoneal cavity, one in the soft tissues along the right ventrolateral thoracic wall and another in the right cervical soft tissues. The regional subcutaneous tissues contained small amounts of emphysema.

Consistent with a gravid uterus, a large ovoid soft tissue structure was seen in the right caudal abdomen, causing cranial and rightwards displacement of the small intestines. The serosal margins of these intestinal segments were mildly ill-defined, possibly due to crowding or scant peritoneal fluid. The right abdominal wall margins were indistinct, with displacement of small intestine into the subcutaneous space to the level of the eleventh ribs. The remaining abdominal organs were normal in location.

¹Department of Veterinary Clinical Sciences, Oregon State University, Corvallis, OR, USA

²Department of Veterinary Clinical Sciences, Washington State University, Pullman, WA, USA

³VetRad, Cleveland, MI, USA

Corresponding author:

Alexandra G Collins-Webb DVM, Department of Veterinary Clinical Sciences, Oregon State University, Magruder Hall, 700 SW 30th Street, Corvallis, OR 97331-4081, USA
Email: colliale@oregonstate.edu



Creative Commons Non Commercial CC BY-NC: This article is distributed under the terms of the Creative Commons

Attribution-NonCommercial 4.0 License (<https://creativecommons.org/licenses/by-nc/4.0/>) which permits non-commercial use, reproduction and distribution of the work without further permission provided the original work is attributed as specified on the SAGE and Open Access pages (<https://us.sagepub.com/en-us/nam/open-access-at-sage>).

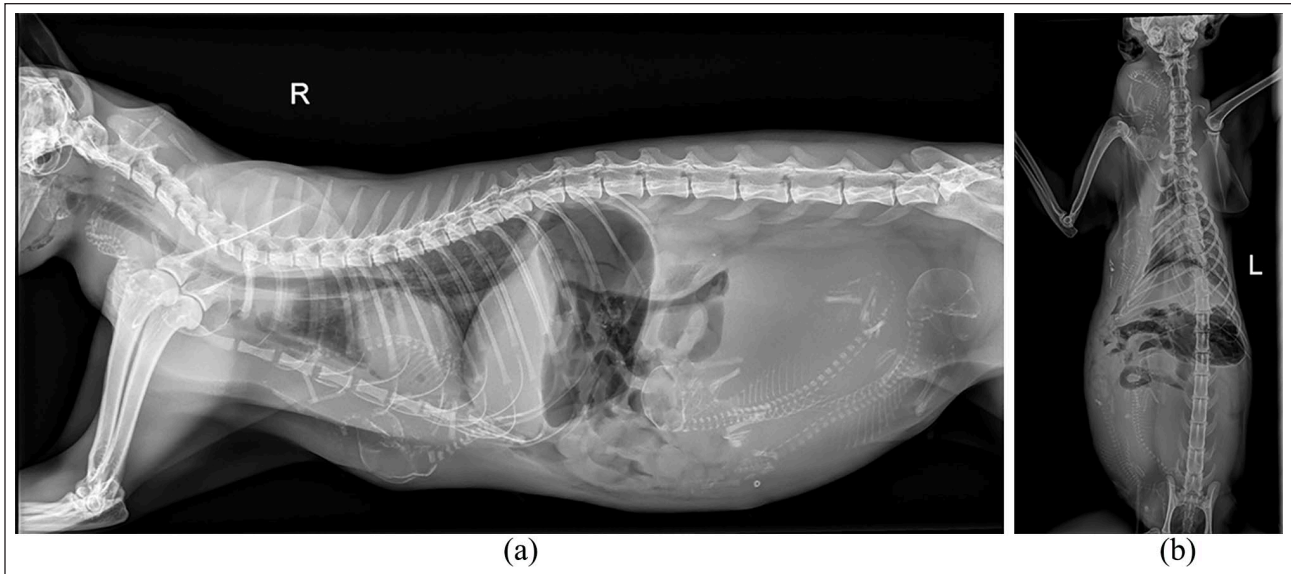


Figure 1 (a) Right lateral and (b) ventrodorsal post-mortem radiographs of a female domestic shorthair cat after having been hit by a car. Mineralized fetuses are seen in the peritoneal cavity and within the extrathoracic and cervical soft tissues. The right-sided abdominal wall is discontinuous with craniolateral displacement of the small intestines. A small amount of subcutaneous emphysema is present

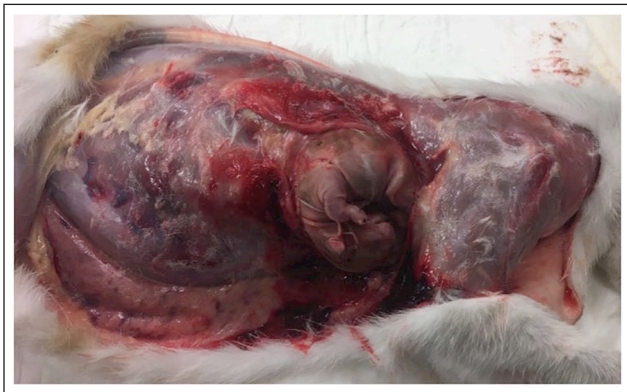

Figure 2 Post-mortem photograph of the right lateral thoracic and abdominal wall with the skin removed as part of the necropsy examination of a female domestic shorthair cat, euthanized after having been hit by a car. Dissection of thoracic subcutaneous tissues revealed a herniated fetus, ecchymosis and mild hemorrhage

Necropsy was initiated by extending a small, full-thickness cutaneous laceration on the right lateral thoracic wall. The first fetus was immediately present in the subcutaneous space over right ventrolateral thorax (Figure 2). Dissection was continued cranially through the subcutaneous tissues along the lateral aspect of the thorax to expose a second extraluminal fetus, the head of which was entrapped in the brachial plexus. The abdominal musculature was avulsed at its insertion on the ribs with partial herniation of small intestines. Within the peritoneal cavity, the right uterine horn was torn in half

with a ruptured amniotic sac, scant serous peritoneal fluid and a third extraluminal fetus. The left uterine horn was intact and enclosed an amniotic sac and fetus. The fetuses were considered normal for the estimated gestational age and exhibited no external signs of trauma. There was no hemorrhage or gross change to the remainder of the abdominal organs.

Discussion

In cases of blunt force trauma, abdominal radiographs are used ante-mortem to evaluate for accumulations of peritoneal or retroperitoneal fluid and gas, abdominal wall and diaphragm integrity, organ location and margination, and musculoskeletal injury. In this patient, post-mortem radiography and necropsy diagnosed uterine rupture with fetal herniation through a rent in the abdominal wall and into the subcutaneous tissues of the thorax and neck.

Radiographic signs of abdominal wall herniation include a discontinuous abdominal wall, an absence of abdominal organs in their normal locations and the presence of organs within subcutaneous tissues,² all of which were noted. Traumatic body wall herniation occurs when musculature is torn away from bony attachments or when the distribution of force damages fascia, often sparing elastic skin.^{2,3} Although the overall incidence of traumatic abdominal wall hernias is low, this condition is most commonly seen as a result of blunt trauma or penetrating injury,^{2,3} consistent with this patient's history of being hit by a car.

Traumatic rupture of the gravid uterus in a cat has been reported several times,⁴⁻¹¹ most commonly as the result of

traffic accident or bite wounds. Uterine rupture after known trauma was diagnosed by routine or elective ovariohysterectomy in four cases,^{4,5,7,9} and via exploratory celiotomy following known trauma and subsequent, incomplete parturition in two cases.^{10,11} Surgery was prompted in two cases owing to severe bite wounds with either protruding fetal tissue⁶ or ultrasonographic suspicion of an extra-uterine fetus.⁸ The remaining two cases were diagnosed by surgery or necropsy after clinical deterioration in hospital.⁵ As the two abdominal fetuses in our case summated with a normally positioned uterus and did not display radiographic signs of fetal death, ultrasonography could have been used to evaluate fetal viability and uterine wall integrity as part of surgical planning and prognostication.

Had surgical treatment been attempted in this patient, ovariohysterectomy, concurrent extrication of the extra-uterine fetuses through both intra-abdominal and subcutaneous exploratory surgery, and primary herniorrhaphy of the abdominal wall would have been recommended. As the three extraluminal fetuses were separated from the maternal blood supply, it is anticipated that they died from hypoxic injury. Theoretically, if ultrasonography had determined the intraluminal fetus to be viable, a partial, right-sided hysterectomy could have been performed to allow the fetus to mature to full term within the intact left horn. Subsequent hospitalization with serial ultrasonography to evaluate fetal heartbeat would have been strongly recommended. However, in the light of the extensive abdominal surgery and the intra-abdominal pressures required for parturition, both uterine inertia and rupture at the surgical site would be of major concern.

Herniation of the gravid, intact, uterus into the thoracic cavity through a diaphragmatic rent has also been reported in both cats^{12,13} and dogs,^{14–17} as has herniation of mineralized fetuses through peritoneopericardial diaphragmatic hernia in a dog.¹⁸ However, concurrent uterine rupture and fetal displacement outside of the body cavities is exceedingly rare. To our knowledge, a single case is documented in which a cat had fetal herniation through a uterine tear and abdominal wall rent that extended from the left inguinal canal, likely due to unwitnessed trauma.¹⁹ This was diagnosed via both radiography and exploratory surgery. Our case has similar findings but displays an extreme degree of fetal displacement through the subcutaneous tissues of the thorax, axilla and neck with minimal other radiographic or gross findings of trauma.

Conclusions

Uterine rupture and abdominal wall herniation of fetuses, albeit rare, is a potential complication of blunt force trauma or motor vehicle accident in gravid felids. Furthermore, uterine rupture may be present without radiographic evidence of peritoneal fluid or fetal displacement, so ultrasonography is warranted to evaluate for ectopic fetuses and fetal distress.

Acknowledgements We acknowledge Katelyn Kelley at VCA Great Lakes Veterinary Specialists for case management and assistance with necropsy.

Conflict of interest The authors declared no potential conflicts of interest with respect to the research, authorship, and/or publication of this article.

Funding The authors received no financial support for the research, authorship, and/or publication of this article.

Ethical approval This work involved the use of non-experimental animals only (including owned or unowned animal and data from prospective or retrospective studies). Established internationally recognized high standards ('best practice') of individual veterinary clinical patient care were followed. Ethical approval from a committee was therefore not necessarily required.

Informed consent Informed consent (either verbal or written) was obtained from the owner or legal custodian of all animal(s) described in this work (either experimental or non-experimental animals) for the procedure(s) undertaken (either prospective or retrospective studies). For any animals or humans individually identifiable within this publication, informed consent (either verbal or written) for their use in the publication was obtained from the people involved.

ORCID iD Alexandra G Collins-Webb  <https://orcid.org/0000-0002-7146-0894>

References

- 1 Kinns J and Nelson N. **Uterus, ovaries, and testes.** In: Thrall D (ed). *Textbook of veterinary diagnostic radiology*. 7th ed. St Louis, MO: Elsevier Saunders, 2018, pp 880–892.
- 2 Smeak DD. **Abdominal wall reconstruction and hernias.** In: Tobias K and Johnston S (eds). *Veterinary surgery: small animal*. St Louis, MO: Elsevier Saunders, 2012, pp 1353–1379.
- 3 Shaw SR, Rozanski EA and Rush JE. **Traumatic body wall herniation in 36 dogs and cat.** *J Am Anim Hosp Assoc* 2003; 39: 35–46.
- 4 Chong A. **A case of feline ectopic abdominal fetuses secondary to trauma.** *Can Vet J* 2017; 58: 400–402.
- 5 Davies R, Rozanski E, Tseng F, et al. **Traumatic uterine rupture in three felids.** *J Vet Emerg Crit Care* 2016; 26: 782–786.
- 6 Dharmaceelan S, Jayakumar K, Senthilkumar S, et al. **A rare incidence of uterine rupture and foetal escape in a cat.** *Indian Vet J* 2016; 93: 56–57.
- 7 Godfrey DR. **A case of uterine rupture with complete division of the uterus and associated secondary ectopic fetus in a cat.** *Feline Pract* 1997; 25: 20–21.
- 8 Kumru IH, Seyrek-Intas K, Tuna B, et al. **Severe abdominal dog bite wounds in a pregnant cat.** *J Feline Med Surg* 2007; 9: 499–502.
- 9 Leedham R. **Case study of traumatic uterine rupture in a cat.** *Vet Times* 2017; 47.
- 10 Lucas X, Agut A, Ramis G, et al. **Uterine rupture in a cat.** *Vet Rec* 2003; 152: 301–302.

- 11 Wilkinson GT. **A case a recent uterine rupture in a cat.** *Vet Rec* 1951; 63: 470–471.
- 12 Nak D, Celimli N, Karakaya E, et al. **Diaphragmatic hernia of gravid uterus and right sided displacement of heart in a domestic short-haired cat.** *J Anim Plant Sci* 2016; 26: 552–555.
- 13 Planellas M, Martin N, Pons C, et al. **Mummified fetus in the thoracic cavity of a domestic short-haired cat.** *Top Comp Anim Med* 2012; 21: 36–37.
- 14 Bellenger CR, Milstein M and McDonell W. **Herniation of gravid uterus into thorax of a dog.** *Modern Vet Pract* 1975; 56: 553–555
- 15 Deschamps JY, Kolb H, Descol C, et al. **Chronic diaphragmatic hernia with herniation of the gravid uterus in a female dog – a case report and review.** *Rev Med Vet* 2012; 163: 299–301.
- 16 Hattangadi SR and Kohli RN. **An unusual case of diaphragmatic hernia in a female dog.** *Indian Vet J* 1967; 44: 1076–1077.
- 17 Sullivan JL, Puckett JR and Sevedge JP. **What is your diagnosis? Ruptured diaphragm with herniation of gravid uterus and abdominal viscera.** *J Am Vet Med Assoc* 1969; 155: 941–942.
- 18 Iwasaki M. **What is your diagnosis? Peritoneopericardial diaphragmatic hernia with herniation of mineralized fetuses.** *J Am Vet Med Assoc* 1999; 214: 1775–1776.
- 19 Webb AI. **Ventral hernia and ruptured uterus in a cat.** *Aust Vet J* 1972; 48: 212–214.