



Peripartum clinical manifestations of a mesentericorenocaval shunt in a Burmese cat

Authors: Hoon, QiCai J, Siow, Jia Wen, Jenkins, Elizabeth, So, Wilson, Krockenberger, Mark, et al.

Source: Journal of Feline Medicine and Surgery Open Reports, 6(2)

Published By: SAGE Publishing

URL: <https://doi.org/10.1177/2055116920961369>

BioOne Complete (complete.BioOne.org) is a full-text database of 200 subscribed and open-access titles in the biological, ecological, and environmental sciences published by nonprofit societies, associations, museums, institutions, and presses.

Your use of this PDF, the BioOne Complete website, and all posted and associated content indicates your acceptance of BioOne's Terms of Use, available at www.bioone.org/terms-of-use.

Usage of BioOne Complete content is strictly limited to personal, educational, and non - commercial use. Commercial inquiries or rights and permissions requests should be directed to the individual publisher as copyright holder.

BioOne sees sustainable scholarly publishing as an inherently collaborative enterprise connecting authors, nonprofit publishers, academic institutions, research libraries, and research funders in the common goal of maximizing access to critical research.



Peripartum clinical manifestations of a mesentericorenocaval shunt in a Burmese cat

QiCai J Hoon , Jia Wen Siow, Elizabeth Jenkins, Wilson So , Mark Krockenberger, Mariano Makara and Laurencie Brunel

Journal of Feline Medicine and Surgery Open Reports
1–6

© The Author(s) 2020

Article reuse guidelines:

sagepub.com/journals-permissions

DOI: 10.1177/2055116920961369

journals.sagepub.com/home/jfmsopenreports

This paper was handled and processed by the European Editorial Office (ISFM) for publication in *JFMS Open Reports*



Abstract

Case summary A 3-year-old entire female Burmese cat was presented for investigation of intermittent lethargy during gestation followed by persistent hypersalivation and ataxia postpartum. The cat had queened three litters in total, with clinical signs worsening during the most recent lactation period. Mild anaemia (26%), hypoglycaemia (2.4 mmol/l; reference interval [RI] 3.9–8.3 mmol/l) and increased postprandial serum bile acids (74 µmol/l; RI <25 µmol/l) were identified on initial bloodwork. Multiphase contrast-enhanced CT identified a mesentericorenocaval portosystemic shunt; this was attenuated surgically with an ameroid constrictor. Clinical signs resolved after surgery. Follow-up 3 months postoperatively revealed normal pre- and postprandial serum bile acids (2 µmol/l and 3 µmol/l, respectively) with repeat CT identifying evidence of shunt attenuation. The cat continued to be healthy and free of clinical signs 12 months postoperatively.

Relevance and novel information Mesentericorenocaval portosystemic shunt morphology has not been previously reported in the cat and should be considered as a differential diagnosis for cats presenting with peripartum onset of malaise, ptyalism or ataxia.

Keywords: Partum; portosystemic; shunt; pregnancy

Accepted: 17 August 2020

Case description

A 3-year-old entire female Burmese cat was referred for investigation of persistent peripartum hypersalivation and suspicion of a portosystemic shunt (PSS). The cat had queened three litters, with the most recent containing four kittens approximately a month prior to presentation. The first two litters comprised only a single offspring each. A history of only intermittent lethargy and vomiting was identified during all three gestation periods. In addition, worsening clinical signs of hypersalivation, ataxia, inappetence, polyuria and polydipsia were noted exclusively while lactating for the most recent litter. The cat was otherwise reported to be clinically normal between pregnancies and up to date with vaccinations and parasite prophylaxis. The patient was an indoor-only cat living with 14 other Burmese cats as part of a breeding line. The cat was fed on a commercial-based diet previously and supplemented ad libitum

kitten food during lactation. A familial history of PSS had been identified in five other cats within the breeding line, including a queen sharing the same sire. None of the kittens were reported to be unwell.

Reference laboratory diagnostics performed by the primary veterinarian revealed mild normocytic, normochromic anaemia (haematocrit [Hct] 26%, reference interval [RI] 28–45%; mean cell volume [MCV] 40 fl, RI

University Veterinary Teaching Hospital Sydney, School of Veterinary Science, University of Sydney, Camperdown, NSW, Australia

Corresponding author:

QiCai J Hoon BVSc (Hons), MANZCVS (Small Animal Surgery), University Veterinary Teaching Hospital Sydney, School of Veterinary Science, University of Sydney, 65 Parramatta Road, Camperdown, NSW 2220, Australia
Email: jasonhoonqc@gmail.com



Creative Commons Non Commercial CC BY-NC: This article is distributed under the terms of the Creative Commons

Attribution-NonCommercial 4.0 License (<https://creativecommons.org/licenses/by-nc/4.0/>) which permits non-commercial use, reproduction and distribution of the work without further permission provided the original work is attributed as specified on the SAGE and Open Access pages (<https://us.sagepub.com/en-us/nam/open-access-at-sage>).

40–52 fl; mean cell haemoglobin concentration [MCHC] 330 g/l, RI 310–350 g/l), mild hypocholesterolaemia (1.6 mmol/l; RI 2.4–5.2 mmol/l), hypoglycaemia (2.4 mmol/l; RI 3.9–8.3 mmol/l) and increased single postprandial serum bile acids (SBA) of 74 µmol/l (RI <25 µmol/l). All other haematology, biochemistry and urinalysis results were within normal limits. Concerns of toxoplasmosis prompted serological testing via indirect immunofluorescent antibody assay, which identified prior exposure with elevated IgG titres of 1:1024 and no active infection with IgM titres of 1:16 (RI <1:64). Cryptococcal antigen latex agglutination test was negative. The cat was started on amoxicillin (20 mg/kg PO q12h [Betamox Palatable Drops; Norbrook]), oral lactulose (1 ml PO q12h [Actilax; Mylan]) and was transitioned off kitten food prior to referral. The owner subsequently reported significant amelioration of the clinical signs upon starting the interim medical therapy for hepatic encephalopathy.

Physical examination on referral presentation 5 weeks later revealed the cat to be mildly underweight (3.19 kg; body condition score 4/9) with prominent engorged mammary glands. Copper irises were evident on ophthalmic examination. Vital signs, neurological examination and the remainder of the physical examination were unremarkable. Repeated minimum database through a reference laboratory revealed microcytic anaemia (Hct 25%, RI 30–45%; MCV 34.5 fl, RI 40–45 fl; MCHC 352 g/l, RI 310–350 g/l), mild leukopenia ($6.7 \times 10^9/l$; RI $8\text{--}14 \times 10^9/l$) with monocytopenia ($0.07 \times 10^9/l$; RI $0.08\text{--}0.56 \times 10^9/l$) and eosinopenia (0.00; RI $0.16\text{--}1.4 \times 10^9/l$), increased creatine kinase (424 U/l; RI <200 U/l), marginally increased alkaline phosphatase (54 U/l; RI <50 U/l), mild decreased creatinine (77 µmol/l; RI 90–180 µmol/l) and hypobilirubinaemia (1.6 µmol/l; RI 2.5–3.5 µmol/l). Retroviral testing and coagulation profiles were not performed during the diagnostic work-up.

A multiphase (precontrast, arterial, portal, delayed venous) contrast-enhanced CT scan (Brilliance 16; Philips Medical Systems) of the abdomen was subsequently performed under general anaesthesia. The anaesthesia protocol included premedication with medetomidine (2 µg/kg IV [Ilium Medetomidine; Troy Animal Healthcare]) and methadone (0.2 mg/kg IV [Ilium Methadone; Troy Animal Healthcare]), induction with intravenous propofol (Provet; Claris Lifesciences Australia) to effect and maintenance on isoflurane (Isoflo; Zoetis). CT revealed an anomalous, tortuous vessel arising from the cranial mesenteric vein. This appeared to course left laterally and dorsally before entering the left renal vein immediately prior to its insertion into the caudal vena cava (CdVC; Figure 1). The left renal vein appeared enlarged distal to the abnormal vessel insertion. Liver morphology and hepatic vasculature, including the portal vein, were within normal limits, with no appreciable pathology. These findings were

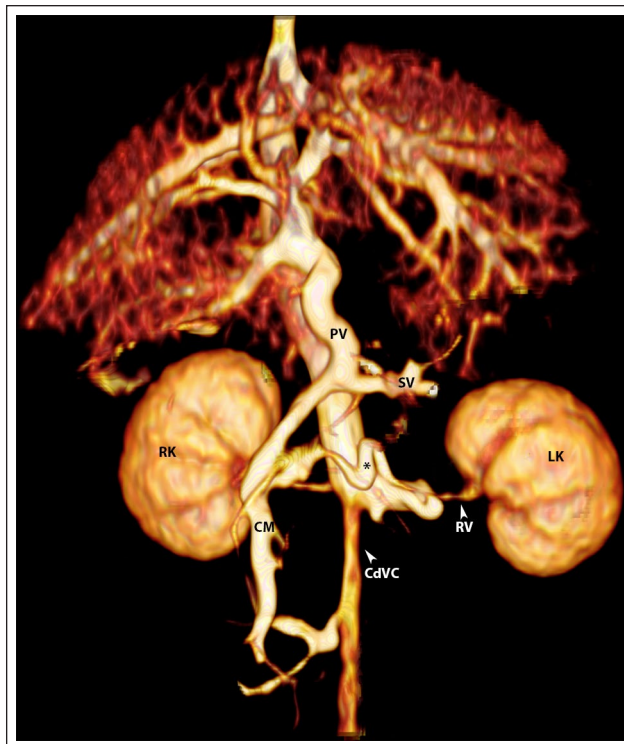


Figure 1 Three-dimensional volume-rendered image following isolation of the portosystemic vasculature in this case. Asterisk (*) marks the anomalous mesentericorenocaval shunt. Note the increase in diameter of caudal vena cava (CdVC) following shunt insertion. RK = right kidney; LK = left kidney; RV = left renal vein; SV = splenic vein; PV = portal vein; CM = cranial mesenteric vein

suggestive of an extrahepatic mesentericorenocaval PSS, albeit an acquired shunt was considered based on the circum-renal location. The patient was discharged home for 3 weeks with levetiracetam (20 mg/kg PO q8h [Keppra Oral Solution; GlaxoSmithKline]) and a low-protein diet (Hill's Prescription Feline k/d), as well as amoxicillin and lactulose as advised previously prior to surgical intervention.

Exploratory celiotomy was undertaken via a standard midline approach with a similar anaesthesia protocol as described earlier. An anomalous shunt was identified entering the left renal vein from the cranial mesenteric vein (Figure 2). Visible and palpable turbulence was present within the renal vein distally. The shunt was skeletonised from the perivascular fascia using Lahey forceps. A 3.5 mm ameroid constrictor (Veterinary Instrumentations; Sheffield) was applied and secured around the shunt vessel without compression. No visceral evidence of portal hypertension was appreciated. Representative punch biopsies were obtained centrally from each liver lobe via 6 mm punch biopsies. A haemostatic gelatine sponge (Gelfoam; Pfizer) was placed within the hepatic biopsy sites to aid haemostasis. No further

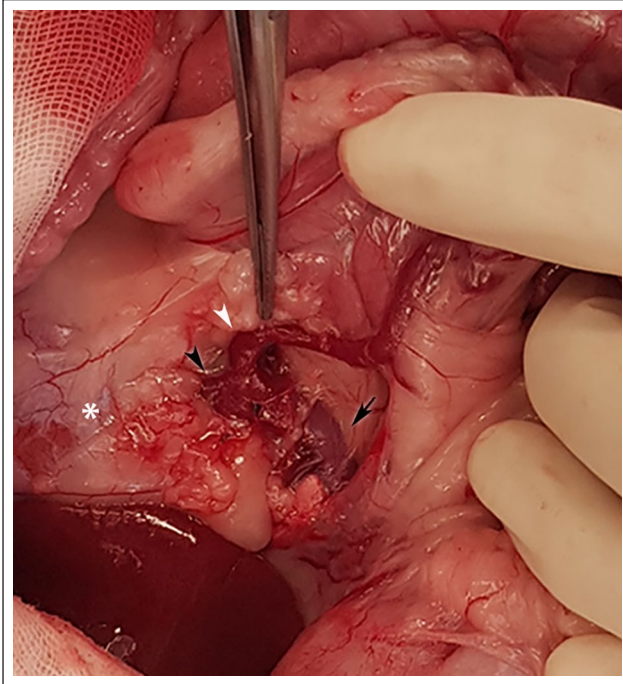


Figure 2 Mesentericorenocaval shunt (white arrowhead) entering left renal vein (black arrowhead) identified in surgery. Caudal vena cava denoted by black arrow. Asterisk represents left kidney. Bottom of image is cranial for orientation

concurrent hepatovascular anomalies were identified, and the remainder of the exploratory surgery was unremarkable. Standard ovariohysterectomy was performed prior to routine abdominal closure.

Histopathological evaluation of the liver biopsies (Figure 3) showed diffuse and variable lobular hypoplasia characterised by an undulating capsular surface, closely associated portal triads and mild hepatocellular atrophy. Within the portal tracts, the portal veins frequently displayed a collapsed profile and were surrounded by increased small calibre arterioles (arteriolar hyperplasia) and minimal proliferations of predominantly small bile ducts (bile duct hyperplasia). These histological features, together with the clinical findings, were consistent with the diagnosis of a PSS.

The patient had an unremarkable recovery following all episodes of general anaesthesia. Postoperative analgesia consisted of methadone (0.2 mg/kg IV q4h) before transitioning to buprenorphine (0.02 mg/kg sublingual q8h [Temgesic; Reckitt Benckiser]). The cat was discharged with the aforementioned medical management protocol. Levetiracetam was tapered down (10 mg/kg PO q8h) 1 week postoperatively. Both levetiracetam and amoxicillin were stopped following the 2-week recheck, where no clinical concerns were noted. Lactulose was ceased 1 month postoperatively. Three months after surgery, the patient remained well with no nausea or

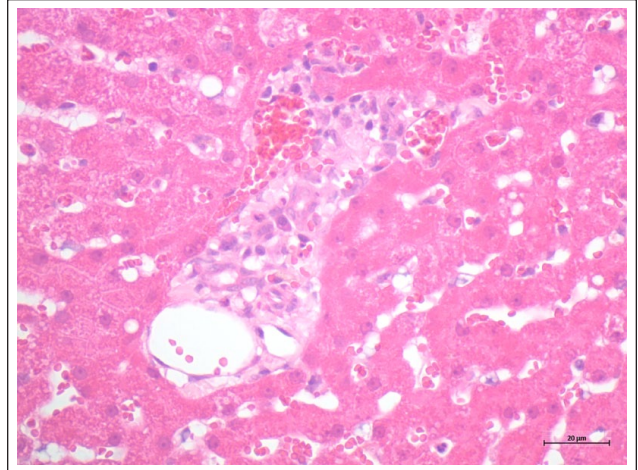


Figure 3 Histopathology of an abnormal portal tract with portal arteriolar hyperplasia characterised by an increased number of small calibre arterioles (haematoxylin and eosin, $\times 40$). Scale bar = 20 μm

neurological dysfunction noted since discharge. Recheck bloodwork then only showed mild hypocholesterolaemia (2.34 mmol/l; RI 2.84–8.27 mmol/l) and mild hyperglobulinaemia (54 g/l; RI 25–45 g/l). Repeat contrast-enhanced CT evaluation showed appropriate positioning of the ameroid constrictor and evidence of shunt attenuation associated with significant reduction in vessel size and minimal contrast enhancement. Despite marked reduction of the left gonadal vein, the right gonadal vein remained patent with contrast filling. This persistent enhancement was attributed to delayed involution post-neutering. Repeat pre- and postprandial SBA were 2 $\mu\text{mol/l}$ and 3 $\mu\text{mol/l}$ (RI <16 – <25 $\mu\text{mol/l}$), respectively, which substantiated clinicopathological shunt resolution. The low-protein diet was transitioned back to the cat's previous commercial diet thereafter. Telephone follow-up 12 months postoperatively revealed that the cat continued to be healthy and free of all clinical signs.

Discussion

PSSs are anomalous vascular communications between the portal and systemic venous circulation, permitting blood to bypass hepatic processing; these can be aetiologically classified as congenital or acquired.^{1–3} Feline PSS is uncommonly seen, with a reported incidence of approximately 2.5 per 10,000 cats managed at referral institutions.⁴ Four main subtypes predominate feline extrahepatic PSS morphology: left gastrophrenic, splenocaval, left gastrocaval and those originating from the left colic vein, with the former three representing 60–92% of reported cases.^{5–10} Other atypical variations described include left gastroazygos, portoazygos, portocaval and pancreaticoduodenocaval conformations.^{5–7,11} To our

knowledge, this report is the first to describe a mesentericorenocaval PSS in the cat. Prior to this, the mesentericorenocaval conformation has only been described once in companion animals in a single geriatric neutered male Pomeranian.¹² Despite similarly having normal portal vein dimensions, the canine morphology differed with the shunt originating instead from the caudal mesenteric vein prior to entering the left renal vein.¹² However, presenting clinical signs, management and outcome were not recorded in that report for comparison.

The aetiology of this mesentericorenocaval shunt is debatable, but is considered most likely to be congenital in origin. Congenital PSSs, which are more common in cats, are single abnormal connections between vitelline and cardinal vasculatures that persist post-embryologically, whereas acquired shunts develop secondary to portal hypertension, opening pre-existing fetal vessels of lower resistance between the portal and systemic circulation to offload hydrostatic pressure.^{1-3,13-15} Acquired shunt morphology commonly depicts multiple vessels connecting the portal system directly to the perirenal CdVC, renal or gonadal veins.¹⁴⁻¹⁶ True feline acquired PSSs are rarely reported, however. Described associations with portal hypertension include hepatic fibrosis, arteriovenous fistulas, chronic diaphragmatic hernia, pathological portal vein occlusion, portal vein hypoplasia and after PSS attenuation, none of which were identified in our patient.^{14,15,17-19} The heritability of feline congenital PSSs has yet to be established, with most breed representations based on increased prevalence within published work.²⁰ Canine breed studies, however, support a familial digenic, tri-allelic trait of PSSs in Irish Wolfhounds, whereas affected Cairn Terriers displayed a polygenic autosomal inheritance pattern.²⁰⁻²² None of the patient's progeny had reported clinical signs attributed to PSSs at the time of writing the manuscript; however, these cats have not been actively investigated. Moreover, the queen only showed clinical signs during perigestational periods and was otherwise well between. Detailed pedigree analysis of this Burmese family line is currently ongoing at our institution. Likewise, in humans, mesentericorenal or caval shunts are uncommon shunt conformations. However, these morphologies have been depicted to develop spontaneously secondary to liver cirrhosis.^{23,24} Considering the single extrahepatic nature, the multitude of PSSs within the familial line and clinicopathological resolution post-shunt attenuation with the absence of ascites and hepatopathy, we favour a congenital aetiology in this case.

Splenosystemic shunts are a unique subtype that draw significant parallels to the mesentericorenocaval shunt identified.^{13,25} In a retrospective study of 33 afflicted cats, a single vascular communication was identified from the splenic vein and terminating in either the left renal vein or CdVC.¹³ The definitive aetiology similarly remains open; Palerme et al hypothesise that these represent congenital shunts with minimal clinical significance, and

their identification during investigations of vomiting or inappetence was completely incidental.¹³ However, 42% of these cats had an underlying hepatobiliary pathology with potential for portal hypertension, sparking concerns of an acquired pathogenesis, although hepatic fibrosis was only identified histologically in three cases.¹³ Embryologically, caudal segments of the vitelline veins contribute to formation of the portal, splenic and part of the cranial mesenteric vein, the last forming secondarily within the mesenteric cleft following regression of the left vitelline vein.²⁶ Comparatively, the CdVC and renal veins originate from the subcardinal venous systems.²⁷ Mesenteric venous variability involving the splenic vein is well described.^{28,29} Acknowledging the analogous termination, embryological proximity and similar delayed presentation, it is plausible that the mesentericorenocaval morphology may be an anatomical variant of these splenosystemic anomalies. Interestingly, the splenosystemic signalment differs, with spayed female cats significantly over-represented, which confounds this possible association. Anomalous portal vascularisation through adhesions of remnant ovarian pedicles following ovariohysterectomy was speculated to explain the neutered predominance.¹³

Manifestation of clinical signs and the impact of PSSs during the peripartum period have not been previously described, further compounding the causality dilemma in this case. Serum serotonin has been demonstrated to mirror mammary-derived serotonin levels, which are upregulated via prolactin-driven autocrine-paracrine loops during pregnancy and lactation.^{30,31} Free tryptophan, the precursor to serotonin, has also been shown to escalate during gestation following albumin depletion and non-esterified fatty acid elevation.³² Increased circulation of these known neurostimulants, bypassing hepatic metabolism in the presence of a PSS, could be implicated in explaining the peripartum malaise in this case.³³ Postpartum eclampsia was considered as a differential, especially in the lactation phase; however, hypocalcaemia was never identified at any time point. Transient puerperium PSS formation in the absence of predisposing portal hypertension has also been described in a woman.³⁴ Retrograde shunting from inferior mesenteric veins to the para-uterine and right gonadal veins was identified following delivery, but this self-resolved within 3 weeks postpartum.³⁴ Experimental murine studies demonstrated a provasodilatory state with alterations in basal venous tone, contractility and adrenergic sensitivity of the mesenteric venous system during pregnancy.³⁵⁻³⁸ One may theorise that endothelial vasodilation and an increase in plasma volume expansion through the mesenteric portal tributary during gestation may promote flow and open vestigial embryonic channels to the systemic circulation. Owing to scarcity within the literature, gestational influence on feline portosystemic haemodynamics should be explored in future studies to challenge the principal aetiology and affirm these hypotheses.

Conclusions

This paper marks the first reported case of a mesenterico-caval PSS in the cat. Although the underlying aetiology remains unclear, this should be considered as a differential diagnosis for cats presenting with peripartum onset of malaise, ptilyism or ataxia.

Conflict of interest The authors declared no potential conflicts of interest with respect to the research, authorship, and/or publication of this article.

Funding The authors received no financial support for the research, authorship, and/or publication of this article.

Ethical approval This work involved the use of non-experimental animals only (including owned or unowned animals and data from prospective or retrospective studies). Established internationally recognised high standards ('best practice') of individual veterinary clinical patient care were followed. Ethical approval from a committee was therefore not necessarily required.

Informed consent Informed consent (either verbal or written) was obtained from the owner or legal custodian of all animal(s) described in this work (either experimental or non-experimental animals) for the procedure(s) undertaken (either prospective or retrospective studies). No animals or humans are identifiable within this publication, and therefore additional informed consent for publication was not required.

ORCID iD QiCai J Hoon  <https://orcid.org/0000-0002-1636-8622>

Wilson So  <https://orcid.org/0000-0003-0935-7818>

References

- Berent AC and Tobias KM. **Portosystemic vascular anomalies.** *Vet Clin North Am Small Anim Pract* 2009; 39: 513–541.
- Griffin S. **Feline abdominal ultrasonography: what's normal? what's abnormal? Hepatic vascular anomalies.** *J Feline Med Surg* 2019; 21: 645–654.
- Bertolini G. **Anomalies of the portal venous system in dogs and cats as seen on multidetector-row computed tomography: an overview and systematization proposal.** *Vet Sci* 2019; 6: 10. DOI: 10.3390/vetsci6010010.
- Levy J, Bunch S and Komtebedde J. **Feline portosystemic vascular shunts.** In: Bonagura JD (ed). *Kirk's current veterinary therapy XII: small animal practice*. Philadelphia, PA: WB Saunders, 1995, pp 743–749.
- White RN, Shales C and Parry AT. **New perspectives on the development of extrahepatic portosystemic shunts.** *J Small Anim Pract* 2017; 58: 669–677.
- Lipscomb VJ, Jones HJ and Brockman DJ. **Complications and long-term outcomes of the ligation of congenital portosystemic shunts in 49 cats.** *Vet Rec* 2007; 160: 465–470.
- Valiente P, Trehy M, White R, et al. **Complications and outcome of cats with congenital extrahepatic portosystemic shunts treated with thin film: thirty-four cases (2008–2017).** *J Vet Intern Med* 2020; 34: 117. DOI: 10.1111/jvim.15649.
- White R, Parry A and Shales C. **Implications of shunt morphology for the surgical management of extrahepatic portosystemic shunts.** *Aust Vet J* 2018; 96: 433–441.
- White RN and Parry A. **Morphology of congenital portosystemic shunts involving the left colic vein in dogs and cats.** *J Small Anim Pract* 2016; 57: 247–254.
- White RN and Parry AT. **Morphology of congenital portosystemic shunts emanating from the left gastric vein in dogs and cats.** *J Small Anim Pract* 2013; 54: 459–467.
- Lamb CR, Hijfte F-V, White RN, et al. **Ultrasonographic diagnosis of congenital portosystemic shunt in 14 cats.** *J Small Anim Pract* 1996; 37: 205–209.
- Specchi S, Pey P, Javard R, et al. **Mesenteric-reno-caval shunt in an aged dog.** *J Small Anim Pract* 2015; 56: 72. DOI: 10.1111/jsap.12255.
- Palerme JS, Brown JC, Marks SL, et al. **Spleno-systemic shunts in cats: a retrospective of 33 cases (2004–2011).** *J Vet Intern Med* 2013; 27: 1347–1353.
- McConnell JF, Sparkes AH, Ladlow J, et al. **Ultrasonographic diagnosis of unusual portal vascular abnormalities in two cats.** *J Small Anim Pract* 2006; 47: 338–343.
- Zandvliet MMJM, Szatmári V, Van Den Ingh T, et al. **Acquired portosystemic shunting in 2 cats secondary to congenital hepatic fibrosis.** *J Vet Intern Med* 2005; 19: 765–767.
- Boothe H, Howe L, Edwards J, et al. **Multiple extrahepatic portosystemic shunts in dogs: 30 cases (1981–1993).** *J Am Vet Med Assoc* 1996; 208: 1849–1854.
- Barfield DM, Gibson AD and Lipscomb VJ. **Multiple acquired portosystemic shunts in a cat secondary to chronic diaphragmatic rupture.** *JFMS Open Rep* 2015; 1. DOI: 10.1177/2055116915585020.
- Langdon P, Cohn LA, Kreeger JM, et al. **Acquired portosystemic shunting in two cats.** *J Am Anim Hosp Assoc* 2002; 38: 21–27.
- Rogers CL, O'Toole TE, Keating JH, et al. **Portal vein thrombosis in cats: 6 cases (2001–2006).** *J Vet Intern Med* 2008; 22: 282–287.
- Watson P. **Breed-related diseases.** In: Washabau RJ and Day MJ (eds). *Canine and feline gastroenterology*. St Louis, MO: WB Saunders, 2013, pp 958–972.
- van Steenbeek F, Leegwater P, Sluijs F, et al. **Evidence of inheritance of intrahepatic portosystemic shunts in Irish Wolfhounds.** *J Vet Intern Med* 2009; 23: 950–952.
- Straten G, Leegwater PAJ, Vries M, et al. **Inherited congenital extrahepatic portosystemic shunts in Cairn Terriers.** *J Vet Intern Med* 2005; 19: 321–324.
- Boixadera H, Tomasello A, Quiroga S, et al. **Successful embolization of a spontaneous mesocaval shunt using the Amplatzer Vascular Plug II.** *Cardiovasc Intervent Radiol* 2010; 33: 1044–1048.
- Laleman W, Simon-Talero M, Maleux G, et al. **Embolization of large spontaneous portosystemic shunts for refractory hepatic encephalopathy: a multicenter survey on safety and efficacy.** *Hepatology* 2013; 57: 2448–2457.
- Bennaïm M, Pivetta M, Puig J, et al. **Acute onset of blindness secondary to a spleno-systemic shunt in an adult cat.** *Vet Rec Case Rep* 2014; 2: e000105. DOI: 10.1136/vet-reccr-2014-000105.

- 26 Abe H, Yamamoto M, Yanagisawa N, et al. **Regressing vitelline vein and the initial development of the superior mesenteric vein in human embryos.** *Okajimas Folia Anat Jpn* 2017; 94: 87–92.
- 27 Ghandour A, Partovi S, Karuppasamy K, et al. **Congenital anomalies of the IVC – embryological perspective and clinical relevance.** *Cardiovasc Diagn Ther* 2016; 6: 482–492.
- 28 Carneiro C, Brito J, Bilreiro C, et al. **All about portal vein: a pictorial display to anatomy, variants and physiopathology.** *Insights Imaging* 2019; 10. DOI: 10.1186/s13244-019-0716-8.
- 29 Graf O, Boland G, Kaufman JA, et al. **Anatomic variants of mesenteric veins: depiction with helical CT venography.** *Am J Roentgenol* 1997; 168: 1209–1213.
- 30 Matsuda M, Imaoka T, Vomachka AJ, et al. **Serotonin regulates mammary gland development via an autocrine-paracrine loop.** *Dev Cell* 2004; 6: 193–203.
- 31 Weaver SR, Jury NJ, Gregerson KA, et al. **Characterization of mammary-specific disruptions for Tph1 and Lrp5 during murine lactation.** *Sci Rep* 2017; 7: 151–155.
- 32 Badawy AAB. **Tryptophan metabolism, disposition and utilization in pregnancy.** *Biosci Rep* 2015; 35: e00261. DOI: 10.1042/BSR20150197.
- 33 Bernardini P and Fischer JE. **Amino acid imbalance and hepatic encephalopathy.** *Ann Rev Nutr* 1982; 2: 419–454.
- 34 Leyendecker JR, Grayson DE and Good R. **Transient postpartum portosystemic shunting revealed by MR venography.** *Am J Roentgenol* 2002; 178: 1152–1154.
- 35 Hohmann M, Keve TM, Osol G, et al. **Norepinephrine sensitivity of mesenteric veins in pregnant rats.** *Am J Physiol Regul Integr Comp Physiol* 1990; 259: R753–R759.
- 36 Hohmann M, Zoltan D and Künzel W. **Age and reproductive status affect basal venous tone in the rat.** *Eur J Obstet Gynecol Reprod Biol* 1996; 68: 185–189.
- 37 Hart JL. **Effects of pregnancy on spontaneous contraction and barium responsiveness of the rat portal vein.** *Biol Res Pregnancy Perinatol* 1984; 5: 78–83.
- 38 Wedel Jones C, Mandala M, Barron C, et al. **Mechanisms underlying maternal venous adaptation in pregnancy.** *Reprod Sci* 2009; 16: 596–604.