

Successful treatment of otodemodiosis due to *Demodex cati* with sarolaner/selamectin topical solution in a cat

Author: Simpson, Andrew C

Source: Journal of Feline Medicine and Surgery Open Reports, 7(1)

Published By: SAGE Publishing

URL: <https://doi.org/10.1177/2055116920984386>

The BioOne Digital Library (<https://bioone.org/>) provides worldwide distribution for more than 580 journals and eBooks from BioOne's community of over 150 nonprofit societies, research institutions, and university presses in the biological, ecological, and environmental sciences. The BioOne Digital Library encompasses the flagship aggregation BioOne Complete (<https://bioone.org/subscribe>), the BioOne Complete Archive (<https://bioone.org/archive>), and the BioOne eBooks program offerings ESA eBook Collection (<https://bioone.org/esa-ebooks>) and CSIRO Publishing BioSelect Collection (<https://bioone.org/csiro-ebooks>).

Your use of this PDF, the BioOne Digital Library, and all posted and associated content indicates your acceptance of BioOne's Terms of Use, available at www.bioone.org/terms-of-use.

Usage of BioOne Digital Library content is strictly limited to personal, educational, and non-commercial use. Commercial inquiries or rights and permissions requests should be directed to the individual publisher as copyright holder.

BioOne is an innovative nonprofit that sees sustainable scholarly publishing as an inherently collaborative enterprise connecting authors, nonprofit publishers, academic institutions, research libraries, and research funders in the common goal of maximizing access to critical research.



Successful treatment of otodemodicosis due to *Demodex cati* with sarolaner/selamectin topical solution in a cat

Journal of Feline Medicine and Surgery Open Reports
1–4

© The Author(s) 2021

Article reuse guidelines:

sagepub.com/journals-permissions

DOI: 10.1177/2055116920984386

journals.sagepub.com/home/jfmsopenreports

This paper was handled and processed by the American Editorial Office (AAFP) for publication in *JFMS Open Reports*



Andrew C Simpson

Abstract

Case summary A 10-year-old spayed female Russian Blue cat was presented with a 3-month history of excessive otic discharge and scratching, only involving the right ear. Other than a moderate amount of ceruminous exudate present within the right ear on video-otoscopic examination, there were no other cutaneous abnormalities. The cat was deemed to be otherwise in good health based on physical examination and several laboratory profiles. A diagnosis of otodemodicosis was determined due to the presence of a large number of *Demodex cati* mites retrieved from cerumen. Treatment consisted only of monthly topical application of sarolaner/selamectin to the nape of the neck with a marked reduction in mite counts and otic pruritus after a single dose. Complete resolution was achieved after a total of four doses.

Relevance and novel information This is the first report to describe the resolution of mite infestation owing to *D cati* after treatment with a sarolaner-containing spot-on product. In addition, to the best of the author's knowledge, this is the first report of any isoxazoline product used in the successful treatment of demodicosis affecting the ear canal. In general, there is a lack of reports describing safe and effective treatments for feline otodemodicosis. Topically applied sarolaner/selamectin resulted in resolution of mites while avoiding any potential ototoxic events from medications applied directly into the ear, and provided a treatment that was easier to apply than oral or injectable macrocyclic lactones.

Keywords: *Demodex cati*; otodemodicosis; isoxazolines; otitis externa; sarolaner/selamectin

Accepted: 18 September 2020

Introduction

Feline demodicosis owing to *Demodex cati* is a rare condition that can affect cats with concurrent immunodebilitating disease or those in good health.^{1,2} Both localized and generalized forms can involve alopecia, comedones, erythema, scaling, crusting, erosions/ulcerations and variable levels of pruritus.^{1–4} It has also been described as a cause of ceruminous otitis externa in approximately 20% of feline cases infested with *D cati*.^{1,3} Otodemodicosis can occur in cats with diabetes mellitus and feline immunodeficiency virus (FIV), as well as cats with no apparent predisposition.^{1,5,6} This includes cases with generalized skin disease and those with demodicosis restricted to the ears. A standard protocol for the

treatment of feline otodemodicosis has not been established,⁷ although the extralabel use of isoxazolines against feline generalized demodicosis has been documented.⁴

This case report describes the successful treatment of otodemodicosis in a cat owing to *D cati* with disease only affecting one ear. A marked reduction in the mite count

Dermatology Department, VCA Aurora Animal Hospital, Aurora, IL, USA

Corresponding author:

Andrew C Simpson DVM, MS, DACVD, Dermatology Department, VCA Aurora Animal Hospital, 2600 West Galena Blvd, Aurora, IL 60506, USA

Email: andrew.simpson@vca.com



Creative Commons Non Commercial CC BY-NC: This article is distributed under the terms of the Creative Commons

Attribution-NonCommercial 4.0 License (<https://creativecommons.org/licenses/by-nc/4.0/>) which permits non-commercial use, reproduction and distribution of the work without further permission provided the original work is attributed as specified on the SAGE and Open Access pages (<https://us.sagepub.com/en-us/nam/open-access-at-sage>).

was achieved after the first dose of topically applied sarolaner/selamectin, with eventual resolution of clinical signs and absence of mites with subsequent doses.

Case description

A 10-year-old spayed female Russian Blue cat weighing 3.6 kg was presented with a 3-month history of excessive otic discharge and scratching at the right ear. There were no other signs of generalized pruritus or cutaneous lesions. Eight years prior, the cat was treated for overgrooming of the abdomen due to *Demodex gatoi*, confirmed via superficial skin scrapings, which was successfully treated with six lime sulfur dips performed weekly. At the time of recent presentation, the owner was not administering any medications including preventive parasiticides. A high-quality commercial diet was fed in both canned and dry formulations. The other cat in the household was asymptomatic and both cats were kept only indoors. Testing was negative for FIV and feline leukemia virus, in addition to having unremarkable bloodwork, including a complete blood cell count, serum biochemistry, total thyroxine levels and urinalysis. No other systemic signs were present and the cat was deemed overall to be in good health.

General physical examination, including lymph node palpation, was unremarkable and there were no cutaneous abnormalities. A video-otoscope was used for the evaluation of both external ear canals. The left ear canal was found to have no inflammation and minimal debris present; however, the right ear contained a moderate amount of brown ceruminous debris (Figure 1) adhered to the walls of the horizontal canal with mild erythema. A positive aural-pedal response was noted on examination and swabbing only of the right ear. The tympanic membrane was intact and appeared healthy in both ears.

A cotton-tipped applicator was used to sample both ear canals; portions of cerumen were mixed with mineral oil on a glass slide using the opposite end of the applicator to break apart the material. Cerumen samples were examined microscopically using the $\times 10$ objective. A separate sample was rolled onto an additional glass slide and then stained with DiffQuick prior to evaluation under $\times 100$ (oil objective). Long-bodied mites (52 live adults and 16 dead adults) morphologically consistent with *D cati* (Figure 2), in addition to a few eggs, were noted in the cerumen from the right ear but not in the left ear. There were no inflammatory cells or infectious organisms noted from either ear. Although there were no cutaneous lesions, the presence of *Demodex* mites in the ear prompted evaluation of other cutaneous sites. Deep skin scrapings from non-lesional skin of the head, dorsal neck, dorsal trunk and ventral abdomen did not retrieve any mites.

Treatment consisted only of sarolaner (5mg)/selamectin (30mg) topical solution (Revolution Plus; Zoetis) applied once monthly to the skin of the dorsal

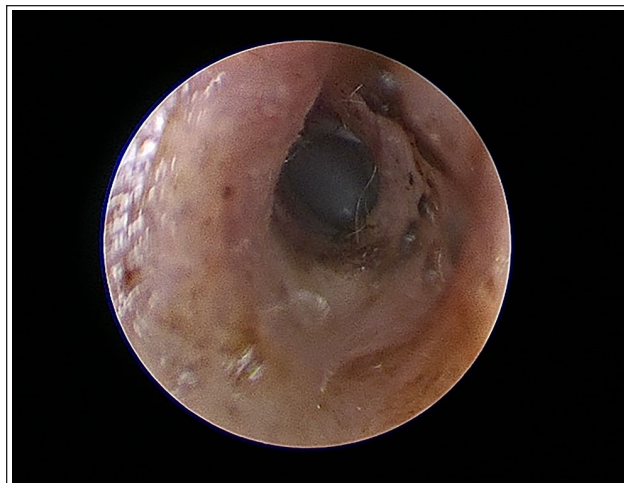

Figure 1 Video-otoscopic image of the right external ear canal showing otitis externa characterized by excessive cerumen and erythema of the canal wall

head and neck. The owners consented to this treatment with full awareness that it was considered off-label use and that no products are licensed for the treatment of feline demodicosis. Ear swab samples and video-otoscopic images were evaluated at each monthly visit. At the first follow-up visit 1 month later, there was still a moderate amount of cerumen within the right ear canal; however, there were only four dead adult *D cati* mites noted and the cat was reported to have a reduced level of otic pruritus. The left ear remained asymptomatic with no cerumen or mites noted on examination throughout the remainder of the observed period. There was only one mite found after the third treatment and no mites were found in the right ear at the final visit, 1 month after the fourth treatment. Otoloscopic examination of the right ear at the final visit showed only minimal cerumen and an absent aural-pedal response of the right ear. The owners reported no adverse effects during treatment and no relapse of clinical signs during the seven subsequent months of continued prevention after the negative mite evaluation.

Discussion

Treatment for *D cati* can often be challenging, especially in cases where the underlying disease needs to be addressed.⁸ One of the more frequently used and successful therapies is weekly lime sulfur dips.^{2,8-10} Amitraz alone or mixed in mineral oil (1:9) has also been described as a localized treatment, although it is not always well tolerated by cats.^{8,9,11,12} Given the unknown potential for ototoxicity if applied to the external ear canal, treatment with these topical therapies was not recommended. Macrocyclic lactones, including daily ivermectin (0.2–0.3 mg/kg PO)² or weekly doramectin (600 μ g/kg SC),¹³ have also been reported as successful




Figure 2 Light microscopy of cerumen from the right ear. (a) Multiple long-bodied mites morphologically consistent with *Demodex cati* at $\times 10$ magnification. (b) A $\times 40$ magnification of *D cati* found from the same otic swab sample

treatments for *D cati*, although this class of injectable drugs has the potential for neurotoxic side effects.^{14,15}

Use of the isoxazoline class of insecticides has become more popular given its success and relative safety in the off-label treatment for demodicosis.¹⁶ The mechanism of action involves blocking both gamma-aminobutyric acid and glutamate-gated chloride channels with higher potency against acarine receptors than mammalian receptors.¹⁷ Fluralaner, a member of this class, has been reported to successfully treat cats infested with generalized *D cati* with single-dose administration of either an oral tablet¹⁸ or topical spot-on,⁴ in addition to *D gatoi* as a single oral treatment.¹⁹ A newer product (Bravecto Plus; Merck) that contains both fluralaner and moxidectin, a previously reported ingredient with potential efficacy against *Demodex*,⁹ would most likely be effective in cases of otodemodicosis as well. This product was not available at the time of initial treatment of the cat in this report.

Sarolaner is also a member of the isoxazoline family, with acaricidal and insecticidal activities. Dogs with generalized demodicosis have been effectively treated with once monthly oral sarolaner, with 100% parasitological cure after no more than five monthly treatments.²⁰ In cats, the commercially available spot-on product that contains sarolaner/selamectin (Revolution Plus) is labeled for the treatment of fleas, ticks, *Otodectes cynotis*, *Toxocara cati*, *Ancylostoma tubaeforme* and *Dirofilaria immitis*.¹⁷ Off-label use of the combined sarolaner/selamectin product for mites effectively treated two cats with *D gatoi*.²¹ To the best of the author's knowledge, this is the first reported use of sarolaner/selamectin in the elimination of *D cati*, and for the treatment of otodemodicosis. Sarolaner/selamectin was selected for the cat in this case report owing to the previously reported efficacy of sarolaner in cases of canine demodicosis, in addition to the added

protection against intestinal parasites and heartworms with selamectin for a more complete parasite preventive.

Selamectin, a topically applied macrocyclic lactone, is the combined ingredient in this product; however, a previous study showed that selamectin was ineffective at eliminating infestation when applied weekly for 6 weeks in cats affected by either *D cati* or *D gatoi*.²² The cats in that study were treated topically with 20 mg/kg per week, making it unlikely that selamectin alone at 8.2 mg/kg applied once monthly would have been effective in the cat of the current report. A synergistic effect between sarolaner and selamectin, as it pertains to interfering with chloride channel conduction,¹⁷ could be possible but cannot be proven through a single case description.

The clinical presentation of *D cati* in an otherwise healthy cat is not necessarily unique, nor is ceruminous otitis externa as a sole clinical sign.^{2,9} Nevertheless, there is a paucity of data in the veterinary literature describing specific treatments for cats affected by otodemodicosis, keeping in mind that conventional treatment with acaricidal dips would need to be applied directly into the ear canal, with unknown potential for ototoxicity. Systemic therapies such as injectable macrocyclic lactones, which have neurotoxic potential, could likely be effective at treating mites found in the ear canal, although at-home application of a spot-on product is far easier for most feline patients. Furthermore, the cat described in this report was infested by *D gatoi* years prior to the more recent *D cati*. Chronic maintenance acaricidal therapy using a spot-on product rather than medicated dips or injectable medications serves as a more practical preventive measure.

This case should also prompt the veterinarian to consider investigating *D cati* as a less common cause for ceruminous otitis externa and otic pruritus in cats (especially as a unilateral presentation), even if the patients

are systemically healthy and without other cutaneous signs.

Conclusions

A spot-on parasiticide containing sarolaner and selamectin was able to safely and successfully eliminate *D cati* mite infestation of the ear while sparing the application of any products directly into the ear canal that do not have a reliable safety profile in terms of ototoxicity. Further studies are needed in larger numbers of cats affected by *D cati* (either localized or generalized) to better assess the overall efficacy of combined sarolaner/selamectin for this off-label use.

Conflict of interest The author declared no potential conflicts of interest with respect to the research, authorship, and/or publication of this article.

Funding The author received no financial support for the research, authorship, and/or publication of this article.

Ethical approval This work involved the use of non-experimental animals only (including owned or unowned animals and data from prospective or retrospective studies). Established internationally recognised high standards ('best practice') of individual veterinary clinical patient care were followed. Ethical approval from a committee was therefore not necessarily required.

Informed consent Informed consent (either verbal and written) was obtained from the owner or legal custodian of all animals described in this work (either experimental or non-experimental animals) for the procedures undertaken (either prospective or retrospective studies). No animals or humans are identifiable within this publication, and therefore additional informed consent for publication was not required.

ORCID iD Andrew C Simpson  <https://orcid.org/0000-0002-3730-5823>

References

- 1 Chesney CJ. **Demodicosis in the cat.** *J Small Anim Pract* 1989; 30: 689–695.
- 2 Beale K. **Feline demodicosis: a consideration in the itchy or overgrooming cat.** *J Feline Med Surg* 2012; 14: 209–213.
- 3 Guaguere E, Muller A and Degorce-Rubiales F. **Feline demodicosis: a retrospective study of 12 cases.** *Vet Dermatol* 2004; 15Suppl 1: 34. DOI: 10.1111/j.1365-3164.2004.411_43.x.
- 4 Beccati MB, Pandolfi PP and DiPalma AD. **Efficacy of fluralaner spot-on in cats affected by generalized demodicosis: seven cases** [abstract]. *Vet Dermatol* 2019; 30: 454.
- 5 White SD, Carpenter J, Moore FM, et al. **Generalized demodicosis associated with diabetes mellitus in two cats.** *J Am Vet Med Assoc* 1987; 191: 448–450.

- 6 Kontos V, Sotiraki S and Himonas C. **Two rare disorders in the cat: demodectic otitis externa and sarcoptic mange.** *Feline Pract* 1998; 26: 18–20.
- 7 Kennis R. **Feline otitis: diagnosis and treatment.** *Vet Clin North Am Small Anim Pract* 2013; 43: 51–56.
- 8 Ghubash R. **Parasitic miticidal therapy.** *Clin Tech Small Anim Pract* 2006; 21: 135–144.
- 9 Mueller RS, Rosenkrantz W, Bensignor E, et al. **Diagnosis and treatment of demodicosis in dogs and cats: clinical consensus guidelines of the World Association for Veterinary Dermatology.** *Vet Dermatol* 2020; 31: 5–27.
- 10 Morris DO and Beale KM. **Feline demodicosis.** In: Bonagura JD (ed). *Kirk's current veterinary therapy*. 13th ed. Philadelphia, PA: Saunders, 1999, pp 580–582.
- 11 Miller WH, Griffin CE and Campbell KL. **Parasitic skin disease.** In: Miller WH, Griffin CE and Campbell KL (eds). *Small animal dermatology*. 7th ed. St Louis, MO: Elsevier Mosby, 2013, pp 284–342.
- 12 Carlotti D. **Canine and feline demodicosis.** Proceeding of the 35th World Small Animal Veterinary Association World Congress; 2010 June 2–5; Geneva, Switzerland. <https://www.vin.com/apputil/content/defaultadv1.aspx?meta=generic&pid=11310> (accessed 5 January 2021).
- 13 Johnston IP. **Doramectin as a treatment for canine and feline demodicosis.** *Aus Vet Pract* 2002; 32: 98–103.
- 14 Merola VM and Eubig PA. **Toxicology of avermectins and milbemycins (macrocyclic lactones) and the role of P-glycoprotein in dogs and cats.** *Vet Clin North Am Small Anim Pract* 2018; 48: 991–1012.
- 15 Nentwig A, Oevermann A and Burgener IA. **Doramectin intoxication in 3 kittens.** *Schweiz Arch Tierheilkd* 2014; 156: 179–183.
- 16 Zhou X, Hohman A and Hsu WH. **Review of extralabel use of isoxazolines for treatment of demodicosis in dogs and cats.** *J Am Vet Med Assoc* 2020; 256:1342–1346.
- 17 Zoetis Website. **Revolution Plus product label.** https://www.zoetisus.com/_locale-assets/pdf/revolution-plus-prescribing-information.pdf (2018, accessed August 16, 2020).
- 18 Matricoti I and Maina E. **The use of oral fluralaner for the treatment of feline generalized demodicosis: a case report.** *J Small Anim Pract* 2017; 58: 476–479.
- 19 Duangkaew L and Hoffman H. **Efficacy of oral fluralaner for the treatment of *Demodex gato* in two shelter cats.** *Vet Dermatol* 2018; 29: 262.
- 20 Becskei C, Cuppens O and Mahabir SP. **Efficacy and safety of sarolaner against generalized demodicosis in dogs in European countries: a non-inferiority study.** *Vet Dermatol* 2018; 29: 203.
- 21 Walker C. **Treatment of *Demodex gato* mange in two sibling Bengal cats with a combination of selamectin and sarolaner.** *Comp Anim* 2019; 24: 127–131.
- 22 Beale KM and Rustemeyer-May E. **Selamectin in the treatment of feline *Demodex*** [abstract]. *Vet Dermatol* 2001; 12: 237.