



Gynaecomastia in a male neutered cat with an adrenal tumour and associated hyperprogesteronism, hypercortisolism and hyperaldosteronism

Authors: Yu, Jane, Lenord, Jason, Lau, Michelle, Brunel, Laurencie, Gray, Rachael, et al.

Source: Journal of Feline Medicine and Surgery Open Reports, 7(2)

Published By: SAGE Publishing

URL: <https://doi.org/10.1177/20551169211045640>

BioOne Complete (complete.BioOne.org) is a full-text database of 200 subscribed and open-access titles in the biological, ecological, and environmental sciences published by nonprofit societies, associations, museums, institutions, and presses.

Your use of this PDF, the BioOne Complete website, and all posted and associated content indicates your acceptance of BioOne's Terms of Use, available at www.bioone.org/terms-of-use.

Usage of BioOne Complete content is strictly limited to personal, educational, and non - commercial use. Commercial inquiries or rights and permissions requests should be directed to the individual publisher as copyright holder.

BioOne sees sustainable scholarly publishing as an inherently collaborative enterprise connecting authors, nonprofit publishers, academic institutions, research libraries, and research funders in the common goal of maximizing access to critical research.



Gynaecomastia in a male neutered cat with an adrenal tumour and associated hyperprogesteronism, hypercortisolism and hyperaldosteronism

Journal of Feline Medicine and Surgery Open Reports
1–8

© The Author(s) 2021

Article reuse guidelines:

sagepub.com/journals-permissions

DOI: 10.1177/20551169211045640

journals.sagepub.com/home/jfmsopenreports

This paper was handled and processed by the European Editorial Office (ISFM) for publication in *JFMS Open Reports*



Jane Yu¹, Jason Lenord², Michelle Lau¹,
Laurencie Brunel¹, Rachael Gray³,
Shannon L Donahoe³ and Lara Boland¹

Abstract

Case summary A 7-year-old male neutered domestic longhair cat was presented with chronic progressive gynaecomastia, polydipsia, polyphagia, weight loss and poor fur regrowth. Sexualised behavioural changes were not reported and virilisation was not present on physical examination. Pertinent haematology, biochemistry and urinalysis findings at the time of referral included mild hypokalaemia. Left adrenomegaly and mild prostatomegaly were identified on a CT scan. Evaluation of adrenal hormones with a low-dose dexamethasone suppression test, serum progesterone, testosterone, oestradiol, plasma aldosterone, renin, plasma metanephrine and normetanephrine measurement supported a diagnosis of hyperprogesteronism, hyperaldosteronism and hypercortisolism. Adrenalectomy was performed and histopathology was consistent with an adrenocortical tumour. Clinical signs and hormone elevations resolved postoperatively.

Relevance and novel information To our knowledge, this is the second report of gynaecomastia secondary to an adrenal tumour in a male neutered cat and the first associated with hyperprogesteronism.

Keywords: Gynaecomastia; adrenal tumour; hyperprogesteronism; hypercortisolism; hyperaldosteronism

Accepted: 24 August 2021

Case description

A 7-year-old male neutered domestic longhair cat was referred with gynaecomastia and left adrenomegaly. Twelve months earlier the cat had been diagnosed with bacterial cystitis. Haematology and biochemistry were unremarkable, and urine specific gravity (USG) was 1.038. Abdominal ultrasonography identified left adrenomegaly (approximately 0.60 cm thick at the caudal pole). The right adrenal gland was unremarkable (approximately 0.31 cm thick at the caudal pole). The infection resolved with antimicrobial treatment based on culture and sensitivity results. Repeat culture was negative.

Five months later, the cat presented with polydipsia, polyphagia and 200 g weight loss. Physical examination identified poor fur regrowth at previously clipped sites.

Urinalysis revealed trace proteinuria and potentially reduced tubular concentrating ability (USG 1.018). Haematology and biochemistry were unremarkable and

¹Valentine Charlton Cat Centre, University Veterinary Teaching Hospital Sydney, Sydney School of Veterinary Science, Faculty of Science, University of Sydney, NSW, Australia

²Balmain Veterinary Hospital, Rozelle, NSW, Australia

³Veterinary Pathology Diagnostic Services, Sydney School of Veterinary Science, Faculty of Science, University of Sydney, NSW, Australia

Corresponding author:

Lara Boland BVSc, DipECVIM-CA, FANZCVS (Feline Medicine), FHEA, Sydney School of Veterinary Science, University of Sydney, Evelyn Williams Building B10, Sydney, NSW 2006, Australia
Email: lara.boland@sydney.edu.au



Creative Commons Non Commercial CC BY-NC: This article is distributed under the terms of the Creative Commons

Attribution-NonCommercial 4.0 License (<https://creativecommons.org/licenses/by-nc/4.0/>) which permits non-commercial use, reproduction and distribution of the work without further permission provided the original work is attributed as specified on the SAGE and Open Access pages (<https://us.sagepub.com/en-us/nam/open-access-at-sage>).

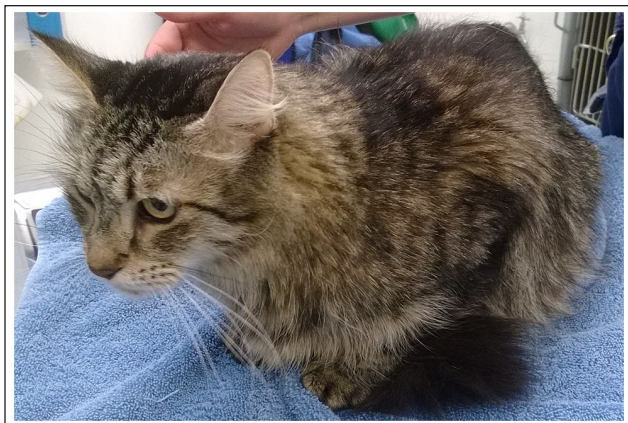

Figure 1 The cat at the first referral presentation preoperatively. Note the poor body condition and sparse fur coat

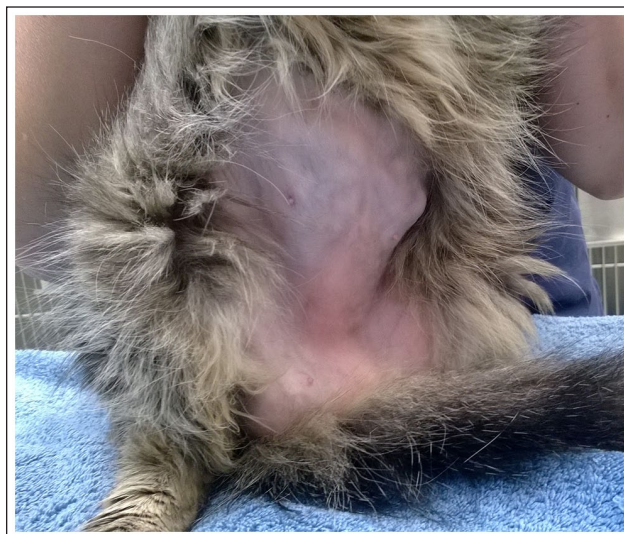

Figure 2 The cat at the first referral presentation showing gynaecomastia. The abdominal fur was clipped for ultrasonography

total thyroxine (TT4) was low ($<10\text{nmol/l}$; reference interval [RI] 10–60).

Three months later the cat presented for mild diffuse mammary gland development over several weeks. Polydipsia and polyphagia continued, and USG was 1.030. Six months later the cat re-presented with persistent polydipsia, polyphagia and progressive gynaecomastia. Fur regrowth following abdominal ultrasound 13 months earlier was incomplete. Abdominal ultrasound identified progressive left adrenomegaly (approximately 1.4cm thick), while the right adrenal gland was unremarkable (approximately 0.2cm thick at the caudal pole, 0.84cm length). Haematology revealed mild neutropenia ($2.2 \times 10^9/\text{l}$; RI 3.8–10.1) and lymphopenia ($0.5 \times 10^9/\text{l}$; RI 1.6–7.0). Biochemistry revealed normoglycaemia, mild hypokalaemia (3.4mmol/l; RI 3.7–4.9), hypercholesterolaemia (6.4mmol/l; RI 2.4–5.2) and hypertriglyceridaemia (0.8mmol/l; RI 0.1–0.6). TT4 was 17nmol/l (RI 6–52). Urinalysis identified 1+ proteinuria, 2+ glucosuria and USG was 1.023. The urinary protein:creatinine ratio was 0.5 (RI <0.4).

Examination at referral revealed diffuse, moderate and symmetrical mammary gland development without discharge (Figures 1 and 2) and a body condition score (BCS) of 3/9. Blood pressure measurement was not possible owing to the cat's temperament, and fundic examination was unremarkable. Sexualised behavioural changes and virilisation were not observed. A low-dose dexamethasone suppression test was performed, and multiple adrenal hormones were measured (Table 1). The results supported a diagnosis of hyperprogesteronism, hyperaldosteronism and hypercortisolism.

CT scans (pre- and postcontrast of the head [soft tissue, brain and bone algorithms] and abdomen [soft tissue and bone algorithms]) were performed for surgical planning and to investigate possible pituitary-dependent

(PD) hypercortisolism. Pertinent findings included left adrenal mass (approximately 1.6cm width \times 1.5cm height \times 1.7cm length), which was heterogeneously contrast enhancing with a small peripheral mineral attenuating area caudomedially (Figures 3 and 4), mild prostatomegaly (approximately 1cm \times 1.6cm in short axis; Figures 5 and 6)⁵ and moderate mammary development. The left phrenicoabdominal vein could not be clearly visualised. The right adrenal gland was unremarkable (approximately 0.3cm width \times 0.2cm height \times 0.8cm length). The pituitary gland was unremarkable.

The left adrenal gland was approached through a ventral midline laparotomy under general anaesthesia. The left adrenal mass was exposed by blunt dissection and a plane was developed between the renal vessels and the caudal aspect of the gland. The phrenicoabdominal vein was isolated and ligated at its entry into the vena cava. The multiple penetrating vessels on the dorsal aspect of the gland were attenuated using a combination of bipolar electrocautery and a vessel sealing device. The adrenal gland was removed in its entirety without rupture of its capsule.

Left adrenal gland histopathology revealed a poorly demarcated, non-encapsulated multinodular epithelial proliferation effacing much of the normal adrenal architecture. A compressed thin rim of atrophied cortical tissue was seen peripheral to the mass (Figure 7), and some remnant medullary tissue was evident. The neoplastic cells were organised into variously sized packets separated by a sparse fibrovascular stroma of varying thickness with abundant vascular spaces amongst the neoplastic cells. The proliferating cells were medium to large and polyhedral with abundant pale granular eosinophilic or, less commonly, vacuolated

Table 1 Hormone test results

Hormones (units)	Preoperative	2 months postoperative	8 months postoperative	11 months postoperative	RI
Progesterone (nmol/l)*	8.6	<0.2	3.1	1.6	0.16–2.2 ¹
17 α -hydroxyprogesterone (nmol/l)*	0.3	–	–	–	0.24–0.91 ¹
Testosterone (nmol/l)*	0.3	–	–	–	<0.5 ²
Oestradiol (pmol/l)*	30	–	–	–	143.5–327.8 ¹
Aldosterone (pmol/l)*	1710	130	366	–	110–540 ³
Renin (fmol/l/s)*	155	402	222	–	60–630 ³
Aldosterone: renin*	11	0.3	1.2	–	0.3–3.8 ³
Metanephrine (pmol/l) [†]	834	–	–	–	407–1799 ⁴
Normetanephrine (pmol/l) [†]	2270	–	–	–	2472–4550 ⁴
Resting cortisol (nmol/l) [†]	–	<28	–	–	28–138
Low-dose dexamethasone suppression test (0.1 mg/kg IV) (nmol/l) [†]	0 h: 53 4 h: 30 8 h: 52	–	–	–	28–138
ACTH stimulation test (nmol/l) (125 μ g tetracosactide acetate IM) [†]	–	–	0 h: 72 45 min: 84	–	28–138

Results outside the reference intervals (RIs) are in bold

*Sydney South West Pathology Service, Australia

[†]IDEXX Laboratories, Australia

ACTH = adrenocorticotrophic hormone

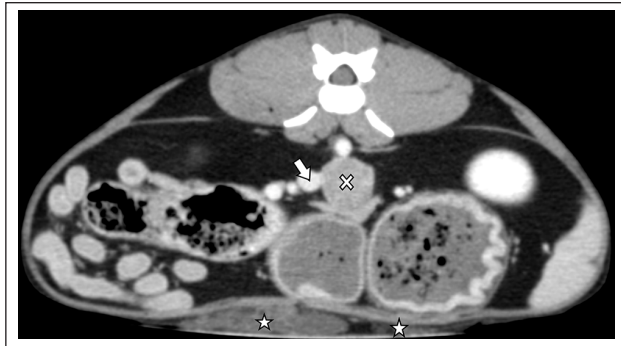

Figure 3 Axial postcontrast CT image displaying the left adrenal mass (white cross) left lateral to the caudal vena cava (white arrow) and mammary development (white stars)

cytoplasm (Figure 8). The nuclei were intermediate to large in size, round to oval and vesicular with a prominent single nucleolus. Nuclei were centrally or eccentrically located within the cell; occasional karyomegaly, as well as plentiful binucleates and rare cells with three or more nuclei, were noted. There was moderate-to-marked anisocytosis and anisokaryosis with few mitoses (one mitotic figure detected in 10 contiguous high-power fields [$\times 400$]). Populations of smaller cells with darker nuclei and darkly eosinophilic cytoplasm were also seen throughout the proliferation. Small areas of peripheral necrosis with mineralisation were seen. Angiolymphatic and capsular invasion were not evident. The mass was diagnosed as an adrenocortical tumour, most consistent with an adenoma given the low mitotic index and absence of definitive criteria of malignancy, specifically capsular and angiolymphatic invasion.

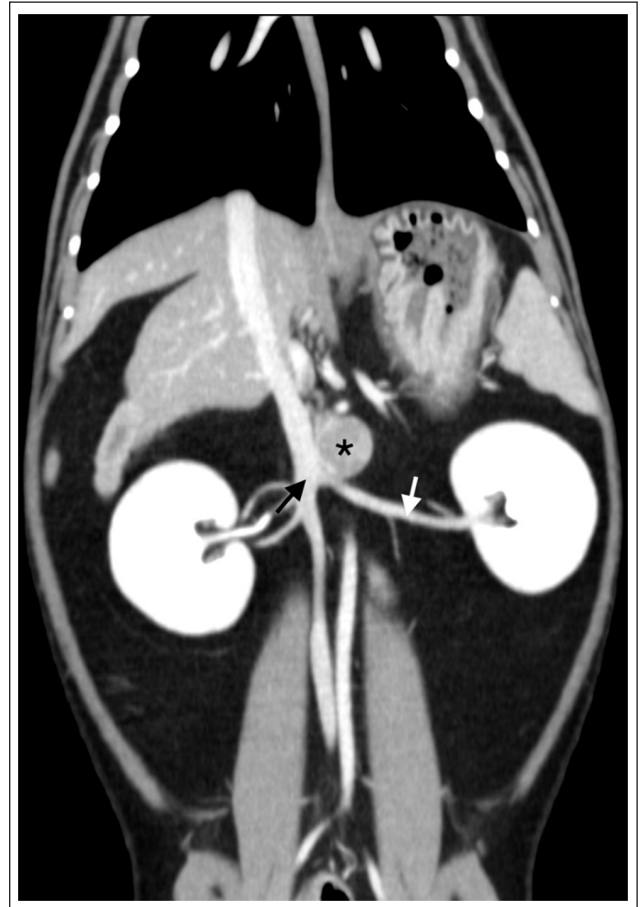


Figure 4 Sagittal postcontrast CT image displaying the close proximity of the left adrenal mass (*) with the left renal vein (white arrow) and caudal vena cava (black arrow)

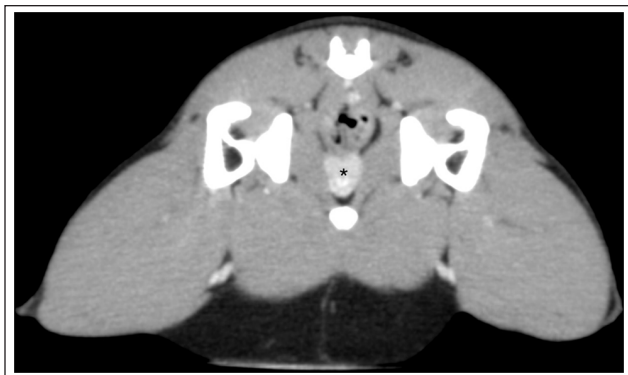


Figure 5 Axial postcontrast CT image displaying the suspect prostatomegaly (*)

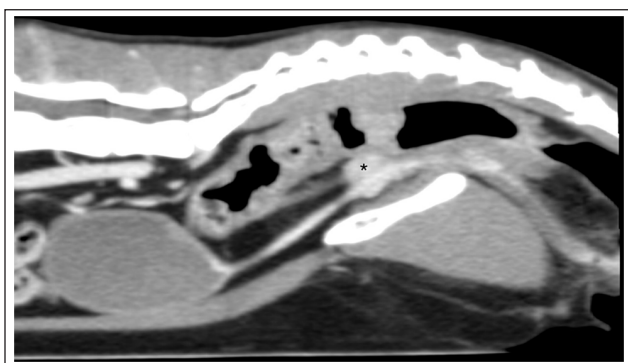


Figure 6 Sagittal postcontrast CT image displaying the suspect prostatomegaly (*)

Postoperative treatment included intravenous fluids (Hartmann's solution, total of 0.06 mmol/kg/h potassium chloride), methadone (0.2 mg/kg q4h for 24h), cefazolin (30 mg/kg IV q8h for 48h) and a hydrocortisone continuous rate infusion (0.5 mg/kg/h for 48h) before starting prednisolone (1.25 mg PO q24h). The postoperative potassium concentration was 3.0 mmol/l (RI 4.0–4.5). The cat ate well postoperatively; however, 24h later the potassium concentration had decreased to 2.5 mmol/l and supplementation was increased to 0.15 mmol/kg/h. Methadone was reduced to every 6h for 48h. By 72h postoperatively the potassium concentration had increased to 3.3 mmol/l. The cat was discharged with buprenorphine (0.02 mg/kg sublingually q8h for 3 days) and a 6-week tapering prednisolone course.

Two months postoperatively, polyphagia had resolved, fur was appropriately regrowing and gynaecomastia had almost completely resolved. Urinalysis revealed a USG of 1.045. Haematology was unremarkable. Biochemistry identified a blood urea concentration of 17.3 mmol/l (RI 5–15) and TT4 was low (<10 nmol/l; RI 10–60). Hormone measurements were repeated (Table 1). Hyperaldosteronism had resolved. Owing to concerns of prolonged adrenocortical function recovery postoperatively,

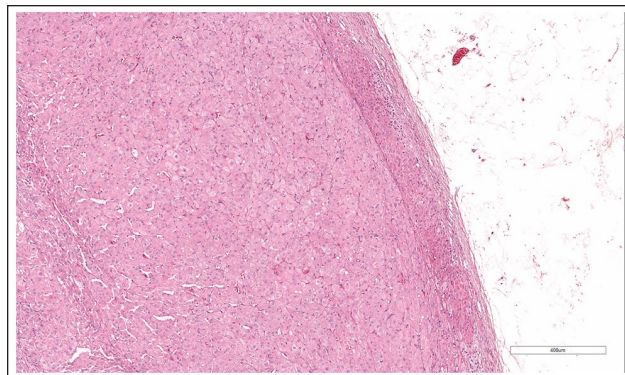


Figure 7 Adrenal capsule, compressed remnant cortical tissue and proliferation of neoplastic cells. Haematoxylin and eosin stain

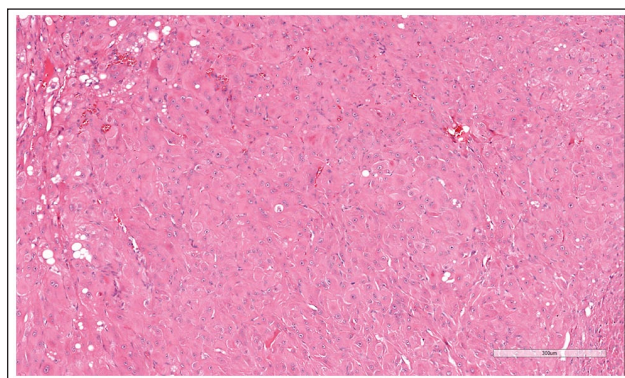


Figure 8 Proliferating epithelial cells. Note the karyomegaly, binucleated and multinucleated cells. Haematoxylin and eosin stain

prednisolone was recommenced at 1.25 mg PO every 3 days for another 6 weeks. Follow-up was done by telephone rechecks owing to the COVID-19 pandemic.

Eight months postoperatively the cat had gained 500g, had a BCS of 5/9, gynaecomastia had resolved, and the clipped fur had completely regrown and was longer and thicker (Figure 9). Haematology, biochemistry and TT4 (21 nmol/l; RI 6–52) were within the RIs. An adrenocorticotrophic hormone stimulation test was performed with 125 µg tetracosactide acetate (Synacthen; Novartis) intramuscularly owing to the patient's temperament (Table 1), which excluded hypo- or hypercortisolism.^{6,7}

The 8-month progesterone level was above the published RI (Table 1).⁵ Progesterone levels were determined for 13 clinically healthy staff-owned cats at the same laboratory (Sydney South West Pathology Service). Serum had been collected for another study with consent for use in other projects (University of Sydney Animal Ethics project approval number 2020/1700). The 13 healthy cats had a median progesterone level of 0.8 nmol/l (range <0.2–3.6 nmol/l) and median age of



Figure 9 The cat 8 months postoperatively. Note the thick fur regrowth and normal body condition score

5 years (range 1.5–14) (Table 2). Eleven months postoperatively the cat was clinically normal and progesterone was within the RI (Table 1).

Discussion

Functional adrenal neoplasms are infrequently reported in cats, with most hypersecreting aldosterone or cortisol.^{8–10} Feline sex steroid-producing tumours are rare, with only 20 previously reported.^{2,3,9,11–21} Cats with hyperprogesteronism commonly present with clinical signs consistent with Cushing's disease, as in this case, and can have secondary diabetes mellitus.^{11–13,15,16,20,22} Cats with tumours producing testosterone, androstenedione and/or oestradiol more commonly present with sexualised behaviours and physical changes.^{2,3,17–20} A single case of gynaecomastia in a neutered male cat secondary to an oestrogen-secreting adrenocortical carcinoma, which also displayed sexual behaviours, has been reported.² A neutered male ferret with gynaecomastia with an adrenocortical carcinoma has been reported; however, hormone measurements were not performed.²³

Gynaecomastia is common in humans and defined as a glandular proliferation of male breast tissue causing breast enlargement. Causes range from benign physiological processes to rare neoplasms.²⁴ In humans, gynaecomastia associated with feminising adrenal tumours is usually secondary to hyperoestrogenism, although other hormones such as dehydroepiandrosterone (DHEA), DHEA sulfate (DHEAS) and androstenedione have been reported.^{25–33} Excess androgens can be aromatised peripherally to oestradiol, leading to clinical signs of hyperoestrogenism. Progesterone-producing adrenal tumours are extremely rare in humans, with four cases reported in women with secondary amenorrhoea or oligomenorrhoea.^{34–37}

Mammary enlargement in male cats is rare and can be caused by neoplasia or fibroadenomatous hyperplasia (MFH).³⁸ MFH is a benign proliferation of ductal epithelium

Table 2 Serum progesterone levels of 13 healthy cats

Cat	Age (years)	Sex	Breed	Progesterone level (nmol/l)*
1	6	MN	Sphynx	<0.2
2	14	FN	DSH	<0.2
3	1.5	MN	DMH	0.3
4	2	MN	DMH	0.4
5	6	MN	DSH	0.5
6	5	MN	DSH	0.7
7	8	MN	DSH	0.8
8	2	MN	DSH	2.0
9	5	MN	DSH	2.2
10	4	MN	DSH	2.4
11	6	MN	DSH	2.7
12	14	MN	DSH	2.8
13	5	MN	DSH	3.6

*Sydney South West Pathology Service, Australia
MN = male neutered; FN = female neutered; DSH = domestic shorthair; DMH = domestic mediumhair

and mammary stroma, usually seen in young female cats.³⁹ Endogenous progesterone and exogenous progestogens are involved in the pathogenesis; however, idiopathic cases, including male cats, are reported.^{39–43} Resolution subsequent to ovariectomy, withdrawal of progestogens, progesterone receptor antagonist treatment, mastectomy or, occasionally, spontaneously is reported.

Both pituitary and ovarian hormones are involved in normal mammary development. Mammary tissue contains both oestrogen and progesterone receptors. Progesterone is involved in mammary duct epithelium and stromal proliferation. Feline cases of spontaneous or progestogen-induced MFH show high levels of mammary progesterone receptors and secondary local expression of growth hormone and insulin-like growth factor-1, considered to be the mechanism of mammary tissue proliferation, compared with normal mammary tissue.^{39,43–46} In contrast, oestrogen receptors have been detected in a lower proportion of MFH cases.^{44,46} Why some cats and not others develop MFH secondary to progesterone or progestogen exposure is unclear and could be due to individual variation in tissue sensitivity.^{39,44}

Twelve other cats with adrenal tumours resulting in hyperprogesteronism have been published (Table 3), but none had gynaecomastia.¹⁰ In the case reported here, we postulate that gynaecomastia occurred secondary to hyperprogesteronism and that adrenal tumour-associated gynaecomastia in cats could, in some cases, have different mechanisms to those reported in humans. However, we did not perform mammary biopsy or immunohistochemistry to assess for progesterone receptors. Progesterone is a precursor hormone for androgens, oestrogens, aldosterone and cortisol. Paraneoplastic aberrant steroid synthesis pathways or enzyme deficiencies can also occur in

Table 3 Published progesterone-secreting adrenal tumours in cats with reported progesterone levels

Source	Age (years)	Sex	Breed	Progesterone level (nmol/l)
Boord and Griffin ¹¹	7	MN	Himalayan	11.5
DeClue et al ¹²	12	MN	DLH	31.64
Briscoe et al ¹³	14	FN	DSH	19
Leshinsky et al ¹⁴	12	MN	DSH	16.1
Guerios et al ¹⁵	14	FN	DSH	8.24
Rossmesl et al ¹⁶	7	MN	DSH	41.98
Millard et al ¹⁸	13	MN	DSH	6.3
Meler et al ¹⁹	15	FN	DSH	1.59

MN = male neutered; FN = female neutered; DSH = domestic shorthair; DLH = domestic longhair

adrenal tumours. Oestradiol, testosterone and 17 α -hydroxyprogesterone were within the RIs in this case. This does not exclude hypersecretion of other hormones, or their precursors, which may have oestrogenic effects such as androstenedione, DHEA or DHEAS, which were not measured owing to limited availability. This cat did not have sexualised behavioural or physical changes as is usually reported in cats hypersecreting oestrogen or testosterone.¹⁰ This further supports hyperprogesteronism as the cause of gynecomastia.

Prostatic disease is rare in cats. The mild prostatomegaly observed in this case could have been incidental or secondary to the functional adrenal mass. Benign prostatic hyperplasia in dogs and humans has an unclear pathogenesis but may be due to increased intraprostatic dihydrotestosterone.⁴⁷ In male ferrets, prostatomegaly is associated with adrenocortical disease. Although the exact pathogenesis is unclear, increased sex hormone levels are believed to stimulate proliferation of prostatic tissue.^{48–50} Whether hyperprogesteronism, or an unmeasured hormone, played a role in this case is speculative and postoperative prostatic imaging was not performed.

Clinical signs of Cushing's disease in this case could have been due to both hypercortisolism and hyperprogesteronism.¹⁰ Preoperatively, the cat did not have clinical signs of hyperaldosteronism; however, conscious blood pressure measurement was not possible. Interestingly, the cat became hypokalaemic postoperatively, which could be explained by a combination of hyperaldosteronism, fasting and fluid therapy.

The cat's initial presentation for bacterial cystitis is uncommon for a 7-year-old male neutered cat with adequate urine-concentrating ability. Immunosuppression secondary to hypercortisolism may have predisposed to infection.¹⁰ Biochemistry performed at the time of referral identified fasting hypertriglyceridaemia and hypercholesterolaemia, consistent with previous reports of feline hypercortisolism.¹⁰ The right adrenal gland measurements reduced over time but remained within normal size limits. This may have been due to atrophy

secondary to a hyperfunctional left adrenal gland or differing imaging modalities and operators.

The pituitary gland of this cat was unremarkable on CT scan; however, this does not exclude a pituitary tumour. The low-dose dexamethasone suppression test was suggestive of PD hypercortisolism with a 4h cortisol of <38nmol/l; however, this was not <50% of baseline, which is considered a more sensitive indicator.²¹ This, combined with the unilateral adrenal mass and resolution of hypercortisolism postoperatively, supports a diagnosis of adrenal-dependent hypercortisolism.

The low cortisol and progesterone 2 months postoperatively may have been secondary to prolonged adrenocortical recovery or recent prednisolone withdrawal. The transiently low TT4 preoperatively may have been secondary to hypercortisolism, and postoperatively may have been due to recent prednisolone withdrawal.

Hormone measurements at a human laboratory (progesterone, 17 α -hydroxyprogesterone, testosterone, oestradiol, aldosterone, renin) and a veterinary laboratory (metanephrine, normetanephrine), which lacked species-specific RIs, was a limitation. The initial progesterone level of the cat was above the published RI and consistent with published adrenal-origin cases of hyperprogesteronism (Tables 1 and 3).¹ Comparison with the progesterone levels of 13 healthy cats suggested that the 8-month postoperative progesterone level was, in fact, normal (Table 2). Ideally, a larger number of cats, stricter inclusion criteria for health and cats with a higher median age should have been used; however, this was beyond the scope of this report.

Conclusions

To our knowledge, this is the second report of gynecomastia secondary to an adrenal tumour and the first associated with hyperprogesteronism in a cat.

Acknowledgements The authors would like to thank the cat's owners, staff and students of the Valentine Charlton Cat Centre and the Veterinary Pathology Diagnostic Services histologists for provision of excellent technical assistance.

Conflict of interest The authors declared no potential conflicts of interest with respect to the research, authorship, and/or publication of this article.

Funding The authors received no financial support for the research, authorship, and/or publication of this article.

Ethical approval The work described in this manuscript involved the use of non-experimental (owned or unowned) animals. Established internationally recognised high standards ('best practice') of veterinary clinical care for the individual patient were always followed and/or this work involved the use of cadavers. Ethical approval from a committee was therefore not specifically required for publication in *JFMS Open Reports*. Although not required, where ethical approval was still obtained, it is stated in the manuscript.

Informed consent Informed consent (verbal or written) was obtained from the owner or legal custodian of all animal(s) described in this work (experimental or non-experimental animals, including cadavers) for all procedure(s) undertaken (prospective or retrospective studies). For any animals or people individually identifiable within this publication, informed consent (verbal or written) for their use in the publication was obtained from the people involved.

References

- Nadolski AC, Markovich JE, Jennings SH, et al. **Mammary development, hyperestrogenemia, and hypocortisolemia in a male cat with an adrenal cortical carcinoma.** *Can Vet J* 2016; 57: 1077–1080.
- Sumner JP, Hulsebosch SE, Dudley RM, et al. **Sex-hormone producing adrenal tumors causing behavioral changes as the sole clinical sign in 3 cats.** *Can Vet J* 2019; 60: 305–310.
- Javadi S, Slingerland LI, van de, Beek MG, et al. **Plasma renin activity and plasma concentrations of aldosterone, cortisol, adrenocorticotropic hormone, and α -melanocyte-stimulating hormone in healthy cats.** *J Vet Intern Med* 2004; 18: 625–631.
- Wimpole JA, Adagra CF, Billson MF, et al. **Plasma free metanephrines in healthy cats, cats with non-adrenal disease and a cat with suspected pheochromocytoma.** *J Feline Med Surg* 2010; 12: 435–440.
- Dimitrov R and Toneva Y. **Computed tomographic features of feline prostate gland.** *Acta Morphol Anthropol* 2007; 12: 186–192.
- Peterson M and Kempainen R. **Comparison of intravenous and intramuscular routes of administering cosyntropin for corticotropin stimulation testing in cats.** *Am J Vet Res* 1992; 53: 1392–1395.
- Peterson ME and Kempainen RJ. **Comparison of the immunoreactive plasma corticotropin and cortisol responses to two synthetic corticotropin preparations (tetracosactrin and cosyntropin) in healthy cats.** *Am J Vet Res* 1992; 53: 1752–1755.
- Ash RA, Harvey AM and Tasker S. **Primary hyperaldosteronism in the cat: a series of 13 cases.** *J Feline Med Surg* 2005; 7: 173–182.
- Daniel G, Mahony OM, Markovich JE, et al. **Clinical findings, diagnostics and outcome in 33 cats with adrenal neoplasia (2002–2013).** *J Feline Med Surg* 2016; 18: 77–84.
- Boland LA and Barrs VR. **Peculiarities of feline hyperadrenocorticism: update on diagnosis and treatment.** *J Feline Med Surg* 2017; 19: 933–947.
- Boord M and Griffin C. **Progesterone secreting adrenal mass in a cat with clinical signs of hyperadrenocorticism.** *J Am Vet Med Assoc* 1999; 214: 666–669.
- DeClue AE, Breshears LA, Pardo ID, et al. **Hyperaldosteronism and hyperprogesteronism in a cat with an adrenal cortical carcinoma.** *J Vet Intern Med* 2005; 19: 355–358.
- Briscoe K, Barrs VR, Foster DF, et al. **Hyperaldosteronism and hyperprogesteronism in a cat.** *J Feline Med Surg* 2009; 11: 758–762.
- Leshinsky J, Beatty JA, Fawcett A, et al. **Aldosterone and progesterone-secreting adrenocortical adenocarcinoma in a cat with a concurrent meningioma.** *JFMS Open Rep* 2016; 2. DOI: 10.1177/2055116915624448.
- Guerios SD, Souza CHdM and Bacon NJ. **Adrenocortical tumor in a cat secreting more than one type of corticosteroid.** *JFMS Open Rep* 2015; 1. DOI: 10.1177/2055116915617970.
- Rossmel J, Jr, Scott-Moncrieff J, Siems J, et al. **Hyperadrenocorticism and hyperprogesteronemia in a cat with an adrenocortical adenocarcinoma.** *J Am Anim Hosp Assoc* 2000; 36: 512–517.
- Boag A, Neiger R and Church D. **Trilostane treatment of bilateral adrenal enlargement and excessive sex steroid hormone production in a cat.** *J Small Anim Pract* 2004; 45: 263–266.
- Millard RP, Pickens EH and Wells KL. **Excessive production of sex hormones in a cat with an adrenocortical tumor.** *J Am Vet Med Assoc* 2009; 234: 505–508.
- Meler EN, Scott-Moncrieff JC, Peter AT, et al. **Cyclic estrous-like behavior in a spayed cat associated with excessive sex-hormone production by an adrenocortical carcinoma.** *J Feline Med Surg* 2011; 13: 473–478.
- Mitchell JW, Mayhew PD, Culp WT, et al. **Outcome of laparoscopic adrenalectomy for resection of unilateral non-invasive adrenocortical tumors in 11 cats.** *Vet Surg* 2017; 46: 714–721.
- Feldman EC. **Hyperadrenocorticism in cats.** In: Feldman EC, Nelson RW, Reusch C, et al (eds). *Canine and feline endocrinology*. 4th ed. St Louis, MO: Elsevier, 2014, pp 452–484.
- Feldman EC, Nelson RW, Reusch C, et al. *Canine and feline endocrinology*, e-book. St Louis, MO: Elsevier Health Sciences, 2014.
- Mor N, Qualls C, Jr and Hoover J. **Concurrent mammary gland hyperplasia and adrenocortical carcinoma in a domestic ferret.** *J Am Vet Med Assoc* 1992; 201: 1911–1912.
- Dickson G. **Gynecomastia.** *Am Fam Phys* 2012; 85: 716–722.
- Kidd MT, Karlin NJ and Cook CB. **Feminizing adrenal neoplasms: case presentations and review of the literature.** *J Clin Oncol* 2011; 29: e127–e130.
- Moreno S, Guillermo M, Decoux M, et al. **Feminizing adrenocortical carcinomas in male adults. A dire prognosis: three cases in a series of 801 adrenalectomies and review of the literature.** *Ann Endocrinol (Paris)* 2006; 67: 32–38.
- Gabrilove J, Sharma D, Wotiz H, et al. **Feminizing adrenocortical tumors in the male: a review of 52 cases including a case report.** *Medicine* 1965; 44: 37–79.

- 28 Swerdloff RS and Ng CM. Gynecomastia: etiology, diagnosis, and treatment. <https://www.ncbi.nlm.nih.gov/books/NBK279105/> (accessed September 2, 2021).
- 29 Zayed A, Stock J, Liepman M, et al. **Feminization as a result of both peripheral conversion of androgens and direct estrogen production from an adrenocortical carcinoma.** *J Endocrinol Invest* 1994; 17: 275–278.
- 30 Takeuchi T, Yoto Y, Ishii A, et al. **Adrenocortical carcinoma characterized by gynecomastia: a case report.** *Clin Pediatr Endocrinol* 2018; 27: 9–18.
- 31 Watanabe T, Yasuda T, Noda H, et al. **Estrogen secreting adrenal adenocarcinoma in an 18-month-old boy.** *Endocrine J* 2000; 47: 723–730.
- 32 Bouyahia O, Gharsallah L, Ouederni M, et al. **Feminizing adrenocortical adenoma in a 5 year-old girl.** *J Pediatr Endocrinol Metab* 2009; 22: 79–84.
- 33 Farida C, Ilyes B, Smina Y, et al. **Feminizing adrenal tumors: our experience about three cases.** *Indian J Endocrinol Metab* 2013; 17: 509.
- 34 Duan L, Yang Y, Gu Y, et al. **The utility of adrenal and ovarian venous sampling in a progesterone-producing adrenal tumor and review of the literature.** *Endocrine* 2019; 66: 319–325.
- 35 Sone M, Shibata H, Homma K, et al. **Close examination of steroidogenesis disorders in a DOC- and progesterone-producing adrenocortical carcinoma.** *Endocrine* 2009; 35: 25–33.
- 36 Takahashi Y, Ninomiya J, Horiguchi J, et al. **Primary amenorrhea accompanied by adrenal adenoma: start of menarche soon after tumor resection.** *Intern Med* 2002; 41: 972–976.
- 37 Zonneveld Pv, Koppeschaar H, De Bruin T, et al. **A patient with a progesterone-producing adrenal adenoma who presented with primary amenorrhea.** *Gynecol Endocrinol* 1995; 9: 189–194.
- 38 Skorupski KA, Overley B, Shofer FS, et al. **Clinical characteristics of mammary carcinoma in male cats.** *J Vet Intern Med* 2005; 19: 52–55.
- 39 Görlinger S, Kooistra H, Van den Broek A, et al. **Treatment of fibroadenomatous hyperplasia in cats with aglepristone.** *J Vet Intern Med* 2002; 16: 710–713.
- 40 Mayayo SL, Bo S and Pisu MC. **Mammary fibroadenomatous hyperplasia in a male cat.** *JFMS Open Rep* 2018; 4. DOI: 10.1177/2055116918760155.
- 41 MacDougall LD. **Mammary fibroadenomatous hyperplasia in a young cat attributed to treatment with megestrol acetate.** *Can Vet J* 2003; 44: 227–229.
- 42 Wehrend A, Hospes R and Gruber A. **Treatment of feline mammary fibroadenomatous hyperplasia with a progesterone-antagonist.** *Vet Rec* 2001; 148: 346–347.
- 43 Loretto AP, da Silva Ilha MR, Ordás J, et al. **Clinical, pathological and immunohistochemical study of feline mammary fibroepithelial hyperplasia following a single injection of depot medroxyprogesterone acetate.** *J Feline Med Surg* 2005; 7: 43–52.
- 44 De Las Mulas JM, Millan Y, Bautista M, et al. **Oestrogen and progesterone receptors in feline fibroadenomatous change: an immunohistochemical study.** *Res Vet Sci* 2000; 68: 15–21.
- 45 Niel MV, Millán Y, Ordás J, et al. **Progesterone receptors in normal, dysplastic and tumourous feline mammary glands. Comparison with oestrogen receptors status.** *Res Vet Sci* 2002; 72: 153–161.
- 46 Millanta F, Calandrella M, Vannozzi I, et al. **Steroid hormone receptors in normal, dysplastic and neoplastic feline mammary tissues and their prognostic significance.** *Vet Rec* 2006; 158: 821–824.
- 47 Yoon S, Alfajaro MM, Cho KO, et al. **Perfusion change in benign prostatic hyperplasia before and after castration in a canine model: contrast enhanced ultrasonography and CT perfusion study.** *Theriogenology* 2020; 156: 97–106.
- 48 Coleman G, Chavez M and Williams B. **Cystic prostatic disease associated with adrenocortical lesions in the ferret (*Mustela putorius furo*).** *Vet Pathol* 1998; 35: 547–549.
- 49 Besso JG, Tidwell AS and Gliatto JM. **Retrospective review of the ultrasonographic features of adrenal lesions in 21 ferrets.** *Vet Radiol Ultrasound* 2000; 41: 345–352.
- 50 Rosenthal KL and Peterson ME. **Evaluation of plasma androgen and estrogen concentrations in ferrets with hyperadrenocorticism.** *J Am Vet Med Assoc* 1996; 209: 1097–1102.