



Sialocoele associated with the molar salivary gland in a British Shorthair cat

Authors: Kilduff-Taylor, Andrea, Gombert, Alexis, Hahn, Harriet, and Dempsey, Lara M

Source: Journal of Feline Medicine and Surgery Open Reports, 7(1)

Published By: SAGE Publishing

URL: <https://doi.org/10.1177/2055116921990307>

BioOne Complete (complete.BioOne.org) is a full-text database of 200 subscribed and open-access titles in the biological, ecological, and environmental sciences published by nonprofit societies, associations, museums, institutions, and presses.

Your use of this PDF, the BioOne Complete website, and all posted and associated content indicates your acceptance of BioOne's Terms of Use, available at www.bioone.org/terms-of-use.

Usage of BioOne Complete content is strictly limited to personal, educational, and non - commercial use. Commercial inquiries or rights and permissions requests should be directed to the individual publisher as copyright holder.

BioOne sees sustainable scholarly publishing as an inherently collaborative enterprise connecting authors, nonprofit publishers, academic institutions, research libraries, and research funders in the common goal of maximizing access to critical research.



Sialocoele associated with the molar salivary gland in a British Shorthair cat

Andrea Kilduff-Taylor¹ , Alexis Gombert² , Harriet Hahn³ and Lara M Dempsey⁴

Journal of Feline Medicine and Surgery Open Reports

Volume: 7: 1–6

© The Author(s) 2021

Article reuse guidelines:

sagepub.com/journals-permissions

DOI: 10.1177/2055116921990307

journals.sagepub.com/home/jfmsopenreports

This paper was handled and processed by the European Editorial Office (ISFM) for publication in *JFMS Open Reports*



Abstract

Case summary A 16-year-old neutered female British Shorthair cat presented with a 5-year history of swelling lateral to the left mandible that intermittently discharged viscous, clear fluid from a small defect in the skin. CT, ultrasonography, physical characteristics and cytology of the fluid were suggestive of sialocoele. CT showed a large, cavitary, fluid-filled mass lateral to the left mandible. A ventral approach was used to resect the left mandibular, sublingual and molar salivary glands and sialocoele. Histopathology of the molar and mandibular and sublingual glands showed chronic active sialoadenitis with more severe changes in the molar gland. There were no signs of recurrence of the sialocoele 12 months after surgery.

Relevance and novel information This is the first report of a cranial cervical sialocoele potentially involving the molar salivary gland in a cat. Resection of the mandibular, sublingual and molar salivary glands should be considered in cats that present with a cranial cervical sialocoele.

Keywords: Salivary glands; salivary mucocoele; sialocoele; computed tomography; soft tissue surgery

Accepted: 4 January 2021

Introduction

The major salivary glands in dogs and cats are the parotid, mandibular, sublingual and zygomatic glands. Cats have a pair of well-developed molar salivary glands located caudal to the lateral commissure of the lip and ventral to the facial vein. These are not present in dogs.^{1,2}

Sialocoeles are caused by rupture of a salivary duct or gland, which results in subcutaneous collection of saliva.^{1,2} They are rare in cats and have previously been reported to be associated with the mandibular, sublingual, zygomatic and parotid glands.^{3–9} They most commonly present as a sublingual swelling or ranula.^{1–5} In the current literature there has been no report of a cervical sialocoele originating from the molar salivary gland in cats.^{1,2,4,5,8,9} Furthermore, some authors have gone as far as to state that sialocoeles in cats can affect all glands except the molar salivary gland.⁵ This case presents the first reported evidence that disease of the molar salivary gland has the potential to produce a sialocoele in cats and therefore clinicians evaluating cervical sialocoeles in cats must give consideration to this gland as a potential

cause of sialocoele. Surgical removal of the affected salivary glands and their associated ducts, as well as marsupialisation of the sialocoele (if a ranula is present) is currently the treatment of choice.^{1,2,4,5,9–11}

Case description

A 16-year-old neutered female British Shorthair cat weighing 4.5 kg was evaluated by the soft tissue surgery service at ChesterGates Veterinary Specialists (Chester,

¹Willows Veterinary Centre and Referral Service, Solihull, UK

²Diagnostic Imaging, Sveriges Lantbruksuniversitet Veterinärmedicin och Husdjursvetenskap, Uppsala, Sweden

³Diagnostic Imaging, Highcroft Veterinary Referrals, Bristol, UK

⁴Soft Tissue Surgery, Willows Veterinary Centre and Referral Service, Solihull, UK

Corresponding author:

Andrea Kilduff-Taylor MA, VetMB, MRCVS, Willows Veterinary Centre and Referral Service, Highlands Road, Shirley, Solihull B90 4NH, UK

Email: andreakilduff@gmail.com



Creative Commons Non Commercial CC BY-NC: This article is distributed under the terms of the Creative Commons

Attribution-NonCommercial 4.0 License (<https://creativecommons.org/licenses/by-nc/4.0/>) which permits non-commercial use, reproduction and distribution of the work without further permission provided the original work is attributed as specified on the SAGE and Open Access pages (<https://us.sagepub.com/en-us/nam/open-access-at-sage>).

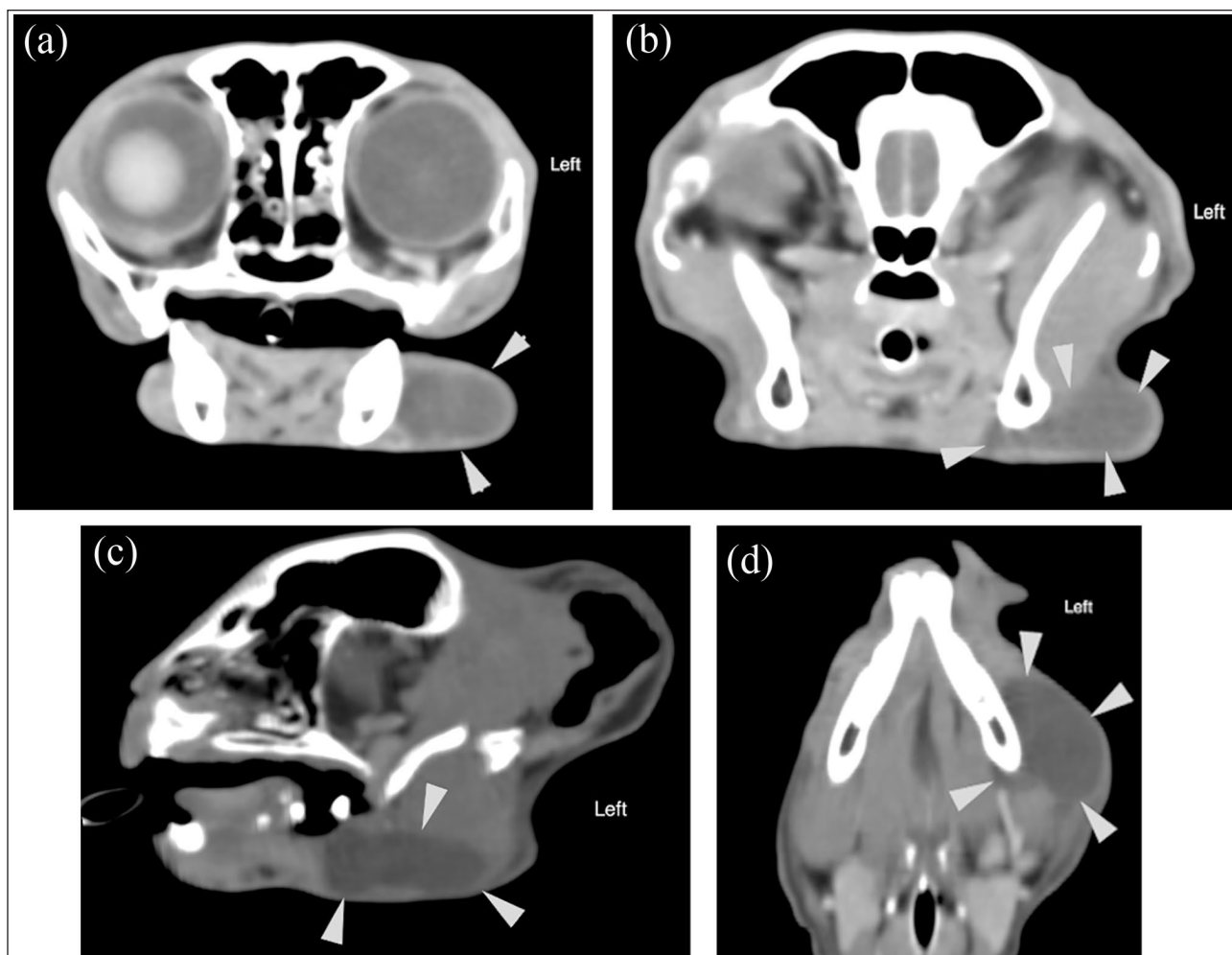


Figure 1 Transverse (a,b), sagittal (c) and dorsal (d) CT images of the head of a 16-year-old British Shorthair cat in soft tissue algorithm, after contrast injection. This shows a well-delineated, hypoattenuating, cavitary, thin-walled, fluid-filled mass (arrowheads) measuring $14 \times 18 \times 35$ mm extending from the level of the first premolar tooth to the level of the left temporomandibular joint, lateral (and slightly ventral) to the left mandible

UK) for a recurrent, fluctuant subcutaneous swelling lateral to the left mandible. This swelling had first been noted by the owner 5 years ago. It was observed to intermittently discharge viscous, clear fluid from a small defect in the skin overlying the ventrolateral aspect of the swelling. At presentation, no skin defect was present. There was no history of trauma associated with the swelling, although the cat did go outdoors, so this possibility could not be excluded. The cat was reported to be in good general health.

Exploratory surgery had been attempted by the primary care veterinarian to remove the fluid-filled mass 3 months previously, but this recurred. The swelling did not appear to be painful, or affect eating or drinking. No hypersialorrhoea or dysphagia had been noted by the owner or referring veterinarian.

General clinical examination revealed tachycardia (heart rate 220 beats/min) and a gallop rhythm to the

heart. The cat underwent echocardiography and electrocardiogram, as well as blood testing for biochemistry, haematology and total thyroxine. Mild hypertrophic cardiomyopathy and tricuspid valve regurgitation without left atrial enlargement were diagnosed, which conferred no additional anaesthetic risk. Hyperthyroidism was diagnosed and treated with carbimazole (15 mg PO q24h [Vidalta; MSD Animal Health]).

Under general anaesthetic, gross examination, oral examination, CT scan, cytology and culture of the swelling contents were performed. After contrast injection, a well-delineated, hypoattenuating, cavitary, thin-walled, fluid-filled mass measuring $14 \times 18 \times 35$ mm extending roughly from the level of the first premolar tooth to the level of the left temporomandibular joint, lateral (and slightly ventral) to the left mandible was evident on the CT scan (Figure 1). No periosteal reaction, periapical lysis, foreign body or sialolith were observed. The mandibular,

zygomatic and parotid salivary glands were within normal limits of size, shape and attenuation. The CT scan of the thorax was unremarkable.

A viscous, clear, fluid compatible with saliva was aspirated from the fluid-filled mass. Cytology of the fluid revealed a basophilic background with gel-like material. A number of small, round cells with a high nuclear-to-cytoplasm ratio were arranged in tightly cohesive clusters (possible ductal cells). There was no evidence of salivary glandular epithelium, macrophage inflammation or haematoidin crystals, which are normally associated with a sialocoele.

Together, these findings suggested a diagnosis of left cervical sialocoele or salivary mucocoele without any evident cause. No ranula was observed intraorally. Bacterial and fungal culture of the fluid was negative.

Once the hyperthyroidism had stabilised, the cat was admitted for surgery. The patient was premedicated with methadone (0.3 mg/kg IM [Comfortan; Dechra]) midazolam hydrochloride (0.25 mg/kg IM [Hypnovel; Roche]), dexmedetomidine (0.001 mg/kg IM [Dexdomitor; Vetoquinol]) and alfaxalone (1 mg/kg IM [Alfaxan Multidose; Jurox]) followed by induction with alfaxalone (0.44 mg/kg IV) and ketamine (0.5 mg/kg IV [Anesketin; Dechra]). The cat was intubated, and anaesthesia was maintained with isoflurane (Isoflo; Zoetis) in oxygen. The patient received cefuroxime (20 mg/kg IV [Zinacef; GlaxoSmithKline]) and meloxicam (0.05 mg/kg SC [Metacam; Boehringer Ingelheim]). Lactated Ringer's solution (Hartmann Lactated Ringers; B Braun) was administered intravenously at a rate of 4.0 ml/kg/h for the duration of anaesthesia. During the anaesthetic two doses of fentanyl (0.002 mg/kg IV [Fentadol; Dechra]) were given and a fentanyl constant rate infusion (5 µg/kg/h IV) was started. This was stopped at the end of anaesthesia.

Ultrasonography of the swelling prior to surgery revealed a large, multilobulated, anechoic structure bordered by a thin, smooth, hyperechoic wall and clear posterior enhancement. It measured approximately up to 5 cm in length, up to 2.5 cm in width and 1.8 cm in height. This enlargement, compared with the previous CT scan, reflected accumulation of fluid within the structure. In continuity with one caudal lobation, a tubular structure was noted with similar wall characteristics, measuring approximately 0.17 cm in diameter and directed dorsally and medially towards the left lip commissure. The tubular structure was consistent with a molar salivary gland duct (Figure 2).

The entire ventral aspect of both mandibles and cranial aspect of the neck were clipped and aseptically prepared (Figure 3a). Using a number 15 scalpel blade, an incision was made in the ventral cervical and sub-mandibular skin parallel to the left mandibular body, extending from caudal to the mandibular ramus to the

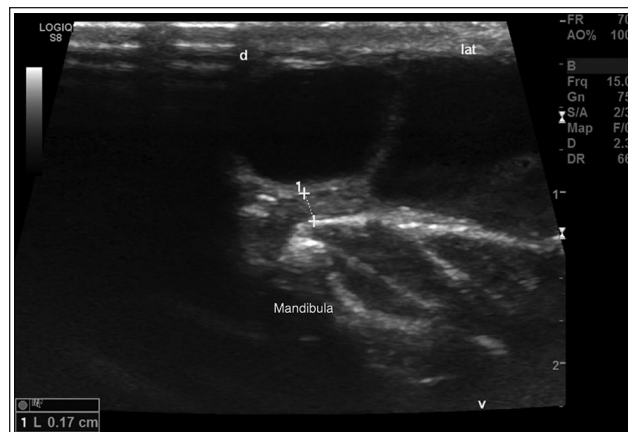


Figure 2 Ultrasound image of a 16-year-old British Shorthair cat's left lateral mandible depicting a sialocoele relative to the mandible, showing a clearly delineated, tubular, 0.17 cm diameter structure with hyperechoic walls, which appears to communicate with the sialocoele. Owing to the location of this structure, it is thought that it may represent a molar salivary gland duct. d = dorsal, v = ventral, lat = lateral

level of the mandibular symphysis. The mandibular salivary gland capsule was opened using Metzenbaum scissors and dissection of the mandibular and sublingual salivary glands and ducts was continued rostrally (Figure 3b). The duct was ligated at the level of the lingual nerve as no ranula was located. The cystic structure was not close to this gland complex.

The dissection was continued around the cyst-like structure, which was lateral to the left mandibular body. During dissection, the cyst-like structure was punctured, which released saliva. The remaining lining was dissected and removed, and was found to be in direct proximity to the molar salivary gland (Figure 3c). The molar salivary gland was identified at the oral commissure, ventral to the facial vein (Figure 3d). This was carefully dissected and excised (Figure 3e). A small incision into the oral mucosa was repaired using simple interrupted 4-0 poliglecaprone (Monocryl; Ethicon) sutures. The surgical site was lavaged. Subcutaneous and skin closure was performed in a routine manner with 4-0 poliglecaprone and 3-0 nylon (Ethilon; Ethicon). The cat recovered uneventfully from anaesthesia and was discharged from the hospital the following day. Oral liquid meloxicam (0.05 mg/kg PO q24h [Meloxidyl; Ceva]) was prescribed and a soft Elizabethan collar was placed to prevent self-traumatisation of the incision site. Soft food and house rest were recommended. About 1 week postoperatively, oral ulceration and reduced appetite developed, but this responded to an extended course of analgesia, including meloxicam and buprenorphine (Buprecare; Animalcare) administered orally. At telephone follow-up 12 months after surgery the owner reported no further problems or recurrence of the sialocoele.

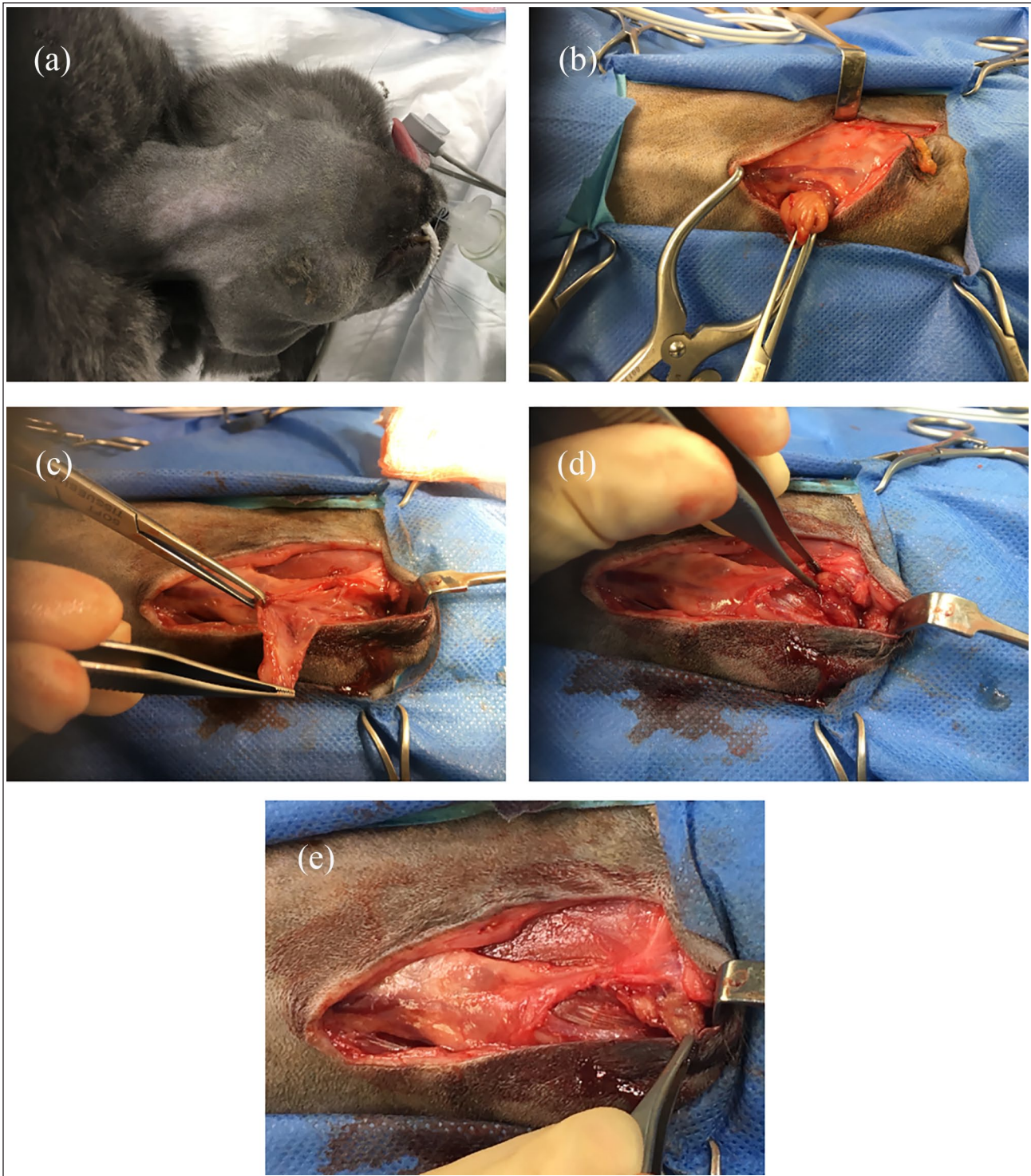


Figure 3 Intraoperative photographs depicting removal of the left sublingual and mandibular salivary gland complex, sialocele removal and molar gland sialadenectomy in a 16-year-old British Shorthair cat using a ventral approach. (a) Position of the swelling lateral to the left mandible (rostral is to the right of the picture in all images). (b) The mandibular salivary gland is grasped with Allis tissue forceps and the mandibular and sublingual gland and duct complex is dissected and removed. (c) The sialocele lining is dissected and resected. The Allis tissue and Adson–Brown forceps show the limits of the sialocele lining. (d) Using an extraoral approach the left molar salivary gland is identified caudal to the lateral commissure of the lips and ventral to the facial vein (seen here between the tips of the Adson–Brown forceps). (e) The molar salivary gland is dissected and extirpated

Histopathology of the excised mandibular, sublingual and molar salivary glands was performed along with examination of the fluid-filled swelling. The molar salivary gland had accumulation of mucinous material along with haemorrhage and degenerative changes to the tissues. Associated ducts were distended, with a low number of inflammatory cells, including lymphocytes, neutrophils, plasma cells and macrophages. The mandibular and sublingual salivary glands had similar but less severe changes. The cyst-like structure was classified as a sialocoele and comprised fibrous connective tissue, glandular tissue, inflammatory cells and distended ducts. A histological diagnosis of chronic active, moderate, multifocal-to-diffuse sialoadenitis and sialocoele associated with ruptured ducts was made.

Discussion

This report describes a sialocoele uniquely located lateral to the mandible in a British Shorthair cat. Owing to the atypical location and proximity of the molar salivary gland to the sialocoele, the origin of the sialocoele was suspected to be the molar salivary gland. A CT scan was selected as the optimal imaging modality in this case as the salivary glands can be identified and sometimes the cause of the sialocoele can be found. For example, sialoliths can be easily identified on CT due to their hyperattenuating nature.^{1,12,13} CT suggested the molar gland as a possible cause of the sialocoele but was not definitive and involvement of the mandibular duct could not be excluded. Ultrasonography was also supportive of the molar gland being highly likely to be the cause or contributory to formation of the sialocoele owing to the immediate proximity of the molar gland to the sialocoele. Sialography can be used to identify the salivary gland duct or gland defect but is technically challenging, especially in cats.^{6,8,11}

In this case, owing to the origin of the sialocoele being unconfirmed, surgical removal of the sublingual and mandibular gland complex was elected in addition to molar sialadenectomy. The anatomical location of the sublingual and mandibular gland complex was remote from the sialocoele. The sialocoele was immediately adjacent to the molar salivary gland, suggesting that the origin of the sialocoele was this gland. In addition, histopathology of the molar salivary gland revealed more severe sialoadenitis than the mandibular gland, as well as the presence of distended salivary ducts. Distended ducts were also observed in the sialocoele.

A lateral or ventral approach can be used to remove the mandibular and sublingual gland complex.^{1,2,10,11,14,15} In this case, a ventral approach was used because it permits removal of the entire mandibular and sublingual gland-duct complex and reduces the risk of recurrence.^{1,14,15} The molar gland can be removed intra- or

extraorally.¹⁴ An extraoral (subcutaneous) approach was used in this case as access to the molar gland was more easily achieved through extension of the original incision.

Reported causes of sialocoeles include trauma to salivary ducts or glands (surgical and non-surgical), foreign bodies, sialoliths and neoplasia, although the majority have an unknown cause.^{1,2,4,7,8,11} Trauma could not be ruled out in this case because the cat had outdoor access. However, the owner was not aware of any trauma prior to the appearance of the sialocoele. No foreign body or sialoliths were identified on the CT scan and neoplasia was not identified on histopathology of the excised glands and sialocoele.

The chronic active sialoadenitis of the molar and mandibular glands identified on histopathology could be the cause of the sialocoele. It is possible that the inflammation made ductal rupture more likely. Alternatively, the sialoadenitis could be secondary to the presence of the sialocoele as these resultant saliva-filled cavities are lined by inflammatory connective tissue.

Conclusions

Sialocoele should be considered in the differential diagnosis of swellings lateral to the mandible in cats. If sialocoele is confirmed, then successful surgical management necessitates removal of all suspected salivary glands, including the molar salivary gland and sialocoele in this atypical location. This case report raises the possibility that the molar salivary gland can be involved in cases of sialocoele in cats although it was not possible to determine the origin of the disease in this case.

Conflict of interest The authors declared no potential conflicts of interest with respect to the research, authorship, and/or publication of this article.

Funding The authors received no financial support for the research, authorship, and/or publication of this article.

Ethical approval This work involved the use of non-experimental animals only (including owned or unowned animals and data from prospective or retrospective studies). Established internationally recognised high standards ('best practice') of individual veterinary clinical patient care were followed. Ethical approval from a committee was therefore not necessarily required.

Informed consent Informed consent (either verbal or written) was obtained from the owner or legal custodian of all animal(s) described in this work (either experimental or non-experimental animals) for the procedure(s) undertaken (either prospective or retrospective studies). No animals or humans are identifiable within this publication, and therefore additional informed consent for publication was not required.

ORCID ID Andrea Kilduff-Taylor  <https://orcid.org/0000-0002-2503-1896>

Alexis Gombert  <https://orcid.org/0000-0001-9387-6906>

References

- 1 Ritter MJ and Stanley BJ. **Salivary glands**. In: Johnston SA and Tobias KM (eds). *Veterinary surgery small animal*. 2nd ed. St Louis, MO: Elsevier, 2018, pp 1653–1663.
- 2 MacPhail CM. **Disorders of the salivary gland**. In: Monnet E (ed). *Small animal soft tissue surgery*. Oxford: Wiley-Blackwell, 2013, pp 299–303.
- 3 Spangler WL and Culbertson MR. **Salivary gland disease in dogs and cats: 245 cases (1985–1988)**. *J Am Vet Med Assoc* 1991; 198: 465–469.
- 4 Tsioli V, Brellou G, Siziopkou C, et al. **Sialocele in the cat. A report of 2 cases**. *J Hellenic Vet Med Soc* 2015; 66: 141–146.
- 5 Bassanino J, Palierne S, Blondel M, et al. **Sublingual sialocele in a cat**. *JFMS Open Rep* 2019; 5. DOI: 10.1177/2055116919833249.
- 6 Speakman AJ, Baines S J, Williams JM, et al. **Zygomatic salivary cyst with mucocele formation in a cat**. *J Small Anim Pract* 1997; 38: 468–470.
- 7 Feinman JM. **Pharyngeal mucocele and respiratory distress in a cat**. *J Am Vet Med Assoc* 1990; 197: 1179–1180.
- 8 Vallefucio R, Jardel N, El Mrini M, et al. **Parotid salivary duct sialocele associated with glandular duct stenosis in a cat**. *J Feline Med Surg* 2011; 13: 781–783.
- 9 Kiefer KM and Davis GJ. **Salivary mucoceles in cats: a retrospective study of seven cases**. *Vet Med* 2007; 102: 582–585.
- 10 Papazoglou LG, Tzimtzimis E, Rampidi S, et al. **Ventral approach for surgical management of feline sublingual sialocele**. *J Vet Dent* 2015; 32: 201–203.
- 11 Smith MM. **Lateral approach for surgical management of feline sublingual sialocele**. *J Vet Dent* 2015; 32: 198–200.
- 12 Durand A, Finck L, Sullivan M, et al. **Computed tomography and magnetic resonance diagnosis of variations in the anatomical location of the major salivary glands in 1680 dogs and 187 cats**. *Vet J* 2016; 209: 156–162.
- 13 Lee N, Choi M, Keh S, et al. **Zygomatic sialolithiasis diagnosed with computed tomography in a dog**. *J Vet Med Sci* 2014; 76: 1389–1391.
- 14 Langley-Hobbs SJ. **Head**. In: Langley-Hobbs SJ, Demetriou JL and Ladlow JF (eds). *Feline soft tissue and general surgery*. Edinburgh: Saunders Elsevier, 2014, pp 571–586.
- 15 Ritter M, von Pfeil DJF, Stanley BJ, et al. **Mandibular and sublingual sialoceleles in the dog: a retrospective evaluation of 41 cases, using the ventral approach for treatment**. *N Z Vet J* 2006; 54: 333–337.