



Surgical treatment of a circumferential oesophagogastric mass associated with a peritoneopericardial diaphragmatic hernia in a Maine Coon cat

Authors: Derré, Maxime G, Findji, Laurent, McLauchlan, Gerard, and Guilherme, Sérgio

Source: Journal of Feline Medicine and Surgery Open Reports, 8(1)

Published By: SAGE Publishing


URL: <https://doi.org/10.1177/20551169221090449>

BioOne Complete (complete.BioOne.org) is a full-text database of 200 subscribed and open-access titles in the biological, ecological, and environmental sciences published by nonprofit societies, associations, museums, institutions, and presses.

Your use of this PDF, the BioOne Complete website, and all posted and associated content indicates your acceptance of BioOne's Terms of Use, available at www.bioone.org/terms-of-use.

Usage of BioOne Complete content is strictly limited to personal, educational, and non - commercial use. Commercial inquiries or rights and permissions requests should be directed to the individual publisher as copyright holder.

BioOne sees sustainable scholarly publishing as an inherently collaborative enterprise connecting authors, nonprofit publishers, academic institutions, research libraries, and research funders in the common goal of maximizing access to critical research.



Surgical treatment of a circumferential oesophagogastric mass associated with a peritoneopericardial diaphragmatic hernia in a Maine Coon cat

Journal of Feline Medicine and Surgery Open Reports
1–8

© The Author(s) 2022

Article reuse guidelines:

sagepub.com/journals-permissions

DOI: 10.1177/20551169221090449

journals.sagepub.com/home/jfmsopenreports

This paper was handled and processed by the European Editorial Office (ISFM) for publication in *JFMS Open Reports*



Maxime G Derré^{1,2} , Laurent Findji¹,
Gerard McLauchlan¹ and Sérgio Guilherme¹

Abstract

Case summary A 7-month-old intact female Maine Coon presented with a 2-week history of vomiting. A peritoneopericardial diaphragmatic hernia (PPDH) and a mass arising from the cardia, protruding into the gastric lumen, were diagnosed using a combination of ultrasound and CT. An exploratory gastrotomy revealed a circumferential, irregular, ulcerated mass involving the submucosal layer of the cardia. This mass was excised by partial-thickness resection of the gastro-oesophageal wall. The PPDH was corrected and a gastrostomy feeding tube was placed under the same anaesthetic. Histopathologically, the most characteristic feature of this mass was a submucosal fibroplasia associated with marked ulceration and granulation tissue. No infectious or neoplastic cells were identified. The affected region of the gastric wall appeared narrowly excised. Resolution of clinical signs was achieved until the cat was lost to follow-up 12 months postoperatively.

Relevance and novel information This is the first report of the surgical management of an oesophagogastric mass in a cat with a concurrent PPDH and no other underlying disease. A benign fibrous mass should be considered as a differential diagnosis of an oesophagogastric mass in feline patients with PPDH. While medical and surgical options are debated for the management of PPDH, symptomatic patients with a concurrent oesophagogastric mass are legitimate candidates for surgical herniorrhaphy to prevent further complications. Based on this case, prognosis can be considered good if surgical resection is complete.

Keywords: Submucosal fibroplasia; lower oesophageal sphincter; cardia; gastro-oesophageal mass; PPDH

Accepted: 10 March 2022

Introduction

Peritoneopericardial diaphragmatic hernia (PPDH) is an anomaly resulting in communication between the pericardium and pleuroperitoneal cavity.¹ The prevalence of PPDH has been reported to be 0.06–0.6% in cats.^{1–4} It is one of the most common congenital cardiac defects diagnosed in cats over 1 year of age;^{1–3,5–7} however, its aetiology is still not fully understood. In humans, PPDH may occur as a result of trauma or be a congenital anomaly, whereas, in cats, traumatic PPDH does not occur as the pericardium and diaphragm are not connected.^{1,5,8} Various proposed mechanisms underlying the pathogenesis of PPDH have been suggested over the past

50 years. Most of these mechanisms allude to altered embryological development of the septum transversum, which is the structure that will form the ventral portion of the diaphragm. This malformation allows the passage

¹Fitzpatrick Referrals Oncology and Soft Tissue Hospital, Guildford, UK

²Department of Veterinary Clinical Sciences, College of Veterinary Medicine, Purdue University, West Lafayette, IN, USA

Corresponding author:

Maxime G Derré DVM, Fitzpatrick Referrals Oncology and Soft Tissue Hospital, 70 Priestley Road, Guildford GU2 7AJ, UK
Email: maximederredvm@gmail.com



Creative Commons Non Commercial CC BY-NC: This article is distributed under the terms of the Creative Commons

Attribution-NonCommercial 4.0 License (<https://creativecommons.org/licenses/by-nc/4.0/>) which permits non-commercial use, reproduction and distribution of the work without further permission provided the original work is attributed as specified on the SAGE and Open Access pages (<https://us.sagepub.com/en-us/nam/open-access-at-sage>).

of abdominal contents through the diaphragmatic hernia into the pericardial sac.^{1,3,5,6,9–13} The most common herniated organs in cats with PPDH are the liver, gallbladder and small intestine.⁵

Breeds reported to have a higher incidence of PPDH include Maine Coons, Himalayans and Persians.^{1,5,7,14,15} In two studies, between 50% and 60% of cats with PPDH presented with associated clinical signs, whereas a hernia was an incidental finding in the other cats.^{1,3} Clinical signs include respiratory signs such as tachypnoea and dyspnoea, or gastrointestinal signs such as intermittent regurgitation, vomiting, dysphagia, anorexia and weight loss.^{1,7,10,11,14,16,17} The prolonged exposure of the oesophageal mucosa to acid is an important cause of oesophagitis and potential stricture formation. In addition, oesophagitis decreases lower oesophageal sphincter (LES) tone, which leads to more reflux and mucosal inflammation. Damage to the muscularis layer of the oesophagus is associated with fibroblastic proliferation and contraction, leading to stricture formation. Herein we describe the first report of a circumferential oesophagogastric mass associated with a PPDH in a young cat, which was managed successfully through surgery.

Case description

A 7-month-old indoor, vaccinated, intact female Maine Coon was initially presented to its primary care

veterinarian with a history of acute vomiting after a recent transition to a commercially available diet. The patient was given a 2-week course of a proton pump inhibitor (omeprazole 5mg PO q12h) and its appetite improved initially. The vomiting episodes reoccurred, however, after the treatment was discontinued. The patient also developed intermittent hiccups. The patient was reassessed and comprehensive blood work performed. Complete blood cell count and serum chemistry results showed no significant abnormalities. A mild non-regenerative, normocytic, normochromic anaemia (haemoglobin 84 g/l; reference interval [RI] 98–162) was the only notable finding. Serum Spec feline pancreatic lipase concentration was within normal limits, and serum folate and cobalamin results were above the respective RIs (cobalamin >1000 ng/l [RI 270–1000]; folate >24.0 µg/l [RI 9.5–20.2]). Thoracic and abdominal radiography revealed marked enlargement of the cardiac silhouette and a confluent silhouette between the diaphragm and the heart (Figure 1). An abdominal ultrasound revealed a soft tissue structure within the stomach. The cat was referred to a referral centre for further evaluation. Over the week preceding presentation to the referral hospital, the patient had lost about 10% of its body weight and became anorexic and lethargic. Large intestinal diarrhoea (tenesmus, small volume stools, presence of mucus) was also reported for a couple of

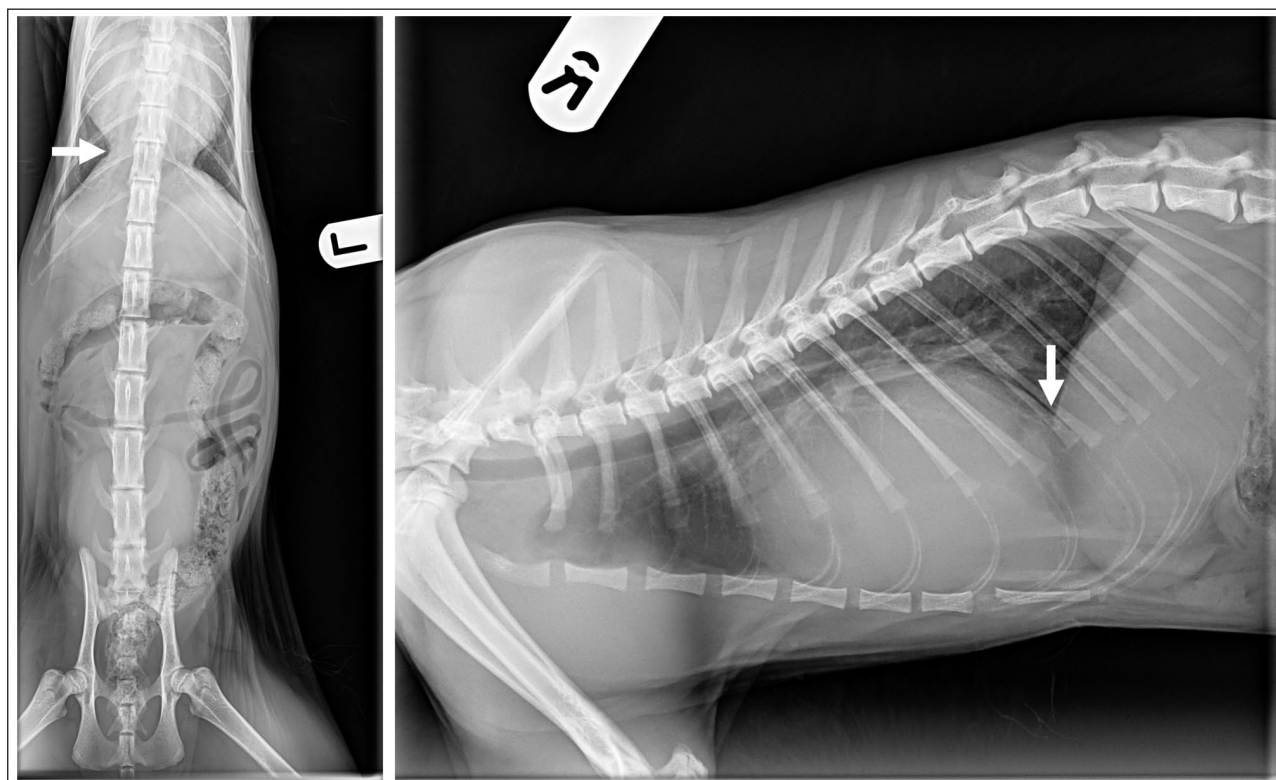


Figure 1 Orthogonal radiographs of a 7-month-old intact female Maine Coon showing severe enlargement of the cardiac silhouette and partial summation of its caudal border with the ventral margins of the diaphragm (white arrows)

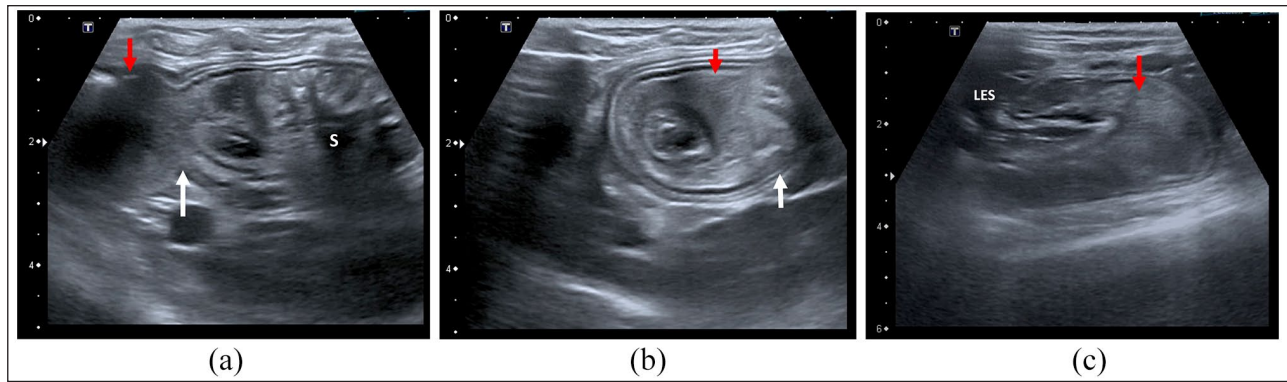


Figure 2 (a) Ultrasonographic image of the stomach showing the presence of a parenchymal structure on the left side of the screen compatible with a mass within the stomach. Visualisation of the transition (white arrow) between the gastric mass (red arrow) and the normal gastric wall (S). (b) Ultrasonographic image of the stomach showing the circumferential mass at the level of the cardia and surrounding the lower oesophageal sphincter (LES). Visualisation of the transition (white arrow) between the gastric mass (red arrow) and the rest of the stomach on the right side of the screen. (c) Ultrasonographic image of the stomach showing the circumferential mass (red arrow) affecting the cardia and surrounding the LES

days prior to presentation. No haematemesis, melaena or haematochezia were noted. No coughing, sneezing, nasal discharge or dyspnoeic episodes were reported.

On physical examination, the patient was bright, alert and responsive, with a body weight of 3.7 kg, a body condition score of 3/9 and a mild-to-moderate loss of lean muscle mass. The patient was tachycardic (220 beats/min), but no murmur, arrhythmias or gallop sounds were auscultated. Femoral pulses were strong and synchronous. The patient was eupnoeic, and no stertor, stridor, wheezes or crackles were noted on auscultation of the respiratory tree. Abdominal palpation was unremarkable.

Comprehensive blood work confirmed a mild non-regenerative, normocytic, normochromic anaemia (haemoglobin 8.8 g/dl [RI 9.8–16.2]) and revealed an inflammatory leukogram characterised by a mature neutrophilia ($17.9 \times 10^9/l$; RI 2.3–10.3) and monocytosis ($1.3 \times 10^9/l$; RI 0.1–0.7). Serum biochemistry was unremarkable. Abdominal ultrasound showed that the right medial lobe, papillary process, left lateral lobe, left medial lobe, quadrate lobe and gallbladder were displaced through the diaphragm, into the thoracic cavity, caudal to the heart. A small volume of pericardial effusion was present. These findings were compatible with a PPDH. A segment of gastric wall adjacent to and surrounding the lower oesophageal sphincter showed marked thickening and loss of layering with a hypoechoic appearance (Figure 2). CT was used to further characterise the gastric wall changes and enable assessment of the vasculature and herniated structures involved in the PPDH for anaesthetic and surgical planning. CT confirmed that the left lateral and left medial liver lobes were herniated into the caudal thoracic cavity. This herniation had occurred via a large midline defect

of the ventral diaphragm, with continuity between the diaphragm and the caudal aspect of the pericardial sac. The stomach was displaced to the left side of the most cranial aspect of the abdominal cavity. A 3 cm diameter broad-based mass was arising from the wall of the cardia and protruding into the gastric lumen. The mass was circumferential and showed heterogeneous contrast enhancement (Figure 3).

The patient was classified as American Society of Anesthesiologists grade III and premedicated with methadone (0.2 mg/kg [10 mg/ml] IV) and medetomidine (3 µg/kg [1 mg/ml] IV). Anaesthesia was induced with alfaxalone (2 mg/kg [10 mg/ml] IV) and maintained with isoflurane in oxygen. The patient was mechanically ventilated and maintained on intravenous fluids during the surgical procedure. Fentanyl (1–2 µg/kg/min [50 µg/ml] continuous rate infusion) and cefuroxime (22 mg/kg [100 mg/ml] IV) were also given perioperatively.

Surgical exploration of the abdomen was performed via a median xipho-umbilical coeliotomy approach. An intraluminal mass was palpated within the stomach, at the oesophagogastric junction (Figure 4a). A gastrotomy was performed and a circumferential, ulcerated, submucosal mass was observed at the level of the LES (Figure 4b). The mucosal and submucosal layers surrounding the mass were incised and the mass was elevated (Figures 4c–e). The muscularis and serosa layers were preserved. The mass was resected and submitted for histopathology (Figure 4f). The mucosal and submucosal layers of the oesophageal and gastric walls were sutured from inside the lumen using absorbable suture material (3-0 PDS). The gastrotomy was closed in a two-layer appositional pattern. The PPDH was inspected. The liver was extracted from the pericardial cavity. No

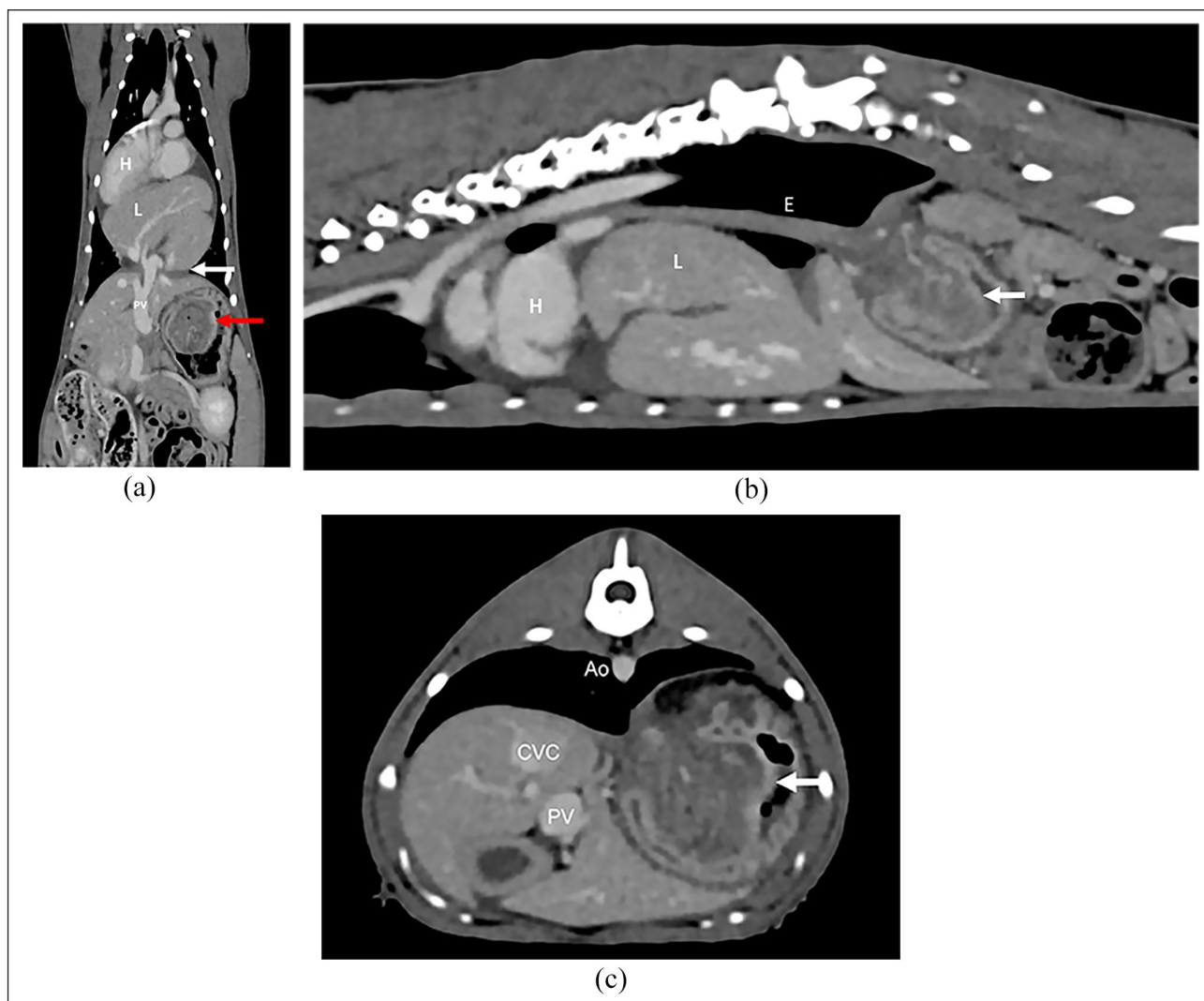


Figure 3 (a) Post-contrast dorsal multiplanar reformatted CT image in a soft tissue window. Visualisation of the peritoneopericardial diaphragmatic hernia (PPDH; white arrow) with liver (L) and portal venous system involvement caudal to the heart (H). A large mass is seen arising from the cardia and protruding into the lumen of the stomach (red arrow). PV = portal vein. (b) Post-contrast sagittal multiplanar reformatted CT image in a soft tissue window. Visualisation of the PPDH with liver (L) and portal venous system involvement caudal to the heart (H). A large mass is seen within the stomach (white arrow). E = oesophagus. (c) Post-contrast transverse CT image in a soft tissue window. Visualisation of the large mass arising from the cardia and protruding into the lumen of the stomach (white arrow). Ao = aorta; CVC = caudal vena cava; PV = portal vein

adhesions were found between the herniated structures and the pericardium or myocardium. The edges of the hernial ring were debrided and closed using a simple continuous suture pattern. A pneumothorax occurred during reconstruction of the diaphragm and was drained via thoracocentesis. A temporary gastrostomy feeding tube (MILA Foley Catheter, 18 F × 55 cm [21 in] with a 10 cc balloon) was placed at the level of the fundus. An ovariohysterectomy was performed at the request of the owner. The abdomen was closed routinely.

The patient recovered well from anaesthesia and remained in hospital for continued fluid therapy, pain relief and supportive care, including tube feeding. No

vomiting or diarrhoea were reported, and the resting respiratory rate remained within normal limits. The patient was discharged after 5 days on an antiemetic (maropitant 8 mg q24h via the tube for 5 days), proton pump inhibitor (omeprazole 5 mg q12h via the tube for 2 weeks) and an adherent acid-buffering agent (sucralfate 500 mg q8h via the tube for 5 days). The patient's activity was restricted for 2 weeks. Only water was allowed by mouth for the first week, then soft food was gradually introduced over 2 weeks, and firmer food was eventually added.

Pathology was performed by a board-certified pathologist and was consistent with a gastric mass with submucosal fibroplasia associated with marked ulceration,

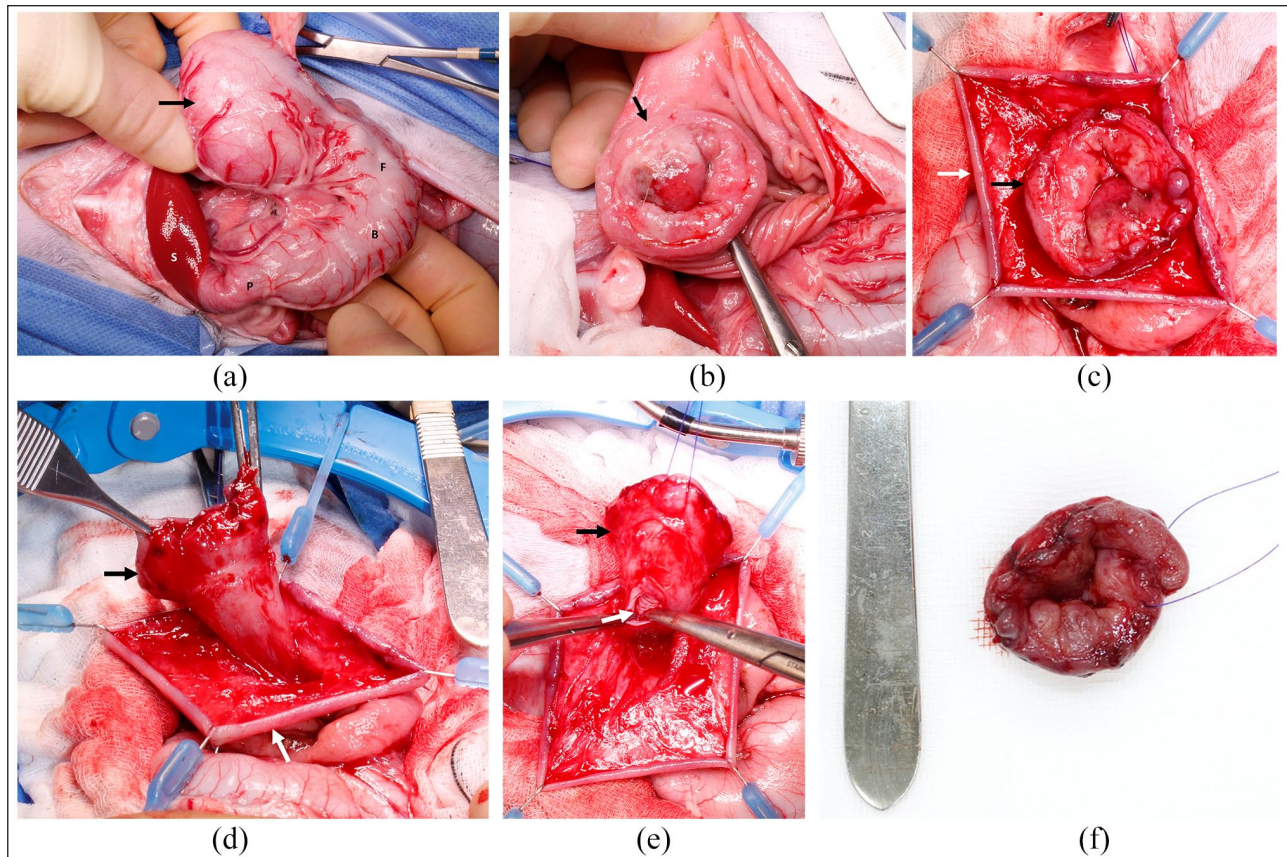


Figure 4 (a) Intraoperative photograph of the patient in dorsal decubitus showing pre-umbilical coeliotomy to correct peritoneopericardial diaphragmatic hernia (PPDH). The black arrow shows the intraluminal gastric mass. The fundus (F), body (B) and pylorus (P), and part of the spleen (S), are also shown. (b) Intraoperative photograph showing the intraluminal circumferential mass after gastrotomy. The black arrow shows the intraluminal gastric mass. Note the lumen of the lower oesophageal sphincter in the centre of the mass. (c) Intraoperative photograph showing the intraluminal circumferential mass after gastrotomy. The black arrow shows the intraluminal gastric mass after dissection of its superficial layer (white arrow). Note the lumen of the lower oesophageal sphincter in the centre of the mass. (d) Intraoperative photograph showing the dissection of intraluminal circumferential mass (black arrow). The white arrow shows the superficial layer of the mass after dissection. (e) Intraoperative photograph showing the dissection of intraluminal circumferential mass (black arrow). The white arrow shows the lumen of the lower oesophageal sphincter. (f) Postoperative photograph showing the circumferential mass. The scalpel was used as a scale

granulation tissue and mineralisation. The submitted tissue contained a well-demarcated region of ulceration, with associated inflammation and extensive stromal proliferation. The stroma consisted of a mix of granulation tissue and fibrovascular tissue. There was no evidence of a neoplastic population, infectious agents or foreign material. A specific cause for the extensive alteration was not identified within the sections. There was extensive stromal proliferation that appeared relatively well demarcated, and the affected region of the gastric wall appeared narrowly excised.

The patient was presented a week later for a recheck examination. The cat's activity level and appetite had reportedly improved. No vomiting or regurgitation episodes were reported. No coughing, sneezing, nasal discharge or dyspnoeic episodes were reported. The

coeliotomy incision and the feeding tube site were healing well. No redness, swelling, pain or purulent discharge were reported. A telephone recheck was performed 2 weeks later. The patient had gained weight and its activity level and appetite continued to improve. One vomiting episode was reported after a meal, but no regurgitation, diarrhoea, coughing, sneezing, nasal discharge or dyspnoeic episodes were observed. Omeprazole was discontinued and the patient was gradually transitioned to a dry diet. A recheck appointment was scheduled 3 weeks later, when the owner had finished transitioning the patient from soft food to dry food. The patient had gained weight and was bright, alert and responsive. Vital parameters were within normal limits, and the coeliotomy incision site was completely healed. The gastrostomy feeding tube was removed. Thereafter,

telephone rechecks were performed 3 months, 6 months and 1 year after discharge. The patient had thrived, and the owners reported no clinical signs.

Discussion

This case report documents an intact female Maine Coon that was diagnosed with a PPDH and a concurrent, believed to be secondary, benign oesophagogastric mass. Diagnostic investigation revealed no other comorbidities, and histopathology reported that the mass was consistent with submucosal fibroplasia associated with granulation tissue, ulceration and extensive stromal proliferation. Grossly, this lesion could be confused with lymphoma, adenocarcinoma, eosinophilic sclerosing fibroplasia or other pyogranulomatous lesions (eg, foreign body, mycobacteriosis and pythiosis).^{18–20} We hypothesised that the PPDH caused chronic, occult, gastro-oesophageal reflux episodes leading to erosion/irritation of the LES and resulting in the development of a benign fibrous mass. Indeed, prolonged exposure of the oesophageal layers to acid represents a common cause of oesophagitis and stricture formation in dogs and cats, and gastroesophageal reflux precedes development of benign oesophageal stricture in 46–65% of cases.^{21,22} Damage to the oesophageal layer is associated with fibroblastic proliferation and contraction, leading to stricture formation. In addition, oesophagitis decreases LES tone, which leads to further reflux and mucosal inflammation. Clinical signs associated with oesophagitis are dependent on the severity of inflammation, extent of oesophageal involvement and type of injury. Early clinical signs can be easily missed by owners, but progressive clinical signs include dysphagia, odynophagia, regurgitation, salivation, anorexia, coughing and weight loss.

In the course of inflammatory diseases, ultrasound findings of the gastrointestinal tract, such as wall thickening, loss of definition among wall layers and mesenteric lymphadenopathy, can be similar to neoplastic lesions.²³ Several studies suggest that the oesophagus and the stomach are the least common gastrointestinal sites to be affected by a neoplastic process in cats, with gastric tumours representing only 0.4–0.7% of all feline neoplasias.^{24–26} Therefore, the presence of an oesophagogastric mass on abdominal ultrasound should prompt the operator to consider non-neoplastic processes more likely (polyps, granuloma, abscess, foreign body).^{23,27,28} In this case, thoracic radiographs and abdominal ultrasound were indicative of a concurrent PPDH, and CT allowed assessment of the anatomy and characteristics of the oesophagogastric mass for surgical planning.

Evidence-based medicine for feline PPDH is limited to case reports or small sample size retrospective studies; therefore, the sensitivity and specificity of diagnostic techniques is scarce and the superiority of medical vs surgical management of cats with PPDH is controversial.^{1–3,5–7,13,14,29,30} In the case reported herein, the

associated oesophagogastric mass was presumed to be the underlying cause for the clinical signs noted. Therefore, the authors considered this patient a legitimate candidate for surgical herniorrhaphy to prevent further complications. Surgery revealed that the mass was ulcerated. Oesophageal and gastric ulcers are considered life-threatening when left untreated as they can extend through the muscularis and be associated with haemorrhage and septic peritonitis.³¹ Oesophageal surgery is associated with potentially serious complications, including stricture, dehiscence, oesophagitis, fistula formation, infection, pyothorax and pleuritis. This is presumably owing to several factors such as oesophageal movement during swallowing, significant wound tension and the presence of a segmental blood supply to the oesophagus. Following oesophageal surgery, the use of a gastrostomy tube is recommended to decrease motion occurring at the surgical site and therefore facilitate mucosal healing. En-bloc resection is associated with a good prognosis, but submucosal resection to debulk the mass without a full resection and anastomosis is considered an acceptable treatment with successful outcomes reported with benign masses and low-grade malignant tumours, such as leiomyomas/low-grade leiomyosarcomas.³² In a study evaluating perioperative morbidity and outcome in dogs and cats undergoing oesophageal surgery, the most common lesion in cats was an oesophageal stricture, which occurred in 3/9 patients.²⁸

In cats with PPDH, assessment of treatment superiority and outcomes is limited to case reports or retrospective studies with small numbers of cases. Cats may present with clinical signs related to the gastrointestinal and respiratory tracts, including regurgitation, vomiting, dysphagia, anorexia, weight loss or respiratory distress.^{1,7,10,11,14,16} Medical and surgical recommendations are dictated by the severity of the patient's clinical signs, diagnostic findings and the clinician's preference. While a retrospective study in cats with hiatal hernias reported a longer survival time for those treated medically,³³ another report revealed no significant differences in long-term survival rate between dogs and cats with PPDH that were managed either medically or surgically.³ Several studies suggest that cats with clinical signs attributable to PPDH are candidates for surgical herniorrhaphy, with one study reporting resolved clinical signs in 29/34 (85.3%) animals.^{1,3} Previous studies in animals with PPDH undergoing herniorrhaphy reported a mortality rate of 5–14% in the first couple of weeks after surgery, and an overall good prognosis for return to normal function.^{1,3,5} Perioperative complications are thought to be associated with reduction of the herniated viscera resulting in re-expansion pulmonary oedema, or the liberation of endotoxin or free radicals following reperfusion of hepatic parenchyma that had undergone long-standing compromised

haemoperfusion.^{1,3} However, none of the patients in those studies underwent the combination of a herniorrhaphy with concurrent resection of an oesophagogastric mass.^{1,3,5,11}

This case report has several limitations. Although combined clinical signs and imaging findings provided sufficient indication for surgical intervention, an oesophagogastric mass could have been performed beforehand to visualise the luminal surfaces of the upper digestive tract and collect superficial biopsies of the oesophagogastric mass. The authors believe that this potential limitation did not affect the overall outcome for the management of this case as it is unlikely that this lesion would have resolved with medical management alone. Moreover, superficial endoscopic biopsy results could have been inconclusive or would have provided comparable results and led to similar therapeutic recommendations. Special staining methods such as periodic acid–Schiff stain or Grocott’s methenamine silver stain could have been used to look for specific bacterial or fungal organisms that could be missed on routine haematoxylin and eosin stain. Similarly, additional diagnostic testing such as immunohistochemistry for detection of intracellular feline coronavirus antigen could have also been performed to look for evidence of feline infectious peritonitis.

Conclusions

This is the first report of the surgical management of an oesophagogastric mass in a cat with a concurrent PPDH. A benign fibrous lesion should be considered a differential diagnosis of an oesophagogastric mass in cats with PPDH. This mass was completely excised and the PPDH was reduced surgically. Resolution of clinical signs was achieved until the cat was lost to follow-up 12 months after surgery.

While medical and surgical options are debated for the management of PPDH, symptomatic patients with concurrent oesophagogastric mass are legitimate candidates for surgical herniorrhaphy to prevent further complications and sequelae. Based on this case, prognosis can be considered good if surgical resection is complete.

Conflict of interest The authors declared no potential conflicts of interest with respect to the research, authorship, and/or publication of this article.


Funding The authors received no financial support for the research, authorship, and/or publication of this article.

Ethical approval The work described in this manuscript involved the use of non-experimental (owned or unowned) animals. Established internationally recognised high standards (‘best practice’) of veterinary clinical care for the individual patient were always followed and/or this work involved

the use of cadavers. Ethical approval from a committee was therefore not specifically required for publication in *JFMS Open Reports*. Although not required, where ethical approval was still obtained it is stated in the manuscript.

Informed consent Informed consent (verbal or written) was obtained from the owner or legal custodian of all animal(s) described in this work (experimental or non-experimental animals, including cadavers) for all procedure(s) undertaken (prospective or retrospective studies). No animals or people are identifiable within this publication, and therefore additional informed consent for publication was not required.

ORCID iD Maxime G Derré  <https://orcid.org/0000-0003-0336-9500>

Sergio Guilherme  <https://orcid.org/0000-0003-3745-8069>

References

- 1 Reimer SB, Kyles AE, Filipowicz DE, et al. **Long-term outcome of cats treated conservatively or surgically for peritoneopericardial diaphragmatic hernia: 66 cases (1987–2002).** *J Am Vet Med Assoc* 2004; 224: 728–732.
- 2 Margolis C, Pipan MJ, Demchur J, et al. **Congenital peritoneopericardial diaphragmatic hernia in a family of Persian cats.** *JFMS Open Rep* 2018; 4. DOI: 10.1177/2055116918804305.
- 3 Burns CG, Bergh MS and McLoughlin MA. **Surgical and nonsurgical treatment of peritoneopericardial diaphragmatic hernia in dogs and cats: 58 cases (1999–2008).** *J Am Vet Med Assoc* 2013; 242: 643–650.
- 4 Murphy LA, Russell NJ, Dulake MI, et al. **Constrictive pericarditis following surgical repair of a peritoneopericardial diaphragmatic hernia in a cat.** *J Feline Med Surg* 2014; 16: 708–712.
- 5 Banz AC and Gottfried SD. **Peritoneopericardial diaphragmatic hernia: a retrospective study of 31 cats and eight dogs.** *J Am Anim Hosp Assoc* 2010; 46: 398–404.
- 6 Archanjo AB, Azevedo MAS, Souza DR, et al. **Congenital peritoneopericardial diaphragmatic hernia in an geriatric Persian cat.** *Medicina Veterinária (UFRPE)* 2020; 14: 117–122.
- 7 Holland M. **Peritoneal cavity.** In: *Feline diagnostic imaging*. John Wiley & Sons, 2020, pp 529–555.
- 8 Reed CA. **Pericardio-peritoneal hernia in mammals, with description of a case in the domestic cat.** *Anat Rec* 1951; 110: 113–119.
- 9 Less RD, Bright JM and Orton EC. **Intrapericardial cyst causing cardiac tamponade in a cat.** *J Am Anim Hosp Assoc* 2000; 36: 115–119.
- 10 Liptak JM, Bissett SA, Allan GS, et al. **Hepatic cysts incarcerated in a peritoneopericardial diaphragmatic hernia.** *J Feline Med Surg* 2002; 4: 123–125.
- 11 Evans SM and Biery DN. **Congenital peritoneopericardial diaphragmatic hernia in the dog and cat: a literature review and 17 additional case histories.** *Vet Radiol* 1980; 21: 108–116.
- 12 Frye FL and Taylor DO. **Pericardial and diaphragmatic defects in a cat.** *J Am Vet Med Assoc* 1968; 152: 1507–1510.
- 13 Nikiphorou X, Chiotti R, Patsikas MN, et al. **Peritoneopericardial diaphragmatic hernia in the dog and cat.** *J Hellenic Vet Med Soc* 2016; 67: 189–194.

- 14 Neiger R. **Peritoneopericardial diaphragmatic hernia in cats.** *Compend Contin Educ Pract Vet* 1996; 18: 461–468.
- 15 Lamb CR, Mason GD and Wallace MK. **Ultrasonographic diagnosis of peritoneopericardial diaphragmatic hernia in a Persian cat.** *Vet Rec* 1989; 125: 186.
- 16 Wilson GP, Newton CD and Burt JK. **A review of 116 diaphragmatic hernias in dogs and cats.** *J Am Vet Med Assoc* 1971; 159: 1142–1145.
- 17 Han E, Broussard J and Baer KE. **Feline esophagitis secondary to gastroesophageal reflux disease: clinical signs and radiographic, endoscopic, and histopathological findings.** *J Am Anim Hosp Assoc* 2003; 39: 161–167.
- 18 Linton M, Nimmo JS, Norris JM, et al. **Feline gastrointestinal eosinophilic sclerosing fibroplasia: 13 cases and review of an emerging clinical entity.** *J Feline Med Surg* 2015; 17: 392–404.
- 19 Craig LE, Hardam EE, Hertzke DM, et al. **Feline gastrointestinal eosinophilic sclerosing fibroplasia.** *Vet Pathol* 2009; 46: 63–70.
- 20 Suzuki M, Onchi M and Ozaki M. **A case of feline gastrointestinal eosinophilic sclerosing fibroplasia.** *J Toxicol Pathol* 2013; 26: 51–53.
- 21 Adamama-Moraitou KK, Rallis TS, Prassinos NN, et al. **Benign esophageal stricture in the dog and cat: a retrospective study of 20 cases.** *Can J Vet Res* 2002; 66: 55–59.
- 22 Sellon RK and Willard MD. **Esophagitis and esophageal strictures.** *Vet Clin North Am Small Anim Pract* 2003; 33: 945–967.
- 23 Simeoni F, Terragni R, Rubini G, et al. **B-mode and contrast enhanced ultrasonography features of gastric inflammatory and neoplastic diseases in cats.** *Animals* 2020; 10. DOI: 10.3390/ani10081444.
- 24 Hart K, Brooks Brownlie H, Ogden D, et al. **A case of gastric leiomyosarcoma in a domestic shorthair cat.** *JFMS Open Rep* 2018; 4. DOI: 10.1177/2055116918818912.
- 25 Munday JS, Löhr CV and Kiupel M. **Tumors of the alimentary tract.** In: *Tumors in domestic animals*. John Wiley & Sons, 2016, pp 499–601.
- 26 Meuten DJ. **Tumors in domestic animals.** John Wiley & Sons, 2016.
- 27 Dollo V, Chambers G and Carothers M. **Endoscopic retrieval of gastric and oesophageal foreign bodies in 52 cats.** *J Small Anim Pract* 2020; 61: 51–56.
- 28 Sutton JS, Culp WTN, Scotti K, et al. **Perioperative morbidity and outcome of esophageal surgery in dogs and cats: 72 cases (1993–2013).** *J Am Vet Med Assoc* 2016; 249: 787–793.
- 29 Siow JW, Hoon QJ, Jenkins E, et al. **Caval foramen hernia in a cat.** *JFMS Open Rep* 2020; 6. DOI: 10.1177/2055116920964021.
- 30 Morgan KRS, Singh A, Giuffrida MA, et al. **Outcome after surgical and conservative treatments of canine peritoneopericardial diaphragmatic hernia: a multi-institutional study of 128 dogs.** *Vet Surg* 2020; 49: 138–145.
- 31 Tolbert K and Gould E. **Gastritis and gastric ulceration in dogs and cats.** In: *Clinical small animal internal medicine*. John Wiley & Sons, 2020, pp 547–555.
- 32 Turner AI. **Cancer of the esophagus and stomach.** In: *Clinical small animal internal medicine*. John Wiley & Sons, 2020, pp 1283–1286.
- 33 Phillips H, Corrie J, Engel DM, et al. **Clinical findings, diagnostic test results, and treatment outcome in cats with hiatal hernia: 31 cases (1995–2018).** *J Vet Intern Med* 2019; 33. DOI: 10.1111/jvim.15583.