



Use of high-flow oxygen therapy in a cat with cardiogenic pulmonary edema

Authors: Pouzot-Nevoret, Céline, Hocine, Leïla, Allaouchiche, Bernard, and Her, Jiwoong

Source: Journal of Feline Medicine and Surgery Open Reports, 9(2)

Published By: SAGE Publishing

URL: <https://doi.org/10.1177/20551169231195767>

BioOne Complete (complete.BioOne.org) is a full-text database of 200 subscribed and open-access titles in the biological, ecological, and environmental sciences published by nonprofit societies, associations, museums, institutions, and presses.

Your use of this PDF, the BioOne Complete website, and all posted and associated content indicates your acceptance of BioOne's Terms of Use, available at www.bioone.org/terms-of-use.

Usage of BioOne Complete content is strictly limited to personal, educational, and non - commercial use. Commercial inquiries or rights and permissions requests should be directed to the individual publisher as copyright holder.

BioOne sees sustainable scholarly publishing as an inherently collaborative enterprise connecting authors, nonprofit publishers, academic institutions, research libraries, and research funders in the common goal of maximizing access to critical research.



Use of high-flow oxygen therapy in a cat with cardiogenic pulmonary edema

Céline Pouzot-Nevoret^{1,2} , Leïla Hocine², Bernard Allaouchiche^{2,3} and Jiwoong Her⁴ 

Journal of Feline Medicine and Surgery Open Reports
1–5

© The Author(s) 2023

Article reuse guidelines:

sagepub.com/journals-permissions

DOI: 10.1177/20551169231195767

journals.sagepub.com/home/jfmsopenreports

This paper was handled and processed by the European Editorial Office (ISFM) for publication in *JFMS Open Reports*



Abstract

Case summary A 7-month-old female spayed domestic shorthair cat was presented for respiratory distress due to cardiogenic pulmonary edema. Despite initial treatment and oxygen delivery in an oxygen tent, the cat still showed signs of severe respiratory effort and oxygen saturation measured via pulse oximetry was below 85%. Because the owners declined mechanical ventilation, the cat was transitioned to high-flow oxygen therapy (HFOT). HFOT allowed significant improvement of the respiration parameters within 15 mins without causing clinical complications. The cat was briefly anaesthetised for the placement of the nasal cannula on initiation of HFOT, and the interface was well tolerated thereafter. The cat was transitioned to an oxygen cage after 16 h, weaned from oxygen 4 h later and was discharged after 3 days of hospitalisation. Long-term follow-up showed no abnormalities, and the leading hypothesis was transient myocardial thickening.

Relevance and novel information The first use of HFOT in a dyspneic cat is described in this study. HFOT could be a life-saving option for cats with severe hypoxemia or do-not-intubate orders that fail to respond to conventional oxygen therapies.

Keywords: High-flow oxygen therapy; hypoxemia; dyspnoea; oxygen therapy

Accepted: 31 July 2023

Introduction

Supplemental oxygen administration is the first supportive measure provided to dyspneic cats upon admission to an emergency facility; however, severely dyspneic patients may fail to respond adequately to conventional oxygen delivery methods. High-flow oxygen therapy (HFOT) is a non-invasive technique allowing delivery of humidified and heated gas through a specific high-flow nasal cannula, at a high flow rate (up to 60 l/min), with a fraction of inspired oxygen (FiO₂) adjustable from 21% to 100%.¹ This technique has gained popularity in dyspneic dogs recently and was shown to be safe and effective in improving oxygenation indices.^{2–5} Gas preconditioning offers several physiological advantages, including improved tolerance⁶ and comfort.¹ It reduces the discrepancy between the oxygen flow and the patient's inspiratory flow, ensuring accurate delivery of FiO₂.⁶ Moreover, it generates a low positive airway

pressure,^{7,8} decreases anatomical dead spaces^{9–11} and alleviates ventilatory drive and breathing effort.¹² These benefits enable the utilisation of HFOT in cases of hypoxaemic respiratory failure. After an extensive review of the available literature, only one letter to the editor has

¹Intensive Care Unit (SIAMU), Université de Lyon, VetAgro Sup, APCSe, Marcy l'Etoile, France

²Université de Lyon, VetAgro Sup, APCSe, Marcy l'Étoile, France

³Hospices Civils de Lyon, Centre Hospitalier Lyon-Sud, Service de Réanimation, Pierre-Bénite, France

⁴Department of Veterinary Clinical Sciences, College of Veterinary Medicine, The Ohio State University, Columbus, OH, USA

Corresponding author:

Céline Pouzot-Nevoret, DVM, PhD, DECVECC, Intensive Care Unit (SIAMU), VetAgro Sup, Campus Vétérinaire de Lyon, 1 avenue Bourgelat, Marcy l'Étoile, 69280, France
Email: celine.pouzotnevoret@vetagro-sup.fr



Creative Commons Non Commercial CC BY-NC: This article is distributed under the terms of the Creative Commons

Attribution-NonCommercial 4.0 License (<https://creativecommons.org/licenses/by-nc/4.0/>) which permits non-commercial use, reproduction and distribution of the work without further permission provided the original work is attributed as specified on the SAGE and Open Access pages (<https://us.sagepub.com/en-us/nam/open-access-at-sage>).

mentioned the use of HFOT in a cat.¹³ In the present report, we describe a case of successful use of HFOT in a cat that failed to respond to conventional oxygen therapy.

Case description

A 7-month-old female spayed domestic shorthair cat (2.1 kg) was referred to the Emergency and Critical Care Service of VetAgro Sup Teaching Hospital for acute respiratory distress. Three days before the presentation, the cat had been spayed by the referring veterinarian. The cat received 2 ml/kg/h of isotonic crystalloids during anesthesia. The cat was discharged on the day of the surgery without any complications; however, 72 h after spaying, the owner noticed laboured breathing. The veterinarian administered 2.5 mg/kg of furosemide SC (Dimazon; Intervet) and referred the patient to the emergency service.

On presentation, the cat was lethargic, hypothermic (rectal temperature = 33.3°C), tachypnoeic (respiratory rate [RR] = 120 breaths per minute) and orthopnoeic with a paradoxical respiratory effort and multiple crackles on thoracic auscultation. The femoral pulses were weak and the heart rate was 210 beats per minute. A gallop rhythm was noticed. The thoracic point-of-care ultrasound showed coalescent B lines in all lung fields associated with an atrial enlargement (the ratio of left atrial to aortic diameter; LA:Ao = 2). The initial database showed hyperlactataemia (blood lactate = 4.5 mmol/l; reference interval [RI] = 0.5–2 mmol/l) consistent with cellular hypoxia, along with mild dehydration (packed cell volume = 58% [RI = 32–48%], total solids = 62 g/l [RI = 57–89 g/l]). Boluses of 0.3 mg/kg butorphanol (Torbugesic; Zoetis) and 2 mg/kg furosemide (Dimazon; Intervet) were administered intravenously (IV), and a furosemide constant rate infusion (CRI) was initiated at 0.5 mg/kg/h. The cat was warmed up and placed in an oxygen cage with a FiO₂ of 0.6.

The cat remained severely dyspnoeic and hypoxaemic, with oxygen saturation measured via pulse oximetry (SpO₂) between 75% and 85% for 30 mins after oxygen supplementation. The owner declined mechanical ventilation for financial reasons. It was therefore decided to transition the cat to HFOT, using an Optiflow nasal cannula interface and an Optiflow machine (Fisher & Paykel Healthcare) (Figure 1). The Optiflow Junior Nasal Cannula – Premature was chosen so that the nasal prongs would not exceed 50% of the diameter of the nares to allow adequate exhalation. The FiO₂ was set at 100%, and the gas temperature was set at 37°C. The oxygen was set to be delivered at a flow rate to cover the patient's minute ventilation (MV = RR × tidal volume, with tidal volume = 15 ml/kg). The RR was 120 breaths per minute

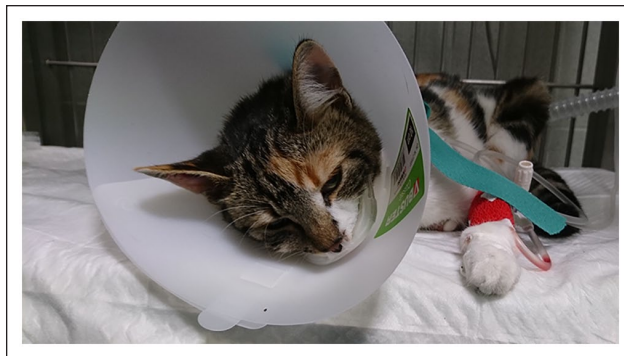

Figure 1 Cat with a high flow nasal cannula in place before fixation

at the time of setting, and the oxygen flow rate was therefore set at 3.8 l/min (1.8 l/kg/min).

The cat remained calm when placing the HFOT interface; however, as soon as the oxygen delivery was started, it rapidly tried to remove the interface. An attempt was made to replace the cannulas by gently holding the cat, but the cat continued to show signs of anxiety when starting the oxygen delivery, even with a lower flow rate. Therefore, it was decided to anaesthetise the patient to allow the placement of a nasal cannula and initiate the HFOT. The oxygen was delivered by flow-by in the meantime. The cat received 0.2 mg/kg IV butorphanol, 0.2 mg/kg midazolam (Midazolam, Mylan) and 0.5 mg/kg of Propofol (Provovet; Zoetis). The HFOT interface was adequately placed on the cat's face (Figure 1) and an e-collar was put on. Butterfly tapes and staples were added to secure the cannula (Figure 2). The cat slowly woke up and showed no more signs of anxiety and did not try to remove the cannulas. The cat's tolerance of HFOT, subjectively evaluated by the absence of attempts to remove the cannula, was excellent throughout the rest of the treatment with HFOT. Fifteen minutes after starting the HFOT, the SpO₂ had increased to 91%, the RR had dropped to 60 breaths per minute and the respiratory effort was subjectively improved. The SpO₂ remained between 85% and 94% for the next 1 h and the RR was between 60 and 130 breaths per minute.

The cat was kept on HFOT for 16 h. FiO₂ was gradually weaned over time to maintain SpO₂ around 97–98%. Furosemide (0.5 mg/kg/h CRI for 12 h and then 1 mg/kg IV q4h) and butorphanol (0.2 mg/kg IV q4h) was continued. As the method of administration was well tolerated, flow rate and temperature were not modified during the HFOT procedure despite the decrease in minute ventilation. When SpO₂ remained stable with a FiO₂ of 40%, the cat was transitioned to conventional oxygen in an oxygen cage for 4 h before the complete weaning of supplemental oxygen.

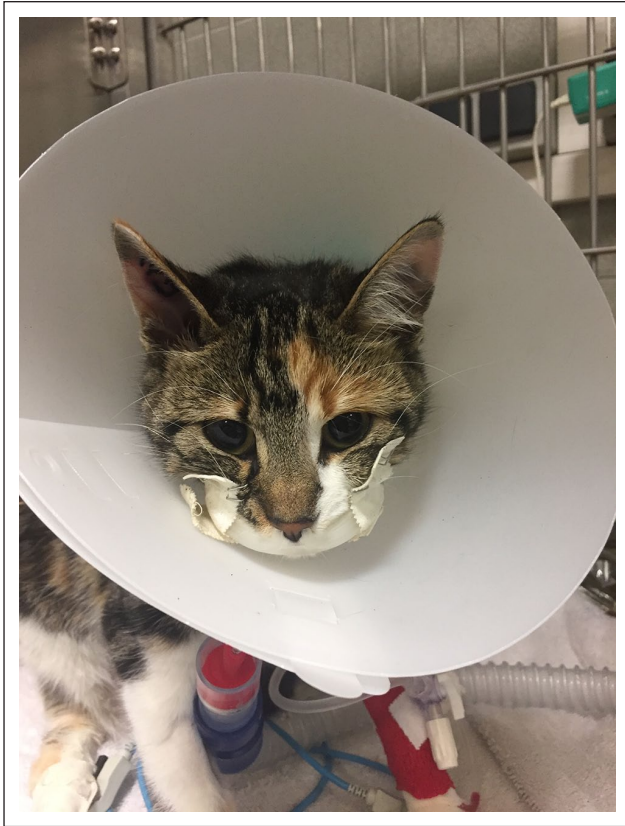

Figure 2 Cat with a high flow nasal cannula fixed with tape and staples placed under anaesthesia

Thoracic radiographs were possible after stabilisation (when HFOT was stopped) and they showed an interstitial-to-alveolar pulmonary pattern, especially in the ventral part of the left lungs and cranial and middle right lung lobes. Moderate cardiomegaly was noticed. Cardiac ultrasound performed by a board-certified radiologist the same day showed an asymmetrical thickening of the left ventricular walls (left ventricular free wall thickness measured at 6.8mm during diastole). The LA:Ao was 2.18, confirming the left atrial enlargement (Figure 3).

After 3 days of hospitalisation, the cat was discharged with furosemide 1 mg/kg PO q8h. Follow-up physical examination and cardiac ultrasound were performed 3 months later, showing no more abnormalities. All treatments were stopped, and a transient myocardial thickening was suspected. Contact with the owner 2 years later confirmed that the cat was healthy with no other episodes of respiratory distress.

Discussion

The use of HFOT has recently been increasingly described in dogs. It is a well-tolerated technique, resulting in improved oxygenation index, RR and respiratory effort in dogs with respiratory failure that fail to respond

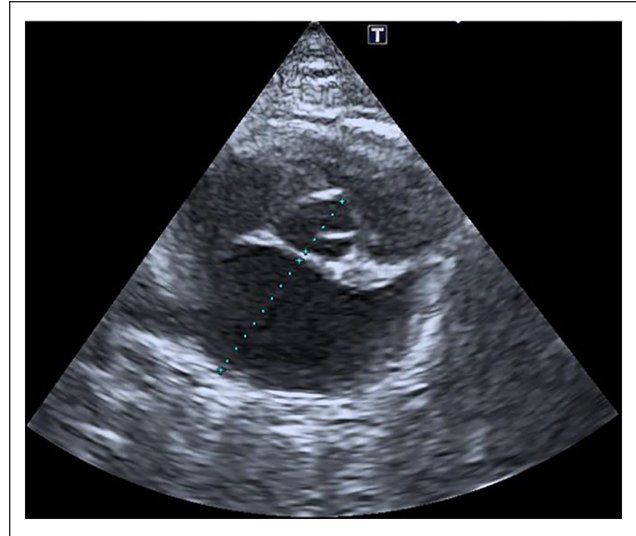


Figure 3 Cardiac ultrasound (short axis trans-aortic right parasternal view). Measurement of the LA:Ao ratio showing atrial enlargement

to conventional oxygen therapy (COT).³⁻⁵ To our knowledge, its use has not been described in cats. This case illustrated the use of HFOT in a cat failing to respond to COT. HFOT allowed a significant improvement in its oxygen saturation and respiratory effort.

Human studies have suggested that HFOT can be an alternative to COT or non-invasive positive pressure ventilation in patients with cardiogenic pulmonary oedema.¹⁴ A randomised controlled trial demonstrated that HFOT significantly improved RR, SpO₂ and arterial blood gas parameters compared with COT in patients with cardiogenic pulmonary oedema.¹⁵ Another randomised controlled trial showed that dyspnoea severity was significantly lower during the first hour of treatment with HFOT compared with COT.¹⁶ The present study concluded that HFOT could deliver adequate oxygenation and comfort with minimal complications or life-threatening adverse events. Similar to that described in the human and canine literature,⁴ HFOT allowed rapid improvement of oxygenation parameters in this cat, with SpO₂ increasing from 70% to 91% in 15 mins and reaching 94% within the first hour.

This case describes the potential utility of sedation/anaesthesia in cats to initiate HFOT. The cat smoothly accepted the placement of the HFOT interface. However, it displayed great stress as soon as the delivery of a high flow rate of oxygen was initiated and removed the interface. When repeating the manoeuvre, the cat instantly calmed down when the oxygen delivery through the HFOT cannulas was temporarily replaced with flow-by. We therefore anaesthetised the cat briefly to secure the HFOT interface with staples and an e-collar and started

the oxygen delivery under sedation. The patient woke up calmly, even with the high flow rate, and did not try to remove the interface anymore. More data are necessary to confirm whether sedation is needed in cats when starting HFOT.

The high inspiratory flows used in HFOT can increase the resistance to exhalation and cause hypercapnia if the nasal leak is inadequate due to large nasal cannulas. However, in human medicine, most studies have shown no clinically significant changes in the partial pressure of carbon dioxide.^{1,9} We tried to avoid blood samples as much as possible in the patient to minimise the stress caused by handling and therefore could not measure the partial pressure of carbon dioxide. However, we were careful to use cannulas that did not exceed 50% of the diameter of the nares. Several nasal cannula sizes are available, allowing the use of HFOT in small patients such as cats.

No clinically relevant complications were noted in this patient. Aerophagia secondary to the use of HFOT has been reported in healthy dogs.^{17,18} On our patient's thoracic radiographs, taken more than 12 h after initiation of HFOT, a discrete aerophagia was noted (whether secondary to the dyspnoea or the HFOT), but it was of no clinical significance. Air-leak syndromes (pneumothorax, pneumomediastinum) secondary to HFOT have been infrequently described in human medicine.^{19,20} Neither pneumomediastinum nor pneumothorax were noted on these radiographs.

Conclusions

This case report presents the first documented description of HFOT use in a cat. HFOT was used safely and allowed for improvement of oxygen saturation, respiratory effort and RR. No significant complications were observed. Except for the brief anaesthetic required to place the HFOT interface, the cat tolerated the treatment without additional sedation. HFOT may have been life-saving in this do-not-intubate feline patient that failed to respond to COT, and further prospective studies are warranted to confirm this observation.



Conflict of interest The authors declared no potential conflicts of interest with respect to the research, authorship, and/or publication of this article.

Funding The authors received no financial support for the research, authorship, and/or publication of this article.

Ethical approval The work described in this manuscript involved the use of non-experimental (owned or unowned) animals. Established internationally recognised high standards ('best practice') of veterinary clinical care for the individual patient were always followed and/or this work involved

the use of cadavers. Ethical approval from a committee was therefore not specifically required for publication in *JFMS Open Reports*. Although not required, where ethical approval was still obtained, it is stated in the manuscript.

Informed consent Informed consent (verbal or written) was obtained from the owner or legal custodian of all animal(s) described in this work (experimental or non-experimental animals, including cadavers) for all procedure(s) undertaken (prospective or retrospective studies). For any animals or people individually identifiable within this publication, informed consent (verbal or written) for their use in the publication was obtained from the people involved.

ORCID iD Céline Pouzot-Nevoret  <https://orcid.org/0000-0001-7269-8450>
Jiwoong Her  <https://orcid.org/0000-0003-3150-591X>

References

- 1 Frat JP, Thille AW, Mercat A, et al. **High-flow oxygen through nasal cannula in acute hypoxemic respiratory failure.** *N Engl J Med* 2015; 372: 2185–2196.
- 2 Keir I, Daly J, Haggerty J, et al. **Retrospective evaluation of the effect of high flow oxygen therapy delivered by nasal cannula on PaO₂ in dogs with moderate-to-severe hypoxemia.** *J Vet Emerg Crit Care* 2016; 26: 598–602.
- 3 Jagodich TA, Bersenas AME, Bateman SW, et al. **High-flow nasal cannula oxygen therapy in acute hypoxemic respiratory failure in 22 dogs requiring oxygen support escalation.** *J Vet Emerg Crit Care* 2020; 30: 364–375.
- 4 Pouzot-Nevoret C, Hocine L, Nègre J, et al. **Prospective pilot study for evaluation of high-flow oxygen therapy in dyspnoeic dogs: the HOT-DOG study.** *J Small Anim Pract* 2019; 60: 656–662.
- 5 Frischer R, Daly J, Haggerty J, et al. **High-flow nasal cannula improves hypoxemia in dogs failing conventional oxygen therapy.** *J Am Vet Med Assoc* 2022; 261: 210–216.
- 6 Sztrymf B, Messika J, Mayot T, et al. **Impact of high-flow nasal cannula oxygen therapy on intensive care unit patients with acute respiratory failure: a prospective observational study.** *J Crit Care* 2012; 27: 324.e9–324.e13.
- 7 Groves N and Tobin A. **High flow nasal oxygen generates positive airway pressure in adult volunteers.** *Aust Crit Care* 2007; 20: 126–131.
- 8 Parke RL, Eccleston ML and McGuinness SP. **The effects of flow on airway pressure during nasal high-flow oxygen therapy.** *Respir Care* 2011; 56: 1151–1155.
- 9 Millar J, Lutton S and O'Connor P. **The use of high-flow nasal oxygen therapy in the management of hypercarbic respiratory failure.** *Ther Adv Respir Dis* 2014; 8: 63–64.
- 10 Fernandez R, Subira C, Frutos-Vivar F, et al. **High-flow nasal cannula to prevent postextubation respiratory failure in high-risk non-hypercapnic patients: a randomized multicenter trial.** *Ann Intensive Care* 2017; 7: 47. DOI: 10.1186/s13613-017-0270-9.
- 11 Helviz Y and Einav S. **A systematic review of the high-flow nasal cannula for adult patients.** *Crit Care* 2018; 22: 71. DOI: 10.1186/s13054-018-1990-4.

- 12 Di Mussi R, Spadaro S, Stripoli T, et al. **High-flow nasal cannula oxygen therapy decreases postextubation neuroventilatory drive and work of breathing in patients with chronic obstructive pulmonary disease.** *Crit Care* 2018; 22: 180. DOI: 10.1186/s13054-018-2107-9.
- 13 Baudin F, Pouzot-Nevoret C, Hocine L, et al. **High flow nasal cannula: an alternative to continuous positive airway pressure in cats.** *J Feline Med Surg* 2021; 23: 405–406.
- 14 Adhikari P, Bhattarai S, Gupta A, et al. **Physiological effects of high-flow nasal cannula therapy and its use in acute cardiogenic pulmonary edema.** *Cureus* 2021; 13. DOI: 10.7759/cureus.13372.
- 15 Ko DR, Beom J, Lee HS, et al. **Benefits of high-flow nasal cannula therapy for acute pulmonary edema in patients with heart failure in the emergency department: a prospective multi-center randomized controlled trial.** *J Clin Med* 2020; 9: 1937. DOI: 10.3390/jcm9061937.
- 16 Makdee O, Monsomboon A, Surabenjawong U, et al. **High-flow nasal cannula versus conventional oxygen therapy in emergency department patients with cardiogenic pulmonary edema: a randomized controlled trial.** *Ann Emerg Med* 2017; 70: 465–472.e2.
- 17 Jagodich TA, Bersenas AME, Bateman SW, et al. **Comparison of high flow nasal cannula oxygen administration to traditional nasal cannula oxygen therapy in healthy dogs.** *J Vet Emerg Crit Care* 2019; 29: 246–255.
- 18 Daly JL, Guenther CL, Haggerty JM, et al. **Evaluation of oxygen administration with a high-flow nasal cannula to clinically normal dogs.** *Am J Vet Res* 2017; 78: 624–630.
- 19 Baudin F, Gagnon S, Crulli B, et al. **Modalities and complications associated with the use of high-flow nasal cannula: experience in a pediatric ICU.** *Respir Care* 2016; 61: 1305–1310.
- 20 Hsu CW. **Iatrogenic pneumothorax related to mechanical ventilation.** *World J Crit Care Med* 2014; 3: 8–14.