



Bacterial pericarditis associated with a hepatic abscess in a cat

Authors: White, Melissa, Miller, Rachel, and Locquet, Laurent

Source: Journal of Feline Medicine and Surgery Open Reports, 9(2)

Published By: SAGE Publishing


URL: <https://doi.org/10.1177/20551169231208896>

BioOne Complete (complete.BioOne.org) is a full-text database of 200 subscribed and open-access titles in the biological, ecological, and environmental sciences published by nonprofit societies, associations, museums, institutions, and presses.

Your use of this PDF, the BioOne Complete website, and all posted and associated content indicates your acceptance of BioOne's Terms of Use, available at www.bioone.org/terms-of-use.

Usage of BioOne Complete content is strictly limited to personal, educational, and non - commercial use. Commercial inquiries or rights and permissions requests should be directed to the individual publisher as copyright holder.

BioOne sees sustainable scholarly publishing as an inherently collaborative enterprise connecting authors, nonprofit publishers, academic institutions, research libraries, and research funders in the common goal of maximizing access to critical research.



Bacterial pericarditis associated with a hepatic abscess in a cat

Melissa White¹, Rachel Miller² and Laurent Locquet¹

Journal of Feline Medicine and Surgery Open Reports
1–5

© The Author(s) 2023

Article reuse guidelines:

sagepub.com/journals-permissions

DOI: 10.1177/20551169231208896

journals.sagepub.com/home/jfmsopenreports

This paper was handled and processed by the European Editorial Office (ISFM) for publication in *JFMS Open Reports*



Abstract

Case summary An 8-year-old male neutered domestic shorthair cat presented collapsed and was subsequently diagnosed with a pericardial effusion based on ultrasound imaging. A laboratory analysis of pericardial fluid revealed a septic pericardial effusion and further diagnostics, including abdominal ultrasound and fluid analysis, revealed a concurrent hepatic abscess. Bacterial isolation and identification from both septic foci revealed *Escherichia coli*. Therapeutic measures included a combination of medical and surgical intervention, the latter including a pericardiectomy, cholecystectomy, liver lobectomy and splenectomy.

Relevance and novel information Septic pericarditis is one of the least reported causes of feline pericardial effusion. This case report describes bacterial pericarditis in a cat, suspected to be derived from a hepatic abscess via haematological spread. In this case, a favourable response was achieved with both surgical and medical management.

Keywords: Bacterial pericarditis; hepatic abscess; pericardiectomy; cholecystectomy; liver lobectomy

Accepted: 4 October 2023

Case description

An 8-year-old male neutered domestic shorthair cat presented to a primary care veterinarian with a 3-day history of lethargy and inappetence. Clinical examination identified pyrexia (40.5°C) and a grade III/VI left-sided heart murmur. The murmur had first been documented 2 weeks prior, at routine vaccination. The cat was regularly vaccinated, lived indoors, with outside access, and had a previous history of urethral obstruction and periodontal disease. The patient was treated with a 7-day course of clavulanate-potentiase amoxicillin (16 mg/kg q12h) and a single injection of dexamethasone (0.2 mg/kg). Pyrexia resolved with treatment but 3 days after initial presentation the patient was found in lateral recumbency and was referred to an internal medicine department.

The cat was recumbent but alert and responsive on presentation. The patient had pale pink mucous membranes with a prolonged capillary refill time (CRT) of 3 s and weak peripheral pulses. The patient was tachypnoeic with a respiratory rate of 60 breaths per minute (bpm) and markedly increased respiratory effort. Cardiac auscultation identified muffled heart sounds

bilaterally with a heart rate of 160 beats per minute. The body condition score (BCS) was low at 3/9 (9-point body condition scoring system¹); the cat weighed 3.89 kg and had concomitant poor coat quality. The remaining clinical parameters were within normal limits.

A point-of-care ultrasound was performed upon arrival and identified pericardial effusion with right-sided cardiac tamponade. No pleural or peritoneal effusions were seen. The patient was sedated with butorphanol (0.2 mg/kg), midazolam (0.2 mg/kg) and dexmedetomidine (2 µg/kg) intravenously for pericardiocentesis. A pericardiocentesis catheter (8.2 Fr × 20 cm pericardiocentesis catheter; Surgivet) was inserted and

¹Dick White Referrals, part of Linnaeus Veterinary Limited, Six Mile Bottom, Cambridgeshire, UK

²Vet Oracle Medicine, CVS Referrals, Diss, Norfolk, UK

Corresponding author:

Melissa White BVetMed, MRCVS, Dick White Referrals, part of Linnaeus Veterinary Limited, Station Farm, London Road, Six Mile Bottom, Cambridgeshire CB8 0UH, UK
Email: Melissa.white@dwr.co.uk



Creative Commons Non Commercial CC BY-NC: This article is distributed under the terms of the Creative Commons

Attribution-NonCommercial 4.0 License (<https://creativecommons.org/licenses/by-nc/4.0/>) which permits non-commercial use, reproduction and distribution of the work without further permission provided the original work is attributed as specified on the SAGE and Open Access pages (<https://us.sagepub.com/en-us/nam/open-access-at-sage>).

Table 1 Laboratory results from initial presentation to internal medicine department and postoperatively

Laboratory parameter	Presentation	24 h postoperatively	Reference interval
Total protein (g/l)	52*	49*	54–78
Albumin (g/l)	15*	14*	24–39
Calcium (mmol/l)	2.1	1.9*	2.1–2.6
ALT (IU/l)	33	319*	30–85
AST (IU/l)	35	248*	15–66
Cholesterol (mmol/l)	4.7*	4.2*	1.9–3.9
Creatinine kinase (IU/l)	250*	4390*	0–152
RBC count ($\times 10^{12}/l$)	5.93*	Not measured	7.0–11.6
Haemoglobin (g/dl)	7.4*	Not measured	9.0–14.0
HCT (l/l)	0.23*	0.24*	0.29–0.46
WBC count ($\times 10^9/l$)	46.06*	Not measured	5.5–19.5
Neutrophils ($\times 10^9/l$)	37.77*	Not measured	2.5–12.5
Basophils ($\times 10^9/l$)	0.46*	Not measured	0.0–0.1
Eosinophils ($\times 10^9/l$)	0.00	Not measured	0.0–1.5

*Results outside of the feline reference interval

ALT = alanine transaminase; AST = aspartate aminotransferase; HCT = haematocrit; RBC = red blood cell; WBC = white blood cell

120 ml of turbid yellow fluid was drained. The patient recovered uneventfully and haemodynamic status was markedly improved after drainage, with good peripheral pulse quality and a CRT of 2s. The previous dyspnoea had resolved and the respiratory rate was reduced to 40 bpm. Fluid cytological evaluation was consistent with septic exudate. Fluid nucleated cellularity was $50.30 \times 10^9/l$, comprising predominantly degenerate neutrophils with bacilli, and a total protein of 34 g/l. The patient developed marked pyrexia of 40.4°C a few hours after the initial pericardiocentesis. At this point, antibiotic treatment was changed from clavulanate-potentiated amoxicillin to pradofloxacin 3 mg/kg PO q24h (Veraflox oral suspension for cats; Elanco) pending bacterial culture and sensitivity results.

Once the patient was stable, further diagnostics were performed. A haematology evaluation identified non-regenerative anaemia with inflammatory leukogram. A biochemical analysis revealed hypoalbuminaemia and a small increase in creatinine kinase above the reference interval. Relevant results are shown in Table 1. A FIV/FeLV snap test (SNAP FIV/FeLV Combo Test; IDEXX) was negative. Urine was collected via cystocentesis. Urinalysis identified moderately concentrated urine (1.032) with unremarkable chemical parameters and no evidence of inflammation or infection. Urine culture was negative. *Bartonella* PCR on blood was negative. Pericardial effusion culture and antimicrobial resistance revealed profuse growth of *Escherichia coli* (Table 2).

Further diagnostic tests were performed 2 days after pericardial drainage. Abdominal ultrasound identified a large 15 × 34 mm cavitated mass protruding from the liver, dorsolateral to the gallbladder on the right (Figure 1). The remaining hepatic parenchyma was unremarkable with no sign of hepatomegaly. The spleen was diffusely

Table 2 Pericardial effusion culture and antimicrobial sensitivity panel from an 8-year-old male neutered domestic shorthair cat

Site	Pericardial effusion
Aerobic culture	Profuse <i>Escherichia coli</i>
Ampicillin	Sensitive
Amoxicillin	Sensitive
Amoxicillin and clavulanate	Sensitive
Cephalexin	Sensitive
Cefovecin	Sensitive
Doxycycline	Sensitive
Tetracycline	Sensitive
Trimethoprim sulphadiazine	Sensitive
Marbofloxacin	Sensitive
Enrofloxacin	Sensitive
Pradofloxacin	Sensitive
Extended-spectrum beta-lactamases-resistant organism	Negative
AmpC-resistant organism	Negative
Multidrug resistance	Negative

enlarged with rounded apices. The splenic parenchyma appeared heterogeneous with multifocal and poorly defined hypochoic patches. Fine-needle aspirates were collected from the cavitated hepatic mass and septic neutrophilic inflammation was identified on cytological examination. Bacterial culture and isolation identified *E coli* (Table 3). An abdominal effusion was sampled and was consistent with an inflammatory exudate. Fluid nucleated cells were $120.50 \times 10^9/l$, and although no bacteria were observed, an infectious agent was suspected given the findings.

Echocardiography was performed with all standard views assessed. A small quantity of residual echogenic

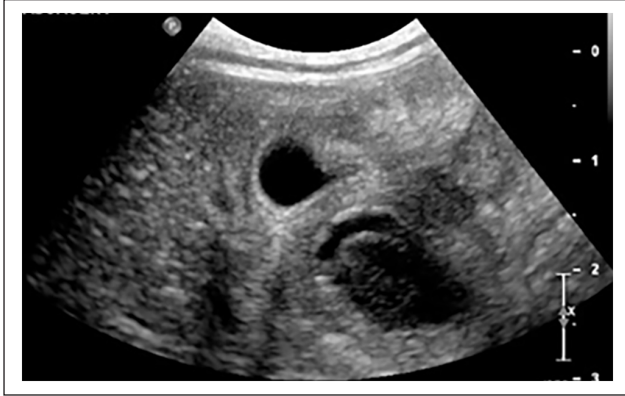

Figure 1 Abdominal ultrasound image. There is a large cavitated mass located dorsolateral to the gallbladder from an 8-year-old male neutered domestic shorthair cat

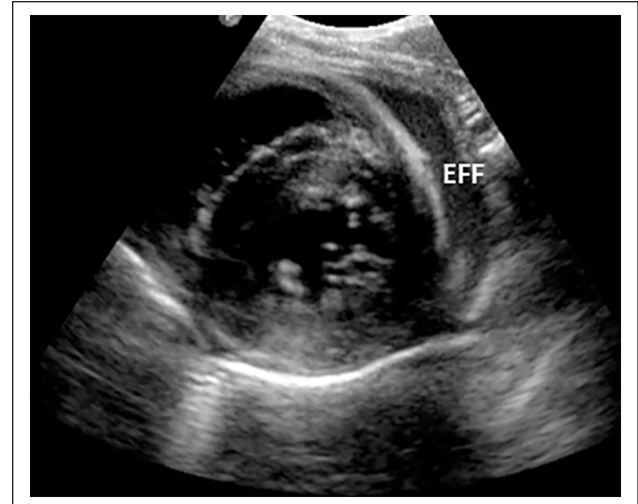


Figure 2 Echocardiography image from an 8-year-old male neutered domestic shorthair. Right parasternal short-axis view at the level of the papillary muscles. There is a small quantity of pericardial effusion (EFF) diffusely present around the ventricles

Table 3 Hepatic mass culture and antimicrobial sensitivity panel from an 8-year-old male neutered domestic shorthair cat

Site	Fluid from hepatic mass
Aerobic culture	Profuse <i>Escherichia coli</i>
Ampicillin	Sensitive
Amoxicillin	Sensitive
Amoxicillin and clavulanate	Sensitive
Cephalexin	Resistant
Cefovecin	Sensitive
Doxycycline	Sensitive
Tetracycline	Sensitive
Trimethoprim sulphadiazine	Sensitive
Marbofloxacin	Sensitive
Enrofloxacin	Sensitive
Pradofloxacin	Sensitive
Extended-spectrum beta-lactamases resistant organism	Negative
AmpC-resistant organism	Negative
Multidrug resistance	Negative

pericardial effusion that was not causing tamponade was noted (Figure 2). The cardiac wall thicknesses and chamber dimensions were within normal limits. A linear shadowing structure in the pericardial space was observed, which ran from the left ventricle apex to the right ventricle free wall. This finding was consistent with gas or foreign material. Post-pericardial drainage thoracic radiography documented a small pleural effusion with a bronchointerstitial pattern, and a moderately enlarged cardiac silhouette.

Shortly after the hepatic mass sampling, the patient's pulse quality decreased and the mucous membranes became pale. Given that medical management of a large hepatic abscess would be challenging and the patient's stability had declined, along with concerns regarding a

possible septic peritonitis, an exploratory laparotomy was recommended. Analgesia included methadone 0.15 mg/kg IV, along with the placement of an epidural catheter injected with levobupivacaine and morphine. A ventral midline coeliotomy was performed with a significant volume of ascites identified. On exploration, a hepatic abscess appeared attached to the gall bladder. The gallbladder itself was thickened and adhered to the right medial liver lobe. A right liver lobectomy and cholecystectomy were performed. The spleen appeared grossly abnormal; therefore, a splenectomy was also performed. A median sternotomy and subtotal pericardiectomy were also performed and both body cavities were flushed copiously with sterile saline.

The patient made an uneventful recovery, not requiring admission to the intensive care unit. Pericardial, hepatic and cholecystic histopathological evaluation revealed marked pyogranulomatous inflammation. No neoplastic indication was seen. A splenic histopathological evaluation showed reactive lymphoid hyperplasia with extramedullary haematopoiesis. The patient was discharged on a 2-week course of pradofloxacin 3 mg/kg q24h, which was given to completion.

A clinical reassessment occurred 3 weeks after discharge, due to owner delay. The patient was reported to be clinically well with a significant improvement in both body weight (4.60 kg) and BCS (5/9). The patient's peripheral pulse was strong and the mucous membranes were pink. The only abnormality noted during examination was a gallop sound with a grade II/VI apical systolic murmur. A new haematological evaluation revealed an improvement in anaemia with haemoglobin within the

reference interval. There was also mild neutrophilia, eosinophilia and basophilia. Previous hypoalbuminaemia had resolved. The patient was discharged with a 5-day course of fenbendazole (50 mg/kg q24h) as a prophylactic measure. A further follow-up was declined by the owner.

Discussion

Reports of feline bacterial pericarditis are scarce in the veterinary literature. A retrospective study of 146 feline patients with pericardial effusion did not report a single case with septic aetiology,² highlighting the rarity of this pathology. Septic pericarditis in dogs and cats can develop for numerous reasons, including concurrent pleural or pulmonary infections, penetrating trauma, migrating foreign body or haematogenous spread from other bacterial foci.³ A few cases have been reported in cats.^{4–8} The suspected mechanisms underlying reported cases include haematogenous spread,^{4,5} localised spread of infection,⁶ migrating foreign body⁷ and unidentified causes.⁸

In this case, the septic pericarditis was suspected secondarily to haematogenous spread from the liver pathology present. *E coli* is commonly isolated in positive culture samples from dogs and cats with hepatobiliary disease.^{9,10} Other common agents include *Enterococcus* species, *Bacteroides* species and *Clostridium* species. These bacteria are commonly found in the gastrointestinal tract and travel to the liver via the biliary system or translocation into the portal vein. A small case series of hepatic abscess in 14 cats found the bacterial populations cultured were often species that populate the gastrointestinal tract, including *E coli*, which was most commonly cultured, as well as *Streptococcus*, *Enterococcus*, *Pseudomonas*, *Enterobacter* and *Bacteroides* species.¹¹ Therefore, given that the infectious agent was *E coli*, it is suspected that the hepatic abscess was the primary site and that haematogenous spread via the portal vein resulted in seeding to the pericardium.

Hepatic abscesses are relatively uncommon pathological findings in cats. In a published study comprising 58 cats with general hepatobiliary disease, no hepatic abscessation was reported; however, 14% of hepatic and 36% of biliary cultured samples were positive for bacterial growth.¹⁰ This highlights that even within a population of cats with positive hepatic tissue cultures, the presentation of abscesses is uncommon. The indicated treatment for hepatic abscessation in cats is unclear. In human medicine, hepatic abscesses less than 3–5 cm in size are usually drained percutaneously and treated with antibiotics, based on culture and antimicrobial sensitivity. Larger abscesses sometimes require surgical management as well as systemic antibiotics.¹² A small case series documented percutaneous drainage and alcoholisation of hepatic abscesses in five dogs and one cat with excellent results.¹³ This less invasive therapeutic method was not considered

in this case given the concerns regarding septic peritonitis. This treatment would be more appropriate in clinically stable patients without additional comorbidities that require surgery.

There are a few veterinary reports that describe septic pericarditis secondarily to suspected haematogenous spread in cats. A single case describes septic pericarditis due to presumed haematogenous spread from the oral cavity in a patient that had recently undergone a dental procedure. The cat was treated solely with medical management and the resolution of pericardial effusion was documented.⁴ An additional report described septic pericarditis associated with a pyometra in an intact female cat. This patient was treated both surgically and medically, with sub-total pericardiectomy and ovariohysterectomy, as well as a 4-week course of enrofloxacin and metronidazole. The patient was clinically well 1 year later.⁵

Due to the low incidence of septic pericarditis in cats,² the most appropriate treatment has not yet been determined. Reported cases suggest some septic pericardial effusions may be managed conservatively with pericardiocentesis, antimicrobial therapy and supportive care^{4,8}; however, pericardiectomy can be recommended once the patient is stabilised due to reports of subsequent complications.⁶ Constrictive pericarditis is a rare complication of acute pericarditis in humans; the incidence rate is 1.8%, but when considering specific aetiologies, an increased risk was observed in those with purulent pericarditis.¹⁴ In dogs, constrictive pericarditis is most commonly idiopathic or associated with infection,¹⁵ but there are limited reports in cats. A previously reported feline case described the medical management of a cat with bacterial pericarditis, suspected to be secondary to pulmonary infection.⁶ The patient did not survive after developing subsequent constrictive pericarditis. This suggests additional surgical management may be of benefit in feline cases.

In the case presented here, the patient was lost to follow-up, and although a favourable response was seen, the long-term outcome was not available. The gallop sound and grade II/VI apical systolic murmur that was documented at the 3-week check-up was not investigated. Given the bacterial infection suspected from haematogenous spread, endocarditis was a sequel to be considered. In human patients, blood culture is often performed since 40–70% of the blood culture samples from cases of septic pericarditis are positive.¹⁶ In this case, blood culture was not performed but could be considered in future cases.

Conclusions

Septic pericarditis is a rare finding in cats and this case documents a favourable response to a combination of surgical and medical management.

Acknowledgements The authors thank Ruth Willis BVM&S DVC FRCVS for the selection of the echocardiography image.

Conflict of interest The authors declared no potential conflicts of interest with respect to the research, authorship, and/or publication of this article.

Funding The authors disclosed receipt of the following financial support for the research, authorship, and/or publication of this article: Linnaeus Veterinary Limited supported the costs of the open access publication charge.

Ethical approval The work described in this manuscript involved the use of non-experimental (owned or unowned) animals. Established internationally recognised high standards ('best practice') of veterinary care for the individual patient were always followed and/or this work involved the use of cadavers. Ethical approval from a committee was therefore not specifically required for publication in *JFMS Open Reports*. Although not required, where ethical approval was still obtained, it is stated in the manuscript.

Informed consent Informed consent (verbal or written) was obtained from the owner or legal custodian of all animal(s) described in this work (experimental or non-experimental animals, including cadavers) for all procedure(s) undertaken (prospective or retrospective studies). No animals or people are identifiable within this publication, and therefore additional informed consent for publication was not required.

References

- 1 Laflamme DP. **Development and validation of a body condition score system for cats.** *Feline Pract* 1997; 25: 13–18.
- 2 Hall DJ, Shofer F, Meier CK, et al. **Pericardial effusion in cats: a retrospective study of clinical findings and outcome in 146 cats.** *J Vet Intern Med* 2007; 21: 1002–1007.
- 3 Calvert C and Thomason J. **Cardiovascular infections.** In: Greene C and Sykes J (eds). *Infectious disease of the dog and cat.* 4th ed. USA, Saunders, 2012, pp 934–935.
- 4 Lobetti RG. **Anaerobic bacterial pericardial effusion in a cat.** *J S Afr Vet Assoc* 2007; 78: 175–177.
- 5 Majoy SB, Sharp CR, Dickinson AE, et al. **Septic pericarditis in a cat with pyometra.** *J Vet Emerg Crit Care* 2013; 23: 68–76.
- 6 Tagawa M, Kurashima C, Shimbo G, et al. **Fibrinous pericarditis secondary to bacterial infection in a cat.** *J Vet Med Sci* 2017; 79: 957–961.
- 7 Denroche K, Fox PR, Prittie J, et al. **Septic pericarditis caused by a migrating grass awn in a cat.** *J Vet Cardiol* 2021; 36: 14–19.
- 8 LeBlanc N and Scollan KF. **Bacterial pericarditis in a cat.** *JFMS Open Rep* 2015; 1. DOI: 10.1177/2055116915603077.
- 9 Center SA, Randolph JF, Warner KL, et al. **Bacterial culture and immunohistochemical detection of bacteria and endotoxin in cats with suppurative cholangitis-cholangiohepatitis syndrome.** *J Am Vet Med Assoc* 2022; 260: 194–211.
- 10 Wagner K, Hartmann F and Trepanier L. **Bacterial culture results from liver, gallbladder, or bile in 248 dogs and cats evaluated for hepatobiliary disease: 1998–2003.** *J Vet Intern Med* 2007; 21: 417–424.
- 11 Sergeef J, Armstrong J and Bunch S. **Hepatic abscesses in cats: 14 cases (1985–2002).** *J Vet Intern Med* 2004; 18: 295–300.
- 12 Lardiere-Deguelte S, Ragot E, Amroun K, et al. **Hepatic abscess: diagnosis and management.** *J Visc Surg* 2015; 152: 231–243.
- 13 Zatlle A, Bonfanti U, Zini E, et al. **Percutaneous drainage and alcoholization of hepatic abscesses in five dogs and a cat.** *J Am Anim Hosp Assoc* 2005; 41: 34–38.
- 14 Imazio M, Brucato A, Maestroni S, et al. **Risk of constrictive pericarditis after acute pericarditis.** *Circulation* 2011; 124: 1270–1275.
- 15 Thomas W, Reed J, Bauer T, et al. **Constrictive pericardial disease in the dog.** *J Am Vet Med Assoc* 1984; 184: 546–553.
- 16 Brook I. **Pericarditis caused by anaerobic bacteria.** *Int J Antimicrob Agents* 2009; 33: 297–300.