



## **Acute Anaplasma phagocytophilum infection in a pediatric domestic cat**

Authors: Graham, Molly, Ewing, Patty, and Whelan, Megan

Source: Journal of Feline Medicine and Surgery Open Reports, 9(2)

Published By: SAGE Publishing

URL: <https://doi.org/10.1177/20551169231213505>

---

BioOne Complete ([complete.BioOne.org](https://complete.BioOne.org)) is a full-text database of 200 subscribed and open-access titles in the biological, ecological, and environmental sciences published by nonprofit societies, associations, museums, institutions, and presses.

Your use of this PDF, the BioOne Complete website, and all posted and associated content indicates your acceptance of BioOne's Terms of Use, available at [www.bioone.org/terms-of-use](https://www.bioone.org/terms-of-use).

Usage of BioOne Complete content is strictly limited to personal, educational, and non - commercial use. Commercial inquiries or rights and permissions requests should be directed to the individual publisher as copyright holder.

---

BioOne sees sustainable scholarly publishing as an inherently collaborative enterprise connecting authors, nonprofit publishers, academic institutions, research libraries, and research funders in the common goal of maximizing access to critical research.



# Acute *Anaplasma phagocytophilum* infection in a pediatric domestic cat

Molly Graham , Patty Ewing and Megan Whelan

*Journal of Feline Medicine and Surgery Open Reports*  
1–5

© The Author(s) 2023

Article reuse guidelines:

sagepub.com/journals-permissions

DOI: 10.1177/20551169231213505

journals.sagepub.com/home/jfmsopenreports

This paper was handled and processed by the American Editorial Office (AAFP) for publication in *JFMS Open Reports*



## Abstract

**Case summary** A domestic shorthair cat estimated to be 4–6 weeks old was presented to a referral center for evaluation of lethargy, anorexia and diarrhea for a duration of 24 h. A feline vector-borne PCR panel, as well as a blood smear, examined by a board-certified pathologist, confirmed an *Anaplasma phagocytophilum* infection. Morulae were identified in both feline neutrophils and eosinophils. Treatment consisted of a 21-day course of liquid doxycycline. Clinical signs rapidly resolved and were not noted to recur.

**Relevance and novel information** This case demonstrates that *A phagocytophilum* can infect cats as young as 4–6 weeks old. Doxycycline, as the antibiotic of choice for the treatment of *A phagocytophilum* infections, was used. Consistent with the literature, a rapid clinical improvement was detected. Anaplasmosis should be listed as a differential diagnosis in pediatric cats suffering from acute febrile illness with potential previous tick exposure (history of living outdoors) in order to provide proper treatment.

**Keywords:** Feline granulocytic anaplasmosis; eosinophilic granulocytes; tick-borne; morulae

**Accepted:** 20 October 2023

## Introduction

Feline granulocytic anaplasmosis is a vector-borne disease caused by the Gram-negative, obligate intracellular bacterium *Anaplasma phagocytophilum* (encompassing the former *Ehrlichia phagocytophila*, *Ehrlichia equi* and the human granulocytic ehrlichiosis agent).<sup>1,2</sup> *A phagocytophilum* infections have often been described in dogs and horses, but reports of natural infections in cats are less common.<sup>1</sup> The clinical signs are non-specific, but may include fever, lethargy and inappetence.<sup>2</sup>

*A phagocytophilum* causes granulocytic anaplasmosis in humans and animals and is transmitted by ticks of the *Ixodes scapularis* complex.<sup>1</sup> Common reservoirs for transmission are rodents and wild ruminants.<sup>1</sup> The New England region is a highly endemic area for *A phagocytophilum* and *Borrelia burgdorferi* complex, as well as their shared tick vector, *I scapularis*.<sup>3</sup>

In Sweden, Bjoersdorff et al were first to report PCR amplification of *A phagocytophilum* from a cat.<sup>4</sup> The DNA sequence in a 14-month-old shorthair cat with lethargy and fever was 100% identical to canine and equine *A phagocytophilum* strains in the same region.<sup>4</sup> A tentative diagnosis of feline anaplasmosis can be made

by detecting intracytoplasmic morulae within neutrophils and eosinophils.<sup>2</sup> The diagnosis is confirmed by PCR and serology in paired serum samples taken before initiating treatment.<sup>2</sup>

In the USA, the antibody prevalence for feline *A phagocytophilum* has been described in the range of 4.3–37.6%.<sup>1</sup> Direct pathogen detection via PCR or identification of neutrophilic morulae in a blood smear was observed in 0–6.9% of cats in the USA.<sup>1</sup> Wide ranges in the prevalence of *A phagocytophilum* infection in dogs and cats could be explained by large geographical areas studied, with varying environments, tick populations and reservoir host populations.<sup>1</sup> Stray cats have an increased risk of vector contact due to living outdoors and lack of ectoparasite prophylaxis.<sup>1</sup>

Angell Animal Medical Center, Boston, MA, USA

### Corresponding author:

Molly Graham DVM, Angell Animal Medical Center,  
350 S. Huntington Avenue, Boston, MA 02130, USA  
Email: mgraham@mspca.org



Creative Commons Non Commercial CC BY-NC: This article is distributed under the terms of the Creative Commons

Attribution-NonCommercial 4.0 License (<https://creativecommons.org/licenses/by-nc/4.0/>) which permits non-commercial use, reproduction and distribution of the work without further permission provided the original work is attributed as specified on the SAGE and Open Access pages (<https://us.sagepub.com/en-us/nam/open-access-at-sage>).

**Table 1** Point-of-care biochemical analysis in domestic shorthair cat aged 4–6 weeks infected with *Anaplasma phagocytophilum*

Biochemistry parameter	Value	Reference interval
Sodium (mmol/l)	144	146–156
Potassium (mmol/l)	5.54	3.41–4.71
Chloride (mmol/l)	116.9	117–125.3
Ionized calcium (mmol/l)	1.31	1.16–1.35
Glucose (mg/dl)	137	72–132
Lactate (mmol/l)	3.20	1.10–3.50
Blood urea nitrogen (mg/dl)	15	22–33
Creatinine (mg/dl)	0.5	0.7–1.9
pH	7.309	7.265–7.424
pCO <sub>2</sub>	26.8	33.2–47.3
HCO <sub>3</sub> (mmol/l)	13.6	

Performed on a NOVA Biomedical pHox Ultra. Reference intervals are not age-related and are specific to the laboratory at this institution

## Case description

### History

An intact female domestic shorthair cat aged approximately 4–6 weeks was presented to a referral center in Massachusetts for lethargy, anorexia and diarrhea in June 2022. The kitten was a stray, found outside 1 week before presentation; no previous medical history was available due to the feral status. The clinical signs began 1 day before presentation and 6 days after the kitten was rescued. The patient's age was estimated based on weight (0.6 kg), dentition and body condition score.

### Clinical presentation

The abnormal findings on initial clinical examination were fever (40.8°C [105.4°F]), mild tachypnea (40 bpm), and mild ocular and nasal crusting. Based on a physical examination, the kitten was noted to be 5% dehydrated. There were no cutaneous lesions or tick attachment noted.

### Diagnostics

A point-of-care ultrasound showed no free fluid or obvious abnormalities in either the thorax or the abdomen. Venous blood samples were obtained in EDTA and heparin tubes. A packed cell volume was performed on heparinized blood and was within the reference interval (RI) used at this institution. A point-of-care biochemical analysis performed on a NOVA Biomedical pHox Ultra showed a decreased pCO<sub>2</sub> (26.8 mmHg; RI 33.2–47.3) (Table 1). A complete blood count (CBC) performed on EDTA anticoagulated blood using a Sysmex XN-V hematology analyzer showed a decreased automated platelet count (Table 2). A manual slide review indicated marked platelet clumping and variation in platelet size, causing interference with the machine count. The platelet numbers were considered adequate on manual review of the

blood smear. Large platelets may indicate increased thrombopoiesis.<sup>5</sup> A Fecal Dx Profile with *Giardia* performed by Idexx Laboratories was negative for antigens of *Giardia*, hookworm, whipworm and roundworm; however, a number of *Toxocara cati* ova (3–10) were present. A blood smear, examined microscopically by a board-certified pathologist, detected morulae that were morphologically consistent with *A phagocytophilum* in approximately 10% of the neutrophils present and at least one eosinophil (Figure 1). A PCR panel for feline vector-borne diseases was performed by Antech Diagnostics (Feline Flea and Tick Borne PCR T965) using EDTA anticoagulated blood and found to be positive for only *A phagocytophilum* (see supplementary material). An upper respiratory PCR panel performed by Antech Diagnostics (Feline Upper Respiratory FastPanel PCR T990) using sterile swabs of the oropharynx detected no sign of upper respiratory infection.

### Treatment

Initially, the patient was started on intravenous fluids (lactated Ringer's solution at a rate of 116 ml/kg/day) and fenbendazole (50 mg/kg PO q24h for 5 days). Oral doxycycline liquid suspension (5 mg/kg q12h for 21 days) therapy was initiated after pathologist review of the blood smear. The owners were instructed to give food, the medication, food and then 5 ml water to decrease the risk of esophageal stricture formation. The patient's fever resolved and its appetite improved within 24 h of hospitalization.

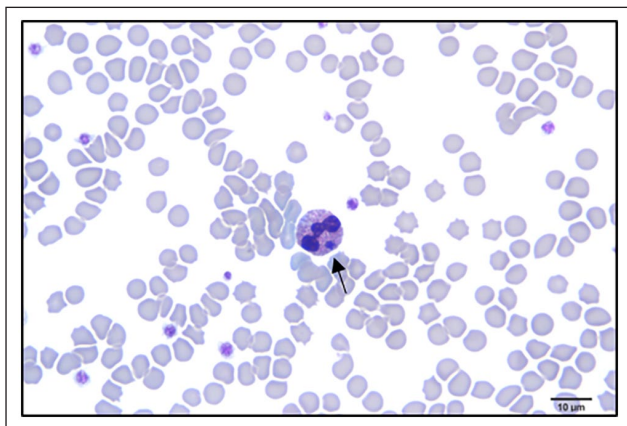
### Follow-up

During a telephone follow-up 23 days after discharge, the owner reported that the patient was clinically healthy and the owner had no concerns. No additional PCR testing was performed.

**Table 2** Complete blood count in a domestic shorthair cat aged 4–6 weeks infected with *Anaplasma phagocytophilum*

Hematologic parameter	Value	Reference interval
White blood cell count (K/ul)	7.4	4.3–15.9
Red blood cell count (M/ul)	8.05	7.40–11.08
Hemoglobin concentration (g/dl)	11.2	10.6–16.5
Hematocrit (%)	33.4	31.6–46.9
Mean cell volume (fl)	41.5	32.9–51.4
Mean cell hemoglobin (pg)	13.9	12.6–16.7
Mean cell hemoglobin concentration (g/dl)	33.5	30.7–38.4
Red blood cell distribution width (%)	17.2	16.0–20.5
Platelet count (K/ul)	141	200–589
Plateletcrit (%)	0.190	0.140–0.620
Mean platelet volume (fl)	13.7	9.0–14.4
Reticulocyte count (K/ul)	22.5	1.1–79.7
Reticulocyte percentage (%)	0.3	0.1–0.9
Neutrophils (K/ul)	4.7	1.7–10.3
Lymphocytes (K/ul)	1.9	0.8–7.4
Monocytes (K/ul)	0.4	0.1–0.6
Eosinophils (K/ul)	0.4	0.1–2.1

Performed on a Sysmex XN-V hematology analyzer. Reference intervals are not age-related and are specific to the laboratory at this institution



**Figure 1** Feline eosinophil containing *Anaplasma phagocytophilum* morula (black arrow). Wright's stain. Image courtesy of P Ewing, Angell Animal Medical Center

## Discussion

The present report describes a clinical case of feline anaplasmosis in a pediatric patient with a history of potential tick exposure due to living outdoors as a stray. To the authors' knowledge, there have been no reports of *A phagocytophilum* infection in cats aged under 16 weeks in the USA. In addition, there have not been any reported cases in cats with naturally occurring *A phagocytophilum* morulae identified in eosinophils. In an experimental setting, morulae of *A phagocytophilum* have been identified in eosinophils of cats within 1 week of inoculation.<sup>6</sup>

The first clinical report of granulocytic anaplasmosis in cats was published in 1999; however, confirmed cases are becoming more frequent.<sup>3</sup> Increasing prevalence of

anaplasmosis in both animals and humans may be a result of several factors, including increasing awareness of vector-borne diseases and how global climate change affects the distribution and prevalence of reservoir animals and vectors.<sup>2</sup> In a recent study by Galemore et al, the prevalence of exposure to *A phagocytophilum* in feral cats in Massachusetts was 9.7%, whereas the prevalence of acute infection was 6.9%.<sup>3</sup> Feral cats have a higher prevalence of *A phagocytophilum* than the previously reported national average of 4.3% in the USA.<sup>3</sup> The acute infection in this cat was confirmed by the presence of morula and the positive PCR test.

Clinical disease owing to anaplasmosis in cats can present with the following signs: fever, thrombocytopenia, hyperglobulinemia, lethargy, anorexia, weight loss, vomiting, polyarthrits, lameness and ocular discharge.<sup>7</sup> In a recent study of *A phagocytophilum* infection in 16 domestic cats in the northeastern USA, all cats were lethargic, 14/16 were anorexic and 15/16 were pyrexical (>39.4°C, >103°F) on presentation.<sup>8</sup> This case exhibited common clinical signs on presentation, including fever, anorexia and lethargy. Savidge et al<sup>8</sup> reported that all cats with morulae identified were hyperthermic. The cat presented here was febrile at 40.8°C (105.6°F), which is consistent with previous studies.

With the exception of the intracytoplasmic morulae identified within neutrophils, reported clinicopathologic abnormalities are non-specific for infection with *A phagocytophilum*.<sup>8</sup> Previous studies have diagnosed thrombocytopenia in over half of the cats evaluated (n = 7/11), but all samples had clumped platelets, which falsely decreases the automated platelet counts.<sup>8</sup> Low platelet counts on mechanical measurements are influenced by

platelet clumping, giant platelets and inadequate separation of erythrocytes and platelets, which can lead to falsely low platelet counts.<sup>1</sup> For this reason, a manual platelet estimate was obtained to more accurately reflect adequacy of platelet number. The minimum platelet estimate excluded thrombocytopenia in this patient. The actual incidence of thrombocytopenia in cats is unknown. The cat in this report had a venous hypocarbia, which has not been previously reported as an association with *A phagocytophilum* infection. This may be a true hypocarbia or artefact secondary to user error, such as exposure of the sample to air or misuse of a clot catcher, which could artificially lower the pCO<sub>2</sub> of the sample.<sup>9</sup> The fever in this patient may have led to hyperventilation and subsequent hypocarbia.<sup>10</sup> Further research is needed to determine if this is clinically significant.

A feline vector-borne PCR test was performed to evaluate for *A phagocytophilum*, *Bartonella clarridgeae*, *Bartonella henselae*, *Bartonella quintana*, *Ehrlichia* species, *Mycoplasma haemofelis*, *Candidatus Mycoplasma haemominutum*, *Candidatus Mycoplasma turicensis*, *Rickettsia felis* and *Rickettsia rickettsia* (see supplementary material).<sup>11</sup> A respiratory PCR test utilizing swab samples (nasal discharge, oropharynx and/or conjunctiva) evaluated for feline calicivirus, influenza H1N1, *Bordetella bronchiseptica*, *Chlamydophila felis*, feline herpesvirus 1 and *Mycoplasma felis* to rule out concurrent respiratory disease due to presence of ocular and nasal crusting.<sup>11</sup> A limitation in this case is that feline leukemia virus-antigen and feline immunodeficiency virus-antibody testing were not performed.

*A phagocytophilum* bacteria infect myeloid cells, primarily neutrophils (occasionally eosinophils), forming intracytoplasmic inclusions called 'morula'.<sup>12</sup> A manual blood smear from this case confirmed morulae in approximately 10% of the neutrophils examined. The pathologist also confirmed morulae in at least one feline eosinophil. The detection of neutrophilic morulae is seemingly easier with a reported percentage of infected circulating neutrophils in the range of 1–24%.<sup>6</sup> A diagnosis of *A phagocytophilum* is made based on clinical suspicions, history of exposure to *Ixodes* species, identification of morulae within neutrophils, positive serologic and/or PCR results and treatment response.<sup>8,13</sup> The cat in this report met all of the above criteria, confirming an acute infection with *A phagocytophilum*.

Infections are highest in the late spring and autumn, when both nymph and adult ticks are most mobile.<sup>8</sup> Transmission to mammals occurs within 24–48 h of tick attachment.<sup>8</sup> This case presented in the late spring/early summer, consistent with the increased activity of nymph and adult ticks.<sup>8</sup> Cats, including pediatric cats, living in

an *Ixodes* species area with outdoor exposure may benefit from monthly treatment with an effective and licensed antiparasitic agent.

Previous reports in cats have recommended treatment with 5 mg/kg doxycycline PO q12h for 28 days, but the duration of treatment is variable and clinician-dependent.<sup>8</sup> Lappin et al reported that with the exception of severe lethargy, clinical signs and hematologic and biochemical abnormalities associated with *A phagocytophilum* infection were mild and resolved quickly after initiation of tetracycline treatment.<sup>14</sup> The cat in this report received 5 mg/kg doxycycline PO q24h for 21 days, which is consistent with the recommendation in Plumb's formulary<sup>15</sup> for anaplasmosis in cats. Clinical signs resolved within 24 h and were not noted to recur. Based on this report, pediatric cats with *A phagocytophilum* infection may present similarly to older cats and response to treatment is rapid.

## Conclusions

*A phagocytophilum* should be included on a differential diagnoses list for any cat that lives in an *Ixodes* species endemic area with potential tick exposure and presents with acute or intermittent unspecific clinical signs.<sup>8</sup> Humans are also susceptible to *A phagocytophilum* infections, making this pathogen relevant to both veterinary and human medicine.<sup>1</sup> Further research is needed to determine the prevalence of *A phagocytophilum* infection in pediatric cats living in endemic regions.

**Supplementary material** The following file is available as supplementary material: Antech Diagnostic Information

**Conflict of interest** The authors declared no potential conflicts of interest with respect to the research, authorship, and/or publication of this article.

**Funding** The authors received no financial support for the research, authorship, and/or publication of this article.

**Ethical approval** The work described in this manuscript involved the use of non-experimental (owned or unowned) animals. Established internationally recognised high standards ('best practice') of veterinary clinical care for the individual patient were always followed and/or this work involved the use of cadavers. Ethical approval from a committee was therefore not specifically required for publication in *JFMS Open Reports*. Although not required, where ethical approval was still obtained, it is stated in the manuscript.

**Informed consent** Informed consent (verbal or written) was obtained from the owner or legal custodian of all animal(s) described in this work (experimental or non-experimental

animals, including cadavers) for all procedure(s) undertaken (prospective or retrospective studies).

**ORCID iD** Molly Graham  <https://orcid.org/0009-0007-9696-0688>

## References

- Schäfer I and Kohn B. *Anaplasma phagocytophilum* infection in cats: a literature review to raise clinical awareness. *J Feline Med Surg* 2020; 22: 428–441.
- Heikkilä HM, Bondarenko A, Mihalkov A, et al. *Anaplasma phagocytophilum* infection in a domestic cat in Finland: case report. *Acta Vet Scand* 2010; 52. DOI: 10.1186/1751-0147-52-62.
- Galemore ER, Labato MA and O’Neil E. Prevalence of *Anaplasma phagocytophilum* infection in feral cats in Massachusetts. *J Feline Med Surg* 2018; 23: 4. DOI: 10.1177/2055116917753804.
- Hegarty BC, Qurollo BA, Thomas B, et al. Serological and molecular analysis of feline vector-borne anaplasmosis and ehrlichiosis using species-specific peptides and PCR. *Parasit Vectors* 2015; 8: 320. DOI: 10.1186/s13071-015-0929-8.
- Silverstein DC, Hopper K, Wang A, et al. Thrombocytopenia. In: Small animal critical care medicine. 2nd ed. Elsevier, 2015, pp 567–568.
- Alison RW and Little SE. Diagnosis of rickettsial diseases in dogs and cats. *Vet Clin Pathol* 2013; 42: 127–144.
- Billeter SA, Spencer JA, Griffin B, et al. Prevalence of *Anaplasma phagocytophilum* in domestic felines in the United States. *Vet Parasitol* 2007; 147: 194–198.
- Savidge C, Ewing P, Andrews J, et al. *Anaplasma phagocytophilum* infection of domestic cats: 16 cases from the northeastern USA. *J Feline Med Surg* 2016; 18: 85–91.
- Narayanan S. Preanalytical issues related to blood sample mixing. <https://acutecaretesting.org/-/media/acutecare-testing/files/pdf/preanalytical-issues-related-to-blood-sample-mixing.pdf> (October 2005, accessed 2 July 2023).
- de Morais HSA and DiBartola SP. Ventilatory and metabolic compensation in dogs with acid-base disturbances. *J Vet Emerg Crit Care* 1991; 1: 39–49.
- Antech Diagnostics. 2023 directory of services. Vol. 1. Antech Reference Laboratory, 2023, pp 99–100. [https://www.flipsnack.com/9E8C8A99E8C/2023-directory-of-services\\_united-states/full-view.html](https://www.flipsnack.com/9E8C8A99E8C/2023-directory-of-services_united-states/full-view.html) (accessed 12 June 2023).
- El Hamiani Khatat S, Daminet S, Duchateau L, et al. Epidemiological and clinicopathological features of *Anaplasma phagocytophilum* infection in dogs: a systematic review. *Front Vet Sci* 2021; 8. DOI: 10.3389/fvets.2021.686644.
- Tarello W. Microscopic and clinical evidence for *Anaplasma (Ehrlichia) phagocytophilum* infection in Italian cats. *Vet Rec* 2005; 156: 772–774.
- Lappin MR, Breitschwerdt EB, Jensen WA, et al. Molecular and serologic evidence of *Anaplasma phagocytophilum* infection in cats in North America. *J Am Vet Med Assoc* 2004; 225: 893–896.
- Plumb DC. Doxycycline. *Plumb’s veterinary drugs*. <https://app.plumbs.com/drug/cqWG1Kqvh9PROD?source=search&searchQuery=doxy> (published January 2015, updated June 2022, accessed 25 June 2023).