

A RETROSPECTIVE STUDY OF PATHOLOGIC FINDINGS IN THE AMAZON AND ORINOCO RIVER DOLPHIN (INIA GEOFFRENSIS) IN CAPTIVITY

Authors: Bonar, Christopher J., Boede, Ernesto O., Hartmann, Manuel García, Lowenstein-Whaley, Joanne, Mujica-Jorquera, Esmeralda, et al.

Source: Journal of Zoo and Wildlife Medicine, 38(2) : 177-191

Published By: American Association of Zoo Veterinarians

URL: [https://doi.org/10.1638/1042-7260\(2007\)038\[0177:ARSOPF\]2.0.CO;2](https://doi.org/10.1638/1042-7260(2007)038[0177:ARSOPF]2.0.CO;2)

BioOne Complete (complete.BioOne.org) is a full-text database of 200 subscribed and open-access titles in the biological, ecological, and environmental sciences published by nonprofit societies, associations, museums, institutions, and presses.

Your use of this PDF, the BioOne Complete website, and all posted and associated content indicates your acceptance of BioOne's Terms of Use, available at www.bioone.org/terms-of-use.

Usage of BioOne Complete content is strictly limited to personal, educational, and non - commercial use. Commercial inquiries or rights and permissions requests should be directed to the individual publisher as copyright holder.

BioOne sees sustainable scholarly publishing as an inherently collaborative enterprise connecting authors, nonprofit publishers, academic institutions, research libraries, and research funders in the common goal of maximizing access to critical research.

A RETROSPECTIVE STUDY OF PATHOLOGIC FINDINGS IN THE AMAZON AND ORINOCO RIVER DOLPHIN (*INIA GEOFFRENSIS*) IN CAPTIVITY

Christopher J. Bonar, V.M.D., Ernesto O. Boede, D.V.M., Manuel García Hartmann, D.V.M., Joanne Lowenstein-Whaley, D.V.M., Esmeralda Mujica-Jorquera, Scott V. Parish, James V. Parish, Michael M. Garner, D.V.M., Dipl. A.C.V.P., and Cynthia K. Stadler, D.V.M.

Abstract: River dolphins are especially susceptible to negative human impacts. For their conservation, attempts of relocation or procreation ex situ may become important in the future to avoid their extinction. Additional knowledge and medical experiences of river dolphin management in captivity may aid such conservation efforts. The medical records and necropsy and histopathology reports on 123 captive Amazon River dolphins (*Inia geoffrensis*) were reviewed. Of these 123 animals, 105 were necropsied and 70 necropsies were supported with histopathology. Eighteen animals were not necropsied. Among wild-born animals, mortality was highest in the first 2 mo immediately postcapture and transport, accounting for 32 of 123 deaths. Pneumonia and skin lesions (cutaneous and subcutaneous ulcerations and abscesses) were the most common findings, found in 44 of 105 (42%) and 38 of 105 (36%) of gross diagnoses, respectively. At least 10 of 44 cases of pneumonia diagnosed grossly included a verminous component. Cachexia, from a variety of causes, was a major gross finding in 21 animals. Fifteen animals had histologic evidence of significant renal pathology, and this was the primary cause of death in 13 cases. Hepatic pathology was found in 18 cases, and bacterial sepsis was confirmed via histology in 16 cases. Based on these findings, it may be concluded that keys to successful maintenance of this species include 1) prophylactic anthelmintic and antibiotic therapy immediately postcapture; 2) maintenance of animals in larger enclosures than in past attempts, in compatible groups, and in facilities capable of separating aggressive animals; 3) maintenance in microbiologically hygienic water quality at all times; and 4) a proactive program of preventive medicine during the immediate postcapture, quarantine, and maintenance period of captivity.

Key words: Amazon River dolphin, *Inia geoffrensis*, captivity, pathology, mortality.

INTRODUCTION

The Amazon River dolphin (*Inia geoffrensis*) was kept occasionally in aquaria from the 1950s to the early 1970s. Between the first live importation of an *I. geoffrensis* to the United States in 1956 and the last recorded death in 2002, more than 140 *I.*

geoffrensis were imported into the United States, five to Europe, and at least two to Japan.^{5,6,10} In general, the species has developed a reputation among aquarists for being delicate and more prone to medical problems than the more commonly kept bottlenose dolphin (*Tursiops truncatus*). However, not only did animals at three institutions produce a total of 10 offspring, but also several animals survived 16–31 yr, and five founder and two F1 captive animals remain alive today.^{3–6,9,10,23,32,57} Only one published study has surveyed the morbidity and mortality of this species; it was based on a limited number of necropsies and was more focused on behavioral needs.¹⁰ This study seeks to compile and to analyze all available necropsy findings from *I. geoffrensis* kept in captivity in the United States, Venezuela, Germany, and Japan from 1956–2006.

MATERIALS AND METHODS

Medical histories, gross necropsy reports, and histopathology reports were requested from 22 institutions that housed *Inia*. Of these, 19 were able to provide medical data and 20 were able to provide longevity data. It was determined that 147 animals had been brought into captivity from 1956–2006.

From Cleveland Metroparks Zoo, 3900 Wildlife Way, Cleveland, Ohio 44109, USA (Bonar, S. V. Parish); the Aquarium of Valencia, Avenida Fernando Fituredo, Valencia, Venezuela (Boede, Mujica-Jorquera); The Cleveland Aquarium, Inc., P.O. Box 5368, Willowick, Ohio 44095, USA (Bonar); Marineland of Florida, 9610 Ocean Shore Boulevard, Marineland, Florida 32080, USA (Lowenstein-Whaley); Zoo Duisburg, Muelheimer Strasse 273, 47058 Duisburg, Germany (García Hartmann); Zairtec Systems, 8665 Dunbar Lane, Brecksville, Ohio 44141, USA (J. V. Parish); Northwest ZooPath, 654 West Main Street, Monroe, Washington 98272, USA (Garner); and the Pittsburgh Zoo and PPG Aquarium, One Wild Place, Pittsburgh, Pennsylvania 15206, USA (Stadler). Present addresses (Lowenstein-Whaley): 134 Brushwood Court, Palm Coast, Florida 32137, USA; (Boede): Apdo. Postal 1595, Valencia 2001, Venezuela; (Mujica-Jorquera): Apdo. Postal 1567, Valencia 2001, Venezuela. Correspondence should be directed to Dr. Bonar (cjb@clevelandmetroparks.com).

Of these animals, 123 partial or complete medical histories, including 105 gross postmortem findings, were available, and 70 necropsies were supported by histopathology. Although a histopathologic diagnosis was preferred, in some cases (e.g., perforating stomach ulcers, gastric foreign body, and severe pneumonia) gross findings were considered definitive. Cases used in previous publications also were included^{3,6,9,33,56–58,63} when original necropsy data could be obtained and could be compared with published accounts to confirm diagnoses. For five animals, histologic slides were available and were submitted to an additional pathologist for review and confirmation of findings.

Whenever captive longevity data was available, it was included in order to help determine if certain findings were more common at certain life stages. For 94 animals, enclosure dimensions were available. In order to help determine if crowding was a factor in mortality, objective indices of crowding were calculated. For these cases, number of animals per tank, number of males per tank, number of animals per unit of surface area (m²), and number of animals per unit volume (m³) were calculated for each individual animal at its date of death. These values then were analyzed using the Cox Proportional Hazards Survival Regression to determine if longevity was influenced by these indices of crowding to a statistically significant ($P < 0.05$) level.

RESULTS

Pathology

Major necropsy diagnoses and frequencies are presented in Table 1. Less frequent but interesting and unusual diagnoses are presented in Table 2.

Pulmonary pathology: Pneumonia was the most common pulmonary disease, found in 44 of 105 (42%) of gross necropsies and 33 of 70 (47%) of histologic diagnoses.

In 10 of 44 cases grossly diagnosed as pneumonia (23%), a verminous component was present, and in one trauma case, pulmonary trematodes were listed as an incidental finding. In nine pneumonia cases, the death occurred within the first month after importation. A higher proportion of the pneumonia cases occurring within 1 mo after shipment (five of nine, 56%) had a verminous component. When lung parasites were identified, they were the campulid trematode, *Hunterotrema caballeri*.^{35,63,64} In five pneumonia cases, bacteriologic cultures were performed. Predominant isolates were *Proteus* (three cases), *Morganella morganii* (two cases), and one isolate each of *Alcaligenes*, *Citrobacter*, *Chryseobacterium*, *Escherichia coli*, *Pas-*

teurella, *Pseudomonas*, and *Streptococcus*. In one case, *Pneumococcus* was isolated in addition to an alpha-hemolytic *Streptococcus*, *Proteus*, and *E. coli*.

Systemic pathology: Sixty-five cases of systemic disease were found. These included 21 cases of cachexia described grossly; 16 of 70 histologic diagnoses included septicemia (23%), with four additional cases suspected based on gross findings. Fourteen medical case histories (14/123, 11%) included descriptions of trauma. Five cases of peritonitis were described. Four of 16 (25%) histologically examined cases of septicemia were found concomitantly with pneumonia (five of 20, 25% of gross diagnoses), and one case occurred in combination with peritonitis.

Dermatopathology: Dermatitis, characterized by ulcerations and subcutaneous abscesses (Fig. 1) was noted either prior to death or at necropsy in 38 of 123 (30%) medical histories. Of these cases, 35 were necropsied and 22 had histopathology; four were not necropsied. Regrettably, in many cases, although histology of major internal organs was performed, biopsies of the skin lesions were not taken. Often, when histology was performed on the skin, etiologic agents were not seen—only acute and chronic inflammation and necrosis. However, in one abscess, gram-positive coccoid bacteria were noted. Septicemia was encountered in eight of 22 (36%) cases of subcutaneous abscessation and ulceration evaluated histologically, and pneumonia in 13 of 38 (34%) of gross diagnoses (10/22 or 45% with histologic diagnoses). Bacteriologic cultures were available from 18 individual animals with skin abscesses, and many animals had more than one organism isolated from the abscesses. The most common isolate was *Streptococcus* (11 isolates), and *E. coli* was the second most common (nine isolates). Isolates recovered from six animals were *Proteus* and *Pseudomonas*. *Klebsiella* and *Alcaligenes* were each isolated in only three separate cases. Other bacteria were represented with one or two isolates each. These bacteria were *Bacillus*, *Clostridium perfringens*, *Clostridium chauvoei*, *Erysipelothrix rhusiopathiae*, *Salmonella infantis*, *Salmonella oranienburg*, and *Staphylococcus aureus*.

Gastrointestinal pathology: Acute gastritis was diagnosed grossly in one case and was confirmed by histology in one additional case. Gastric ulcers (Fig. 2) were found in 14 necropsies, including eight with supporting histology. Gastric foreign bodies were found in 10 cases (Fig. 3). Eosinophilic enteritis was diagnosed histologically in two cases. One gross necropsy found such severe proliferative intestinal lesions as to cause complete obstruction

Table 1. Common pathologic findings in 105 captive *Inia geoffrensis* from 19 institutions in the United States, Venezuela, and Germany from 1956–2006. Frequency of pathologic finding is given in parentheses.

Organ system	Gross only	Histology	Disease findings reported
Body as a whole	19	33	Cachexia (21) Septicemia (16) Trauma (14) Peritonitis (4) Hyperpyrexia (4) Toxicity (3) Shock (2) Anesthetic death (1)
Lung	14	45	Pneumonia (44) Pulmonary trematodes (10) Fetal atelectasis (3) Congestion (2) Fibrosis (1) Edema (1)
Skin	12	23	Ulceration and abscessation (38) Traumatic wounds (4) Fungal dermatitis (1)
Liver	2	18	Hepatitis/cholangitis (7) Abscessation (2) Hemosiderosis (2) Hepatomegaly (1) Toxicity (1) Bile duct hyperplasia (1) Hepatocellular necrosis and hepatitis (1) Hepatopathy due to unknown cause (1) Bile duct obstruction (cholelith) (1) Fatty degeneration (1) Centrilobular necrosis (1)
Gastrointestinal tract	14	18	Ulceration (13) with perforation (3) Foreign bodies (11) Acute gastritis (3) Proliferative enteritis (1)
Kidney	0	15	Tubulonecrosis (3) Pyelonephritis and interstitial nephritis (3) Glomerulonephropathy (2) Hemosiderosis (2) Nephritis, unspecified (1) Chromoblastomycosis (1) Fibrosis and abscessation (1) Polymorphonuclear leukocytes in collecting ducts (1)

of the small intestine. Unfortunately, this unusual diagnosis was not confirmed histologically.

Hepatic pathology: Twenty cases of hepatic disease were encountered, 18 cases were confirmed histologically, and two were reported as gross findings. Histological diagnoses included both hepatocellular disease (Fig. 4) and cholangiocellular disease, as well as concurrent cases of both diseases. Two cases of hepatic abscessation were encountered, one of which was secondary to puncture by a foreign body (an ingested wire). One case included obstruction of the bile duct with a cholelith.

Renal pathology: Fifteen histological diagnoses included some form of renal disease. All were histologic diagnoses. These included two cases of nephritis, six of tubulonecrosis (Fig. 5), three each of glomerulonephritis and pyelonephritis, and one of renal interstitial fibrosis.

Miscellaneous pathology: Miscellaneous diseases included head trauma and cerebral hemorrhage (one), cerebral abscess (two), and two cases of verminous encephalitis, both of which were confirmed histologically.^{5,33,63,64} Pancreatitis was found in six cases, four diagnosed histologically, including one

Table 2. Interesting but uncommon pathologic findings in captive *Inia geoffrensis* from 19 institutions in the United States, Venezuela, and Germany from 1956–2006. Frequency of pathologic finding is given in parentheses.

Organ system	Gross only	Histology	Disease findings reported
Pancreas	2	5	Pancreatitis (6) Atrophy (1)
Hematopoietic/lymphatic	0	3	Splenitis (2) Atrophy (1)
Neurologic	1	4	Verminous encephalitis (2) Meningitis (1) Trauma, hemorrhage (1) Abscess (2)
Musculoskeletal	0	1	Osteomalacia (1)
Cardiac	1	1	Congestive heart failure (1 gross) Endocarditis (1)

case that was confirmed histologically by two independent pathologists (Fig. 6). Two cases of cardiac disease were noted. One case of congestive heart failure was suspected based on gross findings but was not confirmed histologically. One case of subacute, mural endocarditis with thrombus formation was confirmed histologically by two independent pathologists; no causative organism, however, could be identified in these cases.

Life history

A life table of annual mortalities in 97 wild-born *Inia* for which data was available is presented in

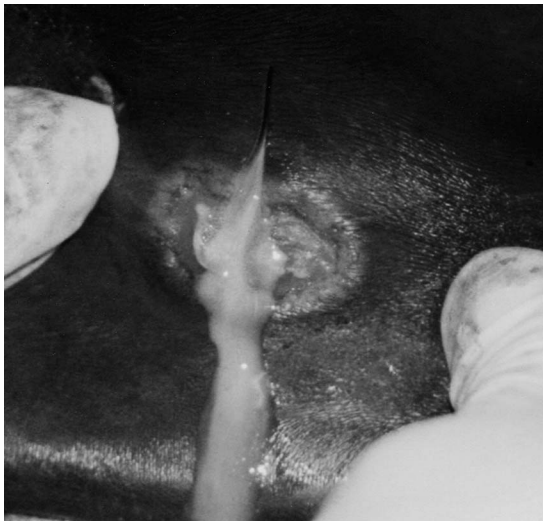

Figure 1. Suppurative discharge from a subcutaneous abscess in an *Inia geoffrensis* with a long history of recurrent abscesses. Such subcutaneous abscesses are a common finding in captive *Inia*, and often, but not always, are associated with *Streptococcus iniae* infection. Photo by the author (CJB).

Figure 7. Mortality was highest during the first year and demonstrates an asymptotic distribution. However, a significant minority of the animals lived beyond 10 yr in captivity. A breakdown of monthly mortality within the first year is presented in Figure 8. The great majority of deaths occurred within the first month of arrival at a facility.

Pool size

There were 13 institutions that provided information on pool size, pool depth, and surface area, as well as the number of inhabitants held (Table 3). The majority of the institutions housing *Inia* maintained them in pools with a depth of less than 2 m. Total surface area and the amount of surface area per animal also are presented in Table 3. Most tanks provided approximately 20 m² of surface area, although some individuals had significantly more space. The Cox Proportional Hazards Survival Regression indicated that there was a significant correlation ($P < 0.05$) between survival time and tank surface area, tank volume, number of animals per cubic meter of water, and female sex. Longer survival times were observed for those in larger tanks, those with a larger volume of water per animal, and for male animals. There was no statistically significant correlation ($P > 0.05$) between longevity and number of animals, number of males, or surface area per animal in the exhibit tank.

DISCUSSION

Pathology

Pulmonary pathology: Pneumonia has been an important cause of death in captive cetaceans since the early days of marine mammal medicine.^{1,8,9,12,16,17,25–28,31,47,55} In studies of the incidence of disease in both captive and wild (stranded) animals, pneumonia was the most common disease,

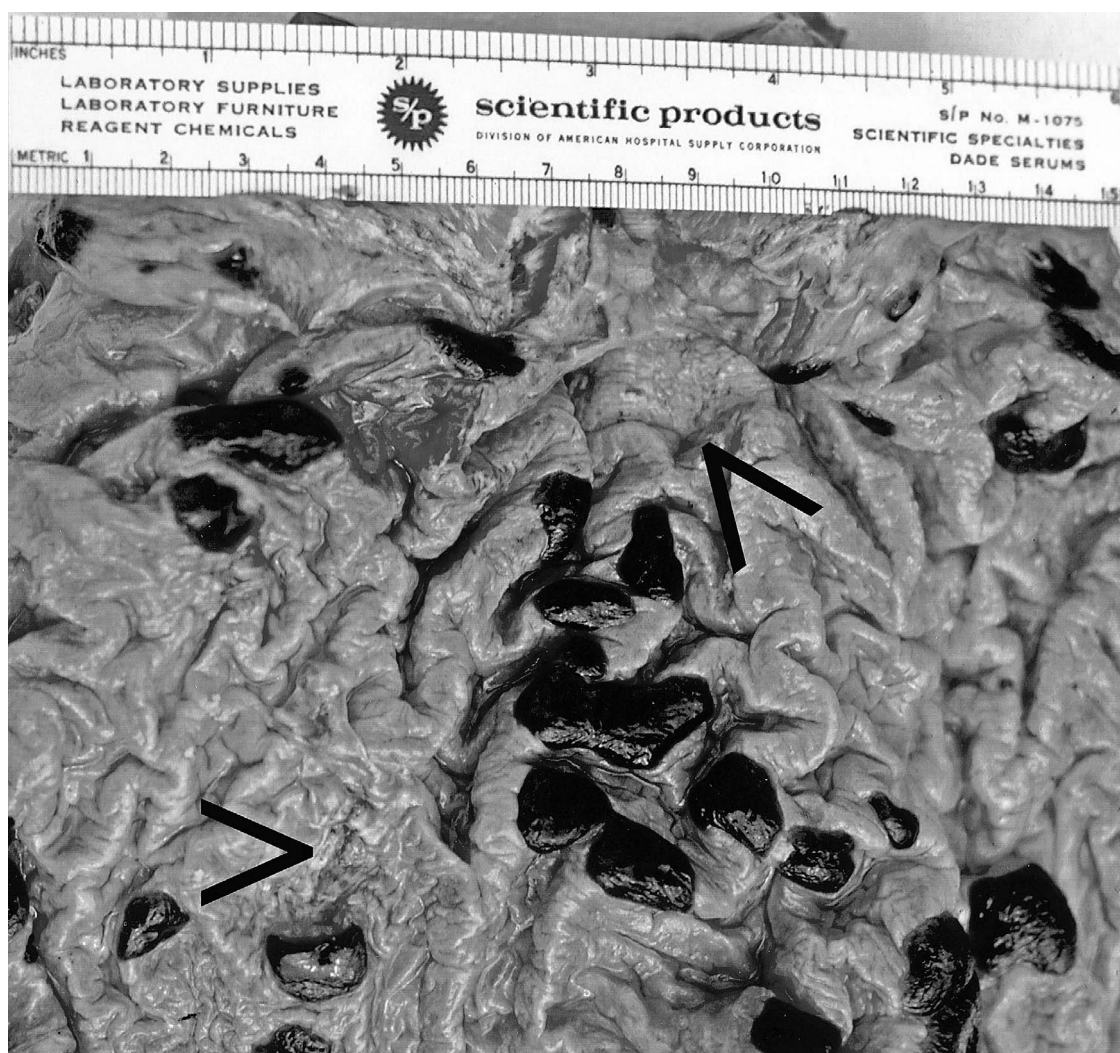


Figure 2. Gastric ulceration (arrows) and blood clots found at necropsy in an adult *Inia geoffrensis* that had been captive for approximately 2 mo. Photograph by the late David K. Caldwell, Marineland of Florida, Marineland, Florida, USA.

ranging from 39–44% of cases.^{17,19,25–28} The similarly high incidence of pneumonia in this study may be attributable to the physical, psychological, and temperature stresses of capture and transport. Additionally, a high percentage of the newly captured dolphins that died of pneumonia were parasitized with pulmonary trematodes, usually identified as *Hunterotrema caballeroi*, which almost certainly predisposed the animal to secondary bacterial infection and death.^{35,63,64} Lungworm infection is common in wild (stranded) and recently captured cetaceans, and parasite migration through the lungs is also apparently a predisposing factor to bacterial pneumonia.^{19,25,27,31,33–35,38} In no instances in *I. geof-*

frensis were viral inclusions noted in pulmonary cells, and these pneumonias generally appeared to be of bacterial origin. Five cases had pulmonary abscesses. Aspiration of bacteria-contaminated water, especially during transport or in cases where holding-tank water contained excessive bacterial loads, may have contributed to this high incidence of pneumonia. These animals were transported most commonly from South America in the 1960s via foam-lined, water-containing boxes in unheated, World War II surplus aircraft. Therefore, they were subjected to some degree of cold stress in flight, and early transporters of river dolphins reported that they became agitated, probably as a result of

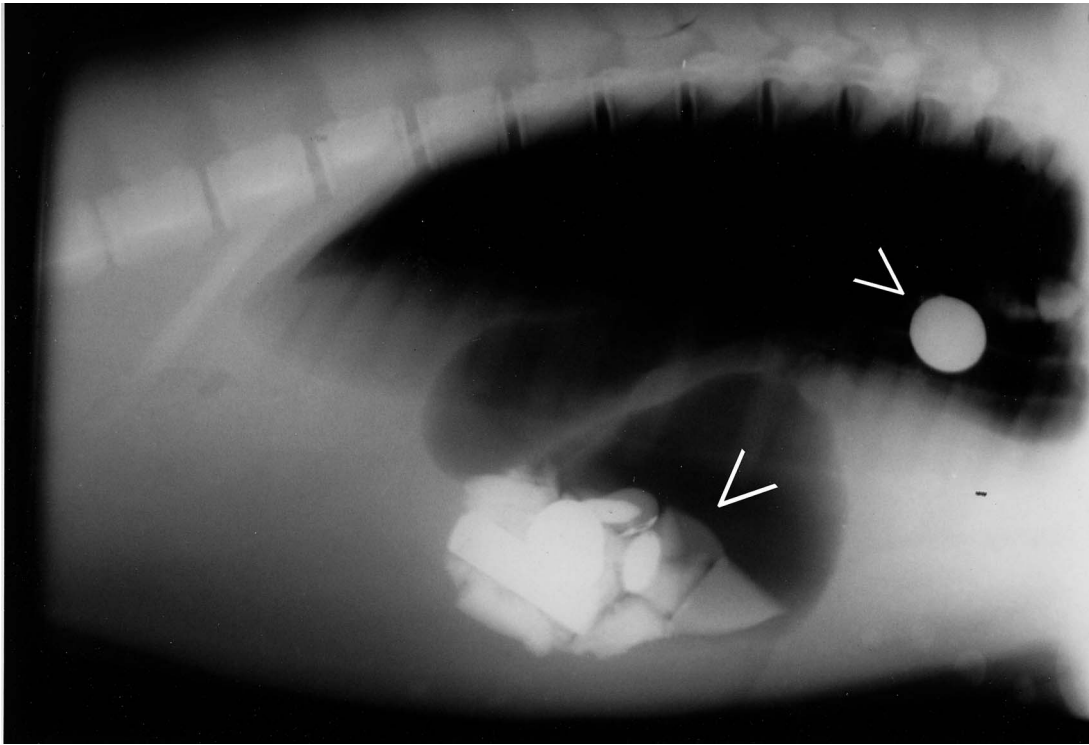


Figure 3. Lateral radiograph of an immature male *Inia geoffrensis* with metallic gastric and esophageal foreign bodies, noted by arrowheads. These foreign bodies were successfully removed manually. Photograph by the author (EOB).

low air pressure in the cabin at higher altitudes.^{33,58} This temperature stress, combined with parasitism and exposure to contaminated water, probably contributed significantly to posttransport mortality. Since that time, significant improvements in marine mammal transport have been made, including transportation of animals in slings, maintenance of normal environmental temperature and water quality, and monitoring of the animals' vital signs.^{2,14,62} One of the last air transports in the 1970s of *I. geoffrensis* had no mortalities using modern slings to support the animals.²³ It is interesting to note that the most significant finding in three cases that died after more than 15 yr in captivity was pneumonia, with no premonitory pulmonary signs. Radiography may be a useful method of diagnosing asymptomatic pneumonia in ailing Amazon River dolphins (Fig. 9).

Systemic pathology: Bacterial septicemia was diagnosed histologically in 16 of 69 (23%) cases and was suspected on gross findings in four additional cases. In eight instances, the animal also had "golf ball disease," the syndrome of spontaneously appearing subcutaneous abscesses that rupture, drain, and sometimes become confluent ulcerations. Ce-

taceans are unusually prone to bacterial septicemia and may become septic and die within a few hours, showing few clinical signs.^{19,36} In seven of these eight cases, culture results were available. In two cases of chronic golf ball disease, cultures of *Streptococcus* and *Proteus* were grown from blood cultures obtained antemortem using aseptic technique, as well as from the skin lesions. In two additional cases, *Erysipelothrix rhusiopathiae*, *Pseudomonas*, and *Streptococcus* were obtained from skin lesions, liver, and spleen at necropsy. In one case of chronic skin abscesses, *Salmonella infantis* was isolated from both the skin lesions as well as all internal organs; in another case, *Salmonella oranienburg* and *Streptococcus* were isolated from skin lesions as well as the bone marrow and small bowel. Finally, in one additional case, *Clostridium* and *E. coli* were isolated from the skin lesions, and *Clostridium*, *E. coli*, and *Streptococcus* were isolated from the blood also. In cases with concomitant skin disease, it therefore seems possible that some cases of septicemia were caused by systemic spread of bacteria from chronically infected skin.

The number of septicemia diagnoses likely underestimates its true prevalence, because some

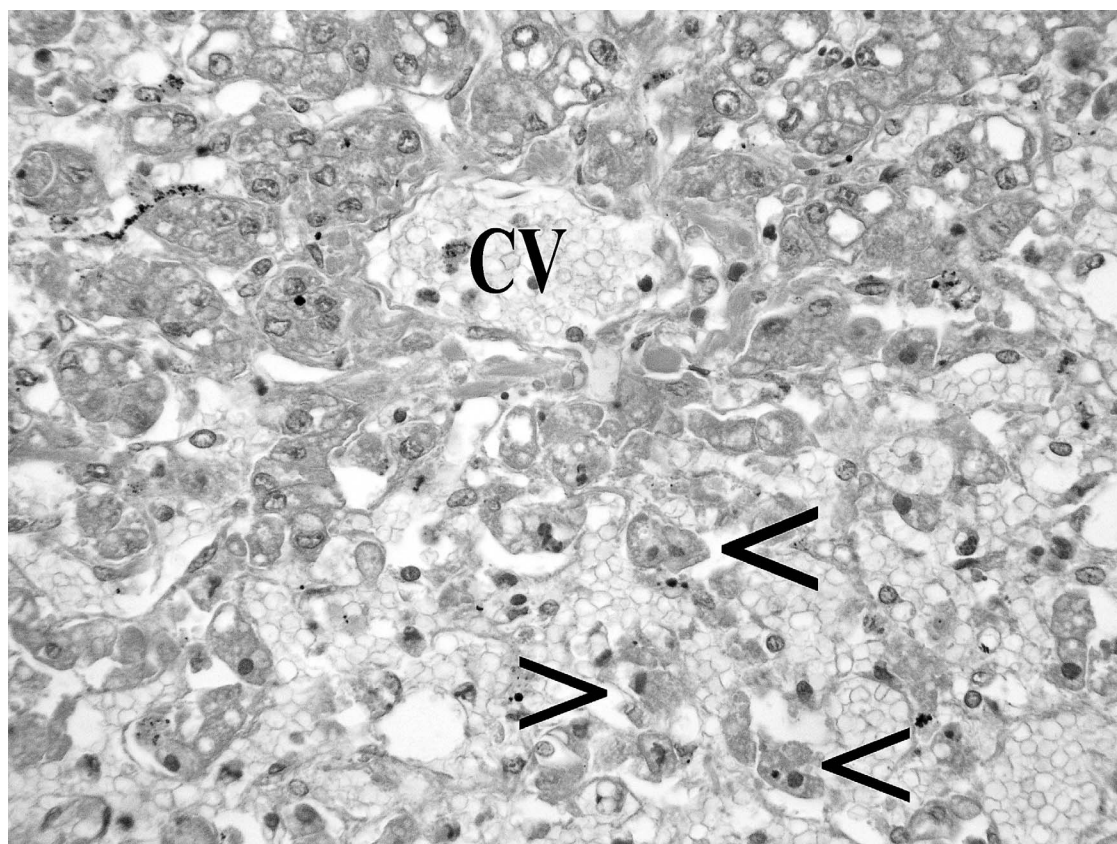


Figure 4. Photomicrograph of a liver from an adult *Inia geoffrensis* with hepatocellular necrosis. Necrotic hepatocytes are indicated with arrows in an area of congestion. CV = central vein. H&E, $\times 100$. Photomicrograph by the author (MMG), courtesy of Northwest Zoopath, Monroe, Washington, USA.

gross necropsies without supporting histology or bacteriology probably missed some cases of septicemia. Some of the animals not necropsied also may have been afflicted with septicemia. Three additional animals may have been septic, because their gross findings (one with gastric perforation by foreign body and two with perforated gastric ulcers) were so severe as to predispose them to sepsis. Two additional individuals suspected of being septic on the basis of culture (based on isolation of beta-hemolytic *Streptococci* from repeated blood cultures antemortem) did not have histologic confirmation of gross findings.

Trauma was listed as either a cause of or a contributing factor to death in 14 of 123 cases (11%). Several of these cases were not necropsied, presumably because the cause of death was apparent. Most were instances of males attacking males, although some cases were males attacking females. In two cases, although the cause of death was listed as bronchopneumonia, the pathologist later noted that

numerous rake marks and contusions were found on the animals, especially around the genital area,⁴⁹ indicating that aggression, particularly sexual aggression, may have played a role in the animals' morbidity and mortality. There were no recorded instances of females attacking other adult females, although clumsy attempts by primiparous dams to assist their neonates to the surface to breathe may have contributed to at least two mortalities in infants.³² A third neonatal mortality involving aggression from the inexperienced dam toward the infant was witnessed by one author (EOB).

Dermatopathology: The chronic, suppurative dermatitis known to aquarists as golf ball disease, a dermatologic syndrome in which subcutaneous abscesses arise, grow to approximately 2–5 cm in diameter, and rupture, has been encountered in 20 of 22 institutions known to have housed *Inia* for a significant period of time. In three cases, a specific species of bacteria (*Streptococcus iniae*) was isolated.^{7,42,43} Although Koch's postulates have not

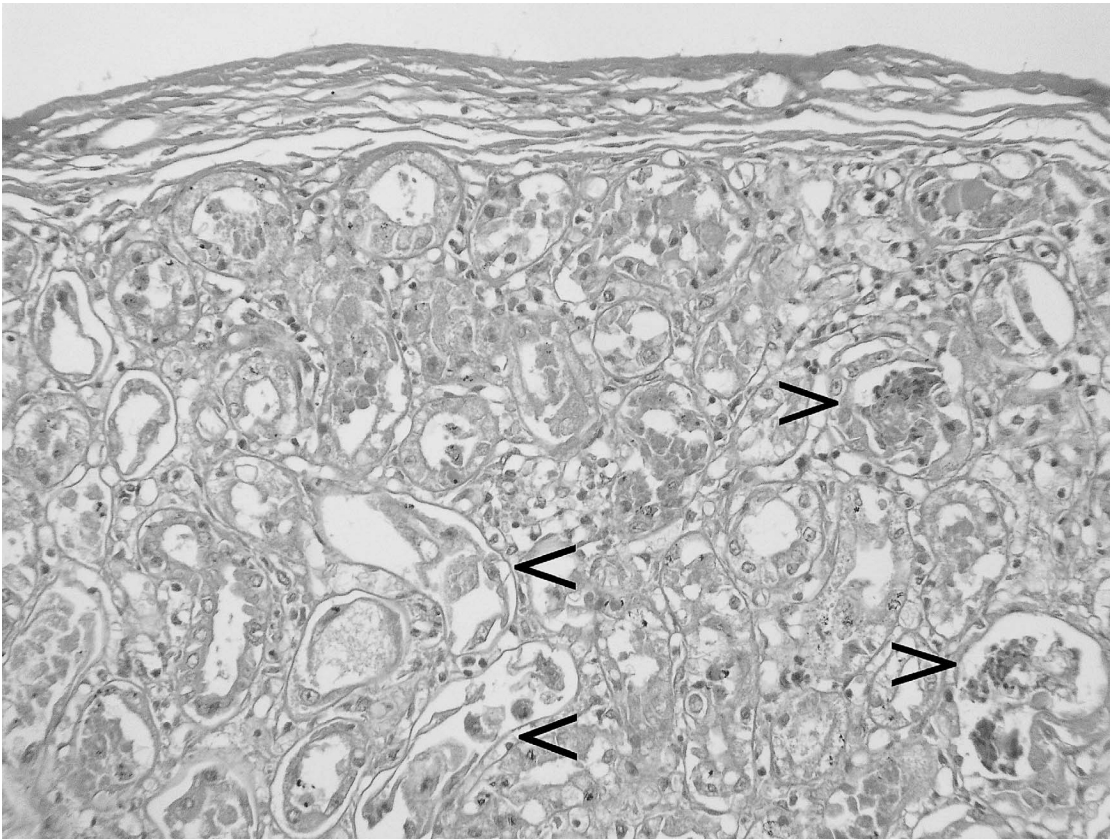


Figure 5. Photomicrograph of a kidney from an adult *Inia geoffrensis* with tubulonephritis. Examples of tubular necrosis are noted with arrowheads. Renal disease is often found in captive *Inia*, although the cause remains obscure. H&E, $\times 100$. Photomicrograph by the author (MMG), courtesy of Northwest Zoopath, Monroe, Washington, USA.

been fulfilled for this organism, three case reports indicate that this agent is often the responsible organism,^{7,42,43} and one study of normal skin flora of *Inia* did not demonstrate it.⁵⁹ In humans exposed to infected freshwater fish, *S. iniae* has been shown to produce localized skin infection, cellulitis, and in some cases, bacteremia that spread to distant organs.⁶¹ It is therefore likely that many of these cases were indeed instances of epidermal infection with *S. iniae* with subsequent septicemia. However, it is also possible that this disorder represents a syndrome with multiple etiologies and that other bacteria could cause virtually identical signs and pathology. In one retrospective examination of culture results from 15 *Inia* with subcutaneous abscesses (golf ball disease) the most common isolate was *Streptococcus* (11/15) followed by *E. coli* (9/15) and *Pseudomonas* (6/15).⁷ Other studies have found the highest incidence of beta-hemolytic *Streptococcus* isolated from abscesses in other cetaceans, and *Pseudomonas aeruginosa* sp. the second most com-

mon isolate.^{17,31,36,38} A higher proportion (10/38 [26%] gross diagnoses and 8/22 [36%] histologic diagnoses) of the animals with subcutaneous abscesses were septicemic than were septicemic in the overall population (20/105 [19%] gross diagnoses and 16/70 [23%] histologic diagnoses). It is probable that some of the cases of peracute death with no gross lesions other than dermatitis were cases of bacterial sepsis subsequent to chronic skin infection. In two cases (and probably a third with identical lesions from the same tank), *Erysipelothrix rhusiopathiae* was isolated from the golf ball disease-like skin lesions in addition to *Streptococcus*, *E. coli*, and *Pseudomonas*. *Erysipelas* is a common cause of bacterial skin disease, septicemia, and death in other cetaceans,^{12,17,31,36,55} although these two isolates are the only ones in our survey of *Inia*.

One animal with histological confirmation of dermatitis was listed as “suspected” of harboring a fungal infection, but fungal organism morphology was not described. One animal that was not nec-

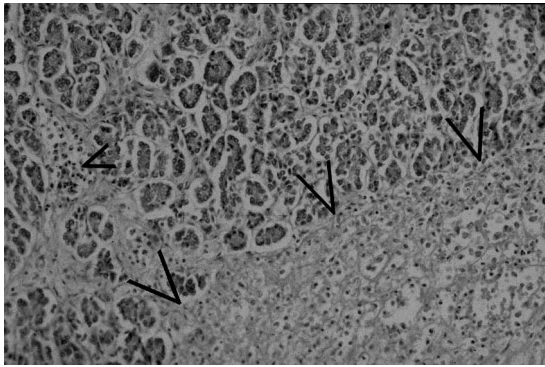


Figure 6. Photomicrograph of a pancreas from an *Inia geoffrensis* that died from acute pancreatitis. An area of acute cellular necrosis is indicated by the large arrowheads. The small arrowhead indicates an aggregation of degenerated inflammatory cells. H&E, $\times 100$. Photomicrograph courtesy of Dr. F. Yvonne Schulman and Dr. Tom Lipscomb, Armed Forces Institute of Pathology, Bethesda, Maryland, USA.

ropsied was noted in its clinical record as having an “overall fungal infection” of the skin, but histologic confirmation of this is lacking. This may have represented colonization of exposed, ulcerated skin by saprophytic organisms such as *Saprolegnia* sp., which would have been visible to the keepers. Although dermatopathology was reported at all

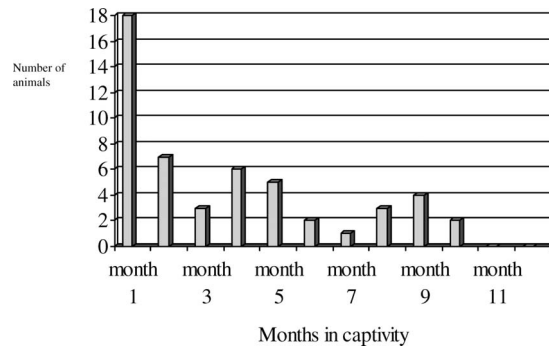


Figure 8. Survival time of 52 wild-born *Inia geoffrensis* dying during the first year of captivity in 20 different institutions in the United States, Venezuela, Germany, and Japan from 1956–2006.

but three institutions known to house *Inia*, it is interesting that one institution without a history of dermatological problems is the Valencia Aquarium in Venezuela. Besides housing the animals in a much larger tank than most institutions, its staff also feed a much greater variety of fish (52 species of local, freshwater fish).⁵ A nutritional component to dermatologic problems may exist, because one other case of golf ball disease resolved with concurrent antibiotic and nutritional therapy.⁷

Gastrointestinal pathology: First, as in other

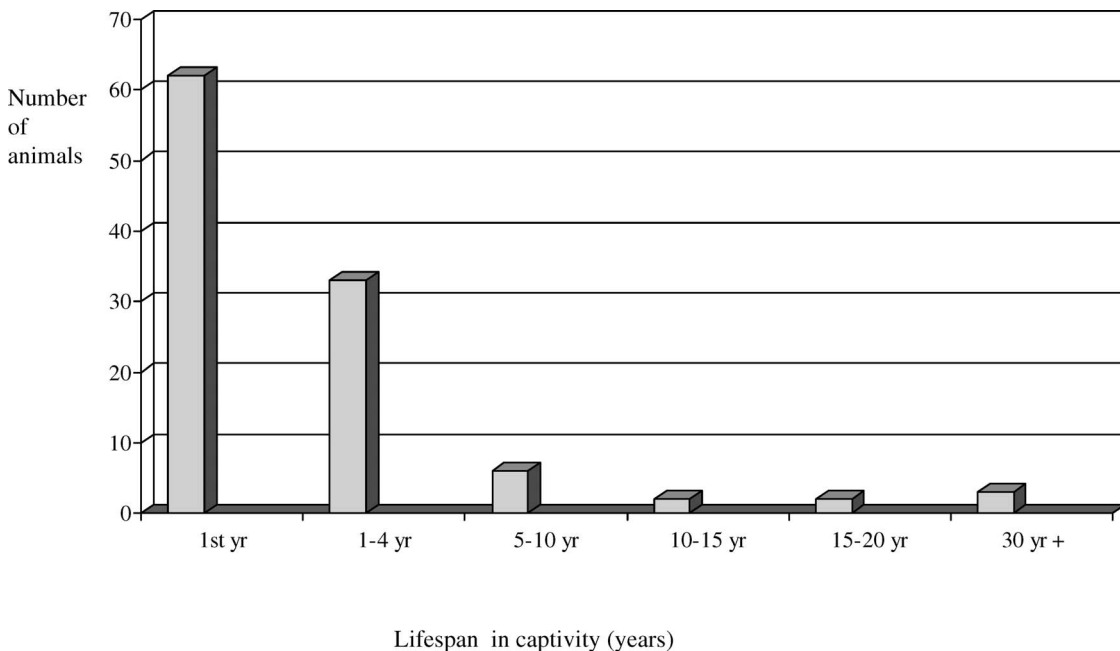


Figure 7. Captive survival time of 97 wild-born *Inia geoffrensis* maintained in 20 different institutions in the United States, Venezuela, Germany, and Japan from 1956–2006.

Table 3. Pool size for 13 *Inia* exhibits in North America, Venezuela, Germany, and Japan from 1956–2006.

Institution	Depth (m)	Surface area (m ²)	Average no. animals	Maximum no. animals	Average longevity (yr)	Max longevity (yr)	Surface area/average no. animals (m ²)	Volume (m ³)	Volume/average no. animals
A	2.000	90.0	4.24	11	1.10	8.40	21.20	180.0	42.45
B	1.500	27.0	1.00	1	16.20	16.20	18.00	40.5	40.50
C	1.800	19.5	1.00	2	19.80	19.80	19.50	35.1	35.10
D	3.200	111.5	1.50	2	3.10	10.30	74.30	356.8	237.90
E	1.178	278.0	1.50	3	1.00	1.00	139.00	139.0	92.70
F	3.300	65.6	4.60	6	3.30	3.00	14.20	216.5	47.00
G	1.200	18.5	1.00	1	27.00	27.00	18.50	22.2	22.20
H	1.200	26.4	1.30	3	3.32	1.00	20.30	31.6	24.30
I	2.100	47.5	2.00	2	7.74	9.00	23.75	99.75	45.40
J	1.800	75.0	2.20	5	28.00	12.30	36.40	135.0	61.36
K	1.900	40.0	1.10	2	9.20	16.27	20.00	76.0	69.00
L	2.300	234.0	4.00	5	4.90	16.00	58.50	538.2	134.50
M	2.100	76.0	4.20	14	0.80	3.40	18.10	159.6	38.00

captive marine animals, occasional foreign-body ingestion has been fatal in *I. geoffrensis*. For the last 18 yr, the Valencia Aquarium in Venezuela has prevented such mortality by performing annual radiographic examination and gastric lavage on their captive *Inia*.⁵ Second, gastric ulceration was also prevalent. Gastric ulceration has been reported in free-living marine mammals.^{48,51} Gastric ulceration has been attributed to gastric parasitism,^{12,55} gastric spiral bacteria,²⁸ and dietary histamine from mildly decomposed food fish.²⁰ In practice, probably all

three etiologies played some role in the pathogenesis of different cases of gastric ulceration in this species. However, because *Helicobacter*-associated gastritis had not been described at the time most of these histologic examinations were made, involvement of gastric spiral bacteria may have been missed. In only one case were histologic sections of a pyloric ulcer available for recent examination, and *Helicobacter* were not observed. In one specimen, histologic evaluation of gastric ulceration revealed invasion of the gastric mucosa by *Candida*.

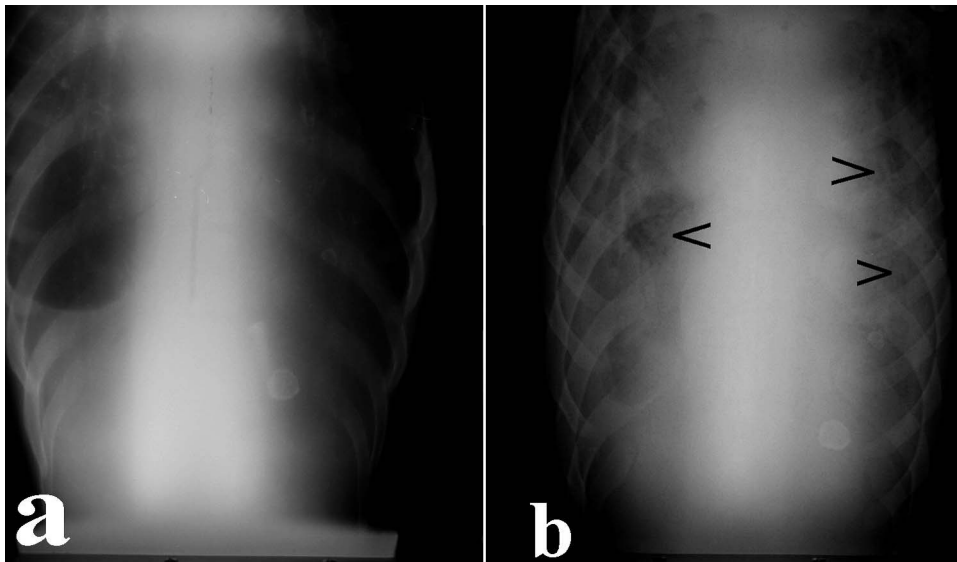


Figure 9. Dorsoventral thoracic radiographs of a male *Inia geoffrensis*. **a.** Animal with no clinical signs of pneumonia. **b.** Thoracic radiograph of the same specimen 14 yr later at death from suppurative bronchopneumonia. Note loss of distinct cardiac silhouette, generalized opacity of lung fields, and air bronchograms (arrowheads). Radiographs courtesy of the Pittsburgh Zoo and PPG Aquarium, Pittsburgh, Pennsylvania, USA.

Candida has been a significant cause of morbidity and mortality in other species of captive cetaceans.^{18,41,46,54}

Hepatic pathology: Hepatitis and cholangitis were the most common hepatic pathologies noted. Hepatic disease had been reported in other cetaceans, often associated with parasitism.^{8,12,25–27,39} Migrating trematodes may have contributed to the cases of cholangitis and bile duct hyperplasia, although parasites were not observed in the liver sections examined. However, some of these cases were also cases of septicemia, which may have contributed to the hepatic pathology. One interesting case involved obstruction of the common bile duct by a cholelith, which must be uncommon, because like other cetaceans, *I. geoffrensis* lacks a gall bladder. Hepatic abscesses were found in two cases, one of which was caused by perforation of the stomach wall and the liver by a gastric foreign body (a wire). Based on histologic examination, one animal was believed to have hepatotoxicity from a very prolonged course of tetracycline therapy for chronic skin abscesses, although no ancillary toxicologic studies were done to confirm or to refute this finding. Viral inclusions were not seen in *Inia*, and the exact etiology of most cases of hepatic pathology is obscure.

Renal pathology: As in one previous study,¹⁰ a higher-than-expected incidence of renal disease was found: 15 of 70 histologic diagnoses (21%). Some of these cases may have been secondary to bacteremia/bacterial septicemia, because bacterial toxins may account for the cases of toxic tubular necrosis, and perhaps glomerulonephropathy, in animals with severe infections in other organs. One histologically examined neonate that died of septicemia had intratubular hemorrhagic foci and degeneration of tubular epithelium with microfoci of necrosis. In one other case, bacterial pyelonephritis was seen histologically, which would account for the nephropathy. In one neonate, perirenal fibrosis was noted with the presence of dematiaceous fungal organisms (chromoblastomycosis). Interestingly, *Podocnemis* sp. turtles were kept in this animal's tank and may have served as a possible source of the infection. Glomerulonephritis was found occasionally; in the literature, localized glomerulonephritis also has been reported in one wild-caught individual (not part of this case series), the cause of which was not determined.⁴⁴

Neonatal pathology: Three neonates that were not necropsied died, apparently of cachexia, because their lactating dams died and attempts at hand raising and/or tube feeding the animals were unsuccessful. One additional neonate died, also ap-

parently of cachexia, because its mother was a poor milk producer. One neonate for which only gross necropsy was performed died subsequent to maternal aggression shortly after birth. One calf of a few months of age was successfully hand-reared.²³

Miscellaneous findings

Three females for which necropsies were unavailable were attacked by males and subsequently died. One animal died of internal hemorrhages; warfarin toxicity was suspected and was confirmed by the Liebermann reaction. In this case, secondary poisoning from eating a poisoned rodent that probably fell into the tank was suspected.⁵ One animal died with 3 mg/kg arsenic in its tissues, although tank water, paint, sealant, and food fish were tested and were found to be negative. The source of the arsenic was not identified. No gross lesions were observed in this case, but bacterial septicemia cannot be ruled out and is indeed likely because *E. coli* and a hemolytic *Streptococcus* were isolated from the spleen. The animal's tank mates did not develop any signs of toxicity.

Environmental correlates with pathological findings

It has been postulated that aggression, especially from male *I. geoffrensis*, contributed to the high level of stress-related illness and bacterial skin infections among captive *I. geoffrensis*.^{5,10} It should be noted that when most of these animals were imported, their behavioral and environmental needs were not known. The curators and aquarists who maintained these animals were pioneers, studying an unusual species in captivity for the first time. At that time, even husbandry requirements for the much more extensively studied *Tursiops* sp. were just being developed. The *I. geoffrensis* often were kept under conditions that, by today's standards, would seem crowded or at least significantly undersized. However, at that time, it was not known that most *I. geoffrensis* in nature are sighted under solitary conditions and that males in captivity can be quite aggressive toward each other. For example, 51–81% of sightings in nature are reported to be of solitary animals.³

Pool surface area per animal ranged from 13.25–139 m² and volume ranged from 13–327 m³. There is no statistically significant correlation between surface area per animal and longevity ($P > 0.05$), especially since the largest figure (139 m² per individual) had one of the lowest average life spans (1.0 yr). The poorest average survival was in one of the three smallest tanks, and the statistically significant correlation between survival and number of

animals per unit volume of water is not unexpected. Not only would higher population density contribute to increased aggression and injuries, but it also would increase organic waste load, placing a higher demand on the life support system, leading to higher bacteria counts in the water. The combination of behavioral stress, aggression-induced injuries, and higher bacteria counts in the environment could be expected to increase the rate of bacterial infections in crowded populations. As one previous survey pointed out,¹⁰ because most of the animals living longer than 5 yr were single males, the data support the notion that aggression between individuals, especially males, may have contributed to the overall low life span of this species in captivity. Of the nine animals that lived more than 10 yr in captivity, five were males who lived the majority of their lives alone. Exceptions to this are the two males who lived together for more than 30 yr at Duisburg Zoo, Germany, and one male and three females that continue to live together in a breeding colony after 18 yr at Valencia Aquarium, Venezuela.⁵

At Duisburg Zoo, five dolphins (three males and two females) were imported in 1975; one of the two long-term surviving males arrived as fully adult, whereas the other one was estimated to be only a few months old at the time and still fully dependent on his mother. This animal's mother died in 1976, and it was then hand-reared until weaned. Between 1976 and the end of 1978, the three males lived together without any females. The third male died on 31 December 1978, estimated to be 5 yr old; before his death, some aggression with the oldest male was reported,⁵⁶ but most aggressive behaviors were noted between this individual and the youngest one.⁵³ After 1978, several ethograms of the two remaining males confirmed that overall aggressive behavior was rare and often was ritualized.^{23,30,40,53} Aggressive behavior included open mouth, jaw claps, and inflicting rake marks (superficial, linear skin abrasions inflicted by the teeth of tank mates), mainly on the younger individual. It is interpreted that the clear dominance of the larger and stronger older male was one of the keys to the social life of these two adult males, which cohabited for 30 yr (MGH).

The recommendation that pool size be large enough to allow for normal spacing among individuals and that facilities allow for separation of aggressive animals,¹⁰ especially males, would therefore seem prudent. The hematological response of cetaceans to corticosteroids is similar to that of other mammals, indicating that chronic stress and subsequently elevated cortisol levels may cause immune suppression.^{21,37,45,52} Therefore, as with most

other animal species, crowding and maintaining inappropriate sex ratios and social groups apparently can predispose an animal to disease through physical trauma from fighting and the physiological results of chronic behavioral stress. Indeed, the success of the breeding group at the Valencia Aquarium in Venezuela is understandable, because the group consists of one adult male, two adult females, and one subadult female, all maintained in one of the largest pools ever devoted to this species.⁵

There has been persistent concern among aquarists that *I. geoffrensis* needs a shallow tank, because they sleep on the bottom; traveling a long distance to the surface to breathe would interrupt their sleep and would cause behavioral stress. Some aquarists, therefore, attributed the poor longevity of *I. geoffrensis* to being kept in deeper tanks.²⁴ Table 3 presents tank size and longevity data for 13 institutions that housed *I. geoffrensis* and for which tank size data are available. There is no distinct correlation between longevity and pool depth. The great majority of *I. geoffrensis* were kept in exhibits approximately 1.5 m deep, so it is difficult to evaluate the effect of depth, if any, on longevity. However, one of the deeper pools (3.2 m) had one animal that lived more than 10 yr, and another deep pool (3.3 m) had an average longevity of 3.3 yr. Only two institutions had tanks with greater depth than 3 m. One of these institutions had a maximum longevity of a male *I. geoffrensis* of 10.3 yr, one of the longer maximum life spans found in this survey. The other institution maintained an animal for 2 yr in a tank that was 3 m (11 ft) deep before being transferred to another, shallower tank. This individual lived for approximately 30 yr thereafter. Therefore, we cannot conclude from the available data that animals in shallow tanks lived longer than those in deep tanks.

Microbiological water quality appears to have been an important issue in the health of these animals. When most of these animals were kept in captivity, routine bacterial cultures of tank water neither were required by law nor were common practice. However, in cases where culture results are available, results ranged from 250,000 CFU (colony forming units)/L to "too numerous to count," in excess of the present zoological facility standards (10,000 CFU/L). Prevailing theory at that time was that the large amount of waste created by cetaceans required bacteriological filtration, and often the animals were maintained in systems with bacteria-laden sand and gravel filters rather than in more hygienic, chlorinated systems.^{11,15,60} Additionally, although in some cases chlorination was available, the level of free chlorine was kept at 0.5 ppm

or less, because *Inia* seem to have dermatologic problems with higher levels of chlorine.^{5,22,23,34,41} Ozone had not yet come into use for disinfection of marine mammal pool water. Two reports indicate a significant improvement in water quality after addition of ultraviolet sterilization.^{22,29} Such was not the norm, however, and review of the records indicates that most of these animals probably lived in water that was not up to today's microbiological standards for water quality. High levels of bacteria in tank water may have contributed to the high incidence of bacterial dermatitis, bacterial pneumonia, and subsequent septicemia.

CONCLUSIONS

The history of *Inia* clearly shows that they can be successfully maintained in captivity for decades, and that conception, birth, and rearing of offspring under human care is possible. However, examination of mortality statistics indicates that prophylactic anthelmintic treatment, specifically for trematodes, as well as broad-spectrum antimicrobial therapy, is appropriate for newly captured or translocated animals before, during, and immediately after transport. Transport in appropriately constructed slings, under sanitary conditions, and with good temperature control (water and air temperature between 25°C and 29°C) would be prudent to prevent posttransport morbidity and mortality due to pneumonia. Maintenance of microbiologically clean water, through the use of ozone or ultraviolet sterilization, is warranted. Separating aggressive males, keeping animals in appropriate social groups, and providing animals with a large volume of water and surface area could significantly reduce aggression, stress, and trauma-related illness. Finally, because *Inia* have a history of bacterial disease and sudden deaths with few or no premonitory signs, a vigorous preventive medicine program involving routine complete blood cell counts and chemistry profiles, as well as monitoring inflammation markers like sedimentation rates and fibrinogen assays, blowhole cultures, and radiography, would significantly increase the probability of detecting medical problems while the animals were still responsive to treatment. Using these techniques, aquarists may maintain this species over several decades and as successfully as other cetaceans, such as the bottlenose dolphin (*Tursiops truncatus*), the orca (*Orca orca*), and the Beluga (*Delphinapterus leucas*), are maintained in aquaria today.

Acknowledgments: The authors gratefully acknowledge the support and generosity of the following individuals and institutions who have

worked hard to help provide information for our study: Antonio Amortegui, M.D., and Adele Millard, Magee-Womens Hospital; Roger Klocek, John G. Shedd Aquarium; Tom Tucker and Pat Morales, Steinhart Aquarium; Tim Reichard, D.V.M., and Wynona Shellabarger, D.V.M., Toledo Zoo; Bill Upson and Kevin Roberts, Marineland of Florida; Nancy Lung, D.V.M., and Annabel Ross, Fort Worth Zoo; Bess Frank, Karin Schwartz, and Jennifer Kinnamon, Milwaukee County Zoo; Gordon Hubbell, D.V.M., and Chris Miller, D.V.M., Miami MetroZoo; and Brad Andrews, Mike Scarpuzzi, Tom Goff, and Judy St. Leger, D.V.M., Dipl. A.C.V.P., SeaWorld, Inc. Expert histologic reviews of five sets of tissues were generously provided by Gregory Bossart, D.V.M., Ph.D., Dipl. A.C.V.P., Harbor Branch Oceanographic Institute; F. Yvonne Schulman, D.V.M., Dipl. A.C.V.P., and Thomas Lipscomb, D.V.M., Dipl. A.C.V.P., Armed Forces Institute of Pathology.

LITERATURE CITED

1. Amsel, S. 1986. Diagnosis and treatment of pneumonia in an Amazon River dolphin (*Inia geoffrensis*) in a wild-captive environment: a case report. *Proc. Am. Assoc. Zoo Vet. Annu. Meet.* 1986: 110–111.
2. Antrim, J., and J. McBain. 2001. Marine mammal transport. *In: Dierauf, L. A., and F. M. D. Gulland (eds.). Handbook of Marine Mammal Medicine*, 2nd ed. CRC Press, Boca Raton, Florida. Pp. 881–891.
3. Best, R. C., and V. M. F. da Silva. 1993. *Inia geoffrensis*. *Mamm. Species* 426: 1–8.
4. Boede, E. O. 2005. Importancia de recopilar datos reproductivos en toninas del Orinoco (*Inia geoffrensis humboldtiana*) mantenidas en zoológicos y acuarios. *Natura* 127: 32–36.
5. Boede, E. O., E. Mujica-Jorquera, and N. de Boede. 1998. Management of the Amazon River dolphin *Inia geoffrensis* at Valencia Aquarium in Venezuela. *Int. Zoo Yearb.* 36: 214–222.
6. Bonar, C. J., and J. Lowenstein-Whaley. 2001. A review of the history and medical problems of river dolphins in captivity. *Proc. Bienn. Conf. Biol. Mar. Mamm.* 14: 29. (Abstr.)
7. Bonar, C. J., and R. A. Wagner. 2003. A third report of “golf ball disease” in an Amazon River dolphin associated with *Streptococcus iniae*. *J. Am. Assoc. Zoo Vets.* 34: 296–301.
8. Brown, D. H., R. W. McIntyre, C. A. Delli Quadri, and R. J. Schroeder. 1960. Health problems of captive dolphins and seals. *J. Am. Vet. Med. Assoc.* 137: 534–538.
9. Caldwell, M. C., and D. K. Caldwell. 1972. The little ugly dolphin. *Sea Frontiers* 18(1): 24–29.
10. Caldwell, M. C., D. K. Caldwell, and R. Brill. 1986. *Inia geoffrensis* in captivity in the United States. *In: Perrin, W. F., Z. Kaiya, and L. Jiankang. Biology and Conservation of River Dolphins.* IUCN Species Survival

- Commission Occas. Pap. 3, Gland, Switzerland. Pp. 35–41.
11. Coates, C. W. 1962. Walruses and whales at New York Aquarium. *Int. Zoo Yearb.* 4: 10–12.
 12. Cordes, D. O., and P. J. O'Hara. 1979. Diseases of captive marine mammals. *N Z Vet. J.* 27: 147–150.
 13. Cornell, L. H., and B. E. Joseph. 1986. Marine mammal transport. *Proc. Am. Assoc. Zoo Vet. Annu. Meet.* 1986: 50.
 14. Cornell, L. H., and B. E. Joseph. 1986. Water quality maintenance within a marine zoological park. *Proc. Am. Assoc. Zoo Vet. Annu. Meet.* 1986: 48–49.
 15. Curtis, L. 1962. Amazon dolphin *Inia geoffrensis* at the Fort Worth Zoological Park. *Int. Zoo Yearb.* 4: 7–10.
 16. Diamond, S. S., D. E. Ewing, and G. A. Caldwell. 1979. Fatal bronchopneumonia and dermatitis caused by *Pseudomonas aeruginosa* in an Atlantic bottle-nosed dolphin. *J. Am. Vet. Med. Assoc.* 175: 984–987.
 17. Dunn, J. L., and J. D. Buck. 2001. Bacterial disease. In: Dierauf, L. A., and F. M. D. Gulland (eds.). *CRC Handbook of Marine Mammal Medicine*, 2nd ed. CRC Press, Boca Raton, Florida. Pp. 302–336.
 18. Dunn, J. L., J. D. Buck, and S. Spotte. 1982. Candidiasis in captive cetaceans. *J. Am. Vet. Med. Assoc.* 181: 1316–1321.
 19. García Hartmann, M. 1997. Pathology of marine mammals. In: Jauniaux, T., J.-M. Bouquegneau, and F. Coignoul (eds.). *Marine Mammals, Seabirds, and Pollution of Marine Systems*. Presse de la Faculté de Médecine vétérinaire de l'Université de Liège, Liège, Belgium. Pp. 117–149.
 20. Geraci, J. R., and K. E. Gerstmann. 1966. Relationship of dietary histamine to gastric ulcers in the dolphin. *J. Am. Vet. Med. Assoc.* 149: 884–890.
 21. Geraci, J. R., and W. Medway. 1973. Simulated field blood studies in the bottle-nosed dolphin *Tursiops truncatus*. *J. Wildl. Dis.* 9: 29–33.
 22. Gewalt, W. 1977. Ultraviolet sterilization of water in a pool for toninia (*Inia geoffrensis*). A preliminary report. *Aquat. Mamm.* 5(3): 69–71.
 23. Gewalt, W. 1978. Unsere Tonina (*Inia geoffrensis* Blainville 1817) Expedition 1975. *Zool. Garten N. F. Jena.* 48: 323–384.
 24. Goodlett, R. O. 1988. Basic husbandry requirements for *Inia geoffrensis* including spatial needs. *Proc. Int. Marine Anim. Train. Assoc.* 1988: 82–92.
 25. Greenwood, A. G., and D. C. Taylor. 1979. Clinical and pathological findings in dolphins in 1978. *Aquat. Mamm.* 7(3): 71–74.
 26. Greenwood, A. G., and D. C. Taylor. 1978. Clinical and pathological findings in dolphins in 1977. *Aquat. Mamm.* 6(2): 33–38.
 27. Griner, L. A. 1983. *Pathology of Zoo Animals*. Zoological Society of San Diego, San Diego, California. Pp. 471–472, 1321.
 28. Harper, C. G., Y. Feng, S. Xu, N. S. Taylor, M. Kinsel, F. E. Dewhurst, B. J. Paster, M. Greenwell, G. Levine, A. Rogers, and J. G. Fox. 2002. *Helicobacter cetorum* sp. nov., a urease-positive *Helicobacter* species isolated from dolphins and whales. *J. Clin. Microbiol.* 40: 4536–4543.
 29. Herald, E. S., R. P. Dempster, and M. Hunt. 1970. Ultraviolet sterilization of aquarium water. *Drum Croaker Spec. Ed.* 57–71.
 30. Herling, A. 1993. *Verhaltensstudien an Zoo-Delphinen: Aktivitätsmöglichkeiten und Ruheverhalten. Schriftliche Hausarbeit im Rahmen der ersten Staatsprüfung für das Lehramt für Primarstufe*. Universität Dortmund, Fachbereich 12/Biologie, Dortmund, Germany. Pp. 1–93.
 31. Howard, E. B., J. O. Britt, G. K. Madsumoto, R. Itahara, and C. N. Nagano. 1983. Bacterial diseases. In: Howard, E. B. (ed.). *Pathobiology of Marine Mammal Diseases*. CRC Press, Boca Raton, Florida. Pp. 69–118.
 32. Huffman, W. E. 1970. Notes on the first captive conception and live birth of an Amazon dolphin in North America. *Underwater Nat.* 6(3): 9–11.
 33. Layne, J. N., and D. K. Caldwell. 1964. Behavior of the Amazon dolphin, *Inia geoffrensis* (Blainville), in captivity. *Zoologica* 49(5): 81–111.
 34. Marks, S. K. 1992. Diseases of the Amazon River dolphin (*Inia geoffrensis*). *Proc. Joint Conf. AAZV/AAWV 1992*: 61–63.
 35. McIntosh, A. 1960. A new campulid trematode, *Hunterotrema caballeroi*, n.g. n.sp. from an Amazon dolphin, *Inia geoffrensis*. *Sobretiro del libro Homenaje al Doctor Eduardo Caballero y Caballero*, Instituto Politecnico Nacional, Mexico, D.F., Mexico. Pp. 207–208.
 36. Medway, W. 1980. Some bacterial and mycotic diseases of marine mammals. *J. Am. Vet. Med. Assoc.* 177: 831–834.
 37. Medway, W., J. R. Geraci, and L.V. Klein. 1970. Hematologic response to administration of a corticosteroid in the bottle-nosed dolphin (*Tursiops truncatus*). *J. Am. Vet. Med. Assoc.* 157: 563–565.
 38. Medway, W., and H. F. Schryver. 1973. Respiratory problems in captive small cetaceans. *J. Am. Vet. Med. Assoc.* 163: 571–573.
 39. Medway, W., H. F. Schryver, and B. Bell. 1966. Clinical jaundice in a dolphin. *J. Am. Vet. Med. Assoc.* 149: 891–895.
 40. Moreno, M. P. T. 1996. *Estudo preliminar do comportamento de Inia geoffrensis em cativo e caracterizacao de sinais acusticos emitidos em contexto sexual*. Master's Thesis, Instituto Superior de Psicologia Aplicada, Lisboa, Portugal. Pp. 1–70.
 41. Ostenrath, F. 1976. Some remarks on therapy of mycotic and bacteriological skin diseases in freshwater dolphins, *Inia geoffrensis*. *Aquat. Mamm.* 4(2): 49–51.
 42. Pier, G. B., and S. H. Madin. 1978. Isolation and characterization of a second isolate of *Streptococcus iniae*. *Int. J. Syst. Bact.* 28: 311–314.
 43. Pier, G. B., and S. H. Madin. 1976. *Streptococcus iniae* sp. nov., a beta-hemolytic *Streptococcus* isolated from an Amazon freshwater dolphin, *Inia geoffrensis*. *Int. J. Syst. Bact.* 26: 545–553.
 44. Pilleri, G., and F. Testi. 1972. Localised chronic glomerulonephritis in an Amazon dolphin, *Inia geoffrensis*. *Invest. Cetacea* 4: 101–104.

45. Reidarson, T. H., and J. McBain. 1999. Hematologic, biochemical, and endocrine effects of dexamethasone on bottlenose dolphins (*Tursiops truncatus*). *J. Zoo Wildl. Med.* 30: 310–312.
46. Reidarson, T. H., J. F. McBain, L. M. Dalton, and M. G. Rinaldi. 2002. Mycotic diseases. *In: Dierauf, L. A., and F. M. D. Gulland (eds.). CRC Handbook of Marine Mammal Medicine*, 2nd ed. CRC Press, Boca Raton, Florida. Pp. 337–355.
47. Ridgway, S. H. 1965. Medical care of marine mammals. *J. Am. Vet. Med. Assoc.* 147: 1077–1085.
48. Ridgway, S. H., and D. G. Johnston. 1965. Two interesting disease cases in wild cetaceans. *Am. J. Vet. Res.* 112: 771–775.
49. Ridgway, S. H., K. S. Norris, and L. H. Cornell. 1986. Some considerations for those wishing to propagate platanistoid dolphins. *In: Perrin, W. F., Z. Kaiya, and L. Jiankang (eds.). Biology and Conservation of the River Dolphins*. IUCN Species Survival Commission, IUCN Publications Division, Cambridge, United Kingdom. Pp. 159–167.
50. Robeck, T. R., and L. M. Dalton. 2003. *Saksenaevasiformis* and *Apophysomyces elegans* zygomycotic infections in bottlenose dolphins (*Tursiops truncatus*), a killer whale (*Orcinus orca*), and Pacific white-sided dolphins (*Lagenorhynchus obliquidens*). *J. Zoo Wildl. Med.* 33: 356–366.
51. Schroeder, J. P., and H. M. Wegeforth. 1935. The occurrence of gastric ulcers in sea mammals of the California coast, their etiology and pathology. *J. Am. Vet. Med. Assoc.* 87: 333–347.
52. St. Aubin, D. J., and L. A. Dierauf. 2001. Stress and marine mammals. *In: Dierauf, L. A., and F. M. D. Gulland (eds.). CRC Handbook of Marine Mammal Medicine*, 2nd ed. CRC Press, Boca Raton, Florida. Pp. 253–269.
53. Stachelhaus, M. 1977. Einige Anmerkungen zum Spielverhalten beim Orinoko-Flußdelfin (*Inia geoffrensis*) im Zoo Duisburg. Schriftliche Hausarbeit im Rahmen der ersten Staatsprüfung für das Lehramt der Primarstufe, Gesamthochschule Duisburg, Fachbereich 6/Biologie. Gesamthochschule, Duisburg, Duisburg, Deutschland. Pp. 1–72.
54. Sweeney, J. C., G. Migaki, P. M. Vainik, and R. H. Conklin. 1976. Systemic mycoses in marine mammals. *J. Am. Vet. Med. Assoc.* 169: 946–948.
55. Sweeney, J. C., and S. H. Ridgway. 1975. Common diseases of small cetaceans. *J. Am. Vet. Med. Assoc.* 167: 533–540.
56. Sylvestre, J. 1985. Some observations on behaviour of two Orinoco dolphins (*Inia geoffrensis humboldtiana* Pilleri and Gühr 1977) in captivity at Duisburg Zoo. *Aquat. Mamm.* 11(2): 58–65.
57. Tobayama, T., and T. Kamiya. 1986. Some data on the keeping of *Inia geoffrensis* in Kamagowa Sea World, Japan. *In: Perrin, W. F., Z. Kaiya, and L. Jiankang (eds.). Biology and Conservation of the River Dolphins*. IUCN Species Survival Commission, IUCN Publications Division, Cambridge, United Kingdom. Pp. 42–45.
58. Trebbau, P. 1975. Measurements and some observations on the freshwater dolphin, *Inia geoffrensis*, in the Apure River, Venezuela. *Zool. Garten N. F.* 45: 153–167.
59. Ushakova, N. A. 1991. A microbiological examination of the skin and vaginal fold mucous of Amazon River freshwater dolphins (*Inia geoffrensis*) in relation to an assessment of the physiological state of the animals. *Izv. Akad. Nauk. SSSR Biol.* 6: 943–949.
60. van der Toorn, J. 1987. A biological approach to dolphinarium water purification: I. theoretical aspects. *Aquat. Mamm.* 13(3): 83–92.
61. Weinstein, M. R., M. Litt, D. A. Kertesz, P. Wyper, D. Rose, M. Coulter, A. McGeer, R. Facklam, C. Ostach, B. M. Willer, A. Borczyk, and D. E. Low. 1997. Invasive infections due to a fish pathogen, *Streptococcus iniae*. *New Engl. J. Med.* 337: 589–594.
62. Wilkie, D. H., G. B. Bell, and J. S. Coles. 1966. A method of dolphin transportation and its physiologic evaluation. *Int. Zoo Yearb.* 8: 199–202.
63. Woodard, J. C., S. G. Zam, D. K. Caldwell, and M. C. Caldwell. 1969. Some parasitic diseases of dolphins. *Pathol. Vet.* 6: 257–272.
64. Zam, S. G., D. K. Caldwell, and M. C. Caldwell. 1970. Some internal parasites from freshwater cetaceans from the upper Amazon. *Invest. Cetacea* 2: 250–251.

Received for publication 13 July 2006