



LISTERIA MONOCYTOGENES INFECTION IN FREE-RANGING RED FOXES (VULPES VULPES) AND EURASIAN LYNX (LYNX LYNX) IN SWITZERLAND

Authors: Heiderich, Elisabeth, Origgi, Francesco C., Pisano, Simone R.R., Kittl, Sonja, Oevermann, Anna, et al.

Source: Journal of Zoo and Wildlife Medicine, 55(1) : 268-276

Published By: American Association of Zoo Veterinarians

URL: <https://doi.org/10.1638/2022-0144>

BioOne Complete (complete.BioOne.org) is a full-text database of 200 subscribed and open-access titles in the biological, ecological, and environmental sciences published by nonprofit societies, associations, museums, institutions, and presses.

Your use of this PDF, the BioOne Complete website, and all posted and associated content indicates your acceptance of BioOne's Terms of Use, available at www.bioone.org/terms-of-use.

Usage of BioOne Complete content is strictly limited to personal, educational, and non-commercial use. Commercial inquiries or rights and permissions requests should be directed to the individual publisher as copyright holder.

BioOne sees sustainable scholarly publishing as an inherently collaborative enterprise connecting authors, nonprofit publishers, academic institutions, research libraries, and research funders in the common goal of maximizing access to critical research.

LISTERIA MONOCYTOGENES INFECTION IN FREE-RANGING RED FOXES (*VULPES VULPES*) AND EURASIAN LYNX (*LYNX LYNX*) IN SWITZERLAND

Elisabeth Heiderich, Dr med vet, Francesco C. Origgi, PhD, DACVM, DACVP, DECZM (Herpetology), Simone R.R. Pisano, Dr med vet, DECZM (Wildlife Population Health), Sonja Kittl, PhD, DACVM, DECVM, Anna Oevermann, Dr med vet, DECVP, Marie-Pierre Ryser-Degiorgis[†], Dr med vet, DECZM (Wildlife Population Health), and Iris A. Marti, Dr med vet

Abstract: *Listeria monocytogenes* is an ubiquitous environmental saprophytic bacterium causing listeriosis in domestic animals, humans, and occasionally wildlife. In animals, this foodborne zoonotic disease mainly occurs in ruminants and it is rare in carnivores. Seven red foxes (*Vulpes vulpes*) and one Eurasian lynx (*Lynx lynx*) were diagnosed with listeriosis between 2010 and 2021 at the Institute for Fish and Wildlife Health, Bern, Switzerland. Necropsy and histopathology revealed meningitis (six of seven red foxes), hepatitis (six of seven red foxes), pneumonia (five of seven red foxes), splenitis (two of seven red foxes) and splenomegaly (the Eurasian lynx, two of seven red foxes). *Listeria monocytogenes* was isolated from either lung, spleen, liver, or kidney of all animals. Serotyping detected *L. monocytogenes* serotype 1/2a in five red foxes and the Eurasian lynx and serotype 4b in two red foxes. Six red foxes were positive for canine distemper virus (CDV) by polymerase chain reaction, whereas the Eurasian lynx and one red fox were negative. One red fox that was positive for CDV and listeriosis was also diagnosed with salmonellosis. The identified *L. monocytogenes* serotypes are among the three most frequently isolated serotypes (1/2a, 1/2b, and 4b) from food or the food production environment and those that cause most listeriosis cases in humans and animals. Coinfection with CDV in six red foxes questions the role of CDV as potential predisposing factor for septicemic listeriosis. The detection of listeriosis in the regionally endangered Eurasian lynx and in carnivores highly abundant in urban settings, such as red foxes, reinforces the importance of wildlife health surveillance in a One Health context and adds the Eurasian lynx to the list of carnivores susceptible to the disease. Further investigations are required to assess the prevalence and epidemiology of *L. monocytogenes* in free-ranging carnivores and its interaction with CDV.

INTRODUCTION

Listeria monocytogenes is a gram-positive, saprophytic, facultative intracellular and facultative anaerobe rod-shaped bacterium.^{4,8,17} It is the causative agent of listeriosis, a severe foodborne disease that can result in stillbirths, meningitis, septicemia, and death in humans. Risk groups include pregnant women, neonates, and immunocompromised individuals. Humans usually get infected through consumption of contaminated food and rarely via contact with infected animals or their feces.⁴ Case

fatality rate ranges from 20 to 30%, despite adequate antimicrobial treatment.²³ *Listeria* spp. can be found in organic matter in the soil, such as decomposing plants.⁴ The species is frequently part of the intestinal flora of clinically healthy humans (prevalence of 6–24%) and domestic and wild animals.⁸ Disease development depends on the immunocompetence of the host as well as the bacterial load and typically requires *Listeria* spp. to cross the oral or intestinal mucosae.^{8,23} Thirteen serotypes of *L. monocytogenes* have been described and are divided into four phylogenetic subdivisions (lineages I–IV),⁷ including the serotypes 1/2a, 1/2b, and 4b, each commonly reported in humans, whereas serotypes 1/2a and 4b are often detected in animals. Via gel-based multiplex polymerase chain reaction (PCR), *L. monocytogenes* serotypes are classified into four serogroups by detecting specific target genes.²⁵

In animals, the disease is mainly reported in domestic ruminants, potentially associated with poor-quality silage feeding, but it can also affect many other mammals (artiodactyls, carnivores, lagomorphs, rodents, insectivores, and primates) as well as birds.^{4,8} Disease presentation includes septicemia, encephalitis, meningitis, meningoen- cephalitis, abortion, stillbirth, and gastroenteritis.^{4,24}

From the Institute for Fish and Wildlife Health, University of Bern, Laenggassstrasse 122, Postfach, 3001 Bern, Switzerland (Heiderich, Origgi, Pisano, Ryser-Degiorgis, Marti); Institute of Veterinary Bacteriology, University of Bern, Laenggassstrasse 122, Postfach, 3001 Bern, Switzerland (Kittl); and Department of Clinical Research and Veterinary Public Health, Neurological Sciences, University of Bern, Bremgartenstrasse 109a, 3001 Bern, Switzerland (Oevermann). Present addresses (Origgi): Institute of Animal Pathology, Laenggassstrasse 122, Postfach, 3001 Bern, Switzerland; Institute of Infectious Animal Diseases, Department of Veterinary Sciences, Università di Messina, Polo Universitario dell'Annunziata, 98168 Messina, Italy. Correspondence should be directed to Dr. Heiderich (elisabeth.heiderich@unibe.ch).

In wildlife, *L. monocytogenes* infection has been described in farmed fallow deer (*Dama dama*),²⁴ free-ranging sika deer (*Cervus nippon*),²² red deer (*Cervus elaphus*),²⁸ wild boar (*Sus scrofa*),^{22,28} western European hedgehogs (*Erinaceus europeaus*),⁹ hares,^{21,30} rodents,²⁷ and wild birds.¹⁰ Although *L. monocytogenes* can cause severe disease and death to wildlife, infected wild boar, red deer, and sika deer may remain asymptomatic and carry the bacterium as part of their normal microbiome.^{19,22,28}

Listeriosis is not commonly diagnosed in carnivores, and reports of *L. monocytogenes* infections in free-ranging carnivores are limited. Clinical listeriosis was diagnosed in gray foxes (*Urocyon cinereoargenteus*)¹⁴ and a raccoon dog (*Nyctereutes procyonoides*),¹ whereas the bacterium was isolated from black bears (*Ursus americanus*),¹⁹ red foxes (*Vulpes vulpes*), beech martens (*Martes foina*), and raccoons (*Procyon lotor*)¹⁵ without associated pathologies.

In Switzerland, the red fox is the most widely distributed free-ranging carnivore. It is an extremely adaptive species that can be found in high alpine as well as urban environments. The ability to thrive in human-dominated landscapes makes it a particular relevant species for the surveillance of zoonotic pathogens.³ By contrast, the Eurasian lynx (*Lynx lynx*) is considered endangered in Switzerland and its conservation is of high national and international priority.²⁶ Consequently, investigation of mortalities within a health surveillance program is essential in a One Health context.

We report listeriosis in seven red foxes and one Eurasian lynx that were found over a period of 10 yrs in geographically distant locations in Switzerland.

CASE REPORTS

Animals

Between 2010 and 2021, 566 red foxes and 232 Eurasian lynx were submitted to the Institute for Fish and Wildlife Health (FIWI), University of Bern, Switzerland, for postmortem examination within the national general wildlife health surveillance program. All animals were not systematically tested for *L. monocytogenes*, but molecular diagnostic testing was performed based on macroscopic and histopathologic findings. In seven red foxes and one Eurasian lynx, the examination was macroscopically and histopathologically suspicious for listeriosis, which was confirmed via molecular data. All animals were found dead, except one red fox, which was found in agony and died spontaneously upon arrival of the game warden. Case history and animal data are given in Table 1, and the

Table 1. History and animal data of red foxes (*Vulpes vulpes*) and Eurasian lynx (*Lynx lynx*) diagnosed with *Listeria monocytogenes* in Switzerland from 2010 to 2021.

ID no.	Species	Month and year found dead	Autolysis degree	Age class and sex	Body condition	Body weight (kg)	Habitat type, location, canton	History of other animals found dead in same area ^a
1	Red fox	Mar 2010	Moderate	Adult female	Good	5.0	Rural, Rietberg, Graubünden	3 red foxes
2	Red fox	Jun 2010	Moderate	Adult male	Poor	5.3	Rural, Baldingen (on a farm), Aargau	No
3	Red fox	Nov 2010	Moderate to severe	Juvenile female	Good to moderate	4.9	Rural, Abtwil (village border), Aargau	3 red foxes over 10 d
4	Red fox	Feb 2015	Moderate	Adult male	Good	6.9	Rural, Gumels, Freiburg	3 red foxes
5	Eurasian lynx	Aug 2016	Severe	Subadult male	Emaciated	7.8	Rural, Les Geneveys-sur-Coffrane, Neuenburg	No
6	Red fox	Oct 2020	Moderate	Adult male	Poor	4.4	Rural, Vuarat (on a farm), Freiburg	1 red fox culled the same day due to illness
7	Red fox	Oct 2020	Mild	Juvenile male	Good to moderate	4.9	Rural, Hasliberg Reuti, Bern	2 foxes and a European badger (<i>Meles meles</i>) over 20 d
8	Red fox	Feb 2021	Mild	Adult female	Moderate	4.4	Suburban, Thônex, Genéve	No

^a Not submitted to the Institute for Fish and Wildlife Health for further investigation.

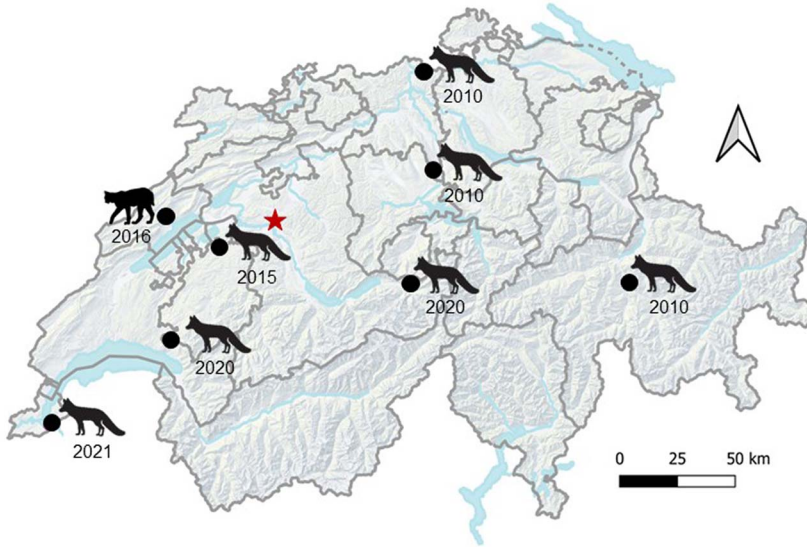


Figure 1. Origin and year of submission of the carcasses of free-ranging carnivores diagnosed with *Listeria monocytogenes* at the Institute for Fish and Wildlife Health (FIWI) in Switzerland; star = location of FIWI.

geographical distribution of the cases is illustrated in Figure 1.

Pathology

Macroscopic examination and full dissection was performed in all cases and complemented by histopathology in all but one red fox. Tissue samples were fixed in 10% neutral-buffered formalin. They were then processed, embedded in paraffin, sectioned at 5- μ m thickness, and stained with H&E for histologic examination following the accredited protocols of the Institute of Pathology, University of Bern. Gram stain was applied to selected samples as needed. Representative specimens of organs were collected at necropsy for ancillary laboratory analysis.

Laboratory analysis

Bacteriology: Bacterial culture of lung ($n = 5$), spleen ($n = 5$), liver ($n = 3$), and kidney ($n = 2$) was done at the Institute of Veterinary Bacteriology, University of Bern, Switzerland. Heated spatula was used to sear the exterior of the organ surface, after which one loopful of material was streaked onto BDTM Trypticase soy agar with 5% sheep blood (Becton Dickinson, 4123 Allschwil, Switzerland), BDTM chocolate agar (GC II Agar with IsoVitaleX, Becton Dickinson), OxoidTM MacConkey agar no. 3 (lung) (Becton Dickinson, 4123 Allschwil, Switzerland), and OxoidTM Broth agar (other organs) (ThermoFisher Scientific). Plates were incubated aerobically (sheep blood and chocolate agar

with 5% CO₂) and read after 24 and 48 h (72 h for chocolate agar). Suspected *Listeria* spp. isolates were identified to species level by using VITEK[®] 2 COMPACT (Biomérieux, 1213 Petit-Lancy, Switzerland) GP card.

For serotyping, the suspected *L. monocytogenes* isolates were submitted to the National Reference Centre for Enteropathogenic Bacteria and Listeria at the Institute for Food Safety and Hygiene, University of Zurich, Switzerland.

Immunohistochemistry: Presence of *L. monocytogenes* was confirmed by immunohistochemistry (IHC) on paraffin-embedded tissue sections of liver ($n = 4$ red foxes, $n = 1$ Eurasian lynx) and spleen ($n = 2$ red foxes, $n = 1$ Eurasian lynx) as well as brain ($n = 1$ red fox) with a polyclonal rabbit antibody against *L. monocytogenes* serotypes 1 and 4 (1:200, Difco Laboratories, Detroit, MI 48201, USA) following antigen retrieval by enzymatic digestion with trypsin 0.2% at 37°C for 10 min as previously described.⁵ Tissue sections were incubated with the primary antibody for 1 h at room temperature, and positive reactions were visualized with mouse- and rabbit-specific horseradish peroxidase/3-amino-9-ethylcarbazole detection kit (ab93705, abcam, Cambridge CB2 0AX, United Kingdom).

PCR: A reverse transcription PCR for the detection of canine distemper virus (CDV) RNA was performed from total RNA extracted brain and lung tissues⁹ from red foxes and from brain tissue and a lymph node of the Eurasian lynx.

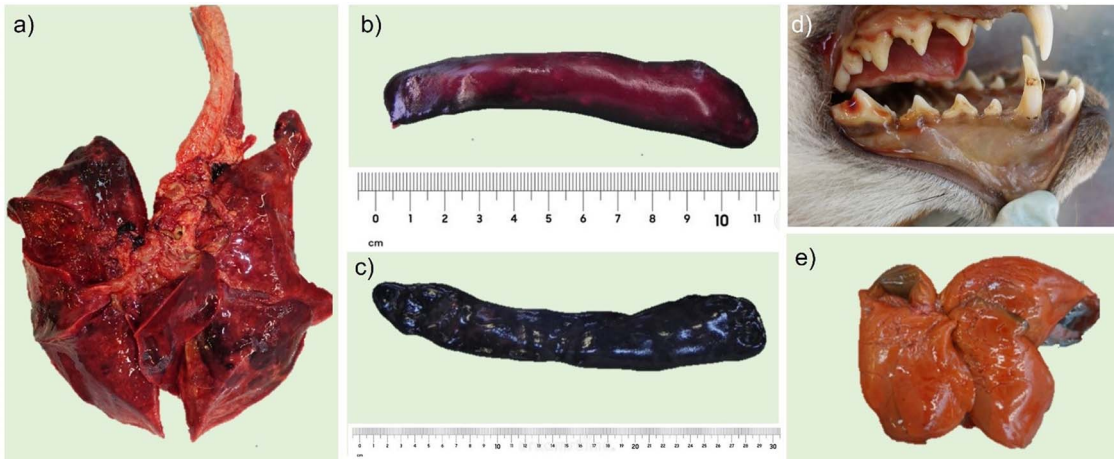


Figure 2. Gross lesions of free-ranging Eurasian lynx (*Lynx lynx*) and red foxes (*Vulpes vulpes*) with listeriosis in Switzerland. (a) Lung (red fox): multifocal-to-coalescent hemorrhages. (b) Spleen (red fox): mild splenomegaly with tan foci on the surface. (c) Spleen (Eurasian lynx): severe splenomegaly (the multifocal depressions of the surface are due to autolysis). (d) Oral cavity (red fox): icteric mucous membranes. (e) Liver (red fox): brown-to-orange discoloration.

Pathology findings

Macroscopic examination: Carcass condition varied from mildly ($n = 2$) to moderately ($n = 4$) to severely autolytic ($n = 1$) in the red foxes. The Eurasian lynx was severely autolytic, with considerable tissue loss due to myiasis, thus limiting its examination. Body condition was moderate to good in five red foxes, poor in two red foxes, and emaciated in the Eurasian lynx (Table 1). Six of seven red foxes showed multifocal-to-coalescent lung hemorrhages (Fig. 2a), occasionally in association with increased lung consistency or nodular formation ($n = 5$). Mild-to-moderate splenomegaly was observed in two red foxes (Fig. 2b), whereas severe splenomegaly was found in the Eurasian lynx (Fig. 2c). In one red fox multiple, prominent light tan foci of 2–3-mm diameter were present on the surface of the spleen. In three red foxes, the mucous membranes including conjunctivae were icteric (Fig. 2d). In one red fox, the liver had an orange-to-brown color with a fragile consistency (Fig. 2e). Key necropsy, histopathology, and microbiology findings are summarized in Table 2.

Histology: The histopathologic interpretation of all organs of the Eurasian lynx was severely hampered by advanced autolysis and is therefore not further described.

In the liver multiple necrotic lesions as well as infiltrations with macrophages and neutrophils were observed in five red foxes. Intralesional gram-positive bacteria were present in two individuals (Fig. 3a).

The spleen of five red foxes showed severe lymphoid depletion, with a severe necrotizing splenitis in two foxes and intralesional gram-positive bacteria in one fox (Fig. 3b). Eosinophilic intracytoplasmic inclusion bodies were present in macrophages of one fox.

Bronchointerstitial pneumonia was detected in four red foxes: three had multiple necrotic lesions with embedded intralesional gram-positive bacteria in one individual. Eosinophilic intracytoplasmic inclusion bodies were detected in the alveolar macrophages of another red fox.

Three red foxes had a meningitis with infiltrating macrophages and vacuolization of the white matter and gitter cells. Choroiditis characterized by multifocal infiltrations of macrophages and plasma cells was observed in one fox. Meningoencephalitis either with necrotizing lesions or with mixed infiltration of histiocytes, lymphocytes, and plasma cells was found in two red foxes. Eosinophilic inclusion bodies were detected in the cytoplasm of macrophages as well as in the nucleus and the cytoplasm of the neurons of one red fox.

Other findings included dermatitis and cellulitis with severe infiltrations of gram-positive coccobacilli in two red foxes and a multisystemic amyloidosis (liver, spleen, and lung) in one red fox.

Laboratory analysis findings

Bacteriology: The *L. monocytogenes* serotype 1/2a was identified from five red foxes and the Eurasian lynx, and serotype 4b was isolated from

Table 2. Main findings in red foxes (*Vulpes vulpes*) and Eurasian lynx (*Lynx lynx*) diagnosed with *Listeria monocytogenes* in Switzerland from 2010 to 2021.^a

ID no.	Species	Key macroscopic findings	Histopathology findings	Microbiology (aerobic culture LM) ^b	LM serotype	Coinfection
1	Red fox	Liver: mild hepatomegaly; spleen: mild splenomegaly; lung: multifocal hemorrhages	Spleen: necrotizing splenitis with lymphoid depletion, multifocal, severe, chronic; liver: necrotizing hepatitis, multifocal, severe, chronic; brain: meningitis, multifocal, moderate with vacuolization of white matter associated with gutter cells	Liver, spleen, kidney: +++; lung: +	Serotype 4b	CDV positive (brain, lung)
2	Red fox	Lung: increased consistency of the right lung lobe; liver: fragile consistency with light tan round foci (2–3 mm in diameter) on the surface; skin: large purulent-oozing laceration (mandible to thorax)	Lung: bronchointerstitial pneumonia, mild with intralobular gram-positive bacteria, focal necrosis and hemorrhages; liver: necrotizing hepatitis with intralobular gram-positive bacteria, focal, mild; spleen: lymphoid depletion, mild with multinucleated giant cells; skin: dermatitis and cellulitis, purulent, necrotizing, ulcerative, severe with intralobular, gram-positive bacteria and regional, necrotizing lymphadenitis	Lung, bronchus: ++	Serotype 1/2a	none detected
3	Red fox	Spleen: multifocal light tan foci (2–3 mm in diameter) on the surface	Lung: bronchointerstitial pneumonia, moderate, multifocal with intracytoplasmic inclusion bodies, necrotizing and hemorrhagic pneumonia, moderate, multifocal; spleen: necrotizing splenitis moderate, multifocal with lymphoid depletion and intracytoplasmic inclusion bodies; liver: necrotizing hepatitis, mild to moderate, with intralobular bacteria; brain: necrotizing meningoencephalitis, mild, multifocal with intracytoplasmic inclusion bodies	Spleen: +++	Serotype 4b	CDV positive (brain, lung)
4	Red fox	Lung: margins of left caudal and middle lobes are of increased consistency and of light gray color, multifocal nodular (~5 mm) formation in the caudal lobes	Lung: granulomatous, interstitial pneumonia, multifocal, moderate with intravascular parasitic structures, bronchointerstitial pneumonia multifocal, mild, with syncytial cells; liver: necrotizing hepatitis, multifocal, moderate; spleen: lymphoid depletion, moderate to severe with severe congestion of vessels; brain: meningoencephalitis, multifocal, mild to moderate, with mild, diffuse gliosis	Lung, bronchus: ++	Serotype 1/2a	CDV positive (brain, lung)
5	Eurasian lynx	Spleen: splenomegaly, severe; liver: hepatomegaly, mild; lymph nodes: lymphadenomegaly	Histopathologic interpretation limited due to advanced autolysis	Spleen: +++	Serotype 1/2a	none detected
6	Red fox	Mucous membranes: icteric; lung: dark red colored, increased consistency; liver: orange-brown color, fragile consistency; spleen: splenomegaly, rounded margins, fragile consistency	Lung: interstitial pneumonia, severe, fibrinous-necrotizing, multifocal; brain: meningitis, moderate, multifocal with gliosis and congestion; liver: necrotizing hepatitis, severe, multifocal; spleen: lymphoid depletion	Lung, bronchus: +++	Serotype 1/2a	CDV positive (brain, lung), <i>Salmonella enterica</i> subsp. <i>enterica</i> +++ (lung, bronchus)

Table 2. Continued.

ID no.	Species	Key macroscopic findings	Histopathology findings	Microbiology (aerobic culture LM) ^b	L.M serotype	Coinfection
7	Red fox	Eyes: icteric conjunctivae, conjunctivitis; lung: multifocal hemorrhages with nodular formation (3–10 mm in diameter)	No histopathologic examination performed	Lung, bronchus, kidney: ++	Serotype 1/2a	CDV positive (brain, lung)
8	Red fox	Mucous membranes: icteric; eyes: mucopurulent secretion; skin: multifocal skin perforations on snout and forelimb; spleen: mild splenomegaly	Liver, spleen, kidney, lung: amyloidosis, multisystemic, severe, chronic, with hepatocellular necrosis (liver), splenomegaly (spleen), icterus (whole body); brain: choroiditis, mild, multifocal with gliosis and mild meningitis; skin and mucous membrane (mouth): perforation, multifocal, severe, chronic with dermatomyositis and gingivitis, necrosis, hemorrhages, mineralizations and epidermal ulcerations	Spleen: +++	Serotype 1/2a	CDV positive (brain, lung)

^a LM = *L. monocytogenes*; CDV = canine distemper virus.

^b + = mild; ++ = moderate; +++ = severe.

two red foxes. In addition, *Salmonella enterica* subsp. *enterica* was isolated from the pulmonary parenchyma and the bronchus of one red fox (Table 2).

IHC: Six red foxes showed strong immunohistochemical cytoplasmic labeling for *L. monocytogenes* in the liver (hepatocytes, macrophages, and Kupffer cells) (Fig. 3c). In three red foxes, IHC labeling was also present in the spleen (Fig. 3d). In the Eurasian lynx, IHC showed positive lymphoid tissue. No IHC labeling was detected in the brain ($n = 2$ red foxes), kidney ($n = 3$ red foxes), or lung ($n = 2$ red foxes).

PCR: CDV nucleic acid was detected in the brain and lung of six of seven red foxes, but not in the Eurasian lynx.

DISCUSSION

We documented listeriosis in two free-ranging carnivore species in Switzerland, the red fox ($n = 7$) and the Eurasian lynx ($n = 1$), over a 10-yr period. This diagnosis was supported by morphologic, microbiologic, and molecular data. All cases were incidental findings within the national general wildlife health surveillance program, meaning that no systematic investigation for *L. monocytogenes* was conducted, but molecular diagnostic testing was performed based on macroscopic and histopathologic findings. Therefore, the presented cases do not allow conclusions on the disease prevalence in red foxes and Eurasian lynx. The infected animals originated from different places and were of both sexes and different age classes.

Infection with *L. monocytogenes* has been previously described in red^{12,15} and gray foxes¹⁴ as well as in other free-ranging carnivores, such as beech martens, raccoons,¹⁵ and black bears.¹⁹ To the best of the authors' knowledge, this is the first description of listeriosis in a lynx.

In this study, the bacterium was isolated from extraintestinal sites in all cases, indicating bacterial dissemination and septicemic listeriosis. This is the most common presentation of the disease in small mammals, whereas carnivores may present either the septicemic or encephalitic form.¹³

The main histopathologic findings in the red foxes were necrotizing hepatitis and splenitis, consistent with reports in gray foxes,¹⁴ and more recently in a white-tailed jackrabbit (*Lepus townsendii*)²¹ and free-living western European hedgehogs.¹¹

The rhombencephalitic form is the most common disease presentation in ruminants, such as sheep, goats, and cattle.²⁹ Characteristic histopathologic changes, such as microabscesses in the brainstem with adjacent perivascular mononuclear cuffing,¹⁷

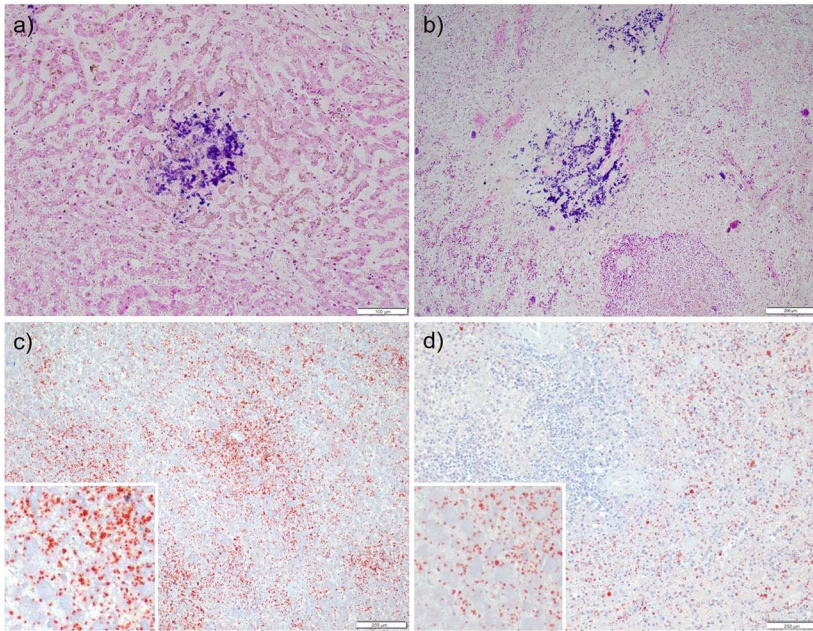


Figure 3. Histopathologic lesions of free-ranging red foxes (*Vulpes vulpes*) with listeriosis in Switzerland. (a) Liver (red fox), Gram stain, necrotic focus with intralesional gram-positive bacteria. (b) Spleen (red fox), Gram stain, severe necrotizing splenitis with intralesional gram-positive bacteria. (c) Liver (red fox), immunohistochemistry, positive cytoplasmic labeling for *Listeria monocytogenes* (see also the inset). (d) Spleen (red fox), immunohistochemistry, positive cytoplasmic labeling for *L. monocytogenes* (see also the inset).

were not detected in any of the reported cases. However, the animals in this study were not specifically examined for listeriosis and the brainstem was not routinely sampled for microscopic examination, so histopathologic changes in this area of the brain may have been missed. Furthermore, the advanced autolysis partially compromised the histopathologic examination and interpretation of the lesions of several organs, especially in the Eurasian lynx.

Lesions in the lung and the brain of the red foxes were likely caused by the CDV infection. CDV is known to be associated with nonsuppurative encephalitis,¹⁸ whereas listeriosis is characterized by neutrophilic infiltration.¹⁷ Furthermore, *L. monocytogenes* IHC was negative in the lung and brain in all cases. CDV is a well-known pathogen of carnivores.¹⁸ The virus emerged in several wild carnivore species, including red foxes and Eurasian lynx, in Switzerland between 2009 and 2010,¹⁸ and the disease has remained endemic in the Swiss red fox population with recurrent epidemic peaks. Although the number of listeriosis cases is very low, this disease was not diagnosed in wild carnivores in Switzerland before 2010. Thus, the concurrent infection with listeriosis and CDV in six of seven red foxes may suggest the immunosuppressive effect of CDV as a potential predisposing factor to develop listeriosis,

similar to gray foxes in New Hampshire, USA.¹⁴ However, one red fox and the Eurasian lynx with listeriosis were negative for CDV. One of the red foxes had a triple infection with CDV, *L. monocytogenes*, and *Salmonella enterica* subsp *enterica*, suggestive of a severely immunocompromised status. *Salmonella enterica* subsp *enterica* is a foodborne pathogen that can contaminate agricultural products and is responsible for 99% of salmonellosis cases in humans and warm-blooded animals.² In Poland, *Salmonella enterica* subsp *enterica* was detected in 2.45% of the 286 sampled red foxes, whereas *L. monocytogenes* was detected in 4.5%. By contrast, all tested beech martens ($n = 65$) and raccoons ($n = 70$) were negative for both pathogens. It was concluded that red foxes might pose a threat to human health due to growing population size and occurrence close to human settlements.¹⁵

The detected *L. monocytogenes* serotypes 1/2a and 4b are among the most frequently isolated serotypes (1/2a, 1/2b, and 4b) from food or the food production environment which cause >95% of human infections.²³ Serotypes 1/2a and 4b were most frequently found in other wild animals, such as red deer, wild boar,²⁸ and wild birds,¹⁰ as well as American black bears.¹⁹ Because the high prevalence of serotypes 1/2a or 3a (57%) and 4b (33%),

American black bears were considered a potential vehicle and perhaps carrier for *L. monocytogenes* and other *Listeria* spp., suggesting potential public health implications.¹⁹ Similar to black bears, red foxes frequently occur close to human settlements and could therefore contribute to the distribution of the pathogen in the anthropogenic environment. In the present case series, two of the red foxes were found on a dairy farm, and another red fox was found at the border of a village. *Listeria* spp. are ubiquitous and accordingly widely available for the recipient hosts either from the environment or from prey animals. A spillover from domestic animals (e.g., via spreading manure from domestic ruminants on fields) or from anthropogenic sources (e.g., farm or human waste) is possible. Systematic testing in urban red foxes would be needed to draw conclusions about possible public health risks. Infected mammals such as wild boar and red deer are known to serve as asymptomatic carriers²⁸ and are a potential source of infection for predators or scavengers, such as Eurasian lynx and red foxes, either directly via consumption of infected carcasses or indirectly via fecal shedding. A recent study documented a prevalence of 13% for *L. monocytogenes* in surface waters in Switzerland, with the majority of strains belonging to either serotype 1/2a (48%) or 4b (44%).²⁰ This could represent an additional source of infection not only for red foxes and Eurasian lynx but also for other receptive wildlife.

Since 2010, reported human listeriosis cases in Switzerland ranged from 30 to 100 annually. Main infection sources for humans in Switzerland are raw meat and fish products as well as unpasteurized milk products or soft cheese.^{6,16} In addition, highly processed products such as ready-to-eat salads have been reported as sources of infection. In livestock, 6–16 animals with *L. monocytogenes* infection were documented per year during the same time period.⁶ Besides this report in carnivores, listeriosis was very rarely diagnosed in other free-ranging Swiss wildlife. In the framework of the general health surveillance program at the FIWI, only two European hedgehogs in 2020 were confirmed with listeriosis between 2010 and 2021. However, this agent has not been systematically investigated and the relatively unspecific disease presentation along with existing coinfections might have reduced the probability of pathogen detection.

The present case series adds the Eurasian lynx to the list of carnivores susceptible to listeriosis and demonstrated the presence of *L. monocytogenes* in the red fox and Eurasian lynx population in Switzerland. Coinfections with CDV in six of seven red

foxes question the role of CDV as a potential predisposing factor increasing the susceptibility of these animals to develop septicemic listeriosis. Although passive material collection characterizing general wildlife health surveillance and the lack of systematic investigations cannot be considered representative of the real situation, the detection of two potentially zoonotic bacteria, *L. monocytogenes* and *S. e. enterica*, reinforces the importance of wildlife health surveillance in a One Health context. This case series intends to increase disease awareness in wildlife professionals working with carnivores, but does not allow conclusions on the prevalence, epidemiology, or human health risk of listeriosis. Further investigations are required to assess the prevalence and epidemiology of *L. monocytogenes* in free-ranging carnivores and its interaction with CDV.

LITERATURE CITED

1. Aoyagi T, Sato Y, Matsuura S, Wada H. Listeriosis in a raccoon dog (*Nyctereutes procyonoides*) associated with canine distemper. *J Vet Med Sci.* 2000;62(6):639–641.
2. Chlebicz A, Śliżewska K. Campylobacteriosis, salmonellosis, yersiniosis, and listeriosis as zoonotic foodborne diseases: a review. *Int J Environ Res Public Health* 2018;15(5):863.
3. Deplazes P, Hegglin D, Gloor S, Romig T. Wilderiness in the city: the urbanization of *Echinococcus multilocularis*. *Trends Parasitol.* 2004;20(2):77–84.
4. Dhama K, Karthik K, Tiwari R, Shabbir MZ, Barbudhe S, Malik SVS, Singh RK. Listeriosis in animals, its public health significance (food-borne zoonosis) and advances in diagnosis and control: a comprehensive review. *Vet Q.* 2015;35(4):211–235.
5. Di Palma S, Brunetti B, Doherr MG, Forster U, Hilbe M, Zurbriggen A, Vandeveld M, Oevermann A. Comparative spatiotemporal analysis of the intrathecal immune response in natural listeric rhombencephalitis of cattle and small ruminants. *Comp Immunol Microbiol Infect Dis.* 2012;35(5):429–441.
6. Federal Food Safety and Veterinary Office [Internet]. Report on the monitoring of zoonoses and foodborne disease outbreaks. 2021 [cited 2023 Nov 9]. <https://www.blv.admin.ch/blv/de/home/tiere/tiergesundheit/ueberwachung/ueberwachung-von-zoonosen.html>
7. Feng Y, Yao H, Chen S, Sun X, Yin Y, Jiao X. Rapid detection of hypervirulent serovar 4h *Listeria monocytogenes* by multiplex PCR. *Front Microbiol.* 2020; 11:1309.
8. Ferroglio E. Listeria infections. In: Gaviera-Widén D, Duff JP, Meredith A (eds.). *Infectious diseases of wild mammals and birds in Europe*. Chichester, United Kingdom: Blackwell Publishing; 2012. p. 413–416.
9. Frisk AL, König M, Moritz A, Baumgärtner W. Detection of canine distemper virus nucleoprotein RNA by reverse transcription-PCR using serum, whole blood,

and cerebrospinal fluid from dogs with distemper. *J Clin Microbiol.* 1999;37(11):3634–3643.

10. Hellström S, Kiviniemi K, Autio T, Korkeala H. *Listeria monocytogenes* is common in wild birds in Helsinki region and genotypes are frequently similar with those found along the food chain. *J Appl Microbiol.* 2008;104(3):883–888.

11. Hydeskov HB, Amar CFL, Fernandez JR-R, John SK, Macgregor SK, Cunningham AA, Lawson B. *Listeria monocytogenes* infection of free-ranging western European hedgehogs (*Erinaceus europaeus*). *J Zoo Wildl Med.* 2019;50(1):183–189.

12. Lempp C, Jungwirth N, Grilo ML, Reckendorf A, Ulrich A, van Neer A, Bodewes R, Pfankuche VM, Bauer C, Osterhaus ADME, Baumgärtner W, Siebert U. Pathological findings in the red fox (*Vulpes vulpes*), stone marten (*Martes foina*) and raccoon dog (*Nyctereutes procyonoides*), with special emphasis on infectious and zoonotic agents in northern Germany. *PLoS One* 2017;12(4):e0175469.

13. Mörner T. Listeriosis. In: Williams ES, Barker IK (eds.). *Infectious diseases of wild mammals*. 3rd ed. Ames (IA); Iowa State Univ Press; 2001. p. 502–505.

14. Needle DB, Marr JL, Park CJ, Andam CP, Wise AG, Maes RK, Wilkes RP, Anis EA, Sidor IF, Agnew D, Ellis JC, Tate P, Mathewson A, Benton C, Gibson R. Concurrent infection of *Skunk Adenovirus-1*, *Listeria monocytogenes*, and a regionally specific clade of canine distemper virus in one gray fox (*Urocyon cinereoargenteus*) and concurrent listeriosis and canine distemper in a second gray fox. *Pathogens* 2020;9(7):591.

15. Nowakiewicz A, Zięba P, Ziółkowska G, Gnat S, Muszyńska M, Tomczuk K, Majer Dziedzic B, Ulbrych Ł, Trościańczyk A. Free-living species of carnivorous mammals in Poland: red fox, beech marten, and raccoon as a potential reservoir of *Salmonella*, *Yersinia*, *Listeria* spp. and coagulase-positive *Staphylococcus*. *PLoS One* 2016;11(5):e0155533.

16. Nüesch-Inderbinnen M, Bloemberg GV, Müller A, Stevens MJA, Cernela N, Kollöffel B, Stephan R. Listeriosis caused by persistence of *Listeria monocytogenes* serotype 4b sequence type 6 in cheese production environment. *Emerg Infect Dis.* 2021;27(1):284–288.

17. Oevermann A, Zurbrüggen A, Vandeveldt M. Rhombencephalitis caused by *Listeria monocytogenes* in humans and ruminants: a zoonosis on the rise? *Interdiscip Perspect Infect Dis.* 2010;2010:1–22.

18. Origi FC, Plattet P, Sattler U, Robert N, Casaubon J, Mavrot F, Pewsner M, Wu N, Giovannini S, Oevermann A, Stoffel MH, Gaschen V, Segner H, Ryser-Degiorgis M-P. Emergence of canine distemper virus strains with modified molecular signature and enhanced neuronal tropism leading to high mortality in wild carnivores. *Vet Pathol.* 2012;49(6):913–929.

19. Parsons C, Niedermeyer J, Gould N, Brown P, Strules J, Parsons AW, Bernardo Mesa-Cruz J, Kelly

MJ, Hooker MJ, Chamberlain MJ, Olfenbittel C, DePerno C, Kathariou S. *Listeria monocytogenes* at the human–wildlife interface: black bears (*Ursus americanus*) as potential vehicles for *Listeria*. *Microb Biotechnol.* 2020;13(3):706–721.

20. Raschle S, Stephan R, Stevens MJA, Cernela N, Zurfluh K, Muchaamba F, Nüesch-Inderbinnen M. Environmental dissemination of pathogenic *Listeria monocytogenes* in flowing surface waters in Switzerland. *Sci Rep.* 2021;11(1):9066.

21. Rothenburger JL, Bennett KR, Bryan L, Bollinger TK. Septicemic listeriosis in wild hares from Saskatchewan, Canada. *J Wildl Dis.* 2015;51(2):503–508.

22. Sasaki Y, Goshima T, Mori T, Murakami M, Haruna M, Ito K, Yamada Y. Prevalence and antimicrobial susceptibility of foodborne bacteria in wild boars (*Sus scrofa*) and wild deer (*Cervus nippon*) in Japan. *Foodborne Pathog Dis.* 2013;10(11):985–991.

23. Swaminathan B, Gerner-Smidt P. The epidemiology of human listeriosis. *Microbes Infect.* 2007;9(10):1236–1243.

24. Tham W, Bannerman E, Bille J, Danielsson-Tham ML, Eld K, Ericsson H, Gavier-Widén D, Rocourt J, Mörner T. *Listeria monocytogenes* subtypes associated with mortality among fallow deer (*Dama dama*). *J Zoo Wildl Med.* 1999;30(4):545–549.

25. Vitullo M, Grant KA, Sammarco ML, Tamburro M, Ripabelli G, Amar CFL. Real-time PCRs assay for serogrouping *Listeria monocytogenes* and differentiation from other *Listeria* spp. *Mol Cell Probes* 2013;27(1):68–70.

26. Von Arx M, Kaczynsky P, Linnell JDC, Lanz T, Breitenmoser-Würsten C, Boitani L, Breitenmoser U. Conservation status of the Eurasian lynx in West and Central Europe. *CATnews Spec Issue* 2021;(14):5–8.

27. Wang Y, Lu L, Lan R, Salazar JK, Liu J, Xu J, Ye C. Isolation and characterization of *Listeria* species from rodents in natural environments in China: isolation and characterization of *Listeria* species. *Emerg Microbes Infect.* 2017;6(1):1–6.

28. Weindl L, Frank E, Ullrich U, Heurich M, Kleta S, Ellerbroek L, Gareis M. *Listeria monocytogenes* in different specimens from healthy red deer and wild boars. *Foodborne Pathog Dis.* 2016;13(7):391–397.

29. World Organisation for Animal Health. *Listeria monocytogenes*. *Terrestrial Manual*. Chapter 3.10.5 [Internet]. 2021 [cited 2023 Nov 9]. https://www.woah.org/fileadmin/Home/eng/Health_standards/tahm/3.10.05_LISTERIA_MONO.pdf

30. Wuthe HH, Schönberg A. Listeriose beim Feldhasen in Norddeutschland Listeriosis in the European brown hare in northern Germany. *Berl Munch Tierarztl Wochenschr.* 1999;112(3):98–99.

Accepted for publication 7 November 2023