



## Regeneration of Axons in Transection of the Carp Spinal Cord

Authors: Yamada, Hajime, Miyake, Toshihiko, and Kitamura, Tadahisa

Source: Zoological Science, 12(3) : 325-332

Published By: Zoological Society of Japan

URL: <https://doi.org/10.2108/zsj.12.325>

---

BioOne Complete ([complete.BioOne.org](https://complete.BioOne.org)) is a full-text database of 200 subscribed and open-access titles in the biological, ecological, and environmental sciences published by nonprofit societies, associations, museums, institutions, and presses.

Your use of this PDF, the BioOne Complete website, and all posted and associated content indicates your acceptance of BioOne's Terms of Use, available at [www.bioone.org/terms-of-use](https://www.bioone.org/terms-of-use).

Usage of BioOne Complete content is strictly limited to personal, educational, and non - commercial use. Commercial inquiries or rights and permissions requests should be directed to the individual publisher as copyright holder.

---

BioOne sees sustainable scholarly publishing as an inherently collaborative enterprise connecting authors, nonprofit publishers, academic institutions, research libraries, and research funders in the common goal of maximizing access to critical research.

## Regeneration of Axons in Transection of the Carp Spinal Cord

HAJIME YAMADA, TOSHIHIKO MIYAKE and TADAHISA KITAMURA

*Shionogi Institute for Medical Science, 12-4, Sagisu 5-chome,  
Fukushima-ku Osaka 553, Japan*

**ABSTRACT**—Axonal regeneration in the central nervous system (CNS) was investigated in the fine structural and histochemical aspects using carp spinal cord, which was completely transected at the level of the dorsal fin. Fusion of the transection region and the regeneration of axons already began to be recognized 26 days after operation by electron microscopy. At 115 days after operation, the rostral and caudal parts of the transected spinal cord were completely connected by the regenerating nervous tissue, which contained numerous axons among the ependymal and glial processes.

Horseshoe peroxidase (HRP), which was injected in the spinal cord at the portion caudal to the transection site was detected in the cytoplasm of large neurons located in the reticular formation of midbrain. This demonstrates that these long axons were regenerated passing through the ablation gap 151–204 days after operation. These findings indicate that regenerating axons in the carp spinal cord can pass through the glial scar formed in the transected portion, which is considered to be the main obstacle for the prolongation of axons in the mammalian CNS.

Many regenerating axons, both unmyelinated and myelinated, were observed being in contact directly with the cell membrane of the ependymal as well as astroglial cells. This indicates that neither ependymal nor glial cells play a role as an obstacle for elongation of axons in the carp spinal cord. Numerous GFAP (glial fibrillary acidic protein) positive intermediate filaments were observed in the cell bodies and cytoplasmic processes of both ependymal cells and astroglia. Their morphological similarity and similar property for axonal elongation indicate that the cells of both types in the carp spinal cord are intimately related with each other in origin, morphology and function.

### INTRODUCTION

Axonal regeneration hardly takes place in the central nervous system (CNS) of higher vertebrates in the transected nerve fibers. The main obstacle to extension of the regenerating axons has been considered to be the glial scar that is formed at the site of damage [7, 10, 17, 19]. In contrast, regeneration of long axons was reported to occur in the spinal cord as well as in the optic nerve of amphibians and fishes [3, 4, 11, 12, 21]. Anderson *et al.* [1] reported that in the fish spinal cord, regenerating axons can extend passing through the glial scar, which is composed of numerous glial processes containing many GFAP-positive intermediate filaments as in mammals.

Two hypotheses have been proposed to explain this phenomenon. The first one is that the surface properties of these processes are different from those in mammals which inhibit extension of axons, although the glial scar in the lower vertebrates is composed of processes of the astroglia similar to those in higher vertebrates [1]. The second one is that the cytoplasmic properties of scar-forming glial cells in lower vertebrates are different from those in mammals. Most astroglial cells in the spinal cord and brain of the lower vertebrates do not belong to stellate astrocytes but belong to radially oriented ependymal cells [2, 14, 16, 18]. However, whether the cell processes forming the glial scar in the spinal cord of lower vertebrates including teleosts are of stellate astroglia or of other type of glial cells has not been proved.

In the present study, we investigated the fine structure and chemical properties of these scar-forming glial processes by immunohistochemistry using an anti-GFAP antibody and found that regenerating axons were directly in contact with the astroglial as well as the ependymal cells.

### MATERIALS AND METHODS

#### *Surgical procedure*

Carp (*Cyprinus carpio*) of 16–27 cm in body length were used for this study. Under anesthesia with 0.02% ethyl m-aminobenzoate methanesulfonate (Tricaine), skin and muscle of the right side of the body were incised at the level of the caudal end of the dorsal fin. After laminectomy the spinal cord was exposed. Then, the spinal cord was transected completely with a micro-dissecting scissors at the site between the vertebral segments 7 and 8 as counted from the caudal end. The skin and muscle were closed with sutures and the fish were kept in an ordinary water aquarium.

#### *Histological examination*

Fish were sacrificed on days 5, 10, 13, 20, 26, 27, 31, 39, 43, 115 and 168 after transection, and the damaged portion of the spinal cord was removed and examined by light and electron microscopy. For light microscopic observation, the tissue of the spinal cord was fixed with 4% paraformaldehyde in 0.1 M phosphate buffer (pH 7.4), and embedded in paraffin. Four  $\mu\text{m}$ -thick sections were cut and stained with either hematoxylin-eosin or Bodian's protein-silver solution. For electron microscopy (EM), the tissue was fixed with a fixative containing 2.4% paraformaldehyde, 2.2% glutaraldehyde, and 10 mM  $\text{CaCl}_2$  in 0.1 M cacodylate buffer (pH 7.4). After osmification, the tissue was dehydrated by ethanol and embedded in epon 812. Ultrathin sections were cut, stained with uranyl acetate and lead acetate, and were observed under a JOEL 100CX II electron

Accepted March 27, 1995

Received February 9, 1995

microscope.

#### *Retrograde labeling of nerve cells with horseradish peroxidase (HRP)*

Carp which were allowed to survive 151–204 days after transection were used. Under anesthesia, laminectomy was performed at the portion 9–13 mm caudal to the transection site, and 1–2  $\mu$ l of horseradish peroxidase (HRP) solution (50% HRP in 0.05 M Tris-HCl buffer, pH 8.6, Sigma) was injected into the spinal cord. Six days later, the carps were sacrificed and the brain tissue including the midbrain was removed. The tissue was fixed with a fixation mixture containing 1.5% glutaraldehyde, 1% paraformaldehyde, and 4% sucrose in 0.1 M phosphate buffer (pH 7.4) for 2 hr, placed in 10–20% sucrose in 0.1 M phosphate buffer (pH 7.4) for several hr, and were then embedded in embedding medium (O.C.T. compound, Miles Inc.). Serial 20  $\mu$ m-thick frozen sections covering the entire length of the midbrain were cut and placed in an ice-cold reaction mixture containing 50 mg of 3,3'-diaminobenzidine tetrahydrochloride (DAB), 0.6 ml of dimethyl sulfoxide, 2.5 ml of 0.2 M acetic acid-sodium buffer (pH 4.3–4.5), 10 ml of 0.2% gelatin, 23 ml of methanol, and 13 ml of distilled water. After 10 and 140 min, 0.15 ml and 0.2 ml of 1.5% hydrogen peroxide were added, respectively [13]. The sections were rinsed in distilled water, dehydrated in a graded series of ethanol, and mounted in methacrylate resin. HRP depositions were detected as brown granules in the cytoplasm of the large nerve cells located in the reticular formation (RF), and the number of HRP-labeled nerve cells was counted. For the control, the tissues of spinal cords and midbrain of non-operated carps were processed in the same manner as described above.

#### *Electron microscopic immunohistochemistry for GFAP*

Intact and operated carps sacrificed 27 days after transection were used. The animals were anesthetized with 0.02% Tricaine and were fixed by perfusion with 2% paraformaldehyde and 1% glutaraldehyde in 0.1 M phosphate buffer (pH 7.4). After perfusion, the regenerating portion of the spinal cord was removed and was immersed in the same fixative for 3 hr at 4°C. The tissue was postfixed in 1.5% aqueous potassium ferrocyanide-reduced 1% osmium tetroxide for 30 min. The fixed tissue was then dehydrated in graded ethanol and was embedded in LR white resin [15]. Ultrathin sections were mounted on nickel grids. The sections were incubated in 1% BSA for 20 min, and next in anti-cow GFAP antibody (1:10 dilution by 0.1% BSA, DAKO) overnight at 4°C. After rinsing in 0.1% BSA/PBS, the sections were incubated in protein A-gold complex (15 nm gold particles, E.Y. Lab., Inc., U.S.A., diluted by 0.1 M Tris-HCl pH 8.4) for 1 hr. The sections

were rinsed in 0.1% BSA/PBS, and were treated with 2.5% glutaraldehyde for 10 min. After being washed with distilled water, the sections were dried in air and stained with uranyl acetate and lead acetate.

## RESULTS

The carp spinal cords were completely transected, making an approximately 1 mm-wide gap between the rostral and caudal stumps (Fig. 1a). At 10 days after the operation the gap was already filled with a small amount of semi-transparent mesenchymal tissue. At 26 days after the operation, the severed stumps of the transected spinal cord were connected with the fragile nervous tissue (Fig. 1b). The severed stumps of the fish examined approximately 40 days after the operation were connected with the grayish-white nervous tissue which was surrounded by the semi-transparent mesenchymal tissue.

At 115 days after the operation, the ablation gap was filled with whitish opaque nervous tissue, and the diameter of the spinal cord of this portion was almost the same as that of the normal part of the spinal cord (Fig. 1c). We could confirm by light microscopy that the damaged site was almost entirely replaced by the nervous tissue, which was surrounded by a small amount of mesenchymal connective tissue and pia mater (Fig. 2a). Bodian staining showed numerous neuronal processes in the regenerated nervous tissue (Fig. 2b).

At this stage, the central canal in the rostral stump was dilated showing fork-like or more complicated appearance and was sometimes located near the pia mater (Fig. 2a). In the rostral stump, the central canal was dilated, while in the caudal stump, the lumen was extremely narrow and hardly detectable by light microscopy. The ependymal cells tightly aligned at the inner surface of the canal were usually attenuated in the rostral stump and cylindrical in the caudal stump. Mitotic figures of the ependymal cells were sometimes observed in the ependymal layer throughout the entire experimental period in the rostral and caudal stumps.

#### *HRP-labeled nerve cells*

HRP, which was injected into the spinal cord at 9–13 mm caudal part from the severed margin, was histochemically

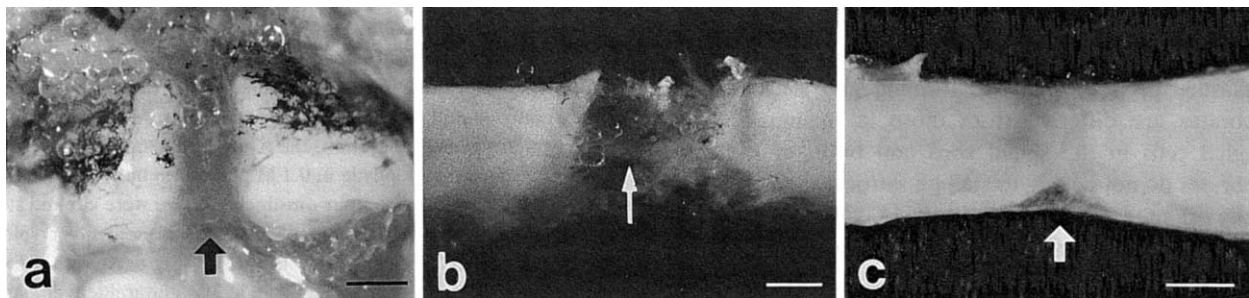


Fig. 1. Photographs of transected carp spinal cord. (a) A spinal cord is completely transected and an approximately 1 mm-wide gap (arrow) is made between the rostral (left) and caudal (right) stumps. upper: dorsal. lower: ventral. Bar=500  $\mu$ m. (b) 26 days after the operation. An ablation gap is connected with very narrow regenerating nervous tissue (arrow). Bar=500  $\mu$ m. (c) 115 days after the operation. An ablation gap (arrow) is replaced completely by whitish opaque nervous tissue. Bar=500  $\mu$ m.

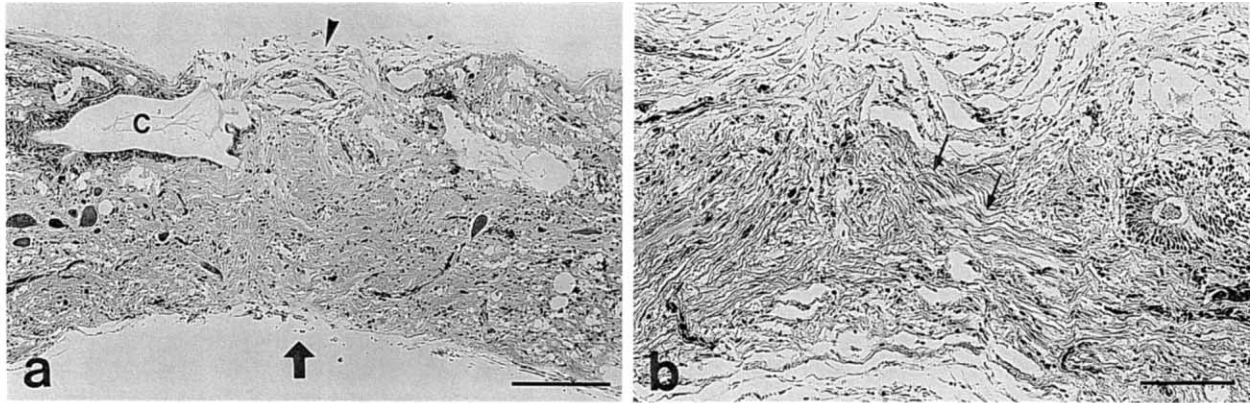


FIG. 2. Light micrograph of regenerated spinal cord 115 days after the operation. Sagittal sections. (a) The transection part (arrow) is almost completely filled with nervous tissue, and a small amount of mesenchymal connective tissue (arrowhead) are observed in the periphery of the regenerated spinal cord. H.E. staining. C: central canal. Bar=100  $\mu$ m. (b) Many regenerated neuronal processes (arrows) in the nervous tissue are filling the transected part. Bodian staining. Bar=100  $\mu$ m.

demonstrated in the perikarya of large nerve cells located in the area of reticular formation of the brain stem (Fig. 3). The average number of these HRP-labeled nerve cells at 151–

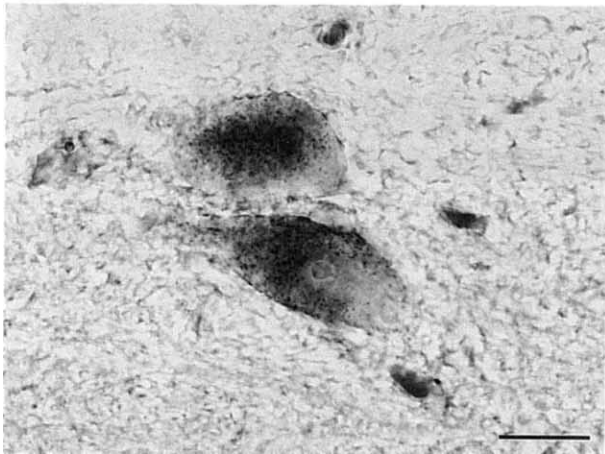


FIG. 3. Light micrograph of labeled nerve cells in the reticular formation of brain stem at 6 days following injection of HRP into the spinal cord 9–13 mm caudal to the transection region. Reaction products for HRP are localized in the cytoplasm of the large nerve cells. Bar=25  $\mu$ m.

TABLE 1. Number of labeled cells in the brain stem reticular formation 6 days after injection of horseradish peroxidase (HRP) into the spinal cord 9–13 mm caudal to the transection region

	Days after transection	Number of labeled cells (Average)	
Control	—	120	(130)
	—	124	
	—	145	
Operated	151	27	(40)
	162	51	
	180	29	
	204	52	

204 postoperative days was 40. On the contrary, in the unoperated carp, approximately 130 large nerve cells of the reticular formation were labeled by this method (Table 1).

#### *Electron microscopy and electron microscopic immunohistochemistry for GFAP*

In the intact spinal cord, ependymal cells facing the central canal form an ependymal layer. Microvilli and cilia projecting to the central canal were observed on their apical surfaces. The cell nucleus was usually spheroid in shape. Many desmosomes were seen between these cells. The cell cytoplasm contained poorly developed rough endoplasmic reticulum, small Golgi apparatus, a few mitochondria and small amount of glycogen particles (Fig. 4a, b). All the ependymal cells have many intermediate filaments in the cytoplasm of their perikarya and cell processes. Immunohistochemically, all these filaments reacted well with the anti-GFAP antibody. Numerous immuno-gold particles were localized exclusively on these filaments (Fig. 5a). Astroglial cells located far from the central canal have also a lot of GFAP-positive intermediate filaments in their cytoplasm (Fig. 5b). By electron microscopic immunohistochemistry for GFAP, we could exactly distinguish axons from the processes of the ependymal and astroglial cells.

Neither myelinated nor unmyelinated axons were detectable in the ependymal cell layer of the intact spinal cord. A few unmyelinated axons having small dense-cored and/or non-cored vesicles (Fig. 4c) were observed among the ependymal cells in the abluminal region. However, many axons running parallel among the astroglial processes were usually seen.

In the carp 26–27 days after the operation, the spinal cords were completely regenerated by the fragile nervous tissue. The rostral, middle and caudal regions in the regenerated portion of the spinal cord, numerous axons, myelinated and/or unmyelinated, were observed among the elongated ependymal cells and astroglial cell processes (Fig. 6a, b). The cell membranes of the nerve fibers were in

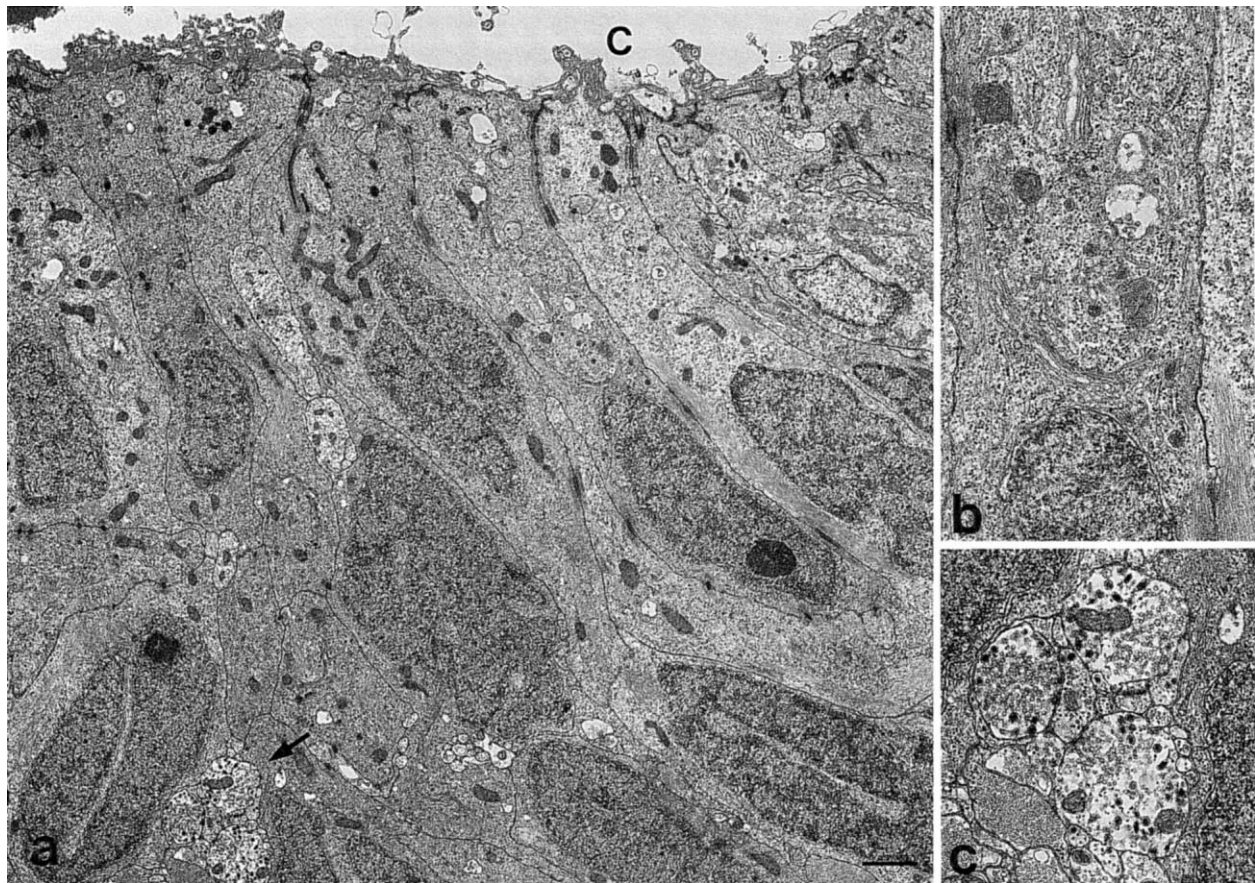


FIG. 4. Electron micrograph of an intact spinal cord. (a) Ependymal cells align around the wall of the central canal. C: central canal. Bar = 1  $\mu$ m. (b) High magnification of the cell body of an ependymal cell. Poorly developed rough endoplasmic reticulum, small Golgi apparatus, a few mitochondria and small glycogen particles are seen in the ependymal cell cytoplasm. (c) Higher magnification of the bundles of unmyelinated axons (in (a) (arrow)) locating in the abluminal region between ependymal cells and astroglial cells. They have small dense-cored vesicles and non-cored ones.

contact with those of the ependymal cells and/or of astroglial cells.

All the ependymal as well as astroglial cells in these experimental animals contained many intermediate filaments strongly positive for GFAP immunohistochemistry as in the normal carp (Fig. 7 a-c).

## DISCUSSION

At about 100 days after complete transection of the carp spinal cord, the rostral and caudal stumps were completely connected by the regenerating nervous tissue, and the caliber at this portion was recovered to almost the same size as that of the adjacent normal portion of the spinal cord. The main constituents of the regenerating nervous tissue were ependymal elements, astroglial elements and axons.

To determine whether the axons observed in the regenerating tissue really extend across the transected lesion, we performed a retrograde HRP-tracing study. It has been widely accepted that HRP taken up by the axon terminal is transported in a retrograde direction through the axon to the neuronal cell body and its dendrites, where the transported

HRP can be visualized as brown granules by histochemical staining [6, 8, 9]. After injection of HRP into the caudal-most part of the intact carp spinal cord, approximately 130 large nerve cells of the reticular formation in the brain stem were labeled with HRP. At 151 to 204 days after the transection of the spinal cord, approximately 40 HRP-labeled large nerve cell bodies were seen. This fact means that about 1/3 of the large nerve cells in the reticular formation regained their long axons extending across the transected lesion within six months after the operation. In the transected spinal cord of the goldfish [3, 4], lamprey [20, 21], and salamander [5], similar findings showing the occurrence of long axonal regeneration were reported using the HRP-tracing method. Thus, we could confirm that axons can regenerate in the long distance passing through the transected portion in the carp spinal cord.

In the normal carp spinal cord, axonal fibers were difficult to find in the ependymal cell layer. However after the transection, bundles of the regenerating axonal fibers, both myelinated and unmyelinated, were usually seen in the ependymal layer, and also in the astroglial scar. In the later stage of regeneration, many regenerated axons were



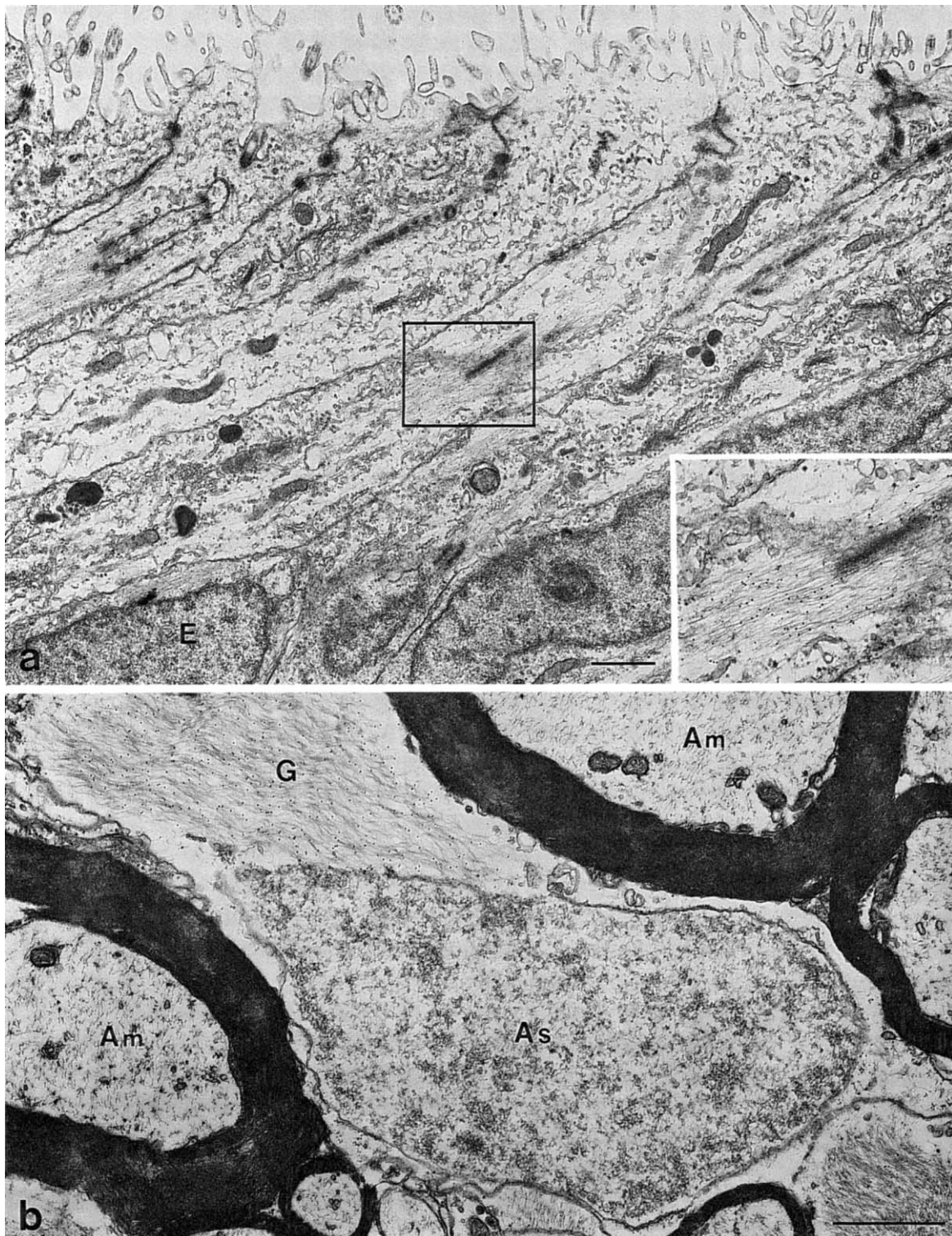


FIG. 5. Electron microscopic immunohistochemistry for glial fibrillary acidic protein (GFAP) in an intact spinal cord. (a) Numerous intermediate filaments positive for GFAP in the ependymal cell bodies (E) and cell processes. Notice the immuno-gold particles. Bar=1  $\mu\text{m}$ . Inset; Higher magnification of the cell body. (b) Numerous intermediate filaments positive for GFAP in the astroglial cell body and cell processes. Notice the immuno-gold particles. The axons do not react with the anti-GFAP antibody. Am: myelinated axon, As: astroglial cell nucleus, G: GFAP immunoreactive intermediate filaments in the astroglial cytoplasm. Bar=1  $\mu\text{m}$ .

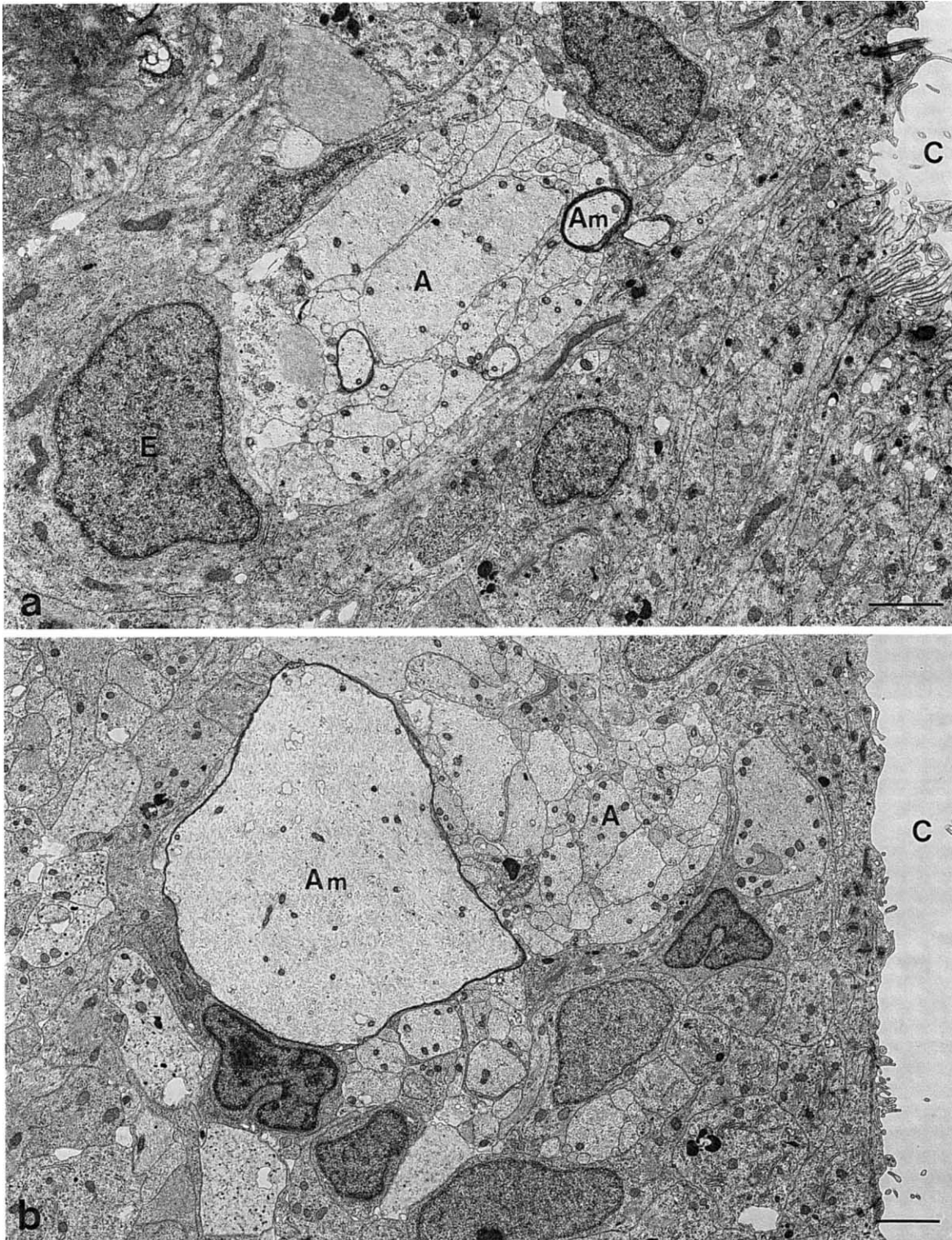


FIG. 6. Electron micrograph of the transected spinal cord 26 days after the operation. The severed stumps of the transected spinal cord are already connected with the fragile, regenerated nervous tissue. (a) Many bundles of myelinated and unmyelinated axons are localized in the ependymal layer and are surrounded by the elongated cell bodies of ependymal cells at the caudal part in the regenerated tissue of the spinal cord. Am: myelinated axon, A: unmyelinated axon, E: ependymal cell, C: central canal. Bar=2  $\mu$ m. (b) Numerous bundles of regenerated axons are seen among the ependymal and astroglial cytoplasmic processes at the rostral part in the regenerated tissue of the spinal cord. Am: myelinated axon, A: unmyelinated axon, C: central canal. Bar=2  $\mu$ m.



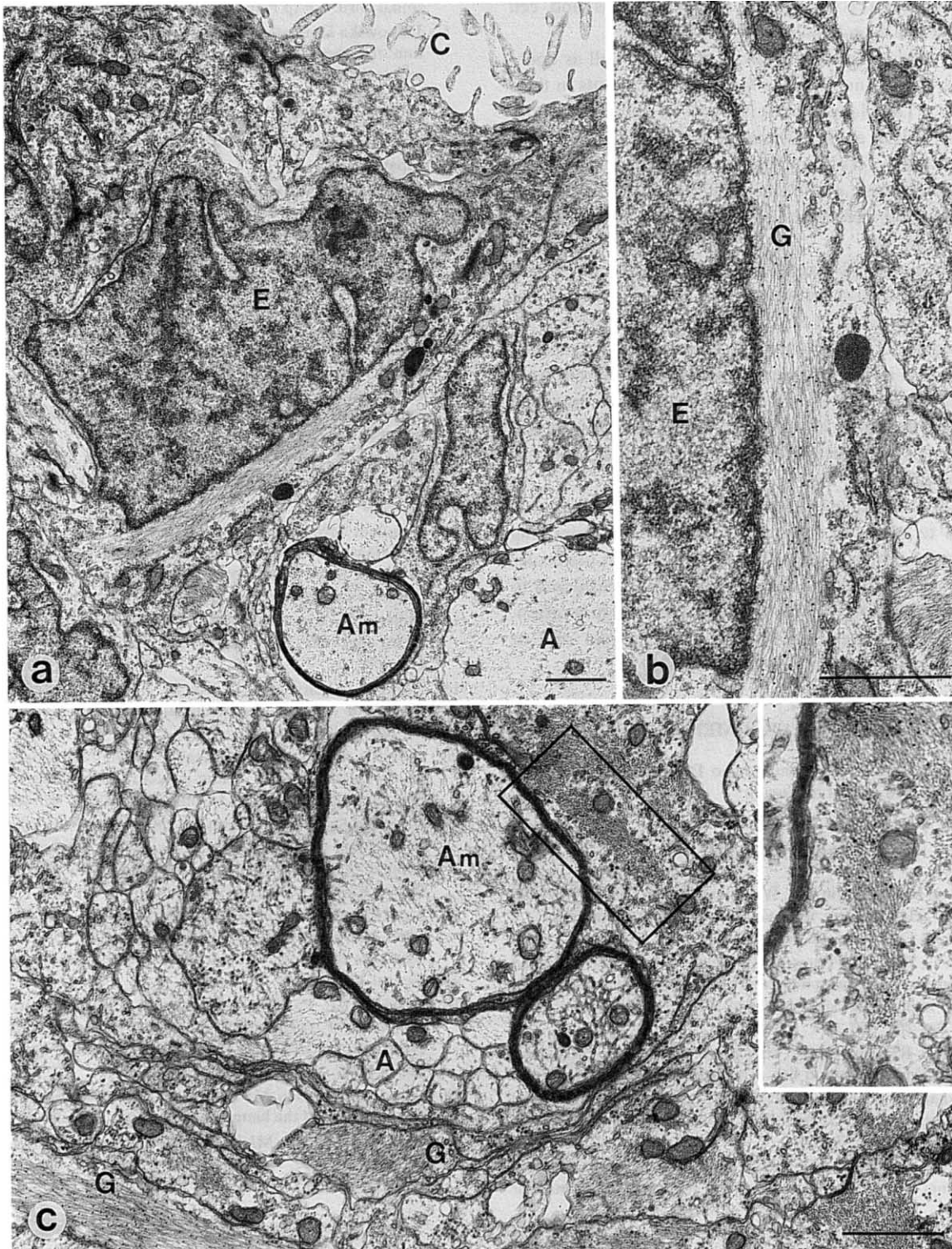


FIG. 7. Electron microscopic immunohistochemistry for GFAP in a regenerated spinal cord 27 days after the operation. The transected portion is fused with the fragile, regenerated nervous tissue. (a) Regenerating myelinated axons and unmyelinated axons are observed to be in contact with the ependymal cells. Am: myelinated axon, A: unmyelinated axon, E: ependymal cell, C: central canal. Bar=1  $\mu$ m. (b) Higher magnification of the cell body of an ependymal cell. A lot of GFAP-positive intermediate filaments are seen only in the ependymal cell cytoplasm. G: GFAP immunoreactive intermediate filaments. Bar=1  $\mu$ m. (c) Bundles of regenerating axons are observed among GFAP-positive astroglial processes locating in the deeper portion of the spinal cord. Inset; GFAP-positive intermediate filaments in the astroglial cytoplasm. Am: myelinated axon, A: unmyelinated axon, G: GFAP immunoreactive intermediate filaments. Bar=1  $\mu$ m.



observed in direct contact with the cell bodies and cell processes of the ependymal and astroglial cells.

In the carp spinal cord, astroglial cells as well as ependymal cells possess numerous intermediate filaments in their cytoplasm. The filaments in both types of cells were clearly positive for GFAP at the immunohistochemistry in electron microscope level. This suggests that the ependymal cells have the same nature as the astroglial cells in the carp spinal cord as reported previously by Onteniente *et al.*[16] and Anderson *et al.* [1].

The processes of ependymal and astroglial cells have common fine structural characteristics. Both of them do not impede the extension of the axons. Thus, probably, the surface property of astroglial processes is similar to that of the ependymal cells in the carp spinal cord, and is different from that of stellate astroglia in higher mammals, where astroglial processes are the major impediment for axonal regeneration. This may cause the successive regeneration of long axons in the carp spinal cord.

Our experimental model of carp spinal cord regeneration enables us to obtain a substantial amount of regenerating nervous tissue, which is large enough to carry out molecular biological analysis of regeneration. It is also considered to be a useful model for further studies of axonal regeneration, such as cell-cell interaction between ependymal and/or astroglial cells and regenerating axons.

#### ACKNOWLEDGMENTS

We wish to express our gratitude to Dr. Hisao Fujita for his valuable advice and critical discussion.

#### REFERENCES

- Anderson MJ, Swanson KA, Waxman SG, Eng LF(1984) Glial fibrillary acidic protein in regenerating teleost spinal cord. *J Histochem Cytochem* 31: 1099-1106
- Bodega G, Suarez I, Fernandez B.(1990) Radial astrocytes and ependymocytes in the spinal cord of the adult toad (*Bufo bufo* L.): an immunohistochemical and ultrastructural study. *Cell Tissue Res* 260: 307-314
- Coggeshall RE, Birse SG, Youngblood CS (1982) Recovery from spinal transection in fish. *Neurosci Lett* 32: 259-264
- Coggeshall RE, Youngblood CS (1983) Recovery from spinal transection in fish : regrowth of axons past the transection. *Neurosci Lett* 38: 227-231
- Davis BM, Duffy MT, Simpson Jr SB (1989) Bulbosplinal and intraspinal connections in normal and regenerated salamander spinal cord. *Exp Neurol* 103: 41-51
- Jankowska E, Rastad J, Westman J (1976) Intracellular application of horseradish peroxidase and its light and electron microscopical appearance in spinocervical tract cells. *Brain Res* 105: 557-562
- Kawaguchi S (1986) Reconstruction of central nervous circuitries by axonal regeneration. *Brain and Nerve* 38: 457-468 (In Japanese)
- Keefer DA (1978) Horseradish peroxidase as a retrogradely-transported, detailed dendritic marker. *Brain Res* 140: 15-32
- LaVail JH, LaVail MM (1978) The retrograde intraaxonal transport of horseradish peroxidase in the chick visual system: a light and electron microscopic study. *J Comp Neurol* 157: 303-357
- Liuzzi FJ, Lasek RJ (1987) Astrocytes block axonal regeneration in mammals by activating the physiological stop pathway. *Science* 237: 642-645
- Lowenger E, Levine RL (1988) Studies of the early stages of optic axon regeneration in the goldfish. *J Comp Neurol* 279: 319-330
- McQuarrie IG, Grafstein B (1981) Effect of conditioning lesion on optic nerve regeneration in goldfish. *Brain Res* 216: 253-264
- Mesulam MM (1987) Tetramethyl benzidine for horseradish peroxidase neurohistochemistry : a non-carcinogenic blue reaction product with superior sensitivity for visualizing neural afferents and efferents. *J histochem Cytochem* 26: 106-117
- Miller RH, Liuzzi FJ (1986) Regional specialization of the radial glial cells of the adult frog spinal cord. *J Neurocytol* 15: 187-196
- Nanci A, Mazariegos M, Fortin M (1992) The use of osmicated tissues for lowicryl K4M embedding. *J Histochem Cytochem* 40: 869-874
- Onteniente B, Kimura H, Maeda T (1983) Comparative study of the glial fibrillary acidic protein in vertebrates by PAP immunohistochemistry. *J Comp Neurol* 215: 427-436
- Reier PJ, Stensaas LJ, Guth L (1983) The astrocytic scar as an impediment to regeneration in the central nervous system. In "Spinal Cord Reconstruction" Ed by CC Kao, RP Bunge, PJ Reier, Raven Press, New York, pp 163-195
- Sasaki H, Mannen H (1981) Morphological analysis of astrocytes in bullfrog (*Rana catesbeiana*) spinal cord with special reference to the site of attachment of their processes. *J comp Neurol* 198: 13-35
- Stensaas LJ, Partlow LM, Burgess PR, Horch KW (1987) Inhibition of regeneration: the ultrastructure of reactive astrocytes and abortive axon terminals in the transition zone of the dorsal root. *Prog Brain Res* 71: 457-468
- Wood MR, Cohen MJ (1979) Synaptic regeneration in identified neurons of the lamprey spinal cord. *Science* 206: 344-347
- Wood MR, Cohen MJ (1981) Synaptic regeneration and glial reactions in the transected spinal cord of the lamprey. *J Neurocytol* 10: 57-79