



Blood collection from the external jugular vein of *Oryctolagus cuniculus algirus* sedated with midazolam: live sampling of a subspecies at risk

Authors: Abade dos Santos, Fabio A., Carvalho, Carina L., Peleteiro, M. Conceição, Gabriel, Sofia Isabel, Patrício, Rui, et al.

Source: Wildlife Biology, 2019(1) : 1-10

Published By: Nordic Board for Wildlife Research

URL: <https://doi.org/10.2981/wlb.00588>

BioOne Complete (complete.BioOne.org) is a full-text database of 200 subscribed and open-access titles in the biological, ecological, and environmental sciences published by nonprofit societies, associations, museums, institutions, and presses.

Your use of this PDF, the BioOne Complete website, and all posted and associated content indicates your acceptance of BioOne's Terms of Use, available at www.bioone.org/terms-of-use.

Usage of BioOne Complete content is strictly limited to personal, educational, and non - commercial use. Commercial inquiries or rights and permissions requests should be directed to the individual publisher as copyright holder.

BioOne sees sustainable scholarly publishing as an inherently collaborative enterprise connecting authors, nonprofit publishers, academic institutions, research libraries, and research funders in the common goal of maximizing access to critical research.

Blood collection from the external jugular vein of *Oryctolagus cuniculus algirus* sedated with midazolam: live sampling of a subspecies at risk

Fabio A. Abade dos Santos, Carina L. Carvalho, M. Conceição Peleteiro, Sofia Isabel Gabriel, Rui Patrício, João Carvalho, Mónica V. Cunha and Margarida D. Duarte

F. A. Abade dos Santos, (<https://orcid.org/0000-0002-0696-7322>) ✉ (faas@fmv.ulisboa.pt) and M. C. Peleteiro, Centro de Investigação Interdisciplinar em Sanidade Animal (CIISA), Faculdade de Medicina Veterinária, Univ. de Lisboa, Av. da Universidade Técnica, PT-1300-477 Lisbon, Portugal. – FAAS, C. Carvalho, M. V. Cunha and M. D. Duarte, Inst. Nacional de Investigação Agrária e Veterinária (INIAV), Laboratório de Virologia, Oeiras, Portugal. – S. I. Gabriel, CESAM – Centro de Estudos do Ambiente e do Mar, Depto de Biologia Animal, Faculdade de Ciências da Univ. de Lisboa, Lisbon, Portugal. – R. Patrício, AllPets-Clínica Veterinária de Tires, Lisbon, Portugal. – J. Carvalho, Associação Nacional de Proprietários e Rurais, Gestão Cínética e Biodiversidade (ANPC), Lisbon, Portugal.

In the last decades, the European wild rabbit, particularly the *Oryctolagus cuniculus algirus*, a keystone species in the Iberian Peninsula ecosystems, declined severely, raising concerns from the wildlife authorities. The hunting calendar in Portugal limits sampling collection to a narrow window of few months annually. Nevertheless, governmental wildlife protection laws allow live rabbit sampling for population and sanitary evaluations. The aim of this study is to adjust blood collection protocols from the external jugular vein (EJV) described for domestic rabbits to the wild rabbit. Collection of peripheral blood is problematic in the wild rabbit given its small body size and the reduced calibre of vessels but mostly its nervous disposition and fragility. We describe in detail a procedure for EJV blood collection in 30 wild rabbits after sedation with midazolam. Emphasis is given to protocol adjustments for wild rabbit. Heart rate, respiratory rate and body temperature were assessed before sedation, after sedation but before collection and after blood collection. Sedation onset took on mean (SD) 8 ± 2 min. The technique allowed the collection at least 1 ml of blood, a satisfactory volume for routine laboratory testing. The differences observed in heart and respiratory rates before and after blood collection were not statistically significant, indicating that no cardiorespiratory interference occurred due to venepuncture. Recovery from sedation took on mean (SD) 17 ± 2 min. All animals were set free during the first hour after blood collection. This work aims to demonstrate that blood collection under sedation is a safe and feasible procedure in wild rabbits when practiced by experienced veterinarians. At no time, whatsoever, was the physiological homeostasis at risk and no injuries were inflicted on the animals. To our knowledge this report constitutes the first guided description of blood collection from the EJV in sedated *O. c. algirus* and the first collection of physiological parameters measured under different conditions.

Keywords: blood collection, external jugular vein, *Oryctolagus cuniculus*, sampling live animals, sanitary surveillance, venepuncture, wild rabbit

The European wild rabbit *Oryctolagus cuniculus* (Linnaeus 1758) is a small herbivorous mammal belonging to the *Leporidae* family of the *Lagomorpha* order whose main morphologic, biologic and physiologic characteristics are summarized in Table 1.

The wild rabbit is a keystone species in Mediterranean ecosystems of Iberian Peninsula in which the preservation of many vulnerable and threatened mammals and bird

species depend on. Moreover, the rabbit has an important role in habitat modulation, due to its digging activity, selective plant ingestion, seed dispersal and soil fertilization, supporting the growth of typical vegetation (Willott et al. 2000, Virgós et al. 2005) and indirectly contributing for the diversity of soil invertebrate community.

In 2008, the International Union for Conservation of Nature (IUCN) rated *O. cuniculus* species as near threatened (NT), following its progressive decline in Europe since 1950, reaching 95% reductions. The most important factors behind the wild rabbit decline are the loss of habitat due to fragmentation and intensive farming, anthropogenic activities (Ward 2005) and the emergence of viral diseases in the 20th century (Delibes et al. 2000). Confinement of

This work is licensed under the terms of a Creative Commons Attribution 4.0 International License (CC-BY) <<http://creativecommons.org/licenses/by/4.0/>>. The license permits use, distribution and reproduction in any medium, provided the original work is properly cited.

Table 1. Morphological, biological and physiological data from wild rabbits.

Parameters		Available information	References
Morphological	head–body length (adults)	34–50 mm	Macdonald and Barrett 1993 La Fuente 1993, Gálvez-Bravo 2017
	rabbit fur	mixed brown-grey fur coat, of yellowish tones in the occipital region and legs, and whitish belly and white inner short tail	
	others	black lateral eyes and long ears though smaller than those of hares. Strong hind legs are more developed than the front ones, allowing them to sprint in jumps and zigzags	
Biological	reproduction season	annual (depending of clime and resource availability)	Bell and Webb 1991
	litter size	3–6 kittens, which leave the warren in under a month [§]	Gibb and Williams 1990
	sexual maturity	♂ 4 months; ♀ 3.5 months	Macdonald and Barrett 1993
	lifespan	♂ max 8.7 years; ♀ max 7.7 years	Macdonald and Barrett 1993, Von Holst et al. 1999
Physiological	body temperature	38.5–39.5°C (101.3–103.1°F)	Patrick et al. 1994
	fasting metabolic rate	750 kcal m ⁻² body surface area	Patrick et al. 1994
	respiratory rate	30–60 breaths per minute*	O'Malley 2005
	heart rate	180–250 per minute	O'Malley 2005
	water intake per day	50–150 ml kg ⁻¹	Cizek 1961
	urine	alkaline (pH 7.6–8.8), specific density: 1.003–1.036, normally cloudy	Patrick et al. 1994

[§] 3/4 of young rabbits are killed by predators before they establish a territory (Gibb 1990, Angulo 2004). Annual mortality of general population was 30% in a studied island (Macdonald and Barrett 1993).

* At rest, rabbit breath mainly using muscular contractions of the diaphragm, with reduced movements of the rib cage. Artificial respiration can be provided moving the rabbit from a head-up to head-down position 45 times per minute (Patrick et al. 1994).

O. cuniculus algirus subspecies to a few restricted geographic locations (including the south–west of the Iberian Peninsula, the Atlantic islands and Morocco) makes its surveillance and recovery even more urgent.

Reverting the recent abrupt decrease of wild rabbit populations due to highly virulent pathogens, such as rabbit haemorrhagic disease virus (RHDV) and myxoma virus (MYXV), requires disease surveillance programmes to assist and support sustainable management of this wild species. Like Myxomatosis, Rabbit haemorrhagic disease is endemic in some countries, including Portugal, occurring in the mainland (Abrantes et al. 2013), autonomous regions (Duarte et al. 2015, Carvalho et al. 2017) and the islands such as the small Berlengas archipelago (Abade dos Santos et al. 2017). Regarding our team, the need for the development a blood collection protocol emerged/was identified during a study conducted in the Berlengas archipelago to investigate haemoparasites and viruses in the local rabbits (Abade dos Santos et al. 2017).

Due to the difficulty in capturing and sampling live specimens without causing great stress, monitoring of wild rabbit populations is usually carried out in biological samples collected from legally hunted rabbits' cadavers. Collections are therefore limited to the hunting season, or dependent on dead animals found in passive surveillance. Furthermore, in areas where the rabbit populations are extremely low, hunting is often suspended to accelerate recovery, precluding sampling.

However, longitudinal serological surveys have proven crucial to evaluate wild rabbit population's immune status as well as to provide a dynamic view on the pathogen–host evolution and population equilibrium. Blood samples allow not only serologic investigations but also culture and/or direct examination for bacteria, viruses and some parasites.

In domestic rabbits, selection of the blood collection method depends on the animals' behaviour, amount of blood

needed, frequency of sampling and whether the animal's survival is required or not. Blood can be withdrawn from the marginal ear veins, central ear artery, cephalic vein and lateral saphenous vein. Domestic rabbits have also large paired external jugular veins (EJV, vena jugularis externa), which are often the preferred venepuncture site under sedation or when a larger amount of blood is required (Nelson et al. 2010). The external jugular vein is formed behind the angle of the mandible, passing backward in a superficial position to the superior thoracic aperture (Nelson et al. 2010), and the work zone for blood sampling is the ventral surface of the neck.

Despite the animal's clinical condition must always be considered, a general rule of thumb is that it is safe to take up a maximum of 1 ml per 100 g bodyweight (Ramer et al. 1999), i.e. 1% (v/w) of bodyweight. All non-terminal blood collection carried out without fluids replacement is limited up to 10% of total circulating blood volume in healthy, normal, adult animals on a single occasion and collection may be repeated only each three to four week. Deep sedation of rabbits is sometimes required for adequate restraint, evaluation and minor procedures (Cantwell 2001).

Contrarily to domestic rabbits, blood sampling in wild rabbits poses serious difficulties due to the extremely nervous nature of the species and innate instinctual fear of humans, causing great stress that may lead to the onset of diseases or even to sudden death (Mullan and Saunders 2018). In wild rabbits, it is very important that handling stress and pain inflicted during blood collection are reduced to a minimum. In addition, the small size of wild rabbit and consequent reduced vessel diameter further complicates peripheral blood collection. The cephalic veins are difficult to locate and hold off and while the lateral saphenous vein is easier to locate it has a very small diameter, making the collection of an adequate blood sample difficult (Graham 2006). Furthermore, hematoma, bruising, vessel thrombosis and skin sloughing

can also occur due to the vessels reduced diameter and the use of ear veins is not recommended in this species (Graham 2006). In juveniles, the blood sampling technique is even harder to perform.

When collecting a blood sample from wild rabbits, cautions must be taken regarding the animal as well as the handler. Clinical fragilities inherent to wild rabbits include risk of heart attack, dehydration and bone fracture. The knowledge of the physiological parameters of this species is critical (Table 1). As to the handler, when the animal is picked up without the appropriate support of the body and hind-quarters, their very sharp claws may inflict painful scratches which easily become infected (Varga 2014). Nevertheless, claws should not be cut off as they are important in rabbits' movements and digging ability. Bites can equally result in skin and soft tissue infection.

Several parenteral anaesthetic protocols for rabbits and rodents, either for research or in pet clinics, are described in literature (Cantwell 2001). Furthermore, many anaesthetics dosages referenced for the rabbit have been developed for use in the laboratory rabbit which is, generally, a robust animal that has been bred to be pathogen free (Borkowski and Karas 1999).

The available anaesthetic protocols, usually designed for clinical purposes, need to be adapted to wildlife/free-living animals. Benzodiazepines, including diazepam, midazolam and zolazepam, are muscle relaxants that act centrally, producing excellent relaxation, reducing muscle spasms and spasticity (Muir et al. 2000), while not inducing muscle paralysis (Flecknell 1987). Sedation induced by this group of drugs is very marked in rabbits and rodents (Flecknell 1987) despite not producing a true anaesthetic state, as awareness persists with relaxation even at high dosages, or any analgesic effect.

Midazolam causes minimal hemodynamic and respiratory changes and is often chosen over diazepam for its water solubility which allows mixing it with other water-soluble substances in a single syringe (Henke et al. 2005). It is also more effective than diazepam (Longley et al. 2008) and has a shorter duration of action (Flecknell 1984). For diagnostic procedures, the use of intramuscular or intravenous midazolam has been recommended due to its short acting sedation (Ramer et al. 1999).

To our knowledge, and from the published bibliography, collecting blood from the EJV from wild rabbits is not used routinely because requires experience, training and a solid knowledge of the anatomy and relative dimensions of the wild rabbit. On the other hand, this work somewhat demystifies the idea that sedation, handling and blood sample of large volumes in small mammals is risky in the field and reinforces the importance of longitudinal study of populations of small mammals, many of them at risk of extinction.

In this work, we describe an EJV blood collection procedure in wild rabbits, based on the protocol described by Nelson et al. (2010) and taking into account the idiosyncrasies of this wild species, under sedation with midazolam, which has proven to be a safe and effective technique for blood sampling in this species under field conditions and allows the collection of a substantially high volume of blood without clotting or haemolysis.

Material and methods

Animals

A total of thirty wild rabbits (12 males and 18 females; 16 adults and 14 juveniles) were analysed in this study. Pregnant females were not used. Animals were captured in Aldeia Gavinha (n=14) and Quinta dos Penedinhos (n=9), two reproduction centres for *Oryctolagus cuniculus algirus* near Lisbon, and in two hunting reserves in Alentejo, Herdade das Romeiras (n=2) and Vila Nova de Mil Fontes (n=5).

The study took place between December 2017 and February 2018 and was carried out within the scope of the Action Plan for the Control of the rabbit haemorrhagic disease (Dispatch no. 4757/2017 of 31 May from the Portuguese Ministry of Agriculture, Forests and Rural Development) and +Coelho project funded by Fundo Florestal Permanente.

No animals were sacrificed for the purposes of this specific study and all procedures were performed and monitored by veterinarians. The data of all animals will be available from the Dryad Digital Repository.

Capture method

The 23 wild rabbits bred in semi-captivity, originating from Lisbon, were caught with painless lever traps, using vegetables and fruit as bait. Traps were checked every 2 h during the day and every 7 h at night. After capture, the animals were kept at maximum 8 h at constant temperature (20°C) and humidity (65%) as well as in the recommended area per animal described in the literature (Buil et al. 2004) with good ventilation. The five freedom rules recommended by the World Veterinary Association (Seamer 1993), were followed as much as possible, namely water and food ad libitum, no infliction of unnecessary pain and stress, and release to nature as fast as possible. Animals originating from the same colony were maintained in groups with only one male per cage and separated according to age. All boxes and bags were used by a group and one animal respectively, on each day of procedure. At the end, boxes were washed with pressurized and warmed water and then sprayed with 5% sodium hypochlorite for decontamination and used after a minimum of two weeks. The bags were washed at 80°C. Animals from the same colony were kept in the same box during the procedure, after clinical evaluation to ensure that they were not sick. The issue of transmission of rabbit haemorrhagic disease virus (RHDV2) or myxomatosis was considered of minor importance since all animals used were vaccinated.

The five rabbits originating from the hunting reserve in Vila Nova de Milfontes were captured with ferrets, according to the Portuguese legislation (Decree Law no. 202/2004 of 18-08-2004, article 85) and kept in the same conditions. Between data assessments, animals were kept in suspended dark fabric bags, allowing them to keep calm and breathe normally.

Clinical evaluation

Animals were manipulated in situ. The animals were handled using clothing that covered the sleeves to minimize the risk of bite and scratch. Cotton gloves covered by nitrile or latex

gloves were used, the latter being changed between different animals.

The rabbits' physical condition was classified as physical status I, according to the American Society of Anaesthesiology criteria (ASA).

Animals were weighed (with a precision of 50 g) to calculate the sedative dose, and their physical condition and body length were assessed. Other morphological parameters (head, ear and tarsus length) were also registered. Given the good body condition of all animals, those weighing less than 900 g were considered juveniles and those with equal or greater weight considered adults.

Heart rate was measured with a pulse oximeter and ECG apparatus (monitor Cygnus 80E vet) designed for veterinary use. The pulse oximeter probe was placed on the lip and the ECG clips in the left and right anterior limbs and left posterior limb according to manufacturer's instructions. Shallow ECG clips were used to avoid skin damage and to minimize animal disturbance. A 70% ethanol spray was used to deflect the hair and remove the oil from the skin allowing full contact with the electrodes. Respiratory rate was determined by observation of the animals' thoracic movements and by auscultation with a stethoscope. Body temperature was measured with a digital thermometer (with a precision of $\pm 0.01^\circ\text{C}$) on the rectal mucosa.

Parameters were taken before sedation (BS), after sedation and before collection (BC) and after collection (AC). Time of sedation onset and of recovery were registered.

Sedation protocol

Because wild rabbits are easily stressed and small, therefore more difficult to contain and bleed, both juveniles and adults were sedated. Sedation was performed by intramuscular (longissimus and iliocostalis muscles) administration of midazolam at a dosage of 1 mg kg^{-1} , a protocol that provides moderate sedation.

A specific antagonist, flumazenil, was available to reversed sedation if necessary at a dose of $0.01\text{--}0.1\text{ mg kg}^{-1}$ IV (Flecknell 1987, Gargiulo et al. 2012).

The method we used to contain the animal was adapted to the idiosyncrasies of wild rabbit protocol described by Nelson et al. (2010). Approaching the rabbit inside the transport boxes was made slowly and precisely. The handler grasped the rabbit through the skin of the back immediately behind the neck (Fig. 1A). A good area of skin was held with the dominant hand to immobilize the animal allowing sedative administration.

After the onset of sedation, the handling approach was the same described above. With the non-dominant hand, the lumbar region of the animal is secured to prevent vertebral injuries and minimize limb movements (Fig. 1A). With a smooth and continuous movement, the animal's body was inverted to a lateral (Fig. 1B) and finally dorsal decubitus position without ever removing the support from the lumbar and cervical zones (Fig. 1C). The hind limbs of the animal were kept between the body and the medial face of the restrainers' arm (Fig. 1D).

Relaxed members (Fig. 1B) indicated that the animal was well restrained and stress-free. The pressure of the dominant hand on the skin of the back is never released so that the

animal does not have the impetus to try to dodge. This pressure, as well as pressure under the abdomen and hind limbs, must be especially firm during venepuncture.

Venepuncture procedure

A rubber elastic (Fig. 1F) was placed caudally to the venipuncture site, precisely in the entrance of the chest, thus promoting venous distension of the EJV allowing a better visualization. The elastic was positioned by the person holding the animal, or by a third person, to apply pressure laterally, only on the selected EJV avoiding pressuring the trachea. The EJV veins appear blue in colour and are found around the caudal end of the mandible (Fig. 1E).

A sprayer with 70% ethanol was used to clean the skin and evidence EJV. Considering the size of the rabbits utilized in this study and their individual characteristics, needles with $25\text{G} \times 5/8''$ ($0.5 \times 16\text{ mm}$) or $26\text{G} \times 1/2''$ ($0.45 \times 12\text{ mm}$) were used as well as a 1 mL syringe. No more than 3–4 mm of needle was inserted in the cephalocaudal direction (front to back) into the blood vessel, as recommended by Parasuraman et al. (2010), and blood slowly withdrawn to avoid the collapse of the vessels (Fig. 1F). To facilitate the insertion of the needle into the vein the needle can be folded about $5\text{--}10^\circ$ using the needle cap. To facilitate/enable a better visualization of the EJV, or whenever blood sampling is to be repeated, clipping the fur on the area may be recommended (Fig. 1E). All animals used in this study were not sheared except the one used for demonstrating the procedure as shown in Fig. 1E.

Finger pressure was applied for 1–3 min after the needle's removal to stop bleeding (Parasuraman et al. 2010, Boyle 2016). After the procedure, the area was disinfected with a 5% chlorhexidine solution. To avoid unwanted cooling of the animals, we developed a thermostat-regulated infrared lamp heating box with an internal temperature of 20°C , where animals could recover their body temperature faster, whenever necessary (Fig. 2). Animals were released into their source colony when the effect of sedation was no longer evident.

For monitoring the animals' recovery, relying on individual identification, the rabbits originating from Aldeia Gavinha (District of Torres Vedras) were marked with an inactivated calcium carbonate solution at both their ear tips, on medial and lateral sides. This compound is inert to the animal's skin, allowing temporary marking visualization in both coloured and black and white photographs, disappearing over time.

For monitorization of a subset of wild rabbits (those caught at reproduction centers), night (with black light) and day monitoring cameras were installed, and the animals were observed for five days. Wheat and corn were scattered next to the cameras to attract the animals.

Genetic assessment

In order to assess the taxonomic status of the animals obtained during this study from the different sampling origins and confirm they belonged to the subspecies *O. c. algirus*, a genetic analysis was carried out, allowing the distinction from the subspecies *O. c. cuniculus* (including domestic breeds).

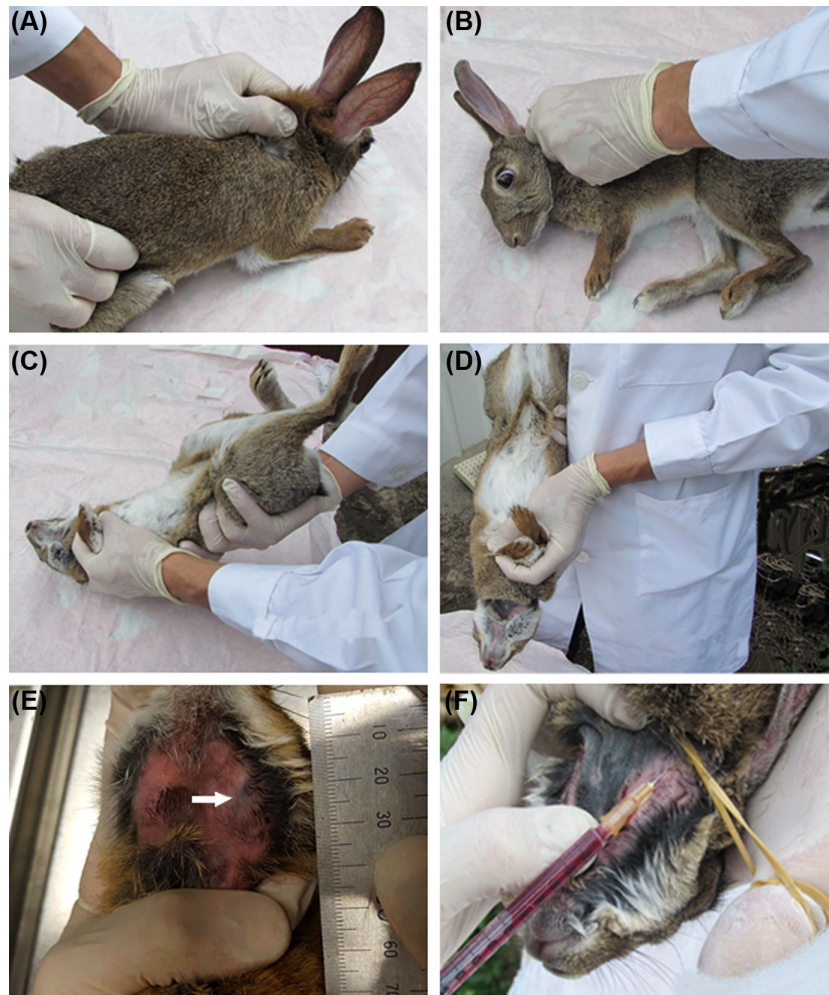

Figure 1. Sequence of procedures for containment and presentation of the animal for blood collection. First approach (A), lateral decubitus (B), dorsal decubitus (C), presentation of the animal for blood collection (D), visualization of external jugular vein (E) and blood collection (F). The arrow indicates the beginning of the external jugular vein. Cranially at this point are the linguofacial and retromandibular veins.

During handling, a small ear biopsy was obtained from a subset of the captured rabbits ($n = 12$) and kept in 96% ethanol until further analysis. Additionally, samples from five domestic rabbits were obtained for comparative purposes. Genomic DNA was extracted using the EZNA DNA purification kit (Omega) following the manufacturer's guidelines. Two molecular markers were amplified via PCR to infer the taxonomic status of the analysed rabbits: the mitochondrial control region and the first intron of the coagulation factor IX (F9) gene (X chromosome). Obtained sequences were compared with those published in public databases for subspecies inference. The details of the protocol are not revealed in this study because they are not within its scope.

Statistical analysis

Initially, an exploratory analysis of the data was performed using syntax Proc univariate, Proc means and Proc freq of SAS 9.4 software (2013) in order to characterize the different variables included/considered in this study. The research of extreme outliers was investigated, whenever they were below the lower outer fence or above the upper outer

fence. Extreme outliers were only found in the temperature measurement and were not removed due to small sample size and clustering. Values biologically non-logical (e.g. heart or



Figure 2. Recovery of body temperature in a box with infrared light heating regulated by thermostat.

respiratory rate outside the physiologically possible range) were also searched for but were not found. The data for the response variables (heart rate, respiratory rate and temperature) was assessed for normality by observing the QQ plots and running the Shapiro–Wilk normality test. The heart and respiratory rates showed no normal distribution ($p < 0.05$) so logarithmic transformation of these data was performed. To evaluate the evolution of the response variables over the three measurement moments: 1) before sedation (BS), 2) after sedation but prior venepuncture (BC) and 3) after venepuncture (AC), the SAS 9.4 PROC MIXED was used. A confidence interval of 95% (p -value < 0.05 significant) was considered.

Results

Morphological parameters

The mean and standard deviations values for the morphological parameters collected from all animals (weight and body length, as well as head, ear and tarsus dimensions) are shown in Table 2. The p -values were obtained with t -test for equality of means after confirmation of equality of variances assumed by the Levene test.

Onset and recovery of sedation

The mean time for the onset of sedation occurred within 7.6 ± 1.9 min after intramuscular administration of midazolam, as determined by the reaction to handling (calmer and more permissive). There was no reaction to sedative administration.

On mean \pm SD, 17.3 ± 2.2 min after sedation, all animals had recovered fully from sedation without the need of antagonist use. Animals were considered recovered from sedation when there was an escape reaction to handling. Altogether, restraint, disinfection and blood collection procedure took an mean (SD) 45 ± 20.5 s.

Blood sampling

The sedation and handling method described here allowed the collection of 1 ml of blood in all of animals, without clot formation. There were no sudden movements of animals that jeopardized their integrity and no major haemorrhage or hematomas were seen. The visualization of the vein was performed with relative ease and the collection performed without need of repetition of the puncture.

Physiological parameters variation

t -test for comparing group means did not reveal differences between the juvenile and adult physiological parameters, except for respiratory rate after venepuncture ($p < 0.05$). Because the value of F was smaller and significantly superior to 0.05, equal variance of data between the two groups may be assumed. So, data from the two groups of animals (juvenile and adults) were analysed together for greater statistical robustness.

The heart rate, respiratory rate and temperature were generally higher in the group of animals captured with ferrets (Table 3), although the statistical significance was not tested given the of the subsample. As expected, heart rate decreased with sedation in mean 45 beats per minute ($p < 0.0001$) but remained stable during the venepuncture procedure. On mean, after venepuncture, the heart rate decreased in adults by 6–57 bpm, while in juveniles a slight increase of this parameter was observed. In fact, 15 animals (50% of the sample) showed an increase in heart rate during the venepuncture procedure. Of these, 40% were adults and 60% juveniles.

The same was not observed for respiratory rate and rectal temperature. Respiratory rate remained relatively stable throughout the whole procedure although there was a decrease on the mean values obtained at the beginning and at the end of the method of 7 bpm ($p = 0.0066$). Neither sedation nor venepuncture caused statistically significant changes to the baseline respiratory rate. The variation registered upon sedation ranged between a reduction of 32 bpm to an increase of 24 bpm. Increase in the respiratory rate was observed in 10 animals (30% adults and 70% juveniles). Regarding the venepuncture, variation in the respiratory rate ranged between a reduction of 40 bpm to an increase of 12 bpm. Increase in the respiratory rate was only observed in seven animals.

Rectal temperature decreased gradually throughout the whole procedure ($p < 0.05$), with a mean difference between BS and BC of -0.8 ± 0.9 and between BC and AC of $-0.6 \pm 0.7^\circ\text{C}$.

Considering all the procedure, minimum and maximum values observed for heart rate (beats per minute) were 72 and 207, for respiratory rate (breaths per minute) 28 and 88 and for temperature (Celsius grades) 34.3°C and 40.2°C , respectively. All these changes are shown in Table 4 and Fig. 3.

Neither morbidity nor mortality were observed by the persons who monitor the areas where the animals were captured and released, including 14 animals that were camera monitored for five days (Fig. 4). Calcium oxide labeling revealed no discomfort from the animals during application

Table 2. Morphological parameters of the adult and juvenile rabbits used in this study. The values presented are the mean \pm SD. Same letters and different letters indicate, respectively, respectively indicate the absence and existence of a statistically significant differences.

Morphological parameters	Juveniles (n = 14)	Adults (n = 16)	p-value	
Weight	568 ± 128^a	956 ± 124^b	0.000	g
Body length	22.6 ± 1.9^a	26.3 ± 2.5^b	0.000	cm
Head length	7.3 ± 0.8^a	8.1 ± 0.6^b	0.002	
Ear length	7.5 ± 0.5^a	7.8 ± 0.6^a	0.064	
Tarsus length	3.9 ± 0.3^a	4.5 ± 0.6^b	0.001	

Table 3. Comparison of the clinical parameters according to the capture method used.

Clinical parameters		Mean \pm SD
Ferrets (n=5)	heart rate	201 \pm 97
	respiratory rate	51 \pm 23
	rectal temperature	37.7 \pm 3.4
Trap (n=25)	heart rate	164 \pm 46
	respiratory rate	58 \pm 14
	rectal temperature	38.2 \pm 2.7

and on the following days and allowed rapid and clear identification in the chambers either day or night.

Genetic analysis

Genetic analysis confirmed that all tested rabbits (n=12, 40% of total sampling), belong to the *O. c. algirus* subspecies (results not shown).

Discussion

The technique described for EJV blood collection in apparently healthy wild rabbits *Oryctolagus cuniculus algirus* under sedation with midazolam has proven to be safe and effective for sampling relatively high volumes of blood (1 ml) in this wild species.

To correctly execute the procedure, the technician must be aware of the morphological and physiological particularities of this fragile species to minimize the associated risks.

During the procedure, keeping stress to a minimum has proven crucial for sedation effectiveness and successful venepuncture at first attempt while it is also important to prevent heart ischemia induced by coronary vasoconstriction since rabbits have limited collateral coronary circulation (Quesenberry and Carpenter 2012).

Also, care was taken to avoid injuring, particularly bone fractures. Vertebral fracture, usually observed at the seventh lumbar vertebra with spinal cord damage, can occur if the animals are not held securely when picked up (Brewer and Cruise 1994). More stressed rabbits were carried with their head under the handler's arm to minimize stress by covering the eyes to limit vision, as recommended in literature (Graham 2006). At the time of the sedative administration, there were no signs of pain in the animals. After the onset of sedation, the animals were handled much more easily, as hind limb movements and attempts to escape were drastically reduced.

As wild rabbits' veins are extremely thin and the most peripheral ones susceptible to hematoma formation (Quesenberry and Carpenter 2012), after venepuncture and needle withdrawal, enough pressure was applied to limit hematomas. Throughout the procedure, both the handler and bleeder constantly monitored the animals' breathing pattern and the colour of the oral mucosa to guarantee proper oxygenation.

Blood collection from the EJV can stimulate the vagus nerve, resulting in heart arrhythmias that may range in severity from bradycardia to complete sinoatrial or atrioventricular block (Hegedus and Shackelford 1965). None of these events were observed during the procedures. This was confirmed by constant clinical observation of the animal and continuous electrocardiogram monitoring. To avoid vagus nerve stimulation and carotid artery laceration, the bleeder ensured that the attempts to locate the vessel, once the needle passed the skin, were done superficially, as recommended by Nelson et al. (2010).

Data obtained from our work showed that heart rates taken prior to sedation ranged between 117 and 292 bpm. There is no reference range for the wild rabbit physiological parameters in the literature. Considering the interval values described for the European rabbit (O'Malley 2005) of 180–250 bpm as a reference, some of our values detected before sedation are relatively low. This can be explained by the fear bradycardia mechanism explained below.

The large interval of heart rate observed in the animals can be explained by differences among the animals, such as environmental responses, sensibility to midazolam, initial physiologic conditions, social status, alongside others (Eisermann 1988). However, in four animals (13.3%), the heart rate increased 4–32 bpm after sedation. This can either be a result of individual higher sensibility and susceptibility to midazolam effects or higher stress due to conservation of the animals in the black bag during the sedation onset. The time considered as onset of sedation was somehow subjective, since it was based on the animal's response to restraint and general behaviour. Consequently, measurement of each physiological parameter may have taken place at different depths of sedation.

The mean increase of heart rate that we observed in juveniles can be explained by 1) different metabolic rate that can influence the pharmacokinetics of midazolam, 2) major stress that these animals are prone to at this age class, 3) individual cardiorespiratory response to the effect of benzodiazepines. Furthermore, the continued reduction in heart rate observed in the other 15 animals may also be explained by a more prolonged sedation in these rabbits.

Table 4. Physiological parameters collected from rabbits submitted to EJV venepuncture. The values of heart rate and respiratory rate are per minute and the value of rectal temperature in °C. Same letters and different letters indicate, respectively, respectively indicate the absence and existence of a statistically significant difference.

Clinical parameters	BS	BC	AC	p-value
Heart rate (mean \pm SD)	164 \pm 39 ^a	119 \pm 27 ^b	121.7 \pm 29.5 ^b	<0.0001 BC–AC=0.6
Respiratory rate (mean \pm SD)	58 \pm 13 ^a	56 \pm 15 ^{ab}	51.0 \pm 10.3 ^b	<0.0001 BS–BC=0.5 BC–AC=0.1
Rectal temperature (mean \pm SD)	38.2 \pm 1.2 ^a	37.4 \pm 1.1 ^b	36.8 \pm 1.2 ^c	<0.0001

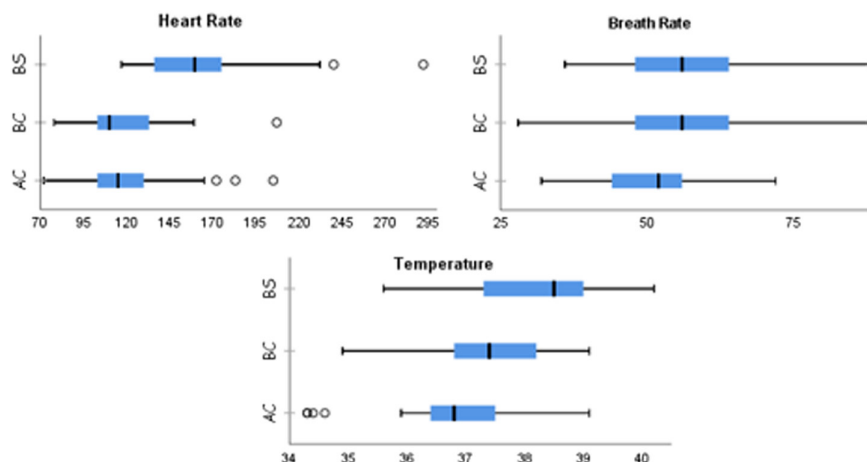


Figure 3. Boxplot graphs depicting heart rate (beats per minute on x-axis), respiratory rate (breaths per minute on x-axis) and temperature ($^{\circ}\text{C}$ on x-axis) evolution in three moments for each graph (before sedation-top; after sedation and before sampling – midline; after sedation and after sampling-down). X represents mean value. The three graphs only represent different viewing angles.

Besides heart rate variation due to sedation, fear bradycardia was also observed in some animals during manipulation. In consequence of the high levels of predation that wild rabbits are subject to, their sensory organs are highly developed. Rabbits are sensitive to catecholamines and have evolved for flight rather than fight, meaning they respond to threat passively by crouching and hiding (Smith et al. 1981). Animals that freeze in situ or drop into a burrow often show a sudden and marked fear bradycardia (Smith et al. 1981), a poorly understood, widely observed, alternate fear response. In lagomorphs, fear bradycardia appears to be due to a reduction of sympathetic activity and an increased parasympathetic activity (Smith et al. 1981). Since it occurs in atropine treated animals, it has been suggested that this type of response is, at least, partly mediated by removal of sympathetic tone (Smith and Worth 1980). Causby and Smith (1981) described a decrease in heart rate of 53% at -11.2 bpm s^{-1} in *Sylvilagus aquaticus*. Keeping our animals in boxes and bags, making

them unable to flee, probably led to the onset of this mechanism during our study.

The rectal temperature decreased since the beginning of the procedure. The reduction of this physiological parameter may have resulted from 1) a decrease in the metabolism of the animals resulting in a reduction of heat production, 2) a reduction in the muscular movements due to containment of the animal, resulting also in a lower heat production and 3) the increment of heat loss due to use of ethanol to wet the animal's fur, due to evaporation. In this context, ethanol can be replaced by another disinfectant with lower heat evaporation effects such as chlorhexidine.

The midazolam dose (1 mg kg^{-1}) used in this study was considered sufficient for the short duration of the procedure. In field conditions, without resuscitation equipment and other supporting means available, it is critical to ensure that the technique in use has negligible risks associated. When using this low dose, individual variation has a greater impact on the depth of sedation, with the animals exhibiting different responses. However, given that the safety margin between anaesthetic and lethal dose in the rabbit is narrower than in other species, and that individual variation is larger (de Vries et al. 2007), the use of this dose (1 mg kg^{-1} midazolam) is recommended.

Despite rabbits' susceptibility to overheating (Wildpro 2017), during our study a steady decrease of body temperature throughout the whole procedure was observed, possibly because most of the blood collections were made during winter (with temperatures ranging between 7°C and 20°C).

From our experience, restraint of the animal by an experienced person and correct identification and visualization of the EJV proved critical to guarantee the success of the procedure, in the first attempt. Presenting the animal correctly to the person in charge of the venepuncture was essential for visualization and less deviation of the EJV, located laterally to the midline and overlying the internal jugular vein and the carotid artery. Shaving the neck over the midtrachea cranial to the thoracic inlet (Quesenberry and Carpenter 2012) can be carried out for a better EJV visualization. If shaving must be performed, electric hair clippers with thin blades



Figure 4. Photographs taken after release of the rabbits. Left- at night (arrow indicates the marking on the ear); right-during the day (arrow indicates the marking on the ear).

(size 50, 1/1 in. [0.2mm], or 40, 1/100 in. [0.25 mm]) (Quesenberry and Carpenter 2012) must be used, because rabbit fur is very thin, and the animal's coat must be clean and dry.

The technician must also be aware that clipping off large amounts of fur or using copious quantities of disinfectant during skin preparation potentiate heat loss and the development of hypothermia, especially in small rabbits with no fat reserves (Varga 2014). Whenever the procedure is to be performed in a timely manner, and once the person performing the procedure has acquired experience, this step can be avoided to minimize stressing the animal and prevent skin exposure to hives and other aggressive plants.

For most cases, where only 0.5 ml of serum was necessary, 1 ml syringes were used given the low negative pressure on the vein. However, in adult animals, or whenever required, a 2 ml syringe can also be used. If this is the case, to minimize the vacuum exerted on the wall of the EJ, the vacuum was withdrawn from the syringe before the animal was punctured.

Whenever the first attempt to collect blood failed, the needle should be slowly removed, and the puncture site monitored for bleeding. More than two attempts should be avoided in case of bleeding due to the risk of vein collapse.

Undoubtedly, in studies involving live animals it is most important to safeguard the individual variability among the specimens. The use of wild specimens from different geographical areas, captured by different methods, with different levels of habituation to humans, leads to a multiplicity of factors that may influence the animals' physiological parameters. In addition, the unknown sanitary condition of the animals due to parasitism, or to any underlying subclinical infection, may also influence the physiological conditions of the animals.

The studies of pathologies in the species are reliant upon dead animals or stool samples found in the fields. This study represents a breakthrough in this area, by allowing in vivo biological sampling of a wild species. Access to blood sampling creates the opportunity for year-round generalised surveys, as well as the evaluation of physiological parameters (e.g. blood count and biochemistry analysis) of this species, without depending on cadavers either obtained during the hunting season or found dead.

Moreover, release of the sampled specimens is critical to avoid disturbance of recovery in diminished populations. The EJ technique allowed the collection of 1 mL of blood from both adults and juveniles. However, researchers should adhere to institution specific guidelines regarding permitted maximum volumes and frequency of blood collection. There was neither significant bruising nor any other injuries before, during or after the venepuncture procedure and sedation. Additionally, there were also no injuries inflicted on the manipulators.

Complementary procedures to assess the influence of the sedation and venipuncture on the physiology of the animal by temperature assessment and monitoring of heart and respiratory rates, were also described in this manuscript to validate the method. When complementary monitoring is no further necessary, the time needed for sedation and blood collection is drastically shortened, as well as the stress level.

The method can potentially be adapted to other species, especially to other small mammals, allowing longitudinal studies and supporting other conservation methods.

Acknowledgements – Thanks to Sebastião Miguel (Gestor Cinegético), Carlos Magro e Mário Gomes (Quinta dos Penedinhos), José Franco (Associação de Caçadores Olivais, Encarnação e Moscavide), Luís Garcia e José Silva (Associação de Caçadores das Sesmarias), Rui Alves e José Luís Coelho (Companhia das Lezírias), António Inácio e Paulo Costa (Zona de Caça Associativa da Herdade das Casas Novas) for collaboration in field work and animal capture.

Funding – Most of the field and laboratory work referred to in this manuscript was supported by the Interdisciplinary Research Centre on Animal Health, Faculty of Veterinary Medicine, University of Lisbon (CIISA, FMV-UL) (Portugal) (Project UID/CVT/00276/2013) and Fundação para a Ciência e Tecnologia (FCT) (Grant SFRH/BD/137067/2018). Laboratory work was also funded by Fundo Florestal Permanente (Government of Portugal) in the scope of the Action Plan for the Control of Rabbit Viral Haemorrhagic Disease (+COELHO, Dispatch no. 4757/2017 of 31 May). We also thank the financial support of CESAM (UID/AMB/50017/2019), FCT/MCTES through national funds.

Conflicts of interest – Funding bodies played no direct role in the design or conclusion of the study.

Author contributions – FAS: experimental design, capture of animals, sedation and blood collection, post-release monitoring. Wrote the manuscript. CC: clinical evaluation, blood collection. Wrote the manuscript. CP: revised the manuscript. SIG: genetic assessment and revised the manuscript. RPo: revised the manuscript. JC: logistics and capture of the animals with ferrets. MC: revised the manuscript. MD: data collection and analysis. Wrote and revised the manuscript.

Ethics approval and consent to participate – This article is about the use of a routine medical procedure for blood collection and was carried out within the scope of a National Plan for the Control of Rabbit Haemorrhagic Disease Virus 2 in rabbits (Dispatch no. 4757/2017 of 31 May), with the legal authorizations from the National Authority, the Instituto da Conservação da Natureza e Florestas (ICNF).

References

- Abade dos Santos, F. A. et al. 2017. Detection of rabbit Haemorrhagic disease virus 2 during the wild rabbit (*Oryctolagus cuniculus*) eradication from the Berlengas Archipelago, Portugal. – BMC Vet. Res. 13: 336.
- Abrantes, J. et al. 2013. New variant of rabbit hemorrhagic disease virus, Portugal, 2012–2013. – Emerg. Infect. Dis. 19: 1900–1902.
- Angulo, E. 2004. El Conejo, el monte mediterráneo en Andalucía. – Cons. Medio Ambient. Junta Andalucía, Sevilla.
- Bell, D.J. and Webb, N.J. 1991. Effects of climate on reproduction in the European wild rabbit (*Oryctolagus cuniculus*). – J. Zoology 224: 639–648.
- Borkowski, R. and Karas, A. Z. 1999. Sedation and anesthesia of pet rabbits. – Clin. Tech. Small Anim. Pract. 14: 44–49.
- Boyle, J. E. 2016. Crow and Walshaw's manual of clinical procedures in dogs, cats, rabbits and rodents, 4th edn. – Wiley.
- Brewer, N. and Cruise, L. 1994. Physiology. – In: Manning, P. et al. (eds), The biology of the laboratory rabbit, 2nd edn. Academic Press, pp. 63–70.
- Buil, T. et al. 2004. Critical points in the transport of commercial rabbits to slaughter in Spain that could compromise animals' welfare. – World Rabbit Sci. 12: 269–279.
- Cantwell, S. L. 2001. Ferret, rabbit and rodent anesthesia. – Vet. Clin. North Am. Exot. Anim. Pract. 4: 169–191.

- Carvalho, Silva, S. et al. 2017. Emergence of rabbit haemorrhagic disease virus 2 in the archipelago of Madeira, Portugal (2016–2017). – *Virus Genes* 53: 922–926.
- Causby, L. A. and Smith, E. N. 1981. Control of fear bradycardia in the swamp rabbit, *Sylvilagus aquaticus*. – *Comp. Biochem. Physiol. C Comp. Pharmacol.* 69: 367–370.
- Cizek, L. J. 1961. Relationship between food and water ingestion in the rabbit. – *Am. J. Physiol.* 201: 557–566.
- de Vries, H. W. et al. 2007. Four methods for general anaesthesia in the rabbit: a comparative study. – *Lab. Anim.* 22: 355–360.
- Delibes, M. et al. 2000. Action plan for the conservation of the Iberian lynx (*Lynx pardinus*) in Europe. – *Counc. Eur. Publ. Nat. Environ.* Strasbourg, Fr. 111.
- Duarte, M. et al. 2015. Rabbit haemorrhagic disease virus 2 (RHDV2) outbreak in Azores: disclosure of common genetic markers and phylogenetic segregation within the European strains. – *Infect. Genet. Evol.* 35: 163–171.
- Eisermann, K. 1988. Seasonal and environmental influences upon the diurnal heart-rate pattern in wild rabbits living under seminatural conditions. – *Physiol. Behav.* 43: 559–565.
- Flecknell, P. A. 1984. The relief of pain in laboratory animals. – *Lab. Anim.* 18: 147–160.
- Flecknell, P. A. 1987. Laboratory animal anaesthesia. – Academic Press.
- Gálvez-Bravo, L. 2017. Conejo – *Oryctolagus cuniculus*. Salvador, A. and Barja, I. (eds), *Enciclopedia virtual los vertebrados*. Mus. Nac. Ciencias Nat. Madrid. <www.vertebradosibericos.org/>.
- Gargiulo, S. et al. 2012. Mice anesthesia. – *ILAR J.* 53: E55–E68.
- Gibb, J. A. 1990. The European rabbit. – In: Chapman, J. A. and Flux, J. E. (eds), *Rabbits, hares and pikas: status survey and conservation action plan*. IUCN, Switzerland, 116–120.
- Gibb, J. A. and Williams, J. M. 1990. European rabbit. – In: King, C. M. (ed.), *Handbook of New Zealand mammals*. Oxford Univ. Press, pp.138–160.
- Graham, J. 2006. Common procedures in rabbits. – *Vet. Clin. North Am. Exot. Anim. Pract.* 9: 367–388.
- Hegedus, S. A. and Shackelford, R. T. 1965. A comparative-anatomical study of the craniocervical venous systems in mammals, with special reference to the dog: relationship of anatomy to measurements of cerebral blood flow. – *Am. J. Anat.* 116: 375–386.
- Henke, J. et al. 2005. Comparative study of three intramuscular anaesthetic combinations (medetomidine/ketamine, medetomidine/fentanyl/midazolam and xylazine/ketamine) in rabbits. – *Vet. Anaesth. Analg.* 32: 261–270.
- La Fuente, F. R. 1993. *Cadernos de campo*. – A Lebre e o Coelho, Lisboa.
- Longley, L. et al. M. 2008. Anaesthesia of exotic pets. – Elsevier.
- Macdonald, D. W. and Barrett, P. 1993. *Mammals of Europe*. – Princeton Univ. Press.
- Muir, W. W. et al. 2000. Drugs used for preanesthetic medication. – *Handb. Vet. Anesth.* 3: 19–40.
- Mullan, S. and Saunders, R. 2018. European rabbits (*Oryctolagus cuniculus*). – *Companion Anim. Care Welf.* 163–184.
- Nelson, E. A. et al. 2010. A jugular bleeding technique in rabbits. – *Lab. Anim.* 39: 17–22.
- O'Malley, B. 2005. Clinical anatomy and physiology of exotic species. Structure and function of mammals, birds, reptiles and amphibians, 1st edn. – Elsevier.
- Parasuraman, S. et al. 2010. Blood sample collection in small laboratory animals. – *J. Pharmacol. Pharmacother.* 1: 87.
- Patrick, J. et al. 1994. The biology of the laboratory rabbit, 2nd edn. – Elsevier.
- Quesenberry, K. E. and Carpenter, J. W. (eds) 2012. Ferrets, rabbits and rodents clinical medicine and surgery. – In: *Clinical medicine and surgery*. 3rd edn. ScienceDirect.
- Ramer, J. C. et al. 1999. Evaluating and stabilizing critically ill rabbits. I. – *Compend. Contin. Educ. Pract. Vet.*
- Seamer, J. 1993. Farm animal welfare in Britain. – *SCAW (Scientists Cent. Anim. Welfare) Newsl.* 14: 13–14.
- Smith, E. N. et al. 1981. Fear bradycardia in captive eastern chipmunk, *Tamias striatus*. – *Comp. Biochem. Physiol. Part A Physiol.* 70: 529–532.
- Smith, E. N. and Worth, D. 1980. Atropine effect on fear bradycardia of the eastern cottontail rabbit, *Sylvilagus floridanus*. – In: Amlaner, C. J. and Macdonald, D. W. (eds), *Handbook on biotelemetry and radio tracking*. ScienceDirect, pp. 549–555.
- Varga, M. 2014. Textbook of rabbit medicine. – Elsevier.
- Virgós, E. et al. 2005. El declive del conejo en España: evidencias a partir de las estadísticas de caza. – *Quercus* 236: 16–20.
- Von Holst, D. et al. 1999. Social rank, stress, fitness, and life expectancy in wild rabbits. – *Naturwissenschaften* 86: 388–393.
- Ward, D. 2005. Reversing rabbit decline: one of the biggest challenges for nature conservation in Spain and Portugal. – *SOSLynx.opg*.
- Wildpro 2017. Detailed physiology notes with literature reports for the European rabbit – *Oryctolagus cuniculus*. – <http://wildpro.twycrosszoo.org/S/0MLagomorph/Leporidae/Oryctolagus/Oryctolagus_cuniculus/10Oryctolagus_cuniculus_DetPhy.htm>, accessed 14 November 2017.
- Willott, S. J. et al. 2000. The contribution of rabbits (*Oryctolagus cuniculus* L.) to soil fertility in semi-arid Spain. – *Biol. Fertil. Soils* 31: 379–384.