

## **DISTRIBUTION OF MUSCLEWORM, *Parelaphostrongylus andersoni*, AMONG WHITE-TAILED DEER OF THE SOUTHEASTERN UNITED STATES \***

Authors: PRESTWOOD, ANNIE K., NETTLES, VICTOR F., and KELLOGG, FOREST E.

Source: Journal of Wildlife Diseases, 10(4) : 404-409

Published By: Wildlife Disease Association

URL: <https://doi.org/10.7589/0090-3558-10.4.404>

---

BioOne Complete ([complete.BioOne.org](https://complete.BioOne.org)) is a full-text database of 200 subscribed and open-access titles in the biological, ecological, and environmental sciences published by nonprofit societies, associations, museums, institutions, and presses.

Your use of this PDF, the BioOne Complete website, and all posted and associated content indicates your acceptance of BioOne's Terms of Use, available at [www.bioone.org/terms-of-use](https://www.bioone.org/terms-of-use).

Usage of BioOne Complete content is strictly limited to personal, educational, and non - commercial use. Commercial inquiries or rights and permissions requests should be directed to the individual publisher as copyright holder.

---

BioOne sees sustainable scholarly publishing as an inherently collaborative enterprise connecting authors, nonprofit publishers, academic institutions, research libraries, and research funders in the common goal of maximizing access to critical research.

## DISTRIBUTION OF MUSCLEWORM, *Parelaphostrongylus andersoni*, AMONG WHITE-TAILED DEER OF THE SOUTHEASTERN UNITED STATES\*

ANNIE K. PRESTWOOD, VICTOR F. NETTLES and FOREST E. KELLOGG

Southeastern Cooperative Wildlife Disease Study, Department of Parasitology,  
College of Veterinary Medicine, University of Georgia, Athens, 30602, U.S.A.

**Abstract:** One hundred and twenty-one white-tailed deer (*Odocoileus virginianus*) from 24 counties in 11 southeastern states were examined for muscleworm, *Parelaphostrongylus andersoni*, and meningeal worm, *P. tenuis*. Muscleworm was found in deer of 12 counties in Florida, Georgia, Louisiana, North Carolina, and South Carolina. Meningeal worm was recovered from deer in 10 counties of Arkansas, Georgia, Maryland, North Carolina, Virginia, and West Virginia. Concomitant infections with *P. andersoni* and *P. tenuis* occurred in deer of two counties in North Carolina. Future studies on the distribution of protostrongylid lungworms of white-tailed deer must be based on the location and identification of adult nematodes since first-stage larvae of *Parelaphostrongylus* are indistinguishable morphologically.

### INTRODUCTION

Information on the prevalence and distribution of parasites is often necessary for subsequent investigations, particularly when dealing with parasites which cause clinical disease in usual or unusual hosts. *Parelaphostrongylus tenuis* (Dougherty 1945) Pryadko and Boev 1971 is noteworthy in this respect since it is a neurotropic helminth which only occasionally produces neurologic disturbances in its usual host, the white-tailed deer,<sup>2</sup> but which frequently causes neurologic disease in unusual hosts, viz., moose,<sup>3,20</sup> caribou,<sup>5</sup> reindeer,<sup>4</sup> wapiti,<sup>7</sup> and domestic sheep.<sup>13,15</sup>

Considerable attention has been given the distribution of *P. tenuis* because of its neurotropic affinities. These studies largely have been based on recovery of the adult parasites,<sup>1-2,8-10,12,17</sup> however, a few reports have been based wholly or

in part on finding characteristic first-stage protostrongylid larvae in fecal samples.<sup>6,11,18-19</sup>

Recently, *P. andersoni* Prestwood 1972 was described from the musculature of white-tailed deer from coastal Georgia and South Carolina. First-stage larvae of *P. andersoni* are morphologically indistinguishable from those of *P. tenuis*.<sup>16</sup> A study therefore was initiated to obtain information on the prevalence and distribution of *P. andersoni*, particularly with regard to that of *P. tenuis*. Results of this investigation are presented herein.

### MATERIALS AND METHODS

White-tailed deer were obtained from 24 counties in 11 southeastern states. Six potential vegetative types,<sup>14</sup> viz., Appalachian oak (*Quercus*), mixed-mesophytic

\* This study was supported by an appropriation from the Congress of the United States. Funds were administered and research coordinated under the Federal Aid in Wildlife Restoration Act (50 Stat. 917) and through Contract No. 14-16-0008-708, Bureau of Sport Fisheries and Wildlife, U.S. Department of the Interior.

(*Acer-Aesculus-Fagus-Liriodendron-Quercus-Tilia*), oak-hickory-pine (*Quercus-Carya-Pinus*), southern mixed (*Fagus-Liquidambar-Magnolia-Pinus-Quercus*), southern floodplain (*Quercus-Nyssa-Toxodium*), and pocosin (*Pinus-Ilex*), comprised the habitats of collection sites (Figure 1). Most deer were collected by shooting, and five deer usually constituted a standard sample. Some natural mortality victims were studied, and less than five deer were examined in these

instances. Post-mortem examinations were made within 5 to 14 hours after death. In warm weather, carcasses were surrounded by crushed ice to retard decomposition.

Heads of deer were examined for meningeal worm using procedures described previously.<sup>17</sup> The longissimus dorsi, psoas, gluteals, and thigh muscles were routinely examined for *P. andersoni*. Separated muscles were placed on a cutting board, sliced thinly, and searched

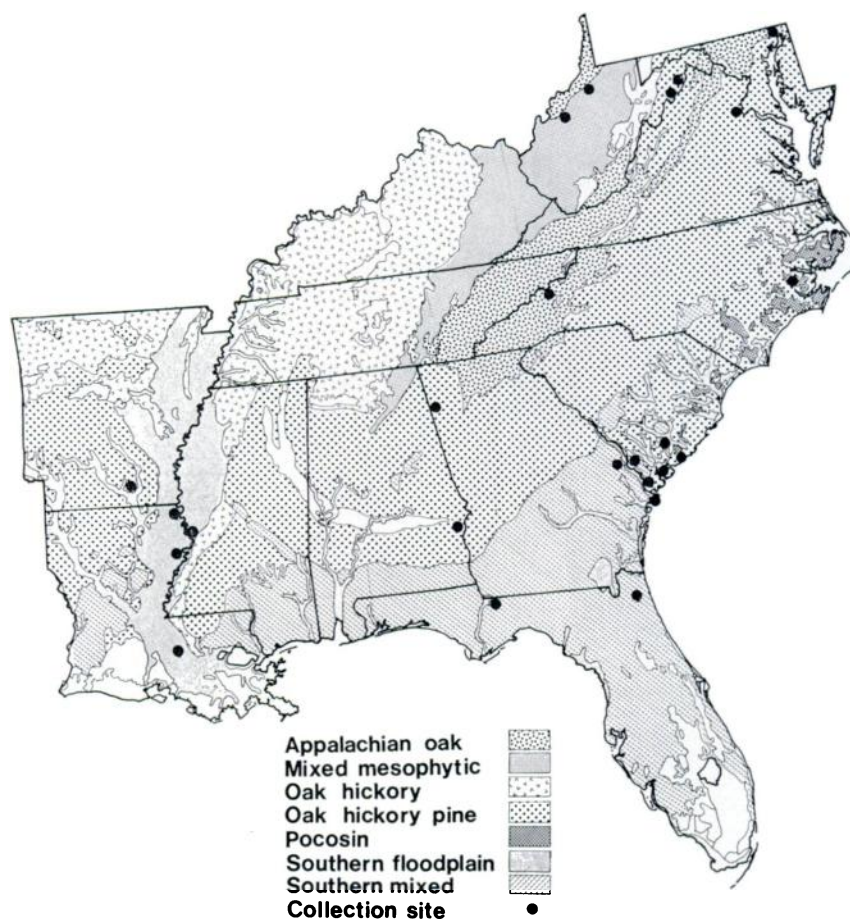


FIGURE 1. Major potential vegetative types and location of collection sites in the southeastern United States. Map adapted from Küchler (1964).

TABLE 1. Prevalence of muscleworm and meningeal worm in white-tailed deer in 24 counties of 11 southeastern states.

State County	Vegetative Type	No. Deer Examined	Number Deer Infected		Larvae	
			Muscleworm	Meningeal Worm	Histology	Baermann
Alabama Barbour	oak-hickory-pine	5	0	0	3	3
Arkansas Bradley	oak-hickory-pine	5	0	4	4	4
Florida Duval	southern mixed	5	1	0	3	1
Gadsden	southern mixed	10	0	0	0	0
Georgia Burke	southern mixed	5	0	0	1	2
Chatham	southern mixed	5	2	0	5	4
Floyd	oak-hickory-pine	5	0	5	5	5
Louisiana East Carroll	southern floodplain	5	1	0	3	3
Iberville	southern floodplain	2	1	0	2	2
Tensas	southern floodplain	5	3	0	3	4
Maryland Harford	oak-hickory-pine	5	0	3	2	1
Mississippi Warren	southern floodplain	4	0	0	2	3
North Carolina Craven	pocosin	5	2	1	4	3
Yancey	Appalachian oak	5	1	4	5	5
South Carolina Allendale	southern mixed	5	2	0	5	3
Beaufort	oak-hickory-pine	10	3	0	10	8
Charleston	oak-hickory-pine	5	2	0	3	3
Colleton	southern floodplain	5	2	0	3	1
Jasper	oak-hickory-pine	5	2	0	2	2
Virginia Stafford	oak-hickory-pine	5	0	4	2	4
West Virginia Doddridge and Wirt	mixed-mesophytic	5	0	4	0	1
Hampshire	oak-hickory-pine	5	0	4	5	5
Hardy	oak-hickory-pine	5	0	3	5	3

for hemorrhagic or abnormal appearing areas with the aid of a bright light. When lesions were found, they were placed under a dissecting microscope and examined for helminths. Nematodes were gently teased from muscle tissue, preserved in boiling glycerine-alcohol or 5% formalin, and cleared in glycerine or phenol for identification.

Ten randomly selected samples of lung tissue from each deer were preserved in 10% buffered formalin for histological study. Tissues were processed according to standard procedures and stained with Delafield's hematoxylin and eosin. Lungs and feces were examined for protostrongylid larvae by the Baermann technique.

#### RESULTS

One hundred and twenty-one white-tailed deer were searched for *P. andersoni* and *P. tenuis*, and adult helminths of one or both species were located in 52 animals. Musclemore was found in 22 deer from 12 counties of five states, while meningeal worm was recovered in 32 deer from ten counties in six states (Table 1). Concomitant infections with *P. andersoni* and *P. tenuis* occurred in two deer from the study sites in North Carolina. Egg emboli and larvae were demonstrated histologically in the lungs of 76 deer from 20 counties. First-stage larvae were recovered by the Baermann technique from 70 deer and were indistinguishable from first-stage larvae of *P. andersoni* and *P. tenuis*.

#### DISCUSSION

Musclemore and meningeal worm were widely distributed among white-tailed deer of the southeastern United States and occurred in a variety of physiographic provinces and vegetative types. Musclemore was most commonly recovered from white-tailed deer inhabiting southern floodplain, southern mixed, and oak-hickory-pine vegetative types. During this study meningeal worm was commonly found among deer of the oak-hickory-

pine and mixed-mesophytic vegetative types, but was absent in deer from southern floodplain and southern mixed vegetative types. Previous studies,<sup>17</sup> however, have shown *P. tenuis* to occur in deer of these vegetative types. Such widely divergent vegetative types as Appalachian oak and pocosin supported deer harboring both species of nematode. The widespread distribution of *P. andersoni* and *P. tenuis* in southeastern white-tailed deer and concomitant infection of deer by both helminths therefore suggest that future studies on distribution of members of the genus *Parelaphostrongylus* should be based on location and identification of the adult parasite.

In a few instances, hemorrhage or other gross lesions were not associated with adult *P. andersoni*, however this helminth was found most frequently in hemorrhagic sites adjacent to small blood vessels in the longissimus dorsi. These muscle were relatively easy to isolate and examine, which probably accounts for our success in locating worms in these muscles. Only occasionally were parasites found in the gluteal and thigh muscles when the longissimus was negative. Worms rarely were located in the psoas major. The longissimus dorsi therefore appears to be the muscle of choice when surveying for *P. andersoni*.

Adults of the genus *Parelaphostrongylus* were recovered from 43% of the deer. Eggs or larvae were demonstrated histologically in 63%, while nearly 58% were actively shedding larvae indistinguishable from those of this genus. This disparity in prevalence of adults and larvae most likely can be attributed to failure to locate the adult helminth in the definitive host. The small size, relatively obscure location of *P. andersoni* in muscle tissue, and occasional lack of observable lesions made it particularly difficult to locate. Failure to find adult *P. andersoni* was greater than failure to find adult *P. tenuis*. With a sample size of five deer, the presence of this parasite in a particular locale usually could be detected. The possibility exists, however, that a third undiscovered member of this group may inhabit southeastern white-tailed deer.

The two methods used to detect first-stage larvae generally agreed, however the histologic method appeared to be slightly more efficient, viz. 63% vs. 58% positive. Microscopic examination of lung tissue had the advantage of revealing egg emboli as well as larvae. The

Baermann technique, however, yielded larvae suitable for morphologic study and was easier and less expensive to perform. The Baermann technique appears to be the method of choice when only one technique can be utilized.

#### LITERATURE CITED

1. ALIBASOGLU, M., D. C. KRADEL and H. W. DUNNE. 1961. Cerebral nematodiasis in Pennsylvania deer (*Odocoileus virginianus*). Cornell Vet. 51: 431-441.
2. ANDERSON, R. C. 1963. The incidence, development, and experimental transmission of *Pneumostrongylus tenuis* of white-tailed deer (*Odocoileus virginianus borealis*) in Ontario. Can. J. Zool. 41: 775-792.
3. ———. 1965. An examination of wild moose exhibiting neurologic signs in Ontario. Can. J. Zool. 43: 635-639.
4. ———. 1971. Neurologic disease in reindeer (*Rangifer tarandus tarandus*) introduced into Ontario. Can. J. Zool. 49: 159-166.
5. ——— and UTA R. STRELIVE. 1968. The experimental transmission of *Pneumostrongylus tenuis* to caribou (*Rangifer tarandus terraenovae*). Can. J. Zool. 46: 503-510.
6. BINDERNAGEL, J. A. and R. C. ANDERSON. 1972. Distribution of the meningeal worm in white-tailed deer in Canada. J. Wildl. Mgmt. 36: 1349-1353.
7. CARPENTER, J. W., HELEN E. JORDAN and B. C. WARD. 1973. Neurologic disease in wapiti naturally infected with meningeal worms. J. Wildl. Dis. 9: 148-153.
8. DE GIUSTI, D. L. 1963. Incidence and distribution of *Elaphostrongylus odocoilei* in Michigan deer herd. J. Parasit. 49 (5, Sect. 2): 47.
9. DUDAK, D., G. W. CORNWELL, R. B. HOLLIMAN and B. S. MCGINNIS. 1965. The incidence and degree of infection of *Pneumostrongylus tenuis* in the white-tailed deer of western Virginia. Tr. 17th Annual Conference, Southeastern Assoc. Game and Fish Commissioners, Tulsa, Okla., 10-13 Oct., p. 128-141.
10. GILBERT, F. F. 1973. *Parelaphostrongylus tenuis* (Dougherty) in Maine: I—The parasite in white-tailed deer (*Odocoileus virginianus*, Zimmerman). J. Wildl. Dis. 9: 136-143.
11. KARNS, P. D. 1966. *Pneumostrongylus tenuis* from elk (*Cervus canadensis*) in Minnesota. Bull. Wildl. Dis. Ass. 2: 79-80.
12. ———. 1967. *Pneumostrongylus tenuis* in deer in Minnesota and implications for moose. J. Wildl. Mgmt. 31: 299-303.
13. KENNEDY, P. C., J. H. WHITLOCK and S. J. ROBERTS. 1952. Neurofilariosis, a paralytic disease of sheep. I. Introduction, symptomatology and pathology. Cornell Vet. 42: 118-124.
14. KUCHLER, A. W. 1964. *Potential Natural Vegetation of the Conterminous United States*. Special Publication No. 36, American Geographical Society, New York. Map + 116 p. manual.
15. NIELSON, S. W. and J. AFTOSMIS. 1964. Spinal nematodiasis in two sheep. J. Am. vet. med. Ass. 144: 155-158.

16. PRESTWOOD, ANNIE K. 1972. *Parelaphostrongylus andersoni* sp. n. (Metastrongyloidea: Protostrongylidae) from the musculature of white-tailed deer (*Odocoileus virginianus*). J. Parasit. 58: 897-902.
17. ——— and J. F. SMITH. 1969. Distribution of meningeal worm (*Pneumostrongylus tenuis*) in deer in the southeastern United States. J. Parasit. 55: 720-725.
18. SAMUEL, W. M. and R. L. BEAUDOIN. 1966. Evaluation of two survey methods for detection of helminth infections in white-tailed deer (*Odocoileus virginianus*). Bull. Wildl. Dis. Ass. 2: 100-107.
19. ——— and D. O. TRAINER. 1969. A technique for survey of some helminth and protozoan infections of white-tailed deer. J. Wildl. Mgmt. 33: 888-894.
20. SMITH, H. J. and R. M. ARCHIBALD. 1967. Moose sickness, a neurologic disease of moose infected with the common cervine parasite *Elaphostrongylus tenuis*. Can. vet. J. 8: 173-177.

Received for publication 18 March 1974

---