

## **POXVIRUS INFECTION IN THE WHITE-BACKED MAGPIE (*Gymnorhina hypoleuca*) AND POX-LIKE CONDITIONS IN OTHER BIRDS IN AUSTRALIA**

Authors: HARRIGAN, K. E., BARKER, I. K., and STUDDERT, M. J.

Source: Journal of Wildlife Diseases, 11(3) : 343-347

Published By: Wildlife Disease Association

URL: <https://doi.org/10.7589/0090-3558-11.3.343>

---

BioOne Complete ([complete.BioOne.org](https://complete.BioOne.org)) is a full-text database of 200 subscribed and open-access titles in the biological, ecological, and environmental sciences published by nonprofit societies, associations, museums, institutions, and presses.

Your use of this PDF, the BioOne Complete website, and all posted and associated content indicates your acceptance of BioOne's Terms of Use, available at [www.bioone.org/terms-of-use](https://www.bioone.org/terms-of-use).

Usage of BioOne Complete content is strictly limited to personal, educational, and non - commercial use. Commercial inquiries or rights and permissions requests should be directed to the individual publisher as copyright holder.

---

BioOne sees sustainable scholarly publishing as an inherently collaborative enterprise connecting authors, nonprofit publishers, academic institutions, research libraries, and research funders in the common goal of maximizing access to critical research.

## POXVIRUS INFECTION IN THE WHITE-BACKED MAGPIE (*Gymnorhina hypoleuca*) AND POX-LIKE CONDITIONS IN OTHER BIRDS IN AUSTRALIA

K. E. HARRIGAN, I. K. BARKER<sup>[1]</sup> and M. J. STUDDERT<sup>[2]</sup>

Department of Veterinary Paraclinical Sciences, University of Melbourne, Australia.

**Abstract:** Lesions, grossly and histologically typical of pox infection, occurred in a white-backed magpie from Melbourne, Australia. Electron microscopic examination revealed typical poxvirus particles in lesion material. The disease was experimentally transmitted to other magpies, but chickens, turkeys, pigeons and canaries were refractory to experimental infection with magpie poxvirus. The epidemiology of magpie pox and the probable occurrence of pox-like disease in other native Australian birds are discussed.

### INTRODUCTION

Poxvirus infection is known in numerous species of birds from many areas of the world.<sup>4,5</sup> Reports of avian poxvirus infection in the Australian region appear scarce, being limited to observations on silvereyes (*Zosterops lateralis*) and pipits (*Anthus novaeseelandiae*) from New Zealand<sup>1</sup> and a reference<sup>2</sup> to an unpublished observation by Fenner of pox being common in Australian magpies (*Gymnorhina* sp.), a corvid genus which was assigned in error to the Corvidae by Kirmse.<sup>5</sup>

During December 1973, and January 1974 a number of white-backed magpies were reported to the Victorian Department of Fisheries and Wildlife by Melbourne householders, as having tumors or warts on the face and legs. One householder, who had regularly fed a free-flying magpie, noted lesions which developed first on the bird's feet. They spread to the legs and nares over a 2-3 week period, and the magpie was referred to the Veterinary Clinical Centre following its submission to the Department of Fisheries and Wildlife.

### MATERIALS AND METHODS

The bird was anesthetized with ketamine hydrochloride,\* examined and several large nodules were excised, fixed in 10% formalin or frozen at -70 C for further investigation. The formalin-fixed material was embedded in paraffin wax, sectioned 6 µm thick and stained with haematoxylin and eosin.

A small piece of the frozen tissue was minced in a minimum quantity of distilled water to lyse cells. A drop was transferred to a copper grid and allowed to stand for about 5 min. Excess fluid was removed and the grid was stained and rinsed with 2% sodium phosphotungstate (pH7). After rinsing several times a drop of stain was allowed to remain on the grid for 30 sec. Excess stain was removed and the grid was examined in a Hitachi HU11 B electron microscope.

Some frozen tissue was thawed, ground in a tissue grinder, suspended in nutrient broth containing 10,000 IU penicillin and 10 mg streptomycin/ml, and inoculated onto the chorioallantoic membrane

[1] Veterinary Clinical Centre, Werribee, Victoria 3030, Australia.

[2] Veterinary Preclinical Centre, Parkville, Victoria 3052, Australia.

\* Ketalar: Parke-Davis and Company.

(CAM) of six 12 day-old chicken embryos, which were subsequently incubated at 35 C for 5 days. The CAMs of the two eggs which survived were harvested and examined for pocks. Pieces of CAM were frozen at -70 C, and others were fixed for histologic examination.

Suspensions of first passage CAM were inoculated into the following birds: three white-backed magpies, eight domestic pigeons, 12 domestic fowl, 12 domestic turkeys and four canaries. The skin of the wing web or neck was abraded with a hypodermic needle and the area was swabbed with tissue suspension. Sites of inoculation were inspected twice weekly for 6 weeks. Two of the turkeys, two of the chickens and four of the pigeons were challenged 12 weeks post inoculation with suspensions of fowl pox virus isolated on CAM from a clinical case in a chicken.

In order to obtain some indication of the prevalence and distribution of pox

virus infection in magpies, a letter soliciting information on location, date and age of birds with suspect lesions was placed in *The Bird Observer*, a publication of the Bird Observers Club of Victoria.

#### RESULTS

Nodular papillomatous lesions up to 1 cm in diameter and elevated up to 7 mm above the surrounding skin surface were present on the plantar aspect of the right foot, along the side of several digits and on the scaled skin of the metatarsal region of both legs; the right nostril was occluded by a similar mass. No lesions were visible in the oral cavity or pharynx.

The mass excised from the leg consisted of a network of fine fibrous dermal papillae supporting a hyperplastic epithelium. Many cells of the stratum spinosum were hypertrophic and contained typical "Bollinger" bodies in the cytoplasm (Fig. 1). The hypertrophic cells

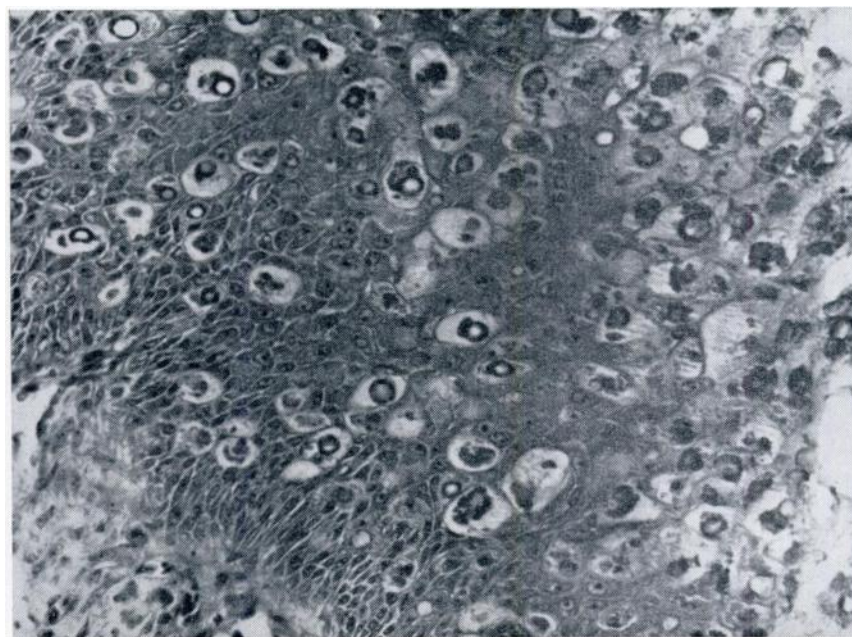


FIGURE 1. Typical pox-type inclusions in the cytoplasm of hypertrophied cells in the hyperplastic epidermis of a nodule from the foot of a white-backed magpie. X285.

accumulated in thick layers with outermost cells becoming extremely vacuolated and necrotic. In the dermis at the base of the lesion, fibroplasia was evident, with infiltration of heterophils around small vessels, extensive diffuse infiltration of round cells and formation of some lymphoreticular nodules. No inclusion bodies were seen in the dermis.

Typical poxvirus particles were observed in large numbers in the negatively stained tissue suspension (Fig. 2).

Both embryos inoculated with the suspension of the lesion and surviving for 5 days had characteristic opaque white pocks up to 1 cm in diameter on the CAM, and upon histologic examination numerous intracytoplasmic inclusion bodies were seen.

The results of test inoculations of tissue suspension into birds, and subsequent

challenge with fowl poxvirus, are presented in Table 1.

Eight replies were elicited by the request placed in *The Bird Observer* for sightings of magpies with pox-like lesions. Eight birds described as juvenile or immature, three adults and two whose age was not given were reported. Of these magpies, six were from Victoria south of the Great Dividing Range, and were probably *G. hypoleuca*, while the remainder were reported from areas of New South Wales between Sydney and Grafton, near the Queensland border. These latter reports probably involve the related black-backed magpie, *G. tibicen*, which has a northern distribution overlapping that of *G. hypoleuca*.

Descriptions of size and extent of lesions varied from small nodules, to "green-pea", to up to "1 inch" in dia-

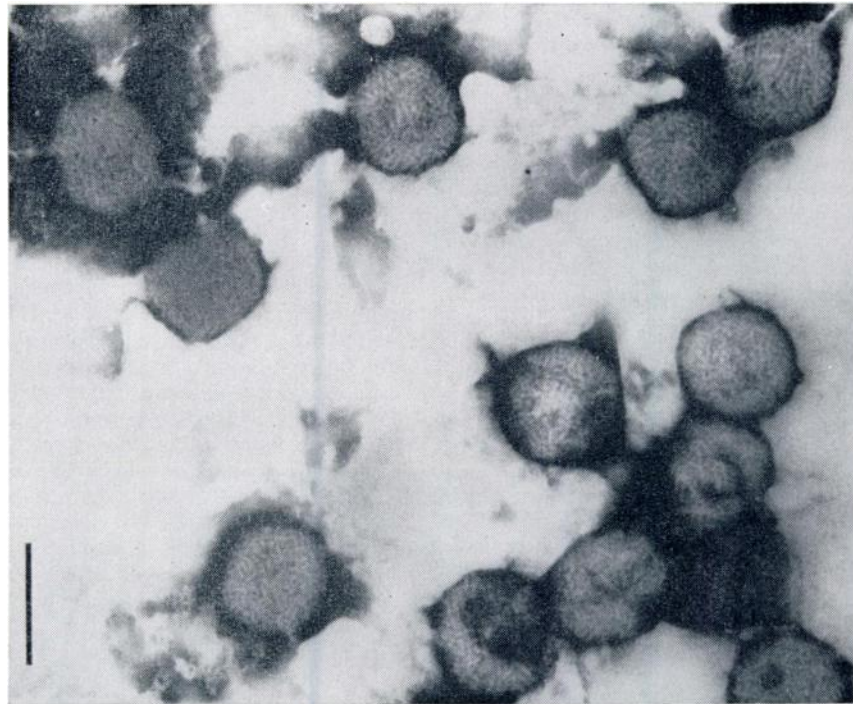


FIGURE 2. Poxviruses in a negatively stained preparation of a lesion from a white-backed magpie. Scale = 300nm.

meter, on the feet, beak, nostrils, eyes, thighs, and general body surface, in some cases associated with local loss of feathers. Two affected birds died shortly after the initial observation and several others were considered to be in such distress that they were killed. However, other birds were observed to recover, even from apparently severe infections, over periods varying from a few weeks to 5 months. One correspondent associated

the disease in one bird with a local mosquito plague.

A report was also received of pox-like lesions in a black swan *Cygnus atratus* (K. N. G. Simpson, pers. com., 1974), while another writer volunteered observations of such lesions on six mudlarks, *Grallina cyanoleuca* and in Eastern Silvereyes, *Zosterops lateralis* trapped for banding in New South Wales (M. A. Johnson, pers. com., 1974).

TABLE 1. Results of inoculation of magpie pox-infected CAM suspension into magpies, chickens, turkeys, pigeons, and canaries, and subsequent challenge with fowl pox virus in chickens, turkeys and pigeons.

	Magpie pox		Fowl pox	
	No. inoculated	No. developing lesions	No. challenged	No. developing lesions
White-backed magpie	3	3	—	—
Chicken	12	0	2	2
Turkey	12	0	2	2
Pigeon	8	0	4	0
Canary	4	0*	—	—

\* 1 of the canaries was discovered to have a pox lesion on the foot (not the site of inoculation) several days after the test exposure, indicating probable intercurrent canary pox infection.

## DISCUSSION

The lesions described on the bird we saw are characteristic of avian poxvirus infection, and the agent observed in negatively-stained preparations of the lesion is a typical poxvirus. Aliquots of virus suspension have been stored by M. J. S. The host specificity and antigenic interrelationships of avian poxviruses present a complex problem which has been discussed by others.<sup>3,4,6</sup> The limited observations reported here indicate that magpie pox will not infect chickens, turkeys, pigeons, or canaries, though the latter birds may not have been fully susceptible due to intercurrent canary pox infection which was incubating in at least one bird when they were obtained. Magpie pox also fails to stimulate immunity in chickens and turkeys to challenge with fowl pox.

The field observations gathered by the survey indicate that poxvirus infection is mainly a disease of juvenile magpies. This may imply a relatively high prevalence of infection, conferring immunity in older birds. It appears to cause mortality in some severely afflicted birds, but this can scarcely be compared with the annual decimation of immature magpies hit by cars while scavenging food along highways. An association by one correspondent of the occurrence of magpie pox with mosquito activity is of note, since mosquitoes are known to play a major role in the transmission of fowl pox virus among chickens in Australia.<sup>7</sup> It is not known if the viruses infecting *G. hypoleuca* and *G. tibicen* are identical.

The pox-like lesions described in other species indicate that, like the avifauna of

other continents, a number of Australian birds may be susceptible to poxvirus infection. The observation of pox-like lesions on eastern silvereyes indicates that this disease of silvereyes in New Zealand<sup>1</sup> in all probability was imported during the recent migration of that species from Australia to New Zealand.

#### Acknowledgements

We wish to express our gratitude to officers of the Victorian Department of Fisheries and Wildlife who referred the bird to us; to Dr. J. E. Peterson, CSIRO Division of Animal Health who collaborated with the preparation of the negatively stained virus; to Mr. Stephen Thomas who cared for the experimental birds and assisted technically; and to the "birdos" who responded to our request for field observations.

#### LITERATURE CITED

1. AUSTIN, F. J., P. C. BULL and M. A. CHAUDRY. 1973. A poxvirus isolated from Silvereyes (*Zosterops lateralis*) from Lower Hutt, New Zealand. *J. Wildl. Dis.* 9: 111-114.
2. BURNET, F. M. 1959. Animal viruses: a comparative survey. In: Vol. 3 *The Viruses*. Edited by F. M. Burnet and W. M. Stanley. Academic. New York. pp 3-14.
3. GIDDENS, W. E., L. J. SWANGO, J. D. HENDERSON, Jr., R. A. LEWIS, D. S. FARNER, A. CARLOS and W. G. DOLOWY. 1971. Canary pox in sparrows and canaries (Fringillidae) and in weavers (Ploceidae). Pathology and host specificity of the virus. *Vet. Path.* 8: 260-280.
4. KARSTAD, L. 1971. Pox. In: *Infectious and Parasitic Diseases of Wild Birds*. Edited by J. W. Davis et al. Iowa State Press, Ames, Iowa. pp. 34-41.
5. KIRMSE, P. 1967. Pox in wild birds. An annotated bibliography. *Wildl. Dis.* No. 49. 10 pp.
6. KIRMSE, P. 1969. Host specificity and pathogenicity of pox viruses from wild birds. *Bull. Wildl. Dis. Ass.* 5: 376-386.
7. LEE, D. J., F. FENNER and J. J. LAWRENCE. 1958. Mosquitoes and fowl pox in the Sydney area. *Aust. vet. J.* 34: 230-237.

Received for publication 18 November 1974