



CEREBRAL ABSCESS ASSOCIATED WITH STRANDING IN A DOLPHIN

Authors: COLGROVE, G. S., and MIGAKI, G.

Source: Journal of Wildlife Diseases, 12(2) : 271-274

Published By: Wildlife Disease Association

URL: <https://doi.org/10.7589/0090-3558-12.2.271>

BioOne Complete (complete.BioOne.org) is a full-text database of 200 subscribed and open-access titles in the biological, ecological, and environmental sciences published by nonprofit societies, associations, museums, institutions, and presses.

Your use of this PDF, the BioOne Complete website, and all posted and associated content indicates your acceptance of BioOne's Terms of Use, available at www.bioone.org/terms-of-use.

Usage of BioOne Complete content is strictly limited to personal, educational, and non - commercial use. Commercial inquiries or rights and permissions requests should be directed to the individual publisher as copyright holder.

BioOne sees sustainable scholarly publishing as an inherently collaborative enterprise connecting authors, nonprofit publishers, academic institutions, research libraries, and research funders in the common goal of maximizing access to critical research.

CEREBRAL ABSCESS ASSOCIATED WITH STRANDING IN A DOLPHIN

G. S. COLGROVE¹ and G. MIGAKI²

Abstract: A captive Atlantic bottlenosed dolphin (*Tursiops truncatus*) was examined after being found beached in the shallows of its lagoon enclosure. An abscess was found in the right cerebral hemisphere, and *Staphylococcus aureus* was isolated from the lesion. Histopathologic examination of the brain revealed a pyogenic meningoencephalitis.

INTRODUCTION

There are numerous reports of wild cetaceans being found on beaches in various parts of the world. Such animals are generally termed stranded.³ While the causes of cetacean strandings are not always apparent, at least two conditions which may produce disorientation or incoordination have been associated with the stranding phenomenon. Fraser (quoted in Norris)⁴ and Reysenback De Hann⁵ reported that the pterygoid or acoustic sinuses of stranded cetaceans are frequently infested with nematodes. Ridgway and Daily,⁶ and Ridgway and Johnston⁷ found cerebral and cerebellar abscesses containing trematode ova in stranded Pacific dolphin (*Delphinus sp.*)

This report describes the finding of a cerebral abscess due to *Staphylococcus aureus* in a stranded, captive Atlantic bottlenosed dolphin (*Tursiops truncatus*).

CASE REPORT

An adult female bottlenosed dolphin was one of six captive dolphins that had been maintained in a fenced lagoon for approximately 9 months. On the morning of 6 April, she was found partially beached in a rocky, shallow area at one end of the lagoon enclosure. The animal was removed from the lagoon and transported to a nearby building for observation and

treatment. Numerous skin lacerations were present on the head, body and flukes, and the animal appeared in shock. Fluid therapy, corticosteroids, and antibiotics were administered, but the dolphin died approximately 30 hrs after the stranding was discovered.

The most significant necropsy finding was a cerebral abscess located beneath the cortex of the right cerebral hemisphere (Figure 1), approximately 2 cm from the longitudinal fissure. The abscess measured 1.5 cm in diameter, contained cream-colored pus, and appeared well encapsulated. Coagulase positive *S. aureus* was isolated from the abscess.³

Histologic examination of sections through the brain revealed both an acute and a chronic inflammatory process. In some sections there was an acute pyogenic abscess characterized by large accumulations of degenerated polymorphonuclear neutrophils with no evidence of a fibrous capsule (Figure 2). Numerous colonies of bacteria were found in the pyogenic exudate. Tissue sections stained with MacCallum-Goodpasture method revealed these bacteria to be gram-positive cocci arranged in large clusters morphologically resembling the genus *Staphylococcus*. An acute pyogenic leptomeningitis was found near the abscess (Figure 3). In other sections of the brain there were

¹ Naval Undersea Center, P.O. Box 997, Kailua, Hawaii 96734, USA.

² Armed Forces Institute of Pathology, Washington, D.C. 20306, USA.

³ Bacterial identification was made by Accu-Path Laboratory, Inc., Honolulu, Hawaii.

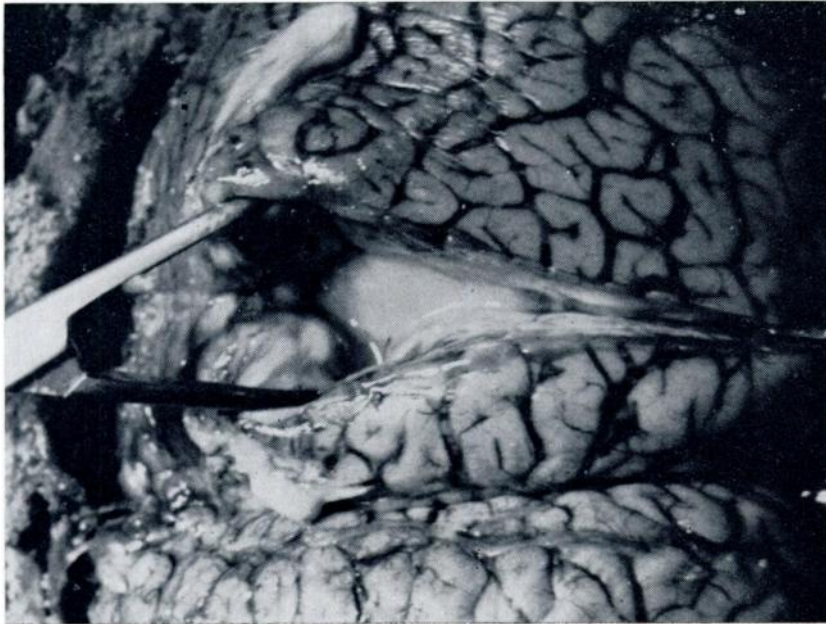


FIGURE 1. Incised abscess in the right cerebral hemisphere of the dolphin.

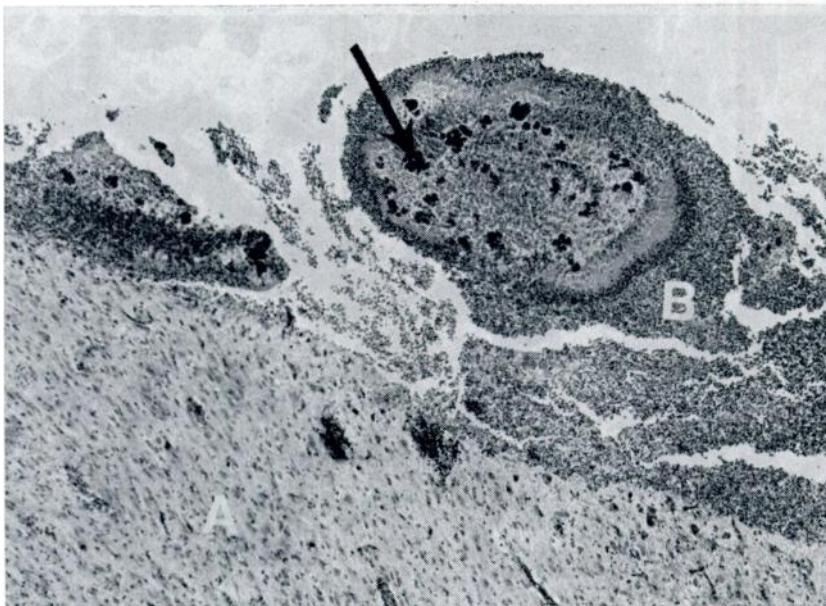


FIGURE 2. Cerebrum (A) containing abscess composed of degenerated polymorphonuclear neutrophils (B). Note large colonies of bacteria (arrow). H&E X50.

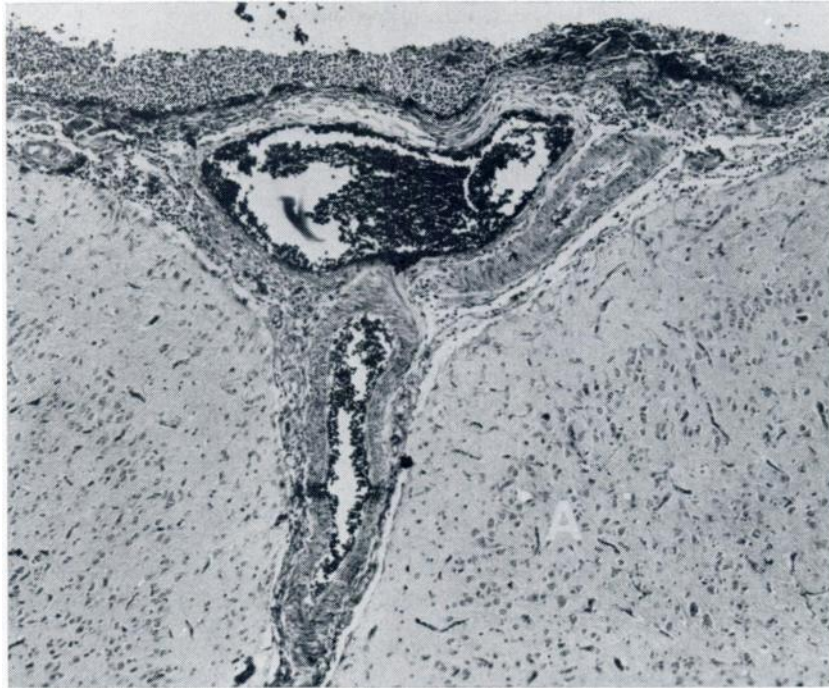


FIGURE 3. Acute pyogenic leptomeningitis of the cerebrum (A). Note the extensive pyogenic exudate in the meninges. H&E X56.

focal areas of chronic leptomeningitis characterized by large accumulations of plasma cells, lymphocytes and macrophages.

DISCUSSION

Prior to the stranding incident, the dolphin was in apparent good health and no manifestations of disease of the central nervous system were observed. Personnel who discovered the beached animal gained the impression that the stranding had required deliberate effort on the part of the dolphin. Attempts to return the dolphin to the water were met with strong resistance, and since tidal fluctuations within the lagoon were neither rapid nor extreme, it seemed unlikely that the animal had been involuntarily grounded by receding tides.

Pyogenic infections of the central nervous system may arise via the bloodstream, by implantation in wounds, or by direct extension to the brain from adjacent structures.¹ Histologically it appeared that this dolphin had a chronic leptomeningitis and subsequently developed an acute pyogenic leptomeningitis and a large acute pyogenic abscess. A direct open wound of the brain could have caused the abscess or it could have been secondary to a pyogenic embolus from lungs, skin, heart or elsewhere. Any infection leading to a septicemia could result in a cerebral abscess. The cause of the chronic leptomeningitis is not apparent, but a remote infection is suspected. No evidence of a pyogenic infection was observed in the lungs or heart.

Medway and Schryver⁸ isolated the genus *Staphylococcus* from the lungs of

several small cetaceans that died of bronchopneumonia. It is interesting to note that in one case, *Staphylococcus sp.* was recovered from the cerebrospinal fluid of a pilot whale (*Globicephala melaena*) with bronchopneumonia and septicemia, but no mention was made in

the report of any lesions in the central nervous system.

Ketterer and Rosenfeld² reported a septic embolic nephritis due to *S. aureus* in a dolphin (*Tursiops aduncus*). The primary infection was a subcutaneous abscess.

Acknowledgments

The technical assistance of P. F. McDowell and J. T. Brown is gratefully acknowledged. Part of this study was supported by the Office of Naval Research Contract No. 136886 from the Microbiology Branch and by Public Health Service Grant No. RR00301-10 from the Division of Research Resources, U.S. Department of Health, Education, and Welfare, under the auspices of Universities Associated for Research and Education in Pathology, Inc.

LITERATURE CITED

1. GREENFIELD, J. G. 1967. Infectious diseases of the central nervous system. In: *Greenfields Neurpathology*. Blackwood, W., W. H. McMenemey, A. Meyer, R. M. Norman and D. S. Russell (Eds.). London, Edward Arnold. pp. 138-234.
2. KETTERER, P. J. and L. E. ROSENFELD. 1974. Septic embolic nephritis in a dolphin caused by *Staphylococcus aureus*. *Aust. Vet. J.*, 50: 123.
3. MEDWAY, W. and H. F. SCHRYVER. 1973. Respiratory problems in captive small cetaceans. *J. A. vet. med. Ass.*, 163: 571-573.
4. NORRIS, K. S. (Ed.) 1966. *Whales, Dolphins and Porpoises*, Univ. of California Press, Berkeley, 602-606.
5. REYSENBACH DE HANN, F. W. 1957. Hearing in whales. *Acta Oto-Laryngol. suppl.* 134: 1-114.
6. RIDGWAY, S. H. and M. D. DAILY. 1972. Cerebral and cerebellar involvement of trematode parasites in dolphins and their possible role in stranding. *J. Wildl. Dis.*, 8: 33-43.
7. RIDGWAY, S. H. and D. G. JOHNSTON. 1965. Two interesting disease cases in wild cetaceans. *Amer. J. vet. Res.*, 26: 771-775.

Received for publication 25 September 1975