

## **LEUCOCYTOZONOSIS IN CANADA GEESE IN UPPER MICHIGAN I. STRAIN DIFFERENCES AMONG GEESE FROM DIFFERENT LOCALITIES**

Authors: DESSER, S. S., STUHT, J., and FALLIS, A. M.

Source: Journal of Wildlife Diseases, 14(1) : 124-131

Published By: Wildlife Disease Association

URL: <https://doi.org/10.7589/0090-3558-14.1.124>

---

BioOne Complete ([complete.BioOne.org](https://complete.BioOne.org)) is a full-text database of 200 subscribed and open-access titles in the biological, ecological, and environmental sciences published by nonprofit societies, associations, museums, institutions, and presses.

Your use of this PDF, the BioOne Complete website, and all posted and associated content indicates your acceptance of BioOne's Terms of Use, available at [www.bioone.org/terms-of-use](https://www.bioone.org/terms-of-use).

Usage of BioOne Complete content is strictly limited to personal, educational, and non - commercial use. Commercial inquiries or rights and permissions requests should be directed to the individual publisher as copyright holder.

---

BioOne sees sustainable scholarly publishing as an inherently collaborative enterprise connecting authors, nonprofit publishers, academic institutions, research libraries, and research funders in the common goal of maximizing access to critical research.

## LEUCOCYTOZOONOSIS IN CANADA GEESE IN UPPER MICHIGAN I. STRAIN DIFFERENCES AMONG GEESE FROM DIFFERENT LOCALITIES

S. S. DESSER,<sup>1</sup> J. STUHT<sup>2</sup> and A. M. FALLIS,<sup>1</sup> Department of Microbiology and Parasitology, Faculty of Medicine, University of Toronto, Toronto, Ontario, Canada M5S 1A1

**Abstract:** Geographic variation in pathogenicity of *Leucocytozoon simondi* in Canada geese (*Branta canadensis maxima*) was investigated by exposing goslings to natural infection at three locations in the upper peninsula of Michigan. Examination of blood smears and tissue sections revealed two patterns of development. Hepatic schizogony and secondary megaloschizogony occurred in cells of the reticulo-endothelial system, with round and elongate gametocytes, or only hepatic schizonts and round gametocytes. The evidence for strain differences in *L. simondi* and its implications in wildfowl management practices are discussed.

### INTRODUCTION

*Leucocytozoon simondi* has been implicated in heavy mortality among Canada goslings (*Branta canadensis maxima*) at the Seney National Wildlife Refuge in the upper peninsula of Michigan.<sup>6,7</sup> In a recent study of *L. simondi* in Algonquin Park, Ontario, pathogenesis was not recorded in geese and in no case could death of a gosling (*B.c. maxima*, *B.c. interior*, *Anser domesticus*) be attributed to the parasite.<sup>3</sup> Pathology in ducks infected with *L. simondi* has been associated with megaloschizogony,<sup>1</sup> a stage which was not observed in goslings infected in Algonquin Park. The purpose of this study was to describe the development and pathogenicity of *L. simondi* in goslings infected at Seney and 2 other locations in the upper peninsula of Michigan.

### STUDY AREAS

Sites selected for study had varying histories with regard to their use by waterfowl, and were located at three localities within the Lake Superior basin (Fig. 1), primarily a northern spruce-fir forest. Bogs and their associated plant species are common, as are aspen stands. Wetlands, with few exceptions, are of low quality for waterfowl. Top soils are thin and acidic, and support only specialized plant species. Runoff is low in nutrients, and streams, lakes and marshes are relatively infertile.

### Seney

The Seney National Wildlife Refuge (46°14'N, 85°57'W) encompasses about 39,000 ha. of marsh and open water in Schoolcraft County. The

<sup>1</sup> With the support of NRC Grant No. 6965 and MRC Grant No. MT2998

<sup>2</sup> Wildlife Pathology Laboratory  
Rose Lake Wildlife Research Center  
Route #1, East Lansing  
Michigan 48823, USA.

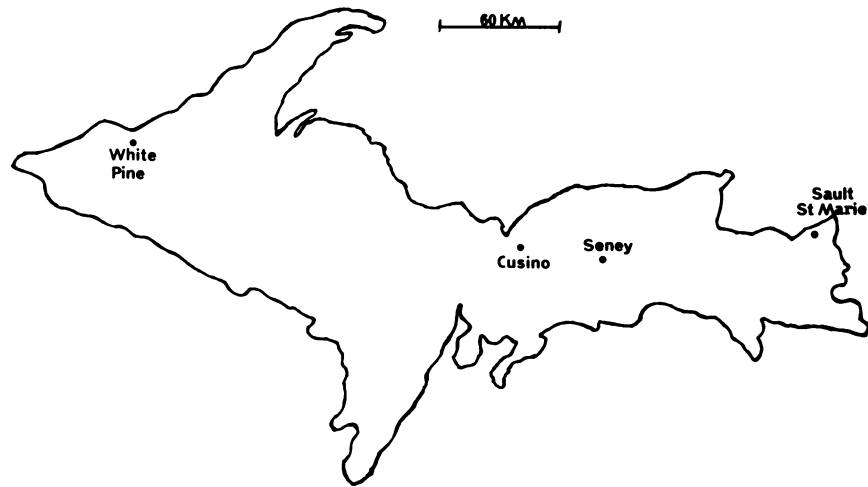


FIGURE 1. Map of the Upper Peninsula of Michigan illustrating the 3 sites where Canada goslings were exposed to infection with *Leucocytozoon simondi*.

region was the breeding ground for Canada geese until the summer of 1910 when their numbers rapidly diminished. There were no resident geese in the area from 1929 to 1935. In 1936, pinioned birds (*B.c. maxima*) were released and their offspring were allowed to fly free. Eventually they established a migrating and homing pattern.<sup>9</sup> Presently, there are about 1500 resident Canada geese and an undetermined number of resident ducks on the Refuge.

#### Cusino

The Cusino Wildlife Research Station (46°21' N, 86°28' W) is 40 km west of Seney in Alger County. Just north of the station a small permanent stream (Hickey Creek) flows through northern hardwoods, conifer swamps, open plains and semi-wooded areas. Although broods of mallards are seen regularly, there are no records of Canada geese nesting on the creek or in the vicinity.

#### White Pine

The White Pine Copper Company (46°47' N, 89°31' W), 278 km west of Seney, has operated a mine, mill, smelter, and refinery in Ontonagon County since the early 1950's. To dispose of waste products, the company built two giant settling basins (708 and 991 ha.), creating about 120 borrow pits varying in size from .5-8 ha. As the basins and pits filled with water and the area revegetated, it became attractive to waterfowl. In 1973, 20 wing-clipped Canada geese (*B.c. maxima*) were released in hope of establishing a resident flock. Additional releases were made in 1974, 75, and 76. The first brood was seen in 1974. Eleven broods were seen in 1975 and 21 in 1976. Ducks, but no geese nested in the area prior to 1974.

#### MATERIALS AND METHODS

In May, June, and July of 1975 and 1976, 5-10 week old Canada goslings

(*B.c. maxima*) and 1-2 week old mallard ducklings (*Anas platyrhynchos*) were held in outdoor pens for varying lengths of time at Seney, Cusino, and White Pine. Their parasitemias were monitored and they were observed for clinical signs of leucocytozoonosis. Several were killed and examined for tissue stages. Thin blood films were stained with Giemsa's stain. Tissues were fixed in 10% formalin or carnoys' and processed using routine histologic methods. Blackflies (Simuliidae) were trapped after they had fed on goslings. Some were preserved in 70% ethyl alcohol for identification, others were held in cardboard containers in the laboratory at ambient temperature (mean 22.5 C, range 21.5 - 24.0 C) and midguts and salivary glands examined for sporogonic stages.<sup>2</sup> Packed cell volume (PCV) was determined by the microhematocrit method.

## RESULTS

### Seney

1975. Five goslings were exposed for varying lengths of time near the headquarters building from 7-9 July. Thereafter they were transported to Cusino and held for observation in a blackfly-proof building. Blood films and hematocrits were taken daily for 20 days. All five became infected with *L. simondi*. Merozoites were seen in erythrocytes on day 6 post-exposure (PE), mature round gametocytes on day 8 PE, merozoites in leucocytes on day 10 PE and mature elongate gametocytes on day 12 PE. The only signs of illness were slight anorexia and anemia (PCV 27%) in the bird with the highest parasitemia (67 gametocytes per 1000 RBC on day 12 PE). This bird had a slower rate of growth than the other four. Engorged *S. rugglesi* were collected from the goslings at the time of exposure.

1976. A total of 12, one week old mallard ducklings were exposed continuously on 19 May as sentinels. Blood films were made daily beginning on the 6th day PE. Twelve goslings were exposed continuously as sentinels on 26 May. Blood films were made daily from 6th-12th day PE. Merozoites were first seen in erythrocytes of one sentinel duckling on 31 May (day 12 PE) and one sentinel gosling on 2 June (day 7 PE). Signs of illness were not observed in any of the birds. Few simuliids were observed around their pens and attempts to collect engorged specimens yielded poor results. Several *S. innocens* were caught on 26 May. The first *S. rugglesi* were collected near the pens on 4 June.

On 2, 4, 6, 8 and 10 June, blood films were made from free ranging 1-3 week old goslings near the headquarters. These birds were part of a large gang brood of 43 goslings. This large and conspicuous group of birds provided a convenient means of monitoring morbidity and mortality during the first week in June, the period during which past epizootics had occurred. From 30 May-10 June the birds were observed closely and counted daily. None of these goslings died or showed signs of illness. Merozoites were seen in erythrocytes on 2 June, mature round gametocytes on 4 June, merozoites in leucocytes on 6 June and elongate gametocytes two days later. Five of these goslings (#53, 66, 67, 69, 70) were captured on 8 June; all were a single brood of 1-2 week old birds. They were taken to Cusino and were kept indoors. Blood films were made daily for two weeks and periodically thereafter. During several months of examination, two of the goslings (#66 and 67) showed only round gametocytes, the other three showed both round and elongate.

On 18 June, a 34-40 day old gosling was found on its back near the refuge

headquarters. Though alert, the bird was unable to stand. When placed on its feet, it ran stumbling and fell forward, rolling over on its back. The gosling was placed in captivity for observation. It had a relatively high parasitemia (14 gametocytes per 1000 RBC) with both round and elongate gametocytes and PCV of 53%. The PCV returned to normal after several days but otherwise the bird appeared abnormal and it was killed. Post mortem examination revealed an enlarged, dark colored spleen but no remarkable microscopic lesions in the brain, joints or other tissues.

On 18 and 19 June, a gosling (#278) and a duckling were exposed during daylight hours near the headquarters building. The birds were transported to a *L. simondi* free area and blood films made daily for three weeks. Both round and elongate gametocytes were seen in the gosling, but only a few round gametocytes in the duckling. *S. rugglesi* were collected from the birds during exposure.

Three goslings and three ducklings were exposed from 3-6 July near the headquarters. One of the ducklings was killed on the 5th and another on the 9th day PE. A gosling was killed on the 5th day PE and one died on the 9th day PE. Tissues from the day 5 PE gosling had only hepatic schizonts. Tissues from the gosling which died on the 9th day PE had hepatic schizonts and megaloschizonts in the spleen, lymph nodes, heart and other tissues. Although the specific cause of death was not determined, acute leucocytozoonosis was not ruled out. The third gosling became sick and examination of blood films revealed a fairly high parasitemia with both round and elongate gametocytes. It stayed alert but did not eat as much nor grow as fast as the other birds, and could not walk normally. Its condition deteriorated to the point where it could

barely move and was eventually killed. Post mortem examination did not reveal any remarkable gross or microscopic lesions in brain, joints or other tissues. The third duckling also developed both round and elongate gametocytes but did not show signs of illness.

#### Cusino

1976. Six goslings (#31, 32, 33, 34, 35, 51) were exposed at Hickey Creek during daylight hours from 27-29 May. Blood films were made daily from the 5th - 14th day PE and periodically thereafter for several months. All goslings had patent infections by the 6th day PE. Parasites occurred only in erythrocytes and were comprised exclusively of round gametocytes. Although relatively heavy parasitemias were seen in two of the birds, neither appeared to be ill.

Approximately 300 engorged *S. innocens* were collected from one of the goslings (#35) exposed on 26 May, and held for dissection. The next morning 10 flies were dissected and their salivary glands examined. Both glands from one fly contained sporozoites typical of *L. simondi*.

On 27 May, gosling 35 was again exposed at the same site. Although the weather was similar, markedly fewer flies were collected than during the same time interval on the previous evening.

On 3 June, exflagellating mature round gametocytes were observed in a wet preparation of blood taken from gosling 35; it was again exposed at Hickey Creek. Engorged *S. innocens* were collected and maintained in the laboratory. Midgut and salivary glands smears were prepared from six flies at 24, 48 and 72 h intervals. Stages of sporogony, including ookinetes and oocysts were abundant in the midguts. Within 72 h numerous sporozoites were observed in the salivary glands.

On 7 June, large numbers of *S. rugglesi* were collected from gosling #35 at Hickey Creek. Some were preserved in alcohol and others were maintained as above. Midgut and salivary gland smears were prepared at 24 h intervals. No sporogonic stages beyond the ookinete were seen.

On 10 June, engorged *S. rugglesi* were collected at Hickey Creek from a gosling (#32) with only round gametocytes in its blood. The flies were held as before for five days, triturated in saline, and inoculated into a gosling and duckling. The gosling died as a result of an accident. Blood films made daily for three weeks from the duckling contained both round and elongate gametocytes.

On 18 and 19 June, a *Leucocytozoon* free gosling (#224) and duckling were exposed during daylight hours on Hickey Creek. The birds were transported to an area free from *L. simondi* and blood films taken daily for three weeks. Only round gametocytes were seen in the gosling. The duckling showed both round and elongate gametocytes. At the time gosling 224 was being exposed, engorged *S. rugglesi* were collected from gosling 34. This bird had only round gametocytes in its blood and had been infected at the same site on 27 May by *S. innocens*. A wet mount of blood from gosling 34 examined prior to exposure showed exflagellation. The flies were held in the laboratory as before and several were examined at 24 h intervals for developing stages. No sporogonic stages beyond the ookinete were seen. At four days post blood meal (PBM) 70 of these flies were ground with saline in a glass tissue grinder and all the material was inoculated into a gosling and a duckling. No parasites were seen in blood films made daily for three weeks.

On 19 June, engorged *S. rugglesi* were collected from a gosling (#66) with round and elongate gametocytes in its

blood at Commencement Creek, a small stream a few km east of Cusino. This bird was from the brood captured at Seney on 8 June. It had been infected in May, presumably by *S. innocens*. A wet mount of its blood examined prior to exposure showed exflagellation. The flies were held as before and several examined at 24 h intervals for developing stages. No sporogonic stages beyond the ookinete were seen. At four days PBM, 70 flies were ground with saline in a tissue grinder and inoculated into a gosling and a duckling. Blood films taken daily for three weeks from both birds showed only small numbers of round gametocytes.

Three goslings and three ducklings were exposed 3-5 July. One of the goslings and one of the ducklings was killed on the 5th and 9th day PE and their tissues examined. Hepatic schizonts were seen in the duckling killed on the 5th day PE, and hepatic and megaloschizonts in the one killed on the 9th day PE. Only hepatic schizonts were seen in the goslings killed on day 5 and 9 PE. The third gosling and duckling both developed patent infections with round and elongate gametocytes in their blood.

On 5 July, engorged *S. rugglesi* were collected from gosling #278 at Commencement Creek. This gosling was infected on 18 June at Seney by *S. rugglesi* and had both round and elongate gametocytes in its blood. The flies were held as before and several examined at 24 h intervals for developing stages. Stages of sporogony, including ookinetes, and oocysts were abundant in midguts. The salivary glands contained numerous sporozoites by 56 h PBM. At 72 h PBM, the salivary glands from a single fly were suspended in saline and inoculated intravenously into a duckling and a gosling. Each bird received a single gland. Fifteen flies from the same

collection were ground with saline and inoculated into a gosling. Blood films were taken daily from each bird for three weeks. The duckling and gosling receiving glands showed only small numbers of round gametocytes, while the gosling receiving flies showed moderate numbers of round and elongate gametocytes.

#### White Pine

1975. Two 10 week old goslings were exposed continuously in a pen at the edge of one of the borrow pits from 1-31 July. Both became infected with *L. simondi*. A careful search of blood films taken every 2-3 days from PE day 13-30 showed only moderate numbers of round gametocytes. Neither bird showed signs of illness. Engorged *S. rugglesi* were collected from the goslings during mid June, July and August.

1976. Six goslings were exposed continuously from 28 May - 10 June. All became infected with *L. simondi*. Only moderate numbers of round gametocytes were seen in blood films taken on PE day 14 and 30. None of the birds showed signs of illness.

## DISCUSSION

### Schizogony

Two distinct patterns of development of *L. simondi* were observed in Canada geese originating from

different localities in upper Michigan (Table 1). At Seney the parasite underwent 'complete' development in most of the goslings with sporozoite-initiated hepatic schizonts, whose merozoites entered erythrocytes to form round gametocytes. This was followed by secondary schizogony (megaloschizogony) in cells of the RES whose progeny developed into elongate gametocytes within leucocytes. This is the normal sequence of development of *L. simondi* in ducks.<sup>1</sup> In contrast, only hepatic schizonts and round gametocytes were seen in all but one of the goslings exposed at Cusino and White Pine, as was observed also in Canada and domestic geese in Ontario.<sup>3</sup> The single Cusino-exposed gosling observed to be infected with round and elongate gametocytes may have been infected at Seney (the truck stopped briefly on route to Cusino and many *S. rugglesi* were noted around the vehicle).

### Sporogony

The apparent absence of sporogony in the first *S. rugglesi* that fed on infected goslings at Cusino in early June is puzzling. A similar "sporogony lag" of approximately three weeks in June has been observed for several years in *S. rugglesi* in Algonquin Park (Desser, unpublished). Sporogony in flies that have fed on infected goslings and were maintained in the laboratory, resumed in late June and early July in both Michigan and Ontario.

TABLE 1. Geographic variation in gametocytemia patterns in Canada goslings infected naturally with *L. simondi* at 3 sites in northern Michigan.

Location	birds with round gametocytes	birds with round and elongate gametocytes
Cusino	7	1
White Pine	8	0
Seney	2	11

### Pathogenesis

The gosling found sick near the headquarters at Seney on 18 June and the one exposed there on 3 July showed clinical signs consistent with acute leucocytozoonosis.<sup>1</sup> The absence of an epizootic among goslings at Seney in 1976 was unexpected in light of earlier reports and predictions.<sup>6,7</sup> Mortality amongst goslings from all causes was estimated at only 30%, well below the 60-90% seen during epizootic years and could be related to unfavourable climatic conditions resulting in a low density of simuliid vectors and/or the relatively late hatch of goslings at Seney, or perhaps some still unknown factor(s). The conditions which contributed to previous epizootics, assuming that they were due to *L. simondi*, probably involved an interplay between the weather, the time of hatching of the goslings and numbers of *S. innocens*. The presence of potentially pathogenic megaloschizonts in the tissues of goslings at Seney lends support to the view of Herman *et al.*<sup>7</sup> that *L. simondi* is primarily responsible for mortality during epizootic years.

### Epizootiology

There is a striking similarity between the vectors of *L. simondi* and their time of appearance in Michigan and in Algonquin Park. During May in Upper Michigan, the parasite is transmitted by *S. innocens*, which disappears in late May and early June and is replaced by *S. rugglesi*. In Algonquin Park, *S. anatinum* serves as the initial vector, followed by *S. rugglesi*.<sup>4</sup> *S. innocens* and *S. anatinum* are difficult to distinguish and may be the same species.<sup>7</sup>

The first goslings hatched on 10 May in 1976. The peak of the hatch occurred between the 12th and 15th. Therefore, the first free-ranging goslings at Seney were probably infected by *S. innocens*

about 25 May, when they were 10-13 days old. The majority were infected several days later. This is about the time that the first parasites were seen in sentinel ducklings at Seney and sporozoites were found in the salivary glands of the *S. innocens* taken at Hickey Creek. Presumably this fly had fed at least four days earlier on a duck in the vicinity. *S. innocens* at Seney could have become infected with *L. simondi* by feeding either on ducks or geese as both harbor chronic parasitemias during the winter, and gametocytes are available in the spring when *S. innocens* take their first blood meal.<sup>7</sup>

Observations reported herein and those from Algonquin Park indicate strain differences in *L. simondi* amongst geese. In areas such as Cusino, White Pine and Algonquin Park, where geese have been recently introduced and where a "duck strain" of *L. simondi* is well established, the parasite appears to undergo partial development and is relatively non-pathogenic. In areas such as Seney, where the breeding sites of geese and ducks have overlapped for many years, the parasite undergoes development similar to that in ducks and appears to be equally pathogenic. The situation is probably similar in Illinois where Levine and Hanson<sup>8</sup> reported elongate gametocytes in Canada geese and in New Brunswick, where they were noted by Herman and Bennett.<sup>5</sup>

Strain differences in *L. simondi*, particularly their potential for pathogenicity, may have implications in the selection of breeding sites for Canada geese in waterfowl sanctuaries. Implementation of intelligent policies for management of populations of Canada geese, especially on sanctuaries, refuges and reserves necessitates additional data on the strains of the parasite, their potential for disease, and their development in vectors.



**Acknowledgements**

We are grateful to all the staff at the Seney National Wildlife Refuge, Cusino Wildlife Research Station and the White Pine Copper Company for their help and cooperation. Mallard ducklings were contributed by the Max McGraw Wildlife Foundation. We extend special thanks to Louis Verme, Jack Frye, John Suffron and George Burger.

**LITERATURE CITED**

1. DESSER, S. S. 1967. Schizogony and gametogony of *Leucocytozoon simondi* and associated reactions in the avian host. *J. Protozool.* 14: 244-254.
2. ———, and A. M. FALLIS. 1967. A description of the stages in the sporogony of *Leucocytozoon simondi*. *Can. J. Zool.* 45: 275-277.
3. ———, and A. K. RYCKMAN. 1976. The development and pathogenesis of *Leucocytozoon simondi* in Canada and domestic geese in Algonquin Park, Ontario. *Can. J. Zool.* 54: 634-643.
4. FALLIS, A. M. and G. F. BENNETT. 1966. On the epizootiology of infections caused by *Leucocytozoon simondi* in Algonquin Park, Canada. *Can. J. Zool.* 44: 102-112.
5. HERMAN, C. M. and G. F. BENNETT. 1976. Use of sentinel ducks in epizootiological studies of anatid blood protozoa. *Can. J. Zool.* 54: 1038-1043.
6. ———, J. BARROW Jr. and I. B. TARSHIS. 1970. Epizootiology of *Leucocytozoon* in Canada geese (*Branta canadensis*). *J. Parasit.* 56(II): 143.
7. ———, ———, and ———. 1975. Leucocytozoonosis in Canada Geese at the Seney National Wildlife Refuge. *J. Wildl. Dis.* 11: 404-411.
8. LEVINE, N. D. and H. C. HANSON. 1953. Blood parasites of the Canada Goose *Branta canadensis interior*. *J. Wildl. Manage.* 17: 185-196.
9. SHERWOOD, G. A. 1968. Factors limiting production and expansion of local populations of Canada geese. Pages 72-85. In: *Canada Goose Management*. R. L. Hine and C. Schoenfeld, eds. Dumber Educational Research Services Inc., Madison.

Received for publication 13 June 1977