

SPONTANEOUS RENAL DISEASE IN BEAVER IN LOUISIANA 1

Authors: STUART, B. P., CROWELL, W. A., ADAMS, W. V., and MORROW, D. T.

Source: Journal of Wildlife Diseases, 14(2) : 250-253

Published By: Wildlife Disease Association

URL: <https://doi.org/10.7589/0090-3558-14.2.250>

BioOne Complete (complete.BioOne.org) is a full-text database of 200 subscribed and open-access titles in the biological, ecological, and environmental sciences published by nonprofit societies, associations, museums, institutions, and presses.

Your use of this PDF, the BioOne Complete website, and all posted and associated content indicates your acceptance of BioOne's Terms of Use, available at www.bioone.org/terms-of-use.

Usage of BioOne Complete content is strictly limited to personal, educational, and non - commercial use. Commercial inquiries or rights and permissions requests should be directed to the individual publisher as copyright holder.

BioOne sees sustainable scholarly publishing as an inherently collaborative enterprise connecting authors, nonprofit publishers, academic institutions, research libraries, and research funders in the common goal of maximizing access to critical research.

SPONTANEOUS RENAL DISEASE IN BEAVER IN LOUISIANA [□]

B. P. STUART,[□] W. A. CROWELL,[□] W. V. ADAMS[□] and D. T. MORROW[□]

Abstract: Interstitial nephritis was present in 13 of 25 adult beavers (*Castor canadensis*). Results of serum chemistry, serotyping, and culture for leptospire were compared with the extent of renal lesions. Although the pathogenesis of the nephritis was not determined, the survey provided baseline information on spontaneous renal disease in beavers.

INTRODUCTION

The beaver, *Castor canadensis*, abounds in the nation's wetlands. Because of declining public interest in beaver pelts, and general lack of hunter interest, it had not been economically feasible to study the diseases of beaver in the wild. Reports published to date have emphasized parasitism and tularemia.^{1,8} Only one report has been published on the morphology of spontaneous diseases of individual organ systems, a medial arterial sclerosis described in captive beaver.²

The extensive distribution of *C. canadensis* in Louisiana, together with the high prevalence of leptospirosis in this state, suggested that beaver might be a reservoir of leptospirosis for humans and domestic animals.⁸ Consequently, from 1961 to 1967 the beaver population was surveyed to determine the prevalence of leptospirosis. Tissue, body fluids, and necropsy reports from beaver collected during that survey were reexamined for this study in an attempt to determine the prevalence of spontaneous renal disease.

MATERIALS AND METHODS

During a survey to determine the prevalence of leptospirosis in wildlife, 40 beaver were trapped from 1961 to 1967. At necropsy, serum was collected for leptospire serotyping and stored at -10 C. Kidneys and urine were cultured for leptospire as described by Roth *et al.*⁶ Kidney samples were fixed in formalin solution, labeled, sealed with paraffin, and stored at ambient temperatures. Kidney samples from 25 of the 40 animals were examined during this retrospective study. Samples from the remaining 15 animals were unsuitable for examination because of drying and other forms of deterioration. The kidneys were embedded in paraffin, sectioned at 6 μ m, and stained with hematoxylin and eosin. Special stains used on selected kidney sections were: Periodic-acid Schiff (mucopolysaccharides), Warthin-Starry (spirochetes), Ziehl-Neelsen (acid fast), Gomori methenamine silver nitrate (fungi), and Goodpasture's (bacteria). Microscopic lesions were graded: 0 (no lesions seen), 1+ (single or mild focal lesions), 2+ (moderate or multifocal

[□] This study was conducted as a cooperative effort between the Department of Veterinary Pathology (Stuart and Crowell) and Veterinary Science (Adams) at Louisiana State University, Baton Rouge, Louisiana.

[□] Veterinary Diagnostic and Investigational Laboratory, College of Veterinary Medicine, University of Georgia, Tifton, Georgia 31794, USA.

[□] Department of Veterinary Pathology, College of Veterinary Medicine, University of Georgia, Athens, Georgia 30602, USA.

[□] Department of Veterinary Science, Louisiana State University, Baton Rouge, Louisiana 70803, USA.

lesions), 3+ (extensive or disseminated lesions).

Serum samples from five animals with renal lesions and six animals without renal lesions were analyzed for blood urea nitrogen (BUN) and serum creatinine (SC).⁵ Results of culture and serology for leptospire on these 25 animals were retrieved from data collected during the original survey and compared with the results of histopathology and serum chemistry.

RESULTS

Thirteen of the 25 (52%) animals had interstitial foci of lymphocytes and macrophages that were graded as 1+ or greater (Table 1). Multinucleate giant cells and a slight amount of fibrosis were seen within the renal interstitium of 11 of 25 (44%) animals examined (Fig. 1). In some of the 11 cases, mononuclear cells and, occasionally, eosinophils were associated with the giant cells. The cytoplasm of the giant cells was finely vacuolated, and contained granular PAS-positive material similar to the material within the cytoplasm of tubular

epithelial cells. Special stains did not demonstrate bacteria, fungi or spirochetes. A mild infiltration of lymphocytes was seen in the renal pelvis of 3 of 25 (12%) animals. No lesions were detected in the glomeruli.

Examination of the records revealed that only 2 of 25 beaver showed any evidence of leptospirosis; *Leptospira australis* was isolated from one, and positive titers for *L. autumnalis* (1:100) and *L. pomona* (1:400) were present in the second. No significant lesions were seen in either of these two cases.

Results of renal function tests were essentially identical, regardless of the presence or absence of lesions (Table 2).

DISCUSSION

Microscopic lesions were seen in the kidneys of 13 (52%) beaver. The most common lesion was a focal or multifocal granulomatous interstitial nephritis associated with giant cells. The renal lesions did not affect renal function as both BUN and SC levels were similar for beaver with or without lesions. Leptospire were isolated from only one

TABLE 1. Distribution of spontaneously occurring renal lesions and results of leptospire serology and culture in 25 beaver (*Castor canadensis*) trapped in Louisiana, 1961-1967.

Lesion	Renal tubules	Renal interstitium	Renal glomeruli	Renal pelvis	Leptospire serology	Leptospire culture
None	7 ^a (7) ^b	7 (5)	12 (13)	10 (12)	1 (0)	1 (0)
Mild	4 (5)	4 (6)	0 (0)	2 (1)	0 (0)	0 (0)
Moderate	1 (1)	1 (1)	0 (0)	0 (0)	0 (0)	0 (0)
Extensive	0 (0)	0 (1)	0 (0)	0 (0)	0 (0)	0 (0)
Percent involved ^c	20 (24)	20 (32)	0 (0)	8 (4)	4 (0)	4 (0)

^aNumber refers to number of male beavers in each category.

^bNumber refers to number of female beavers in each category.

^cNumber refers to percentages of total males and females, respectively, showing lesions or giving positive results for the condition or test listed in each column.

⁵ Hycel, Inc., P.O. Box 36329, Houston, Texas.

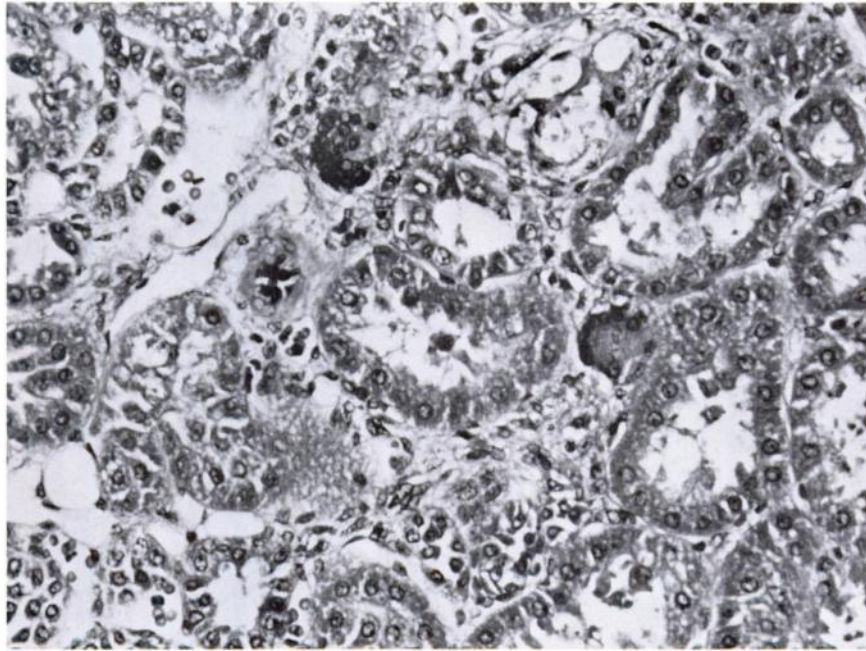


FIGURE 1. Interstitial fibrosis, mononuclear and giant cell infiltrate within the renal cortex of an adult beaver (*Castor canadensis*). H and E \times 160.

TABLE 2. Blood urea nitrogen, serum creatinine, and severity of interstitial renal lesions seen in beaver (*Castor canadensis*).

Animal no:	BUN	Creatinine	Leptospire	Interstitial lesions ^c
8	21	2.0	—	2+
19	34	2.1	—	1+
28	19	1.5	—	2+
32	16	1.2	—	2+
34	19	1.7	—	3+
6 ^a	12	2.2	+	0
12 ^b	16	1.5	+	0
18	10	1.0	—	0
27	32	1.0	—	0
33	32	0.7	—	0
35	16	1.3	—	0

^aAnimal no. 6 was seropositive for *L. autumnalis* (1:100) and *L. pomona* (1:400).

^bAnimal no. 12 was positive for *L. australis* by culture.

^cInterstitial lesions were graded as follows: 0 (no lesions seen), 1+ (single or mild focal lesions), 2+ (moderate or multifocal lesions), and 3+ (extensive or disseminated lesions).

beaver and a serologic titer to leptospire was found in another. Neither animal had kidney lesions and renal function tests indicated both were normal, suggesting that the lesions encountered in other beaver were not a result of leptospirosis.

The presence of eosinophils and giant cells in the kidney might suggest parasitism; however, no parasites were seen. The granulomatous cellular infiltrate was not caseous and consequently did not appear to be a manifestation of tularemia.⁷

Normal results obtained from renal function tests in animals with lesions in the kidney could be explained by the observation that these tests reportedly do not show significant deviation from the norm until over two-thirds of the nephrons are affected.³

The present study indicates that renal disease is common in beaver but fails to explain the pathogenesis of the condition. While lesions appear to be sub-clinical, the results might serve as a baseline for a study on the pathology of the kidney for this species.

LITERATURE CITED

1. BELL, J.F. and S.J. STEWART. 1975. Chronic shedding tularemia nephritis in rodents: Possible relation to occurrence of *Francisella tularensis* in lotic waters. *J. Wildl. Dis.* 11: 421-430.
2. DIETERICH, R.A. 1969. Medial arterial sclerosis in captive beavers, *Castor canadensis* Kuhl. *Bull. Wildl. Dis. Ass.* 5: 115-116.
3. OSBORN, C.A., D.G. LOW and D.R. FINCO. 1972. *Canine and Feline Urology*. W.B. Saunders Co., Philadelphia, Pa.
4. ROTH, E.E. 1964. Leptospirosis in wildlife in the United States. *Am. vet. med. Ass. Scien. Proc.* 101st Ann. Meet.: 211-218.
5. ———, W.V. ADAMS, K. NEWMAN, G.E. SANFORD, B. GREER and K. LOWE. 1965. The epidemiology of leptospirosis in Louisiana. *J. Louisiana State Med. Soc.* 117: 110-115.
6. ———, C. LINDER and W.V. ADAMS. 1961. The use of agar plates as an aid for the isolation of leptospire. *Am. J. Vet. Res.* 22: 308-312.
7. SMITH, H.A., T.C. JONES and R.D. HUNT. 1972. *Veterinary Pathology* 4th Ed. Lea and Febiger, Philadelphia, Pa.
8. SMITH, H.J. and R. MCG. ARCHIBALD. 1967. On the incidence of gastrointestinal parasites in Nova Scotia beaver. *Can. J. Zool.* 45: 659-661.

Received for publication 5 July 1977