



## **TUBERCULOSIS IN MARINE TROPICAL FISHES IN AN AQUARIUM**

Authors: GIAVENNI, R., FINAZZI, M., POLI, G., and GRIMALDI, E.

Source: Journal of Wildlife Diseases, 16(2) : 161-168

Published By: Wildlife Disease Association

URL: <https://doi.org/10.7589/0090-3558-16.2.161>

---

BioOne Complete ([complete.BioOne.org](https://complete.BioOne.org)) is a full-text database of 200 subscribed and open-access titles in the biological, ecological, and environmental sciences published by nonprofit societies, associations, museums, institutions, and presses.

Your use of this PDF, the BioOne Complete website, and all posted and associated content indicates your acceptance of BioOne's Terms of Use, available at [www.bioone.org/terms-of-use](https://www.bioone.org/terms-of-use).

Usage of BioOne Complete content is strictly limited to personal, educational, and non - commercial use. Commercial inquiries or rights and permissions requests should be directed to the individual publisher as copyright holder.

---

BioOne sees sustainable scholarly publishing as an inherently collaborative enterprise connecting authors, nonprofit publishers, academic institutions, research libraries, and research funders in the common goal of maximizing access to critical research.

## TUBERCULOSIS IN MARINE TROPICAL FISHES IN AN AQUARIUM

R. GIAVENNI and M. FINAZZI, Istituto di Anatomia Patologica Veterinaria e Patologia Aviare, Università degli Studi, Milano, Italy

G. POLI, Istituto di Microbiologia e Immunologia Veterinaria, Università degli Studi, Milano, Italy

E. GRIMALDI, C.N.R., Istituto Italiano di Idrobiologia "Marco de Marchi", Pallanza, Novara, Italy

**Abstract:** Skin, gill and visceral tubercle lesions were detected in marine tropical fish in an aquarium. Ninety-seven fish of 17 different genera were affected. The tubercles consisted of a wall of densely packed epithelioid cells and necrotic center packed with acid-fast bacilli identified as *Mycobacterium marinum*.

### INTRODUCTION

Tuberculosis has been identified in at least 150 marine and freshwater fish species.<sup>10</sup> Although classification of acid-fast bacilli isolated on artificial media is difficult, the bacteria most frequently observed are *Mycobacterium marinum* and *Mycobacterium fortuitum*.<sup>10,12,14</sup>

Tuberculous lesions in fishes normally are localized in both the skin and internal organs,<sup>11</sup> and consist of nodular (sometimes ulcerated) structures with a typical granulomatous pattern.<sup>1</sup> The histologic features of the granulomas appear to vary in the different fish species. Besides nodules with extensive central necrosis and calcification, lesions with sarcomatous structures have been described.<sup>8</sup> One of the consistent histologic properties of the tuberculous granuloma of fish is the absence of giant cells, though such cells occasionally have been observed.<sup>20,21</sup>

An important aspect of fish tuberculosis is that some of the causative mycobacteria also are pathogenic for man. Skin lesions (ulcers or abscesses) and lymph node infections from *Mycobacterium marinum*, *M. balnei*, *M. fortuitum* have been described in humans<sup>9,10</sup> exposed to fishes infected with tuberculosis, especially if the in-

dividuals have been subjected to immunosuppressive treatments.<sup>16</sup>

The following is a report of fish tuberculosis observed in an aquarium where environmental conditions were not completely suitable.

### MATERIALS AND METHODS

Approximately 300 marine and freshwater tropical fish, including dead, diseased and apparently healthy subjects, were submitted for examination. Skin and gills were examined with a magnifying lens. Fish were subsequently examined at necropsy and samples of skin lesions, gills and internal organs were fixed in 10% neutral buffered formalin, embedded in paraffin, sectioned at 5-10  $\mu\text{m}$  and stained with hematoxylin-eosin, Mallory's anilin blue, silver impregnation according to Gomori, Alcian Blue-PAS, Ziehl-Neelsen acid fast and von Kossa's.

Smears made from both the nodular lesions found in the spleen and gills, and from the cultured colonies, were stained according to the Ziehl-Neelsen method and microscopically examined for acid-fast bacilli.

Specimens, aseptically obtained from the lesions in the spleen, were cultured on TB  $\square$  broth, Dubos broth, Dubos blood

$\square$  Thomas and Broom

agar, Petragnani medium, Middlebrook 7H10 agar, I.U.T.M. medium.<sup>2</sup>

Specimens obtained from the lesions in the gills were treated with 4% NaOH before culturing; after 10 min contact with NaOH the pH was neutralized using a few drops of 1N HCl. All media were incubated at both 25 C and 37 C.

To differentiate and identify the isolates, growth rate, colonial morphology and pigment production were first observed; the following tests were then performed utilizing the method of Runyon *et al.*:<sup>18</sup> growth in relation to temperature, nitrate reduction, catalase drop method, catalase test after 68 C heating, urea hydrolysis and growth on McConkey agar.

## RESULTS

The disease, which appeared exclusively in marine tropical fishes (97 subjects from 17 different genera, Table 1), showed variable clinical signs including dyspnea, immobility or ataxia, a darker than usual color and focal skin lesions, such as scale loss (Fig. 1), nodules, ulcers, fin necrosis, mutilation and sometimes exophthalmus.

Mortality, although persistent but not high in relation to the chronic development of the disease, was estimated to be about 5-10% of the affected fishes during the observation period.

The environmental conditions of the aquarium were not suitable due to fish crowding and continuous introduction of new subjects.

TABLE 1. Family and genus of marine tropical fishes affected with tuberculosis.

Family	Genus	Cases Observed
Pomacentridae	<i>Abudefduf</i>	32
	<i>Dascyllus</i>	19
	<i>Pomacentrus</i>	18
	<i>Chromis</i>	5
Acanthuridae	<i>Acanthurus</i>	3
	<i>Paracanthurus</i>	3
	<i>Naso</i>	1
Chaetodontidae	<i>Chaetodon</i>	4
	<i>Forcipiger</i>	2
	<i>Chelmon</i>	1
Pomacantidae	<i>Centropyge</i>	2
	<i>Genicanthus</i>	2
Pseudochromidae	<i>Gramma</i>	1
	<i>Pseudopleksiops</i>	1
Serranidae	<i>Cromileptis</i>	1
	<i>Epinephelus</i>	1
Labridae	<i>Thalassoma</i>	1
		97

<sup>2</sup> Prepared according to the formulation of the Laboratory Committee of the International Union against Tuberculosis for the cultivation of *Mycobacterium tuberculosis*.




FIGURE 1. Tubercular skin ulcers in *Chromis cyaneus* (arrows).

Internal examination of the dead fish revealed translucent or opaque miliary foci, scattered or closely grouped, which in some cases caused a considerable increase in the volume of the affected organs (up to 5 times the normal size). Among the fish examined at necropsy, approximately 75% had miliary lesions in the spleen (Fig. 2). Liver lesions were encountered in 50% and kidney lesions in 35% of cases. Nodules often were present in the heart and ovaries, but were encountered less frequently.

Histologic examination of the affected organs revealed that the lesions were substantially similar in the different species observed with the exception of the gills of one fish, described below.

In general, the lesions appeared as granulomatous foci, either isolated or coalesced (Fig. 3), with necrotic centers and epithelioid cells in the walls (Fig. 4). Giant cells were absent. Scattered melanocytes frequently were observed among the epithelioid cells of the granuloma or in the thin layer of surrounding connective tissue. The necrotic centers of the granulomatous foci often contained large calcium precipitates and usually were packed with acid-fast bacilli (Fig. 5).

The epithelioid cells in the walls of these necrotic foci often appeared very

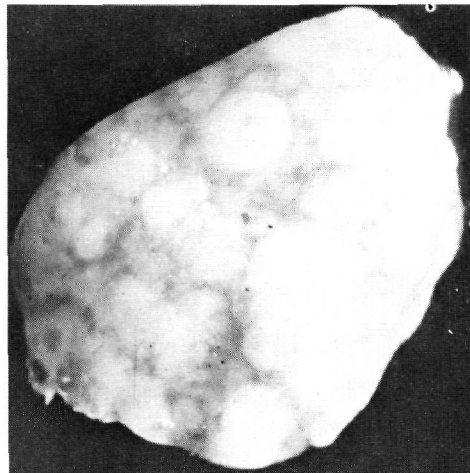
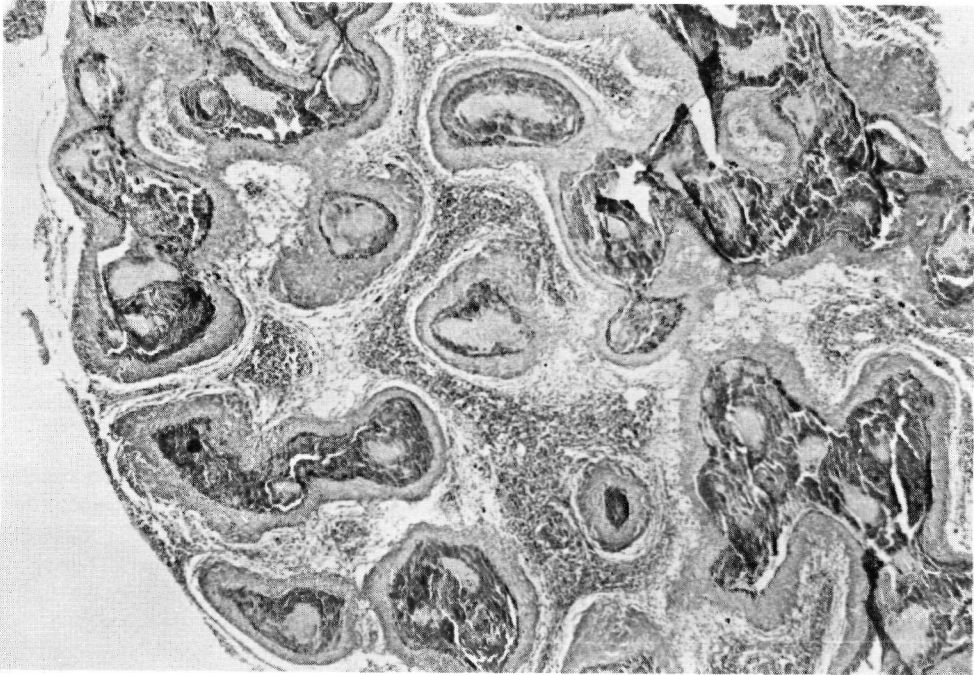


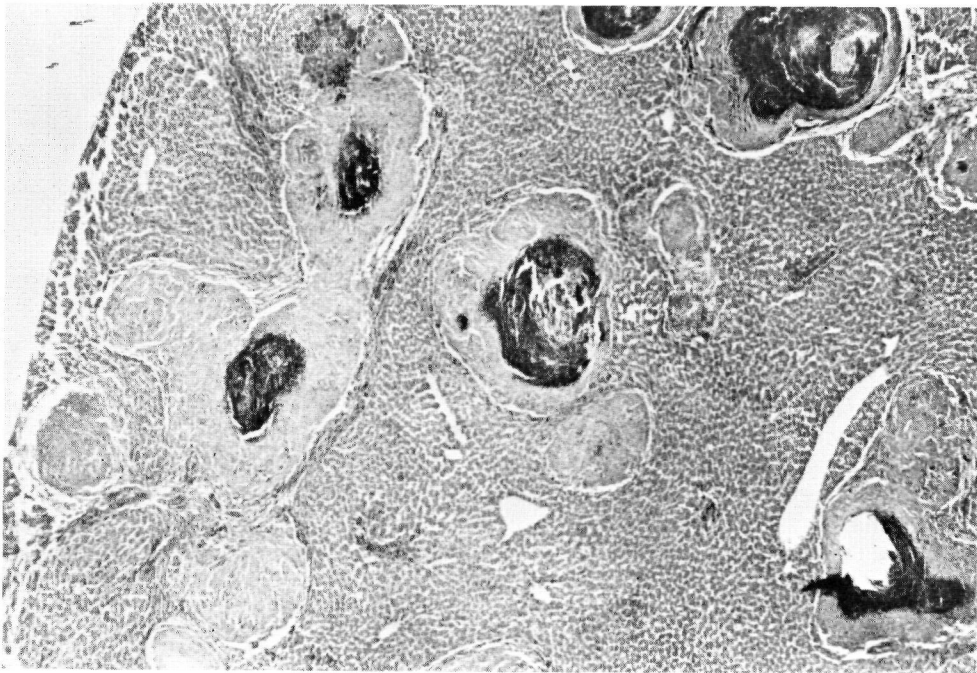
FIGURE 2. Scattered or confluent tubercle granulomas in the spleen.

compact (Fig. 6), free from consistent fibrillar structures, and separated from the necrotic center by a marked alcianophilic halo, due to the presence of free mucopolysaccharidic acids. On the other hand the alcianophily of the perifocal connective tissue was very weak.

As indicated above, in one case the gill lesions had a different pattern. They consisted of areas of necrosis with no



**FIGURE 3.** Spleen section with disseminated tubercle granulomas. H&E  $\times 30$



**FIGURE 4.** Liver section with disseminated tubercle granulomas with necrotic center and thick wall of epithelioid cells. H&E  $\times 30$

cellular reaction scattered throughout the branchial filament and thus were considered to be derived from a very recent infection. Within these areas, and particularly in the related vessel lumina, acid-fast bacilli sometimes were encountered in a very large number and so massively crowded as to suggest bacterial thrombi or emboli (Fig. 7).

The best growth of acid-fast bacilli was observed on I.U.T.M., Petragnani and Middlebrook 7H10 agar, incubated at 25 C; at 37 C colonies also were present but with a reduced growth rate. Colonies developing after seven or more days were rounded, rough and flat, with elevated centers. Colonies grown in the dark were unpigmented; nitrate reduction, catalase drop test, 68 C catalase and growth on McConkey agar were negative, while urea hydrolysis was positive; when grown in light or exposed briefly to light the colonies became brilliant yellow to orange. In the smears taken from lesions

or from colonies, typical acid-fast bacilli were seen.

The results of the tests for species identification allowed us to identify the isolates as *Mycobacterium marinum*, belonging to the photochromogenes of Runyon's group 1.

It is interesting to note that the employee who took care of the diseased fishes developed nodular skin lesions on his hands, from which a cold blooded animal-related mycobacterium was isolated.

## DISCUSSION

This report illustrates the considerable economic loss which can result from tuberculosis in an infected aquarium, and also the many different fish species which can be involved.

Some papers<sup>7,15</sup> and our personal experience suggest that mycobacterial infections are endemic in many of the

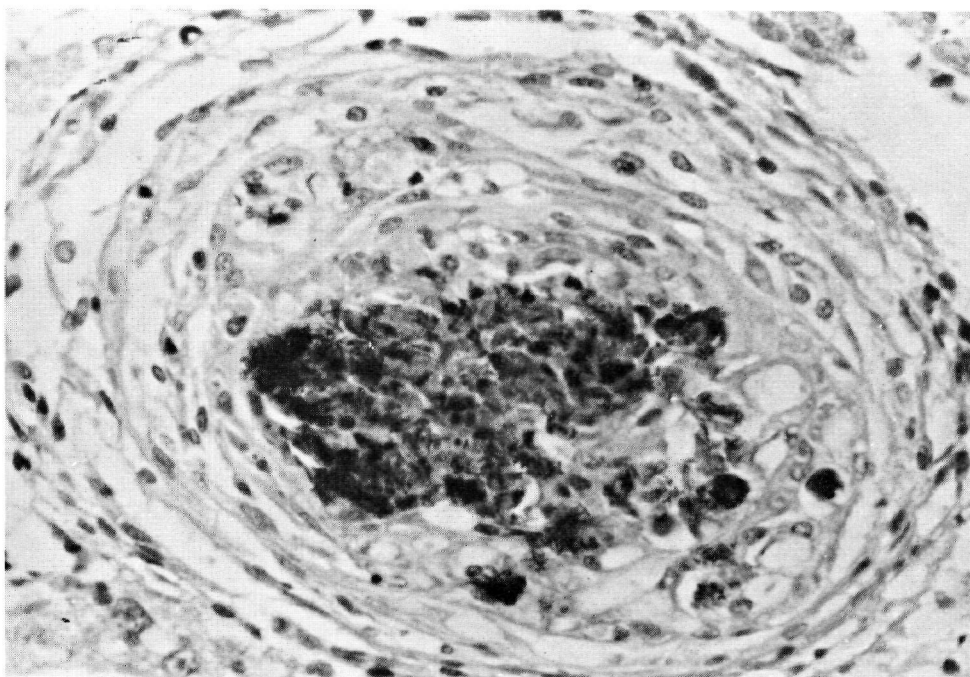


FIGURE 5. Numerous bacteria in the inner part of a tubercle granuloma. Liver, Ziehl-Neelsen, 300X

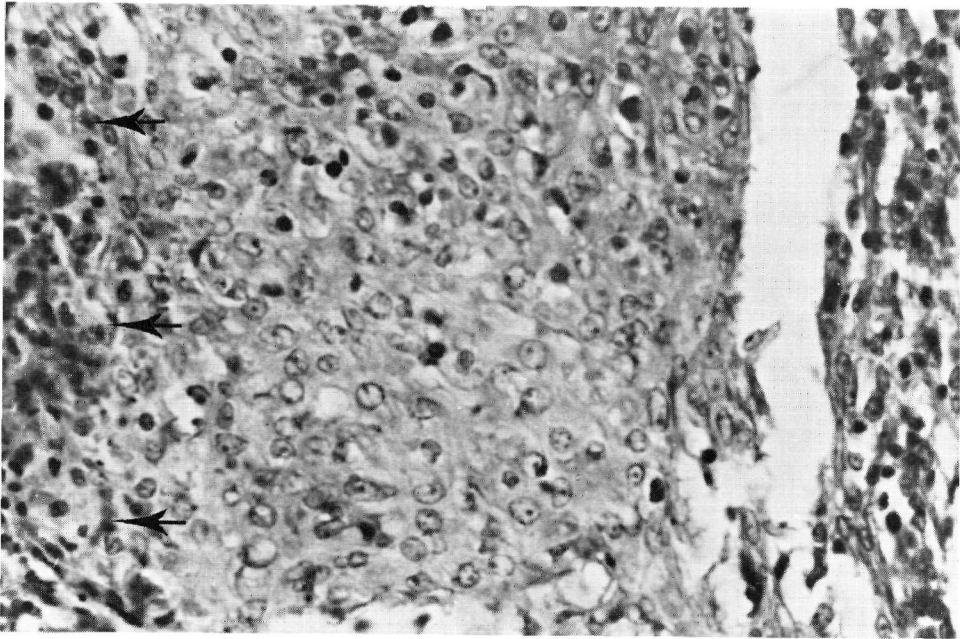


FIGURE 6. High magnification of a tubercle granuloma: the wall is composed of densely packed epithelioid cells with scattered lymphocytes. Necrotic center on the left (arrow). Liver, H&E  $\times 300$

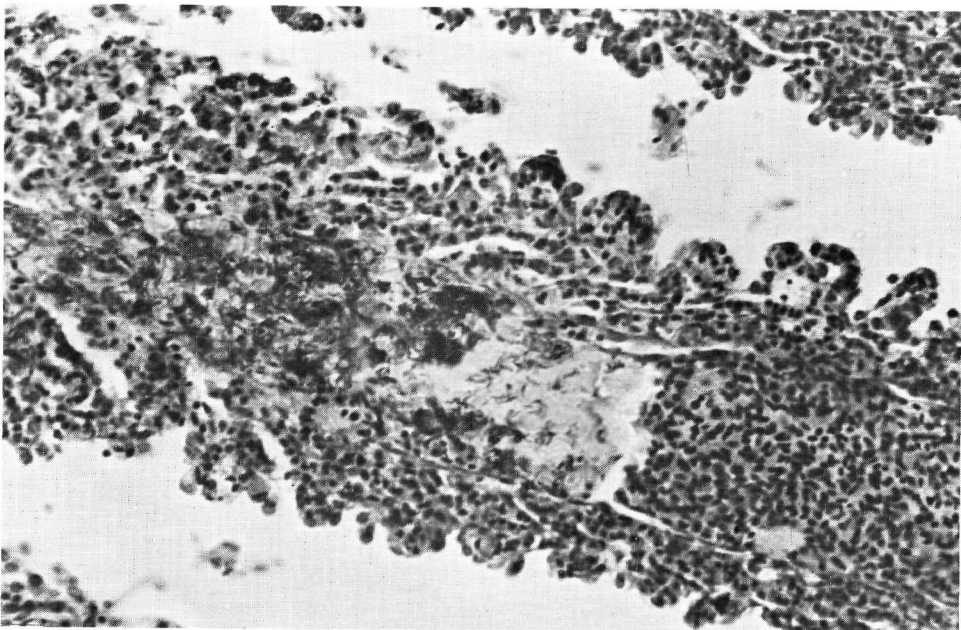


FIGURE 7. Thrombotic axial blood vessel of a gill filament with crowding of tubercle bacilli. Ziehl-Neelsen,  $125\times$

species considered in this report and that the unnatural environmental conditions, like those of an aquarium, can promote the appearance of the disease.

The etiologic agent, *M. marinum*, has been cultured repeatedly from both fresh and salt water fish infected with tuberculosis.<sup>3,9,11</sup> We also observed the simultaneous infection of a human with a cold-blooded animal-related mycobacteria, an additional case to be added to the literature.<sup>4,9,10,16</sup>

The high prevalence of lesions in the spleen compared to other organs appears of diagnostic value. The wide dissemination of nodular lesions seems to suggest a hematogenous spread of mycobacteria not substantially unlike that encountered in birds and mammals. The histology of the nodular lesions revealed a granulomatous structure with a necrotic-calcified center rich in mycobacteria and a dense zone of epithelioid macrophages free from giant cells. The latter occasionally contained melanocytes.<sup>6</sup>

The histologic and histochemical findings of the granuloma in the material we observed appear, for the most part, to be identical in the different fish species examined. In one case early gill necrosis was observed. The lesions were not delimited by granulomatous or connective cell proliferation, but were rich in blood vessels with thrombotic masses crowded with mycobacteria. Similar findings have been reported previously in marine fishes<sup>2</sup> and Pacific salmon.<sup>13,17</sup>

Some forms of tuberculosis, essentially characterized by the proliferation of connective cells with a sarcomatous appearance, but without necrosis, also have been described in fishes.<sup>7,8,19</sup>

The fact that in the present study different fish species had strongly similar lesions, while in the literature quite variable findings are reported, may justify the hypothesis that various *Mycobacterium* species or strains can influence the pathologic pattern of the disease.

### Acknowledgements

The authors wish to express their appreciation to Mr. Ardensi Battista for his assistance in macro- and microphotography.

### LITERATURE CITED

1. AMLACHER, E. 1968. Experimentelle Befunde zur Pathologie und Bakteriologie der Fischtuberkulose. Z. Fisch. N.F. 16: 1-30.
2. ARONSON, J.D. 1926. Spontaneous tuberculosis in salt water fish. J. Inf. Dis. 39: 315-320.
3. CONROY, D.A. 1970. Piscine tuberculosis in the sea water environment. A Symposium on disease of fishes and shellfishes. Am. Fish. Soc., Washington, D.C. N.5: 273-283.
4. JANSSEN, W.A. 1970. Fish as potential vectors of human bacterial disease. A Symposium on disease of fishes and shellfishes. Am. Fish. Soc., Washington, D.C., N.5: 284-290.
5. JOHNSTONE, J. 1913. Diseased conditions of fishes. Rept. Lancs. Sea Fish. Lab. 21: 20-25.
6. ———. 1927. Diseased conditions of fishes. Rept. Lancs. Sea Fish. Lab. 35: 162-163.
7. LAUER, M. 1976. La tuberculose des poissons, une maladie inhérente aux conditions d'élevage. Rev. fr. Acquariol. 1: 42-44.



8. LUND, J.E. and C.S. ABERNETHY. 1978. Lesions of tuberculosis in mountain whitefish (*Prosopium williamsoni*). *J. Wildl. Dis.*, 14: 222-228.
9. MIDDLEBROOK, G. 1965. In: *Bacterial and mycotic infections of man*. 4th ed., Dubos and Hirsch, Ed. J.B. Lippincott Co., Philadelphia. pp. 521-522.
10. NIGRELLI, R.F. and H. VOGEL. 1963. Spontaneous tuberculosis in fishes and other cold-blooded vertebrates with special reference to *Mycobacterium fortuitum cruz* from fish and human lesions. *Zoologica*, 48: 131-144.
11. OPPENHEIMER, C.H. 1962. In: *Fish as Food*, vol. 2. G. Borgstrom, Ed. Academic Press, New York. pp. 541-566.
12. OTTE, E. 1969. Mykobakterielle Infektionen bei Fischen. Erreger und ihre Beurteilung. *Z. Fisch. N.F.* 17: 515-546.
13. PARISOT, T.J. and E.M. WOOD. 1960. A comparative study of the causative agent of a mycobacterial disease of salmoid fishes. 2. A description of the histology of the disease in Chinook salmon (*Oncorhynchus tshawytscha*) and a comparison of the staining characteristics of the fish disease with leprosy and human tuberculosis. *Am. Rev. Resp. Dis.*, 82: 212-222.
14. REICHENBACH-KLINKE, H.H. 1972. Some aspects of mycobacterial infections in fish. *Symp. Zool. Soc. Lond.* 30: 17-24.
15. ———. 1977: Infektionskrankheiten bei tropischen Zierfischen und ihre Bekämpfung. *Prakt. Tierarzt.* 58: 63-64 (Collegium Veterinarium 1976).
16. RICKEN, K.H. and M. LAUER. 1977. Die pathogene Bedeutung fischpathogener Mykobakterien für den Menschen. *Tierarzt. Praxis. München*, 5: 115-117.
17. ROSS, A.J. 1970. Mycobacteriosis among Pacific salmoid fishes. A Symposium on disease of fishes and shellfishes. *Am. Fish. Soc.*, Washington, D.C. N.5: 279-283.
18. RUNYON, H.E., G.P. KUBIKA, W.C. MORSE, C.R. SMITH and L.G. WAYNE. 1970. *Manual of clinical microbiology*. Blair, Lennette, Truant. Eds. Williams-Wilkins Co., Baltimore.
19. SUTHERLAND, P.L. 1922. A tuberculosis-like disease in a salt-water fish (halibut) associated with the presence of an acid-fast tubercle-like bacillus. *J. Path. Bact.*, 25: 31-36.
20. TIMUR, G., R.J. ROBERTS and A. McQUEEN. 1977. The experimental pathogenesis of focal tuberculosis in the plaice (*Pleuronectes platessa*). *J. Comp. Path.* 87: 83-88.
21. WOOD, E.M., W.T. YASUTAKE and W.L. LEHMAN. 1955. A mycosis-like granuloma of fish. *J. Infect. Dis.* 97: 262-267.

*Received for publication 2 August 1979*