

## **LYMPHOSARCOMA IN A HARBOR SEAL (*Phoca vitulina richardii*) 1**

Authors: STROUD, RICHARD K., and STEVENS, DAVID R.

Source: Journal of Wildlife Diseases, 16(2) : 267-270

Published By: Wildlife Disease Association

URL: <https://doi.org/10.7589/0090-3558-16.2.267>

---

BioOne Complete ([complete.BioOne.org](https://complete.BioOne.org)) is a full-text database of 200 subscribed and open-access titles in the biological, ecological, and environmental sciences published by nonprofit societies, associations, museums, institutions, and presses.

Your use of this PDF, the BioOne Complete website, and all posted and associated content indicates your acceptance of BioOne's Terms of Use, available at [www.bioone.org/terms-of-use](https://www.bioone.org/terms-of-use).

Usage of BioOne Complete content is strictly limited to personal, educational, and non - commercial use. Commercial inquiries or rights and permissions requests should be directed to the individual publisher as copyright holder.

---

BioOne sees sustainable scholarly publishing as an inherently collaborative enterprise connecting authors, nonprofit publishers, academic institutions, research libraries, and research funders in the common goal of maximizing access to critical research.

## LYMPHOSARCOMA IN A HARBOR SEAL (*Phoca vitulina richardii*)<sup>□</sup>

RICHARD K. STROUD<sup>□</sup> and DAVID R. STEVENS<sup>□</sup> Veterinary Diagnostic Laboratory, School of Veterinary Medicine, Oregon State University, Corvallis, Oregon 97331, USA.

**Abstract:** Lymphosarcoma is described in a wild juvenile harbor seal (*Phoca vitulina richardii*). Gross lesions included hepatomegaly, splenomegaly and lymphadenopathy. Neoplastic lymphoid cells were observed histologically in lung, kidney, liver, spleen, adrenals, bone marrow and visceral and peripheral lymph nodes.

### INTRODUCTION

Lymphoid neoplasia has been reported in several pinniped species. Two cases of "leukosis", one in a two-year-old seal and another in a four-year-old walrus (species not stated in either case) were reported from the Copenhagen Zoo.<sup>2</sup> Lymphosarcoma was reported in a neonatal northern fur seal (*Callorhinus ursinus*) from the Pribilof Islands, Alaska.<sup>3</sup> Neoplasia of the lymphoid tissues was diagnosed in a young California sea lion (*Zalophus californianus*) (pers. comm., Dr. L. Cornell). Malignant leukemic lymphoma was described in two harbor seals (*Phoca vitulina geronimensis*) that shared the same pool at the San Diego Zoo.<sup>1</sup> Features of lymphosarcoma in these harbor seals were similar to those reported for domestic animals including hepatomegaly, splenomegaly, lymphadenopathy and infiltration of various tissues by neoplastic lymphoid cells and lymphoblastic leukemia.<sup>1,4</sup>

The lack of information concerning neoplasia in wild pinnipeds provided the impetus for the following case report which describes lymphosarcoma in a free

ranging juvenile female harbor seal (*Phoca vitulina richardii*).

### CASE HISTORY

The seal was found stranded on the Oregon Coast near Tillamook Bay by biologists from the Oregon Department of Fisheries and Wildlife. The biologist who euthanized the seal reported that the animal was in severe respiratory distress. A post mortem examination was conducted at the Oregon State University Veterinary Diagnostic Laboratory approximately 24 h after death. Tissues were fixed in neutral buffered 10% formalin, embedded in paraffin, sectioned at 6  $\mu$ m and stained with hematoxylin and eosin by routine methods.

### NECROPSY FINDINGS

The body length was 124 cm, girth 82.5 cm and weight 41 kg. The blubber layer was 2.0 to 2.5 cm thick and normal in consistency. Approximately 500 ml of clear fluid was present in the peritoneal cavity. The spleen was markedly enlarged (42  $\times$  16.5  $\times$  4.5 cm, wt. = 1.6 kg),

<sup>□</sup> Supported in part by Oregon State University Graduate School, Oregon State University Research Council and National Marine Fisheries Service, Marine Mammal Division, Seattle, Washington (Contract #577). Technical paper no. 5204, Agriculture Experiment Station, Oregon State University.

<sup>□</sup> Present address: Department of Pathology, San Diego Zoo, P. O. Box 551, San Diego, California 92112, USA.

<sup>□</sup> Present address: Department of Pathology and Toxicology, The Upjohn Company, Kalamazoo, Michigan 49001, USA.

firmer than normal and had a mottled white appearance. The mesenteric, gastric and hepatic lymph nodes were enlarged, creamy white and semifirm. Two large mesenteric lymph nodes were  $7 \times 4 \times 2$  cm and  $11 \times 3 \times 3$  cm (Fig. 1). Peripheral lymph nodes were also enlarged, but to a lesser degree than the visceral lymph nodes.

The lungs were congested. A single large nematode identified as *Skjabinaria (Dipetalonema) spirocauda* was associated with a thrombus which occluded the lumen of a major pulmonary artery. The wall of the artery was thickened and the surface roughened.

Incidental findings included a small gastric ulcer (1.5 cm dia.) and parasitic infection of the stomach (*Terranova decipiens*), and small intestines (*Corynosoma strumosum*, *C. semerme* and *Pricetrema zalophi*). *Escherichia coli* was isolated from the liver and mesenteric lymph node and *Streptococcus* sp. from the peritoneal fluid.

The liver, spleen, and mesenteric lymph nodes were most severely infiltrated by neoplastic lymphoid cells. Dense aggregations of neoplastic cells occurred adjacent to portal triads and central veins. Individual neoplastic cells or small foci of cells were observed in the hepatic sinusoids.

Neoplastic cells infiltrated the trabeculae and were in foci adjacent to splenic arteries. The red pulp contained a diffuse scattering of neoplastic lymphoid cells. In the visceral lymph nodes, solid sheets of neoplastic lymphoid cells infiltrated the subcapsular sinus and extended into the cortex along the inter-nodular trabeculae. The germinal centers were reactive and contained infiltrating islands and cords of neoplastic cells.

Neoplastic lymphoid cells were also seen adjacent to the renal arcuate veins, throughout the bone marrow, in the pulmonary capillary bed, infiltrating the colonic submucosa, and the mesentery of

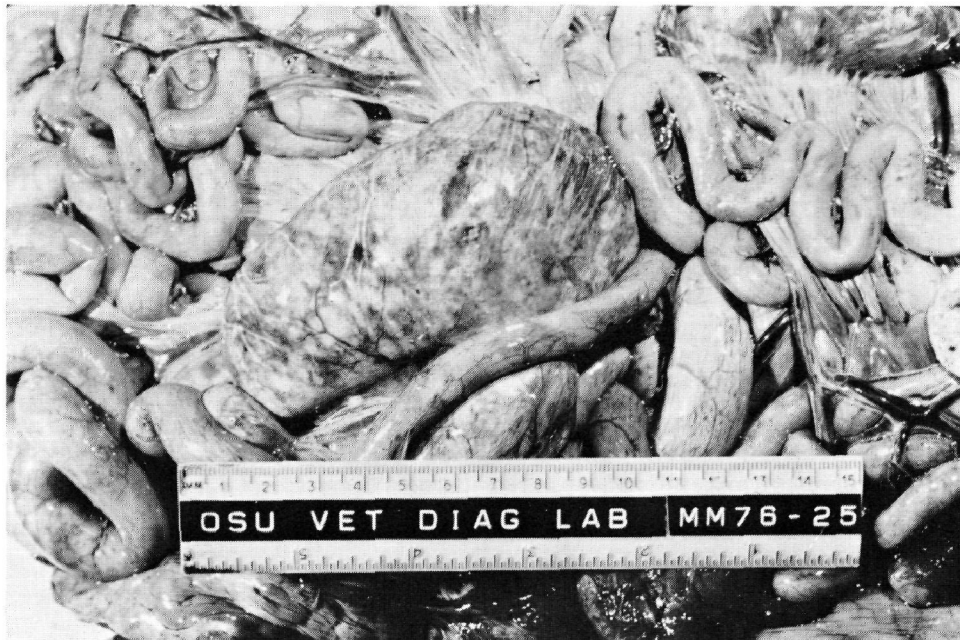

FIGURE 1. Enlarged mesenteric lymph node from subadult harbor seal (*Phoca vitulina richardii*) with lymphosarcoma.

the small intestine, in all layers of the stomach adjacent to the gastric ulcer and in the adrenal sinusoids. Small groups of neoplastic cells were apparent in the veins associated with the pancreas, lung and heart.

Nuclear size and shape, chromatin distribution, presence and number of nucleoli was variable in the neoplastic lymphocytes. Generally, individual cells observed in the mesenteric lymph node, spleen and liver had large oval-round nuclei containing 1-3 prominent nucleoli. Heterochromatin was clumped and frequently margined along the nuclear envelope. In the liver, 1 to 2 mitotic figures were observed per high power field. Mitotic figures were more numerous in the visceral lymph nodes. The cytoplasm was eosinophilic, granular and varied in amount. Cell borders were indistinct to sharply demar-

cated depending on the crowding of individual cells within the solid infiltrating sheets (Fig. 2).

Other histologic changes included chronic severe villous endarteritis and thrombi associated with the presence of the nematode in the pulmonary artery. Acute focal purulent lymphadenitis with necrosis was observed in several peripheral lymph nodes.

## DISCUSSION

Based on the criteria presented in the World Health Organization, International Histological Classification of Tumors of Domestic Animals, this case may be classified as a multicentric histiolympocytic form of lymphosarcoma.<sup>2</sup>

A C-type oncornavirus has been incriminated as the etiologic agent causing

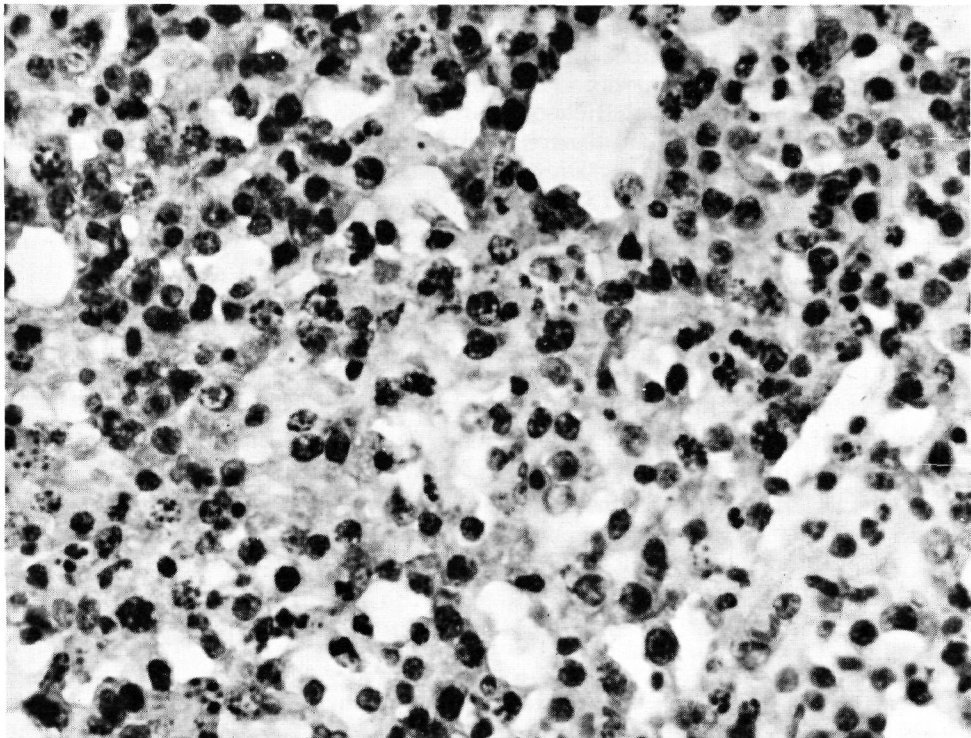


FIGURE 2. Pleomorphic lymphoid cell infiltrate in the mesenteric lymph node. H&E  $\times 400$ .

lymphosarcomas in several domestic species. The role of FELV virus in the pathogenesis of feline lymphosarcoma and related disorders has been extensively studied.<sup>4</sup> The histiolympocytic form of lymphosarcoma is more common in young domestic animals.<sup>2</sup> Based on the case reports available, lymphosarcoma in pinnipeds is also a disease of young animals.<sup>1,3,5</sup>

The almost simultaneous occurrence of leukemic lymphomas in two young harbor seals housed together at the San Diego Zoo suggested that the disease may have been of infectious origin.<sup>1</sup> The gross and microscopic findings in the case reported here are similar to the two harbor seals at the San Diego Zoo. Unfortunately, fresh blood was not available in this case to determine if the animal was leukemic. Leukemia was suggested by the presence of small groups of immature

lymphoid cells observed in the blood vessels of the lung, pancreas and myocardium. Both harbor seals at the San Diego Zoo were leukemic.

Assuming that a viral etiology is involved in pinniped lymphosarcoma, social habits such as congregation in a densely populated rookery or in hauling areas should promote the occurrence of the disease within specific populations. The recovery and recognition of future cases from wild populations may be possible because debilitated pinnipeds frequently beach themselves and may be recovered. These animals should be kept alive in appropriate facilities so that virus transmission studies and/or electron microscopy may be used to demonstrate viral involvement in the pathogenesis of lymphosarcoma in wild pinnipeds.

### Acknowledgements

Biologists from the Tillamook office, Oregon Department of Fisheries and Wildlife, Tillamook, Oregon, euthanized and recovered the seal from the beach for study. Dr. M.D. Dailey, Department of Biology, California State University, Long Beach, California, identified the parasites recovered from the lungs and gastro-intestinal tract. Dr. B. Coles, Veterinary Diagnostic Laboratory, Oregon State University, Corvallis, Oregon, isolated and identified the bacteria.

### LITERATURE CITED

1. GRINER, L.A. 1971. Malignant leukemic lymphoma in two harbor seals (*Phoca vitulina geronimensis*). Am. J. Vet. Res. 32: 827-830.
2. JARRETT, W.F. and L.J. MACKEY. 1974. Neoplastic diseases of the haematopoietic and lymphoid tissues. Bull. Wild. Hlth. Org. 50: 21-34.
3. LARSEN, S. 1962. A survey of the post mortem findings in Pinnipedia autopsied during a 10-year period 1952-1961. Nord. Vet. Med. 14 (Suppl. 1): 150-160.
4. MOULTON, J.E. and D.L. DUNGWORTH. 1978. Tumors of the lymphoid and hemopoietic tissues. Pages 150-196. In: *Tumors in Domestic Animals*. 2nd ed., J.E. Moulton ed. Univ. California Press, Berkeley, California.
5. STEDHAM, M.A., H.W. CASEY and M.C. KEYES. 1977. Lymphosarcoma in an infant northern fur seal. J. Wildl. Dis. 13: 176-179.

Received for publication 14 June 1979