



OCCURRENCE OF POX IN A NORTHERN FUR SEAL ON THE PRIBILOF ISLANDS IN 1951

Authors: HADLOW, W. J., CHEVILLE, N. F., and JELLISON, W. I..

Source: Journal of Wildlife Diseases, 16(2) : 305-312

Published By: Wildlife Disease Association

URL: <https://doi.org/10.7589/0090-3558-16.2.305>

BioOne Complete (complete.BioOne.org) is a full-text database of 200 subscribed and open-access titles in the biological, ecological, and environmental sciences published by nonprofit societies, associations, museums, institutions, and presses.

Your use of this PDF, the BioOne Complete website, and all posted and associated content indicates your acceptance of BioOne's Terms of Use, available at www.bioone.org/terms-of-use.

Usage of BioOne Complete content is strictly limited to personal, educational, and non - commercial use. Commercial inquiries or rights and permissions requests should be directed to the individual publisher as copyright holder.

BioOne sees sustainable scholarly publishing as an inherently collaborative enterprise connecting authors, nonprofit publishers, academic institutions, research libraries, and research funders in the common goal of maximizing access to critical research.

OCCURRENCE OF POX IN A NORTHERN FUR SEAL ON THE PRIBILOF ISLANDS IN 1951

W. J. HADLOW¹, N. F. CHEVILLE² and W. L. JELLISON³

Abstract: The presence of pox in a northern fur seal pup, *Callorhinus ursinus*, examined at necropsy on the Pribilof Islands, Alaska, 13 September 1951 was confirmed by re-examination of formalin-fixed tissues collected at that time. The disease was characterized by multiple 3 to 8 mm nodules in the skin of the nose and flippers. Unlike pox lesions in other pinnipeds studied so far, the nodules were discrete dermal epitheliomas free of any direct connections with the overlying atrophic epidermis. They most likely arose from outer sheath cells of hair follicles. The tightly packed epithelial cells forming the nodules contained large, round, eosinophilic, intracytoplasmic inclusion bodies. As demonstrated by electron microscopy nearly 27 years after the tissues were fixed in formalin, poxvirus virions also were present in these cells. These findings indicate pox was present in a northern fur seal, hitherto undescribed in that species, 18 years before the disease was first reported in pinnipeds.

INTRODUCTION

Sealpox, characterized by nodular proliferative lesions in the skin, was first reported in 1969 in a captive California sea lion, *Zalophus californianus*.¹ Soon thereafter, it was recognized also in free-living members of that species,² in seven captive harbor seals, *Phoca vitulina*,³ and in two captive South American sea lions, *Otaria byronia*.⁴ Other pinnipeds may be affected as well.⁷ But as far as we know, the disease has not been reported in the northern fur seal, *Callorhinus ursinus*. As a result of the re-examining specimens stored at Rocky Mountain Laboratories, we herewith offer evidence of its occurrence in a fur seal pup collected on the Pribilof Islands, Alaska, in September, 1951.

CASE HISTORY

While studying parasites of fur seals on the Pribilof Islands during the late

summer of 1951, one of us (W.L.J.) found a thin female pup floating alone in the surf off St. Paul Island. It was taken to a field laboratory, where it died during the night. At necropsy the next day, 13 September 1951, besides the poor state of nourishment, the only notable findings were an enlarged cervical lymph node, tiny white foci of uncertain significance on the lungs, and multiple small nodules in the skin of the nose and flippers. Some nodules on the nose were excoriated and covered with blood; those on the flippers, mainly the left foreflipper, were generally smooth. None of the other seals examined that summer had similar lesions.

A year later, one of us (W.J.H.) examined the nodules on the nose and left foreflipper that had been stored in 10% formalin since the necropsy. Well circumscribed in the dermis, the nodules had the histologic appearance of solid benign epitheliomas probably derived from epidermal appendages. Their most

¹ National Institutes of Health, National Institute of Allergy and Infectious Diseases, Epidemiology Branch, Rocky Mountain Laboratories, Hamilton, Montana 59840, USA.

² National Animal Disease Center, Ames, Iowa 50010, USA.

³ 504 South Third Street, Hamilton, Montana 59840, USA.

striking feature was the presence of large eosinophilic inclusion bodies in the cytoplasm of the proliferating epithelial cells; they prompted thoughts about the possible role of a viral infection in the genesis of the nodules. That the nodules might represent pox lesions, however, was never considered. Because specimens from other affected seals could not be obtained and because material suitable for animal inoculation was not available, interest in the lesion waned, and it was soon forgotten. Firm conclusions about its cause and true nature were never reached.

After histologic descriptions of sealpox appeared, interest in the cutaneous nodules was revived. Microscopic sections of them, prepared in 1952, were re-examined; their general histologic resemblance to the lesion of sealpox was recognized. So on the off-chance that poxvirus virions might still be demonstrable in the nodules, small pieces were taken from several of those on the flipper for examination by one of us (N.F.C.) with the electron microscope. This was done in June, 1978, nearly 27 years after the specimen had been put in formalin.

MATERIALS AND METHODS

Tissues for light microscopic examination were prepared by standard methods in 1952 and then again in 1979. For electron microscopy, 1 mm cubes of the formalin-fixed nodules were rinsed in sodium cacodylate buffer, post-fixed in glutaraldehyde overnight, and processed by routine methods through osmium tetroxide, ethanols, propylene oxide, and epoxy resin. Ultrathin sections were stained with uranyl acetate and examined in a transmission electron microscope at 60 Kv.

RESULTS

Macroscopic Features

The cutaneous nodules were firm, round, discrete, nonpigmented 3 to 8 mm

masses that protruded from the dermis. They occurred singly and in clusters of up to eight. Those on the left foreflipper were smooth and hairless, though a few were somewhat flattened and faintly umbilicated (Fig. 1). All were either on the dorsal surface of the flipper or along the cranial and caudal edges. Of the 20 or so present, many were near the tip. Nodules on the nose were mainly along the lateral margins of the nostrils. Unlike those on the flipper, they were mostly roughened or partly broken. Three nodules, 5 to 7 mm in diameter, were along the right nostril. A $12 \times 7 \times 7$ mm nodule nearly occluded the left nostril. On the dorsal surface of the nose near the planum nasale was a single 5 mm nodule, smooth and hairless like those on the flipper.

Histologic Features

Composed of compact lobules of polygonal epithelial cells, the nodules occupied the dermis as well circumscribed, but nonencapsulated, symmetrical tumors compressing the subcutis (Fig. 2). Usually a narrow band of dermal collagenous fibers separated the dome of each epithelial mass from the overlying atrophic epidermis. Only occasionally in the smaller nodules was a remnant of a hair follicle seen in this intervening space (Fig. 3). The rind of epidermis, thin and without rete ridges, was otherwise intact except where it sometimes merged with the underlying epithelial tumor at sites of necrosis — the umbilicated surfaces seen macroscopically. Adjacent skin was normal. Regardless of their size, all nodules had this general histologic appearance.

A delicate connective tissue stroma containing a few blood vessels separated the lobules of tightly packed epithelial cells (Fig. 4). Generally large, these cells had abundant finely granular eosinophilic cytoplasm and a round vesicular nucleus containing a prominent nucleolus. Some cells at the periphery of the lobules, which rested on

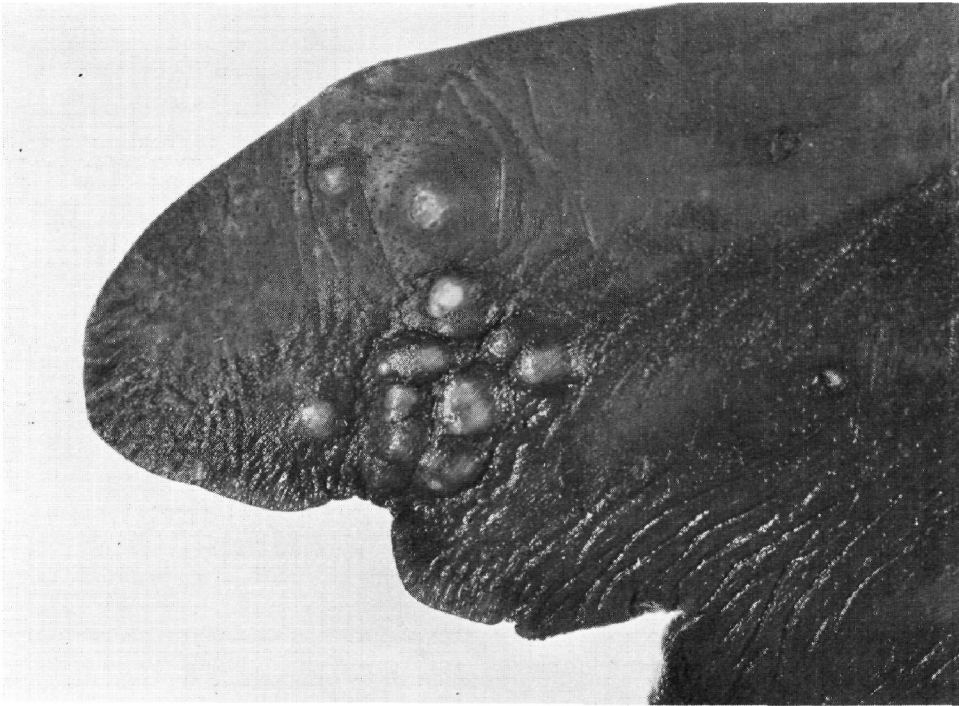


FIGURE 1. Cluster of smooth nodules in the skin of the left foreflipper. Several are faintly umbilicated.

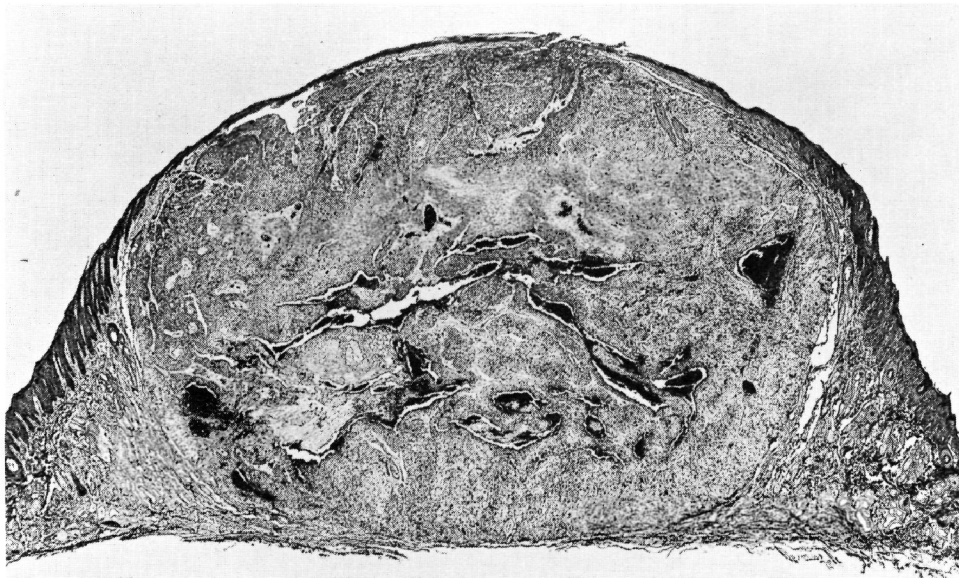


FIGURE 2. Typical appearance of a discrete epithelial nodule in dermis of flipper. It is distinct from the overlying atrophic epidermis. H&E $\times 10$.

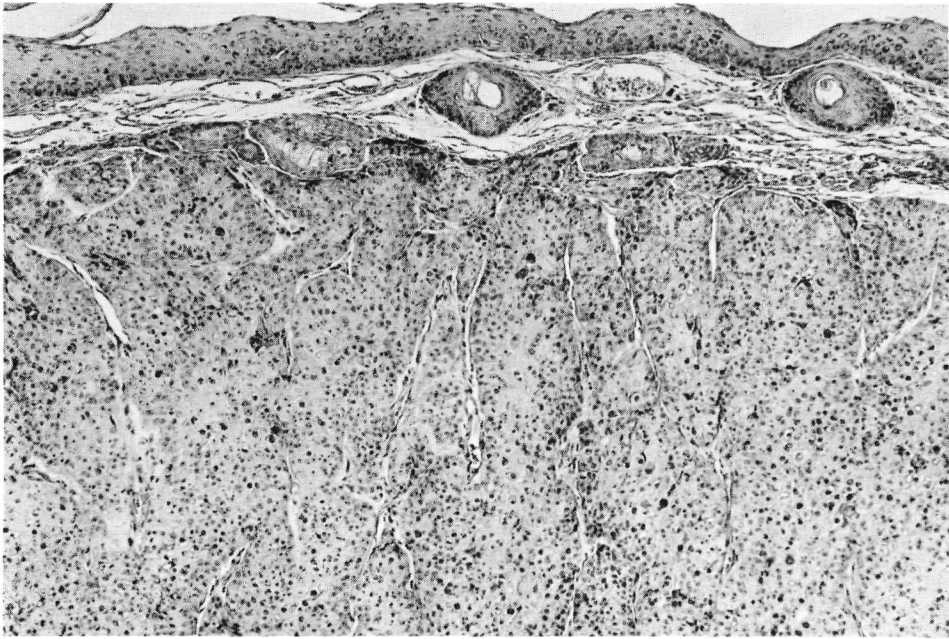


FIGURE 3. Small nodule separated from epidermis by intervening space containing two residual hair follicles. H&E $\times 85$.

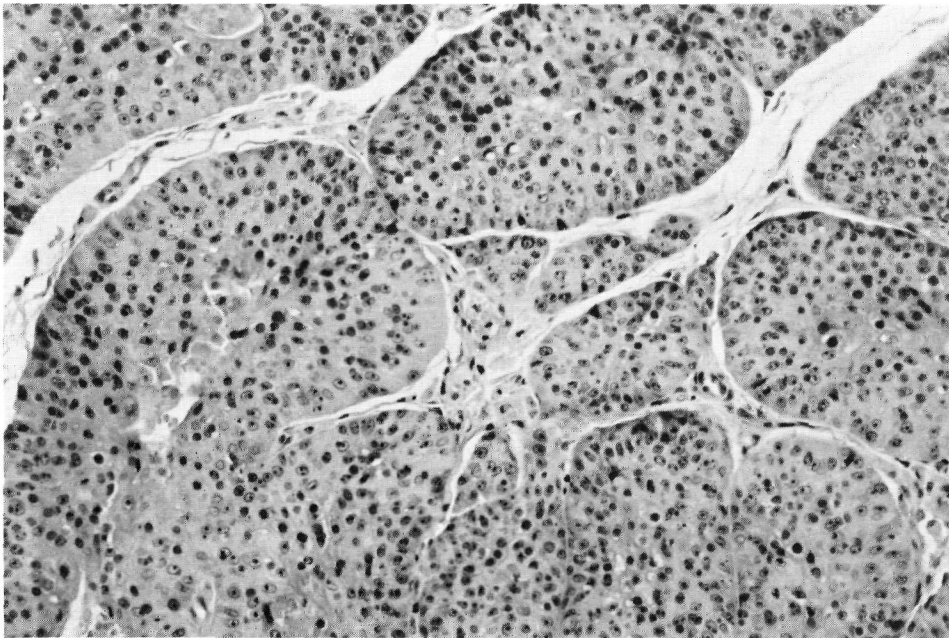


FIGURE 4. Compact lobular arrangement of epithelial cells in a small dermal nodule. The many dark staining bodies are intracytoplasmic inclusion bodies. H&E $\times 180$.

a thin basal lamina, had mostly clear cytoplasm and unusually distinct cell membranes. In none of the cells did the cytoplasm contain fat or material stainable by periodic acid-Schiff reagent. Mitotic figures were rare. Outlines of the epithelial cells became less distinct toward the centers of the lobules, which were often composed of necrotic debris and free inclusion bodies. Where the necrotic debris was retracted from adjacent cells, a pseudolumen was formed. None of the cells was keratinized. Unlike those on the flipper, some nodules on the nose were disrupted by inflammatory changes most likely resulting from trauma and secondary bacterial infection.

Large, round, eosinophilic intracytoplasmic inclusion bodies were a striking component of the nodules (Fig. 5). One to a cell, they tended to reach their maximum size of about $8\ \mu\text{m}$ toward the centers of the lobules. They were colored

deep red by acid fuchsin-orange G and bright pink by phloxine, but were not stained by neutral red or by periodic acid-Schiff reagent. Although abundant in epithelial cells forming the dermal nodules, they were not seen in cells of the epidermis, either that overlying the nodules or that adjacent to them. Nor were they present in cells of neighboring hair follicles, sebaceous glands, or apocrine sweat glands.

That the dermal nodules were distinct from the epidermis was evident in all sections examined. Likewise, they did not have direct connections with epidermal appendages except at the periphery of two small nodules on the flipper. In one, several apocrine sweat glands were replaced by inclusion-bearing cells like those of the nodule. In the other, remnants of several hair follicles were in continuity with cells of the nodule. Whether these adnexal structures were merely being engulfed by the expanding

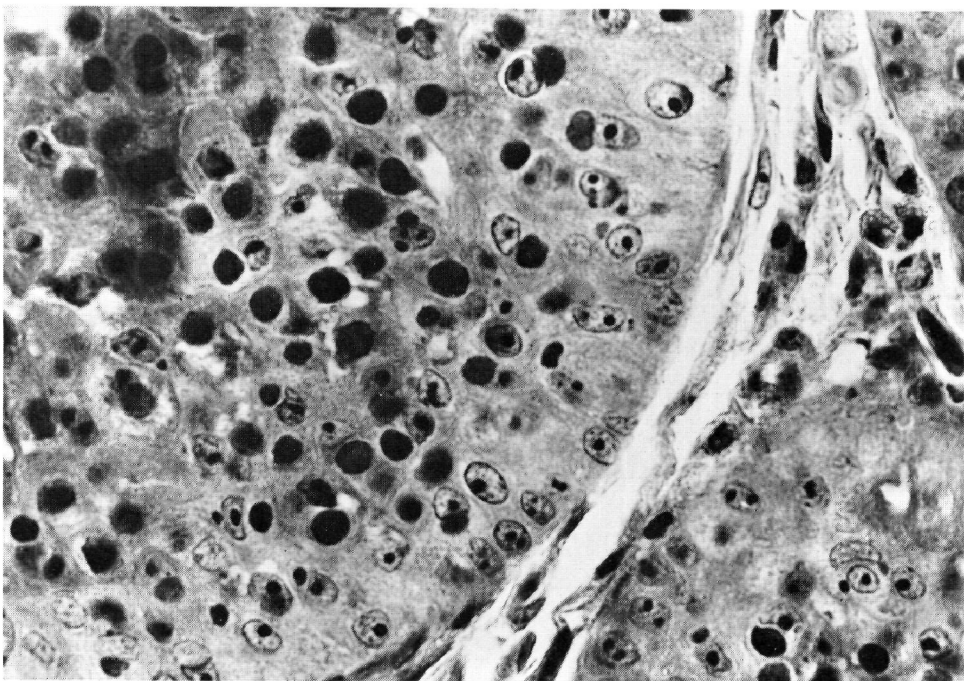


FIGURE 5. Higher power view of deeply acidophilic inclusion bodies near periphery of a lobule. Crossman's triple stain $\times 600$.

nodules or were playing an active role in forming them was uncertain.

Ultrastructural Features

The inclusion-bearing epithelial cells were greatly enlarged, pale keratinocytes

containing large cytoplasmic granular foci composed of immature virus particles and viroplasm (Fig. 6). The granular inclusions were adjacent to nuclei, that is, located centrally. Mature virions occurred throughout the remain-

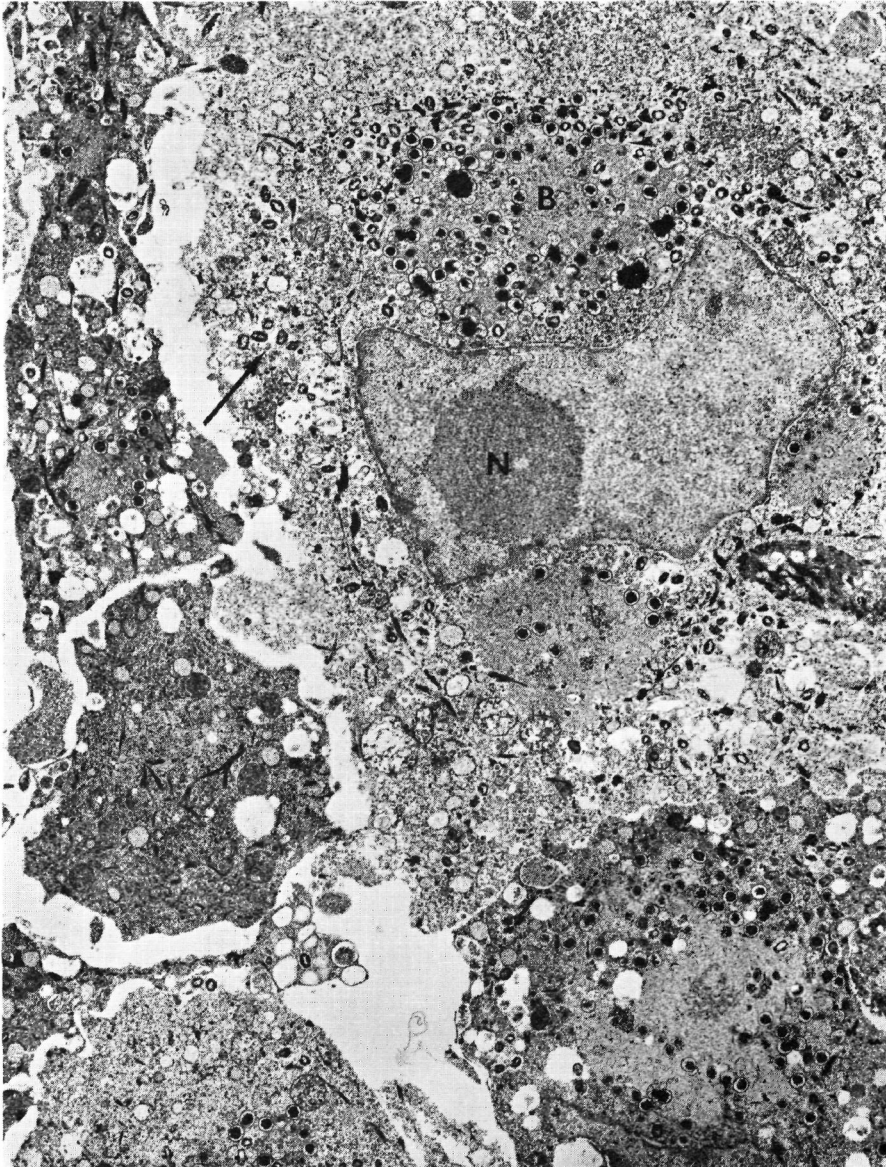


FIGURE 6. Keratinocytes containing perinuclear granular viroplasmic inclusions (B) and mature virions (arrow) in peripheral cytoplasm. Dark cell at left is a necrotic keratinocyte. Nucleolus (N).

ing cytoplasm (Fig. 7). Cytopathic changes in infected keratinocytes included reduced numbers of keratin fibrils, irregular nuclear envelopes, large granular nucleoli, and reduced amounts of chromatin. Necrotic keratinocytes located centrally in groups of infected ones were shrunken, electron dense, vacuolated, and filled with virions.

DISCUSSION

Histologically, these cutaneous nodules in the fur seal differed from the pox lesions found in California sea lions⁴ and harbor seals.⁹ They were more like the dermal nodules described in South American sea lions.⁵ But unlike the pox lesion in any of these three species, the dermal nodules in the fur seal pup were not connected with the epidermis. Nor were intracytoplasmic inclusion bodies found there. In resembling benign dermal epitheliomas, the nodules were altogether different from the epidermal hyperplasia characterizing the pox

lesions in the other pinnipeds. Although we did not reach a firm conclusion about their cellular origin, we have the impression they most likely arose from cells of the outer sheath of hair follicles rather than from the epidermis proper. The electron microscopic findings are consistent with such an origin. If this is so, then the histogenesis of the dermal nodules in the fur seal is different from that of the pox lesion occurring in other pinnipeds studied thus far. As a distinctive proliferative lesion in the skin, these poxvirus-induced nodules in the fur seal warrant more study whenever better preserved specimens become available.

Cytopathic changes and various types of virus particles seen in infected cells of the nodules could not be distinguished from those in lesions of sealpox.^{4,6} Pronounced hyperplasia of keratinocytes without the formation of vesicles or pustules, large irregular cytoplasmic inclusions, and cytomegaly without evidence of water-loading are all characteristic of infections with other un-

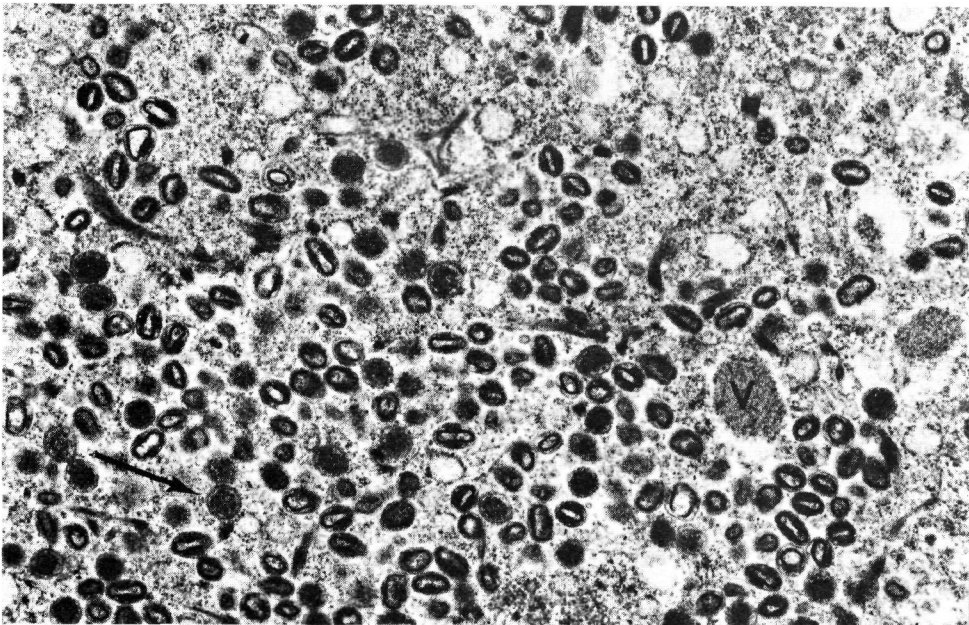


FIGURE 7. Enlarged view of cytoplasm containing virions, intermediate virus particles (arrow), and viroplasm (V).

grouped poxviruses, namely, those of swinepox, molluscum contagiosum, and benign epidermal monkeypox. None of these viruses has been shown to be antigenically related, but in size and structure their virions are similar to those of sealpox virus and to the virions seen in the dermal nodules of the fur seal pup.

Nothing is known about the natural history of poxvirus infection in the fur seal. In other pinnipeds, clinical disease occurs mainly in young animals, usually within several weeks or months after they are taken into captivity.^{2,3} The striking cutaneous lesions, which seem to have little adverse effect on the health of the animal, are self-limiting. Whether the tumor-like lesion in the skin of the fur seal has the same fate is unknown.

No published account of this lesion in the northern fur seal was found. Nevertheless, Scheffer (pers. comm., Dr. Victor

B. Scheffer, Seattle, Wash., 1953) saw and photographed what no doubt was the same nodular lesion on the flippers of two males (a 2- or 3-year-old and an adult) collected on St. Paul Island in 1949 and 1950. Apparently the disease was rare at that time, for apart from these males and the pup collected in 1951, no other affected seals were recorded during those years. Since then, reports from other persons studying the fur seal on the Pribilof Islands have not mentioned pox or any cutaneous lesion suggestive of it.¹ Keyes (pers. comm., Dr. Mark C. Keyes, Seattle, Wash., 1979) did necropsies on about 3000 fur seal pups during 17 summer seasons and did not find pox lesions in any of them. Regardless of its apparent rarity on the Pribilof Islands during the past 28 years, our retrospective study confirmed its presence there, in at least one pup, in 1951 — 18 years before pox was first reported in pinnipeds.

LITERATURE CITED

1. KEYES, M.C. 1965. Pathology of the northern fur seal. *J. Am. vet. med. Ass.* 147: 1090-1095.
2. RIDGWAY, S.H., J.R. GERACI and W. MEDWAY. 1975. Diseases of pinnipeds. *Rapp. P.-V. Réun. Cons. Int. Explor. Mer.*, 169: 327-337. (Proceedings of a symposium, "Biology of the Seal", held in Guelph, Ontario, August 14-17, 1972. K. Ronald and A.W. Mansfield, eds.)
3. SWEENEY, J.C. 1974. Common diseases of pinnipeds. *J. Am. vet. med. Ass.* 165: 805-810.
4. WILSON, T.M., N.F. CHEVILLE and L. KARSTAD. 1969. Seal pox. *Bull. Wildl. Dis. Ass.* 5: 412-418.
5. — and I. POGLAVEN-NEUWALL. 1971. Pox in South American sea lions (*Otaria byronia*). 1971. *Can. J. Comp. Med.* 35: 174-177.
6. — and P.R. SWEENEY. 1970. Morphological studies of seal poxvirus. *J. Wildl. Dis.* 6: 94-97.
7. —, N.F. CHEVILLE and A.D. BOOTHE. 1972. Sealpox questionnaire survey. *J. Wildl. Dis.* 8: 155-157.
8. —, A.D. BOOTHE and N.F. CHEVILLE. 1972. Sealpox field survey. *J. Wildl. Dis.* 8: 158-160.
9. —, R.W. DYKES and K.S. TSAI. 1972. Pox in young, captive harbor seals. *J. Am. vet. med. Ass.* 161: 611-617.

Received for publication 26 June 1979