

DISSEMINATED STAPHYLOCOCCAL INFECTION IN A COLONY OF CAPTIVE GROUND SQUIRRELS (*Citellus lateralis*) 1 4

Authors: CAMPBELL, G.A., KOSANKE, S.D., TOTH, D.M., and WHITE, G.L.

Source: Journal of Wildlife Diseases, 17(2) : 177-181

Published By: Wildlife Disease Association

URL: <https://doi.org/10.7589/0090-3558-17.2.177>

BioOne Complete (complete.BioOne.org) is a full-text database of 200 subscribed and open-access titles in the biological, ecological, and environmental sciences published by nonprofit societies, associations, museums, institutions, and presses.

Your use of this PDF, the BioOne Complete website, and all posted and associated content indicates your acceptance of BioOne's Terms of Use, available at www.bioone.org/terms-of-use.

Usage of BioOne Complete content is strictly limited to personal, educational, and non - commercial use. Commercial inquiries or rights and permissions requests should be directed to the individual publisher as copyright holder.

BioOne sees sustainable scholarly publishing as an inherently collaborative enterprise connecting authors, nonprofit publishers, academic institutions, research libraries, and research funders in the common goal of maximizing access to critical research.

DISSEMINATED STAPHYLOCOCCAL INFECTION IN A COLONY OF CAPTIVE GROUND SQUIRRELS (*Citellus lateralis*)^{□ □}

G.A. CAMPBELL,[□] S.D. KOSANKE,[□] D.M. TOTH[□] and G.L. WHITE[□]

Abstract: Purulent cutaneous and visceral lesions were observed in a colony of 68 golden-mantled ground squirrels, *Citellus (Spermophilus) lateralis*, used in a hibernation study. The squirrels had been purchased from a commercial supplier. Beginning approximately three weeks after their purchase and during the following five weeks, 21 squirrels died. The predominate gross and histologic findings consisted of multifocal suppurative lesions involving the skin, brain and numerous visceral organs. *Staphylococcus aureus* was consistently found to be associated with the disease.

INTRODUCTION

Staphylococcus aureus is cosmopolitan in distribution and is a common component of the normal bacterial flora of the skin and mucus membranes of animals and man. It is considered an "opportunistic" pathogen, waiting for proper conditions before causing significant disease. The majority of reported cases of staphylococcal infection in laboratory and exotic rodents and rabbits are associated with skin lesions due to minor trauma without systemic disease being observed. Suppurative staphylococcal lesions involving the skin and subcutaneous tissue have been described in laboratory rats,^{1,7} guinea pigs,¹² mice,^{2,11} gerbils,⁹ mink and domestic rabbits.⁶ In guinea pigs, *S. aureus* also has been isolated from cases of osteoarthritis.⁵ Disseminated staphylococcal infections, with forma-

tion of visceral abscesses, have been reported in domestic rabbits¹⁰ and in wild rabbits and hares.^{1,8}

The following is a report of disseminated *S. aureus* infection in a small colony of captive ground squirrels.

CASE HISTORY

Sixty-eight ground squirrels (*Citellus lateralis*) were purchased in early August, 1979 from a commercial supplier in Northern California. The animals were captured locally and were quarantined for approximately four weeks in individual cages prior to shipment. The group included 12 adult males, 20 adult females and a total of 36 male and female juveniles. The shipment consisted of three cages: one contained 12 adult males, another contained 13 adult females and the third contained 7 adult

[□] Reprint requests should be sent to Dr. S.D. Kosanke, Animal Resources and Facilities, the University of Oklahoma Health Sciences Center, P.O. Box 26901, Oklahoma City, Oklahoma 73190, USA.

[□] Department of Pathology, the University of Oklahoma Health Sciences Center, P.O. Box 26901, Oklahoma City, Oklahoma 73190, USA.

[□] Department of Anatomical Sciences, the University of Oklahoma Health Sciences Center, P.O. Box 26901, Oklahoma City, Oklahoma 73190, USA.

[□] This study was supported in part by Grant P40-RR01098-03AR from the Division of Research Resources, National Institutes of Health.

females and 36 male and female juveniles. These animals are usually received from the supplier within one day. In this case, however, the animals were delayed overnight, thereby remaining in the group cages at least 12 to 18 h longer than normal. The animals were apparently in good health upon arrival. All were placed in individual cages, except for the juveniles which were housed two to a cage until maturity.

Approximately three weeks after their arrival, 7 of the animals in the colony showed sudden weight loss, emaciation, lethargy and evidence of upper respiratory disease characterized by a dry crusty exudate around the external nares. Death usually followed within two days of onset of clinical signs. Over the next five weeks, 10 adult males, 3 adult females, 4 juvenile males and 3 juvenile females died. An additional adult male died several months later. When the disease outbreak terminated only one of

the 12 adult males while 17 of the 20 adult females had survived.

Postmortem examinations were performed on nine squirrels. At necropsy, representative samples of gross lesions, as well as normal tissue, were fixed in 10% neutral buffered formalin, processed routinely, sectioned at 6 μ m, stained with Harris' hematoxylin and eosin (H&E) and Brown and Hopps (B&H) and examined microscopically. Specimens of the head and nasopharyngeal area of representative animals were decalcified and then processed as indicated above.

In 3 of the 9 cases examined, blood was aseptically withdrawn from the left ventricle and cultured for bacteria. The purulent cutaneous and visceral lesions also were cultured. Coagulase positive *S. aureus* was identified consistently from the blood and tissues sampled. In one instance, *Escherichia coli* also was cultured from heart blood.

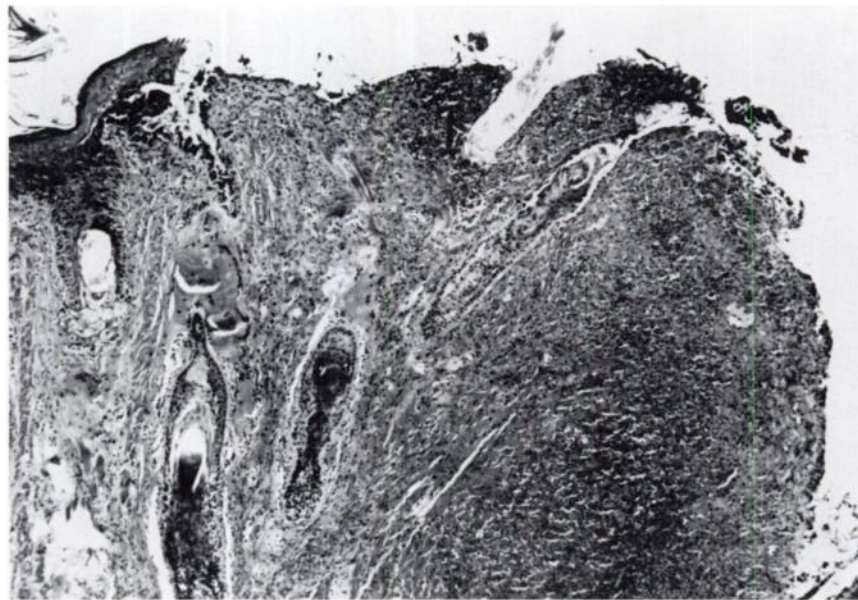


FIGURE 1. A necrotizing purulent reaction involving the skin of the face. The lesion extended deep into the underlying skeletal muscles. H&E \times 50.

NECROPSY FINDINGS

The most consistent gross findings were marked emaciation and dry crusty exudate around the external nares. Almost all of the squirrels examined at necropsy weighed as little as one-half their normal weight at the time of death. Many of the animals showed widespread formation of cutaneous and visceral abscesses. In two of the adult males, cutaneous abscesses were present in the region of the head and neck and were deep-seated, with inflammatory tracts extending deep into the subcutaneous tissue and skeletal muscle of the face and cheeks (Fig. 1). In one case the inflammatory tracts extended from the exterior surface of the face into one of the facial sinuses.

The upper respiratory lesions consisted of a purulent rhinitis and sinusitis with abscess formation. Lung lesions ranged from a pneumonitis to abscess formation. The necrotic tissue was heavily infiltrated with gram-positive cocci

tentatively identified as *S. aureus* by B&H stain and confirmed by culture. Pulmonary abscesses were extensive, nearly eroding through the pleural capsule.

There were two cases of a vegetative valvular endocarditis (Fig. 2). The lesions involving the mitral valve were composed of necrotic cellular debris, polymorphonuclear leucocytes, and large colonies of gram-positive cocci identified by culture as *S. aureus*.

The remaining visceral lesions observed were embolic in nature, involving primarily the brain, myocardium, liver, pancreas and kidneys (Fig. 3). These organs showed bacterial embolization and abscess formation, with bacterial colony growth.

DISCUSSION

Staphylococcal infection may be initiated in several ways. In newborn domestic rabbits,⁶ it has been described

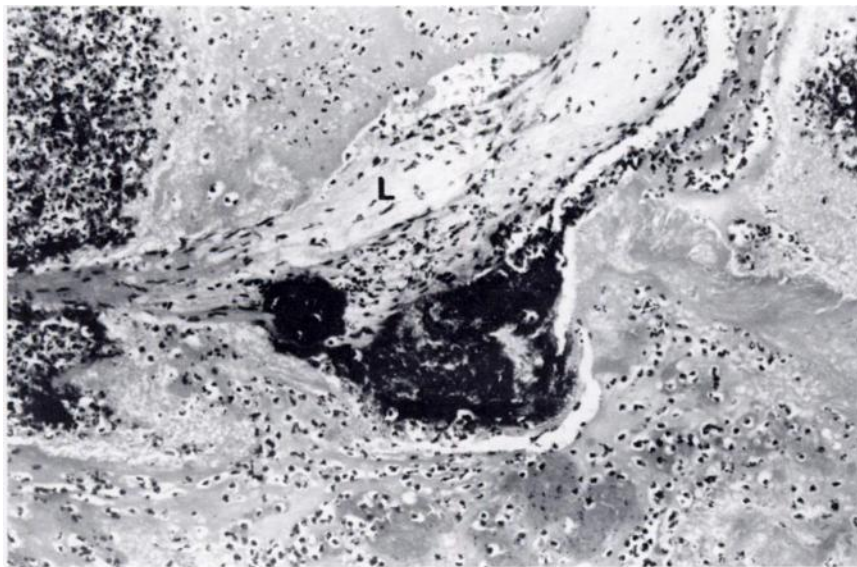


FIGURE 2. Vegetative mass, containing numerous gram-positive cocci, involves one of the leaflets (L) of the mitral valve. H&E $\times 125$.

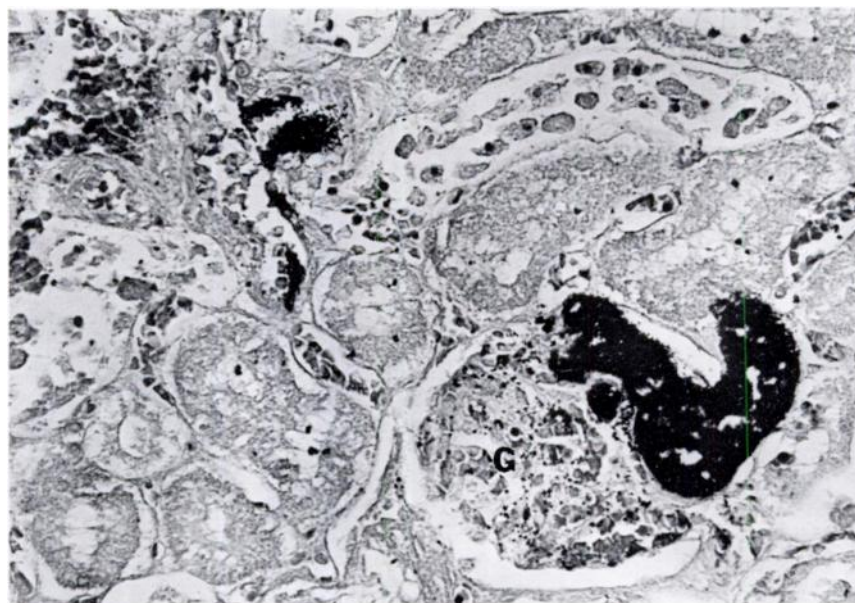


FIGURE 3. Bacterial embolization within a kidney glomerulus (G). B&H \times 313.

as beginning in the umbilical stump or from skin abrasions. Tail rot in laboratory rats,⁷ and osteoarthritis in guinea pigs,⁸ both caused by *S. aureus*, are initiated by mechanical trauma from the caging material. In moist dermatitis of staphylococcal origin described in Mongolian gerbils, trauma from blood sampling and fighting appeared to increase the severity of the disease."

We believe this disease was initiated by fighting among the caged squirrels during the prolonged transit. This belief is supported by the higher mortality among adult males who would be far more likely to fight and thereby sustain injuries. Traumatic skin injuries, inapparent upon receipt, went unnoticed due to the thick fur of the ground squirrels. Even at

necropsy some of these traumatic lesions would have escaped detection, especially in the region of the head, if the heads had not been sectioned and examined microscopically. The cutaneous, often deep-seated, staphylococcal-infected bite wounds observed would provide an excellent location for an ensuing systemic infection.

This problem has not been described previously in any ground squirrel species, including *C. lateralis*. The supplier of this group of animals reported no similar infections or injuries occurring in other animals trapped in the same region at the same time. Thus, the infection was not endemic to the entire population from which this group of animals was selected.

Acknowledgements

The authors wish to thank Ms. Molly Reid and Ms. Gloria Koehn for technical assistance.

LITERATURE CITED

1. ASH, G.W. 1971. An epidemic of chronic skin ulceration in rats. *Lab. Animals* 5: 115-122.
2. CLARKE, M.C., R.J. TAYLOR, G.A. HALL and P.W. JONES. 1978. The occurrence in mice of facial and mandibular abscesses associated with *Staphylococcus aureus*. *Lab. Animals* 12: 121-123.
3. CRANDELL, R.A., G.A. HUTTENHAUER and H.W. CASEY. 1971. Staphylococcal dermatitis in mink. *J. Am. vet. med. Ass.* 159: 638-639.
4. DAVIS, J.W. 1970. Staphylococcosis in rabbits and hares. pp. 283-285. In: *Infectious Diseases of Wild Mammals*. J.W. Davis, L.H. Karstad and D.O. Trainer (eds.). Iowa State University Press, Ames, Iowa.
5. GUPTA, B.N., G.H. CONNER and D.B. MEYER. 1972. Osteoarthritis in guinea pigs. *Lab. Animal Sci.* 22: 362-368.
6. HAGEN, K.B. 1963. Disseminated staphylococcal infection in young domestic rabbits. *J. Am. vet. med. Ass.* 142: 1421-1422.
7. HARD, G.C. 1966. Staphylococcal infection of the tail of the laboratory rat. *Lab. Animal Care* 16: 421-429.
8. OSEBOLD, J.W. and D.M. GRAY. 1960. Disseminated staphylococcal infections in wild jack rabbits (*Lepus californicus*). *J. Infect. Dis.* 106: 91-94.
9. PECKHAM, J.C., J.R. COLE, W.L. CHAPMAN, Jr., J.B. MALONE, Jr., J.W. McCALL and P.E. THOMPSON. 1974. Staphylococcal dermatitis in mongolian gerbils (*Meriones unguiculatus*). *Lab. Animal Sci.* 24: 43-47.
10. REINQUIST, D. and O. SOAVE. 1967. Staphylococcal pneumonia in laboratory rabbits: An epidemiologic follow-up study. *J. Am. vet. med. Ass.* 155: 1221-1223.
11. SHULTS, F.S., P.C. ESTES, J.A. FRANKLIN and C.B. RICKTER. 1973. Staphylococcal botryomycosis in a specific-pathogen-free mouse colony. *Lab. Animal Sci.* 23: 36-42.
12. TAYLOR, J.L., J.E. WAGNER, D.R. OWENS and R.A. STUHLMAN. 1971. Chronic pododermatitis in guinea pigs, a case report. *Lab. Animal Sci.* 21: 944-945.

Received for publication 21 October 1980