

Sarcocystis SPP. IN WHITE-TAILED DEER I. DEFINITIVE AND INTERMEDIATE HOST SPECTRUM WITH A DESCRIPTION OF *Sarcocystis odocoileocanis* N. SP. 1

Authors: CRUM, JAMES M., FAYER, RONALD, and PRESTWOOD, ANNIE K.

Source: Journal of Wildlife Diseases, 17(4) : 567-579

Published By: Wildlife Disease Association

URL: <https://doi.org/10.7589/0090-3558-17.4.567>

BioOne Complete (complete.BioOne.org) is a full-text database of 200 subscribed and open-access titles in the biological, ecological, and environmental sciences published by nonprofit societies, associations, museums, institutions, and presses.

Your use of this PDF, the BioOne Complete website, and all posted and associated content indicates your acceptance of BioOne's Terms of Use, available at www.bioone.org/terms-of-use.

Usage of BioOne Complete content is strictly limited to personal, educational, and non - commercial use. Commercial inquiries or rights and permissions requests should be directed to the individual publisher as copyright holder.

BioOne sees sustainable scholarly publishing as an inherently collaborative enterprise connecting authors, nonprofit publishers, academic institutions, research libraries, and research funders in the common goal of maximizing access to critical research.

***Sarcocystis* SPP. IN WHITE-TAILED DEER I. DEFINITIVE AND INTERMEDIATE HOST SPECTRUM WITH A DESCRIPTION OF *Sarcocystis odocoileocanis* N. SP.[□]**

JAMES M. CRUM,[□] RONALD FAYER[□] and ANNIE K. PRESTWOOD[□]

Abstract: Sporocysts containing four sporozoites and measuring (avg.) $15.2 \mu\text{m} \times 10.7 \mu\text{m}$ (N=195) were shed in the feces of dogs (*Canis familiaris*) 8 to 16 days (avg. 11.6 days) after the first feeding of venison infected with *Sarcocystis* sp. Sporocysts containing four sporozoites and measuring (avg.) $11.5 \mu\text{m} \times 8.1 \mu\text{m}$ (N=35) were shed by a cat (*Felis catus*) 14 days after ingesting *Sarcocystis*-infected venison. Statistical (pooled t-test) comparison of the mean measurements of the sporocysts passed by the dog and cat demonstrated a significant difference ($P < .01$). The raccoon (*Procyon lotor*) and opossum (*Didelphis virginiana*) could not be infected with *Sarcocystis* from white-tailed deer (*Odocoileus virginianus*).

The name, *Sarcocystis odocoileocanis*, is proposed for the species transmitted from white-tailed deer to dogs. *Sarcocystis odocoileocanis* is differentiated from *S. hemionilatrantis* Hudkins and Kistner, 1977 of mule deer (*Odocoileus hemionus*), *S. ovicanis* Heydorn, Gestrich, Mehlhorn and Rommel, 1975 of sheep (*Ovis aries*) and *S. cruzi* Hasselmann, 1926 (= *S. bovicanis* Heydorn, Gestrich, Mehlhorn and Rommel, 1975) of cattle (*Bos taurus*) because *S. odocoileocanis* has (1) low infectivity for calves and sheep and (2) apparent insignificant pathogenicity for its intermediate host.

INTRODUCTION

Sarcosporidian cysts have been reported in all nine genera of North American wild ruminants; however, the life cycle of *Sarcocystis* has been elucidated in only four species, i.e., bison (*Bison bison*),² moose (*Alces alces*),² mule deer (*Odocoileus hemionus*)^{10,11,14,23} and wapiti (*Cervus canadensis*).¹⁸ There are four accounts of *Sarcocystis* in white-tailed deer, *Odocoileus virginianus*,^{13,17,21,22} and each reports a high prevalence of cysts in skeletal muscle. Collectively these reports suggest a wide geographic range for the organism, viz., Alberta, Montana, Ontario, Texas, West Virginia and Wisconsin.

The present study was undertaken to reveal the epizootiology of *Sarcocystis* sp. of white-tailed deer.

MATERIALS AND METHODS

Definitive host studies (Experiments 1-6). Animals fed *Sarcocystis*-infected venison included dogs (*Canis familiaris*), cats (*Felis catus*), raccoons (*Procyon lotor*) and an opossum (*Didelphis virginiana*) (Table 1).

Dogs used in this study included Beagle, Doberman x Labrador and Beagle x Airedale pups which were housed individually. Beagle pups were

[□] This study was supported by the Federal Aid in Wildlife Restoration Act (50 Stat. 917) and Contract No. 14-16-0009-78-025, Fish and Wildlife Service, U.S. Department of the Interior, and by the Animal Parasitology Institute, Science and Education Administration, U.S. Department of Agriculture.

[□] Southeastern Cooperative Wildlife Disease Study, Department of Parasitology, College of Veterinary Medicine, The University of Georgia, Athens, Georgia 30602, USA.

[□] Animal Parasitology Institute, SEA, U.S. Department of Agriculture, Beltsville, Maryland 20705, USA.

TABLE 1. Infectivity of *Sarcocystis* sp. of white-tailed deer for carnivores.

Experiment Number	Origin of Infected Meat	Animal	Number Fed Infected Meat	Number of Controls	Number of Days Feces Examined	Infectivity for Carnivores
1	Georgetown Co., South Carolina	Dog*	6	3	32	+
2	Experimentally Infected Penned Deer	Dog* Cat Raccoon	4 2 1	4 2 0	24-32 45 34	+
3	Brevard Co., Florida	Opossum Raccoon	1 1	0 0	22 33	-
4	Hardy Co., West Virginia	Cat Opossum Raccoon	1 1 2	0 0 0	60 42 42	+
5	Nottoway Co., Virginia	Cat Dog** Opossum Raccoon	2 2 1 2	0 2 0 0	38 38 38 38	-
6	Escambia Co., Florida	Dog** Opossum Raccoon	1 1 1	1 0 1†	37 37 37	+

*Beagle pups

**Doberman x Labrador pups

†Control raccoon died 8 days into experiment

laboratory reared, appeared to be coccidia-free as determined by multiple negative fecal flotations and had not eaten meat. They were used to determine prepatent and patent periods and for production of sporocysts for transmission experiments. Doberman x Labrador pups were littermates reared in an exterior, concrete-floored pen until 8-weeks-old. They were maintained on commercially available dry dog food after weaning. Doberman x Labrador puppies were shedding unsporulated oocysts morphometrically similar to *Isospora canis*, but sporulated oocysts or sporocysts were not detected in preinfection fecal flotations. Beagle x Airedale pups were littermates and were acquired at 6 weeks of age. Pups were fed commercially prepared dry dog food and powdered milk until 8-weeks-old, at which time they were placed on experiment. Beagle x Airedale pups appeared to be coccidia-free as determined by multiple fecal examinations.

Domestic cats used in the experiments were housed in individual cages within a semiclosed colony of cats and fed commercially prepared dry cat food. The cats had been held in the laboratory animal care facility 2 weeks to 6 months before being fed infected deer meat. Cats were coccidia-free with exception of one control cat which sporadically shed unsporulated oocysts morphometrically similar to *Isospora felis*.

A wild-caught female raccoon and two of her captive-born young approximately 1-month-old were acquired from a city park menagerie. The adult female raccoon was held 3 weeks prior to being fed venison, during which time she was fed commercially prepared dry dog food and quail eggs. Fecal examinations performed on the adult raccoon revealed unsporulated oocysts of an *Eimeria* sp. The two young raccoons were held in the laboratory care facility for 3 months prior to being fed infected meat.

The opossum was born in captivity and placed in the laboratory animal care

facility when approximately 4-months-old. Multiple fecal flotations did not reveal coccidian infection. The opossum was fed commercially prepared dry dog food.

All experiments involving carnivores, except Beagle pups, were conducted in the laboratory animal care facility, College of Veterinary Medicine, University of Georgia, Athens, Georgia.

Meat for experiments 1-6 was obtained from 24 deer in four southeastern states (Table 1). Diaphragm, esophagus, heart, loin, thigh muscle and tongue were transported to the University of Georgia on wet ice. Infected muscle tissue was determined by finding sarcocysts in frozen sections (7 μ m) of esophagus, tongue and heart that were stained with hemotoxylin and eosin. Infected meat from each collection was pooled, ground in a food mill and fed daily for 2 to 4 consecutive days to potential definitive hosts. Each feeding consisted of approximately 0.23-1.0 kg of infected meat. Infected venison was shipped on wet ice from Athens to the Animal Parasitology Institute (API) in Beltsville, Maryland, where it was fed to Beagle pups.

Feces from all carnivores were collected daily from the day of feeding for 24 to 60 consecutive days (Table 1). A centrifugal fecal flotation examination was made with Sheather's sugar solution¹⁶ to detect coccidian parasites.

Intermediate host studies (Experiments 7-11). Intermediate host experiments 7 and 9 which involved deer and sheep were conducted in the laboratory animal care facility, College of Veterinary Medicine, University of Georgia. Intermediate host experiments 8, 10 and 11 involving cattle and sheep were conducted at the Animal Parasitology Institute in Beltsville, Maryland.

Sporocysts collected as previously described⁹ from Beagles (experiments 1 and 2) were fed to or orally inoculated into cattle, sheep and white-tailed deer

via gavage. Animals were observed daily for clinical signs of disease. Observations of the calves (experiment 8) also included daily body temperatures; body weights and packed cell volumes were determined at weekly intervals. Observations of the sheep in experiment 11 also included daily body temperatures and body weights taken 2 weeks prior to inoculation, 117 days postinfection (DPI) and 123 DPI.

Prospective intermediate hosts were killed and examined postmortem for gross pathologic lesions. Representative organs and tissues were fixed in 10% neutral buffered formalin for histologic preparation. Tissues were processed according to standard procedures, embedded in paraffin, cut at 7 μ m and stained with hematoxylin and eosin.

Diaphragm, esophagus, heart, skeletal muscle and tongue were collected from prospective intermediate hosts (experiment 7-9), ground and fed to dogs (Table 2). Dogs used for xenodiagnosis consisted of Beagle and Beagle x Airedale pups whose maintenance has been previously described.

Sporocysts obtained from Beagles fed meat of wild white-tailed deer from South Carolina (experiment 1) were given orally to two white-tailed deer (experiment 7, Table 2). Dosages were 5×10^4 and 1×10^6 sporocysts, respectively. The deer were approximately 9-months-old and had been held in an isolated building in the absence of carnivores from approximately 2 to 3 weeks of age (Table 2). Deer were killed 90 DPI.

In experiment 8, each of two calves was orally inoculated with 5×10^5 sporocysts obtained from Beagles fed experimentally infected deer meat (experiment 2), and two calves served as uninoculated controls (Table 2). Calves were 4-month-old male Holstein-Friesian calves reared in isolation from carnivores and housed in individual stalls in an isolated building. Calves were killed 90 DPI.

In experiment 9, an 18-month-old mixed breed sheep and a 6-month-old

white-tailed deer each were given 1×10^5 sporocysts obtained from definitive host experiment 2 (Table 2). The sheep had been reared from birth in a building isolated from carnivores. The deer was reared from approximately 2 to 3 weeks of age in a building isolated from carnivores. Both animals were held in individual stalls. The sheep and deer were killed 120 and 104 DPI, respectively.

In experiment 10, each of two sheep was orally inoculated with sporocysts from Beagles fed experimentally infected deer meat (experiment 2), and one sheep served as an uninoculated control (Table 2). Sheep were 2-month-old male Polled Dorset lambs born and reared in isolation from carnivores and housed in individual stalls. The sheep were killed 94 DPI.

In experiment 11, each of two sheep was orally inoculated with 1×10^6 sporocysts from Beagles fed experimentally infected deer meat. Two sheep served as uninoculated controls (Table 2). Sheep were 4-month-old Polled Dorset lambs which had been reared in isolation from carnivores and housed in individual stalls. The sheep were killed 123 DPI.

An index of infectivity was calculated for all herbivores (Table 2) by counting sarcocysts per section of cardiac and striated muscles (viz., diaphragm, esophagus, skeletal muscle and tongue) and then dividing by the area (cm^2) of the sections. Areas were calculated by projecting the sections from a standard distance and tracing the images. The tracings were measured using a digitizer coupled to an electronic graphics calculator.

RESULTS

Experiments 1-6. All 13 dogs and 1 of 5 cats fed *Sarcocystis*-infected venison shed sporocysts. Sporocysts were not detected in the feces of the raccoons, opossum and unfed control dogs or cats (Table 1).

TABLE 2. Infectivity of sporocysts of *Sarcocystis odocoileocanis* n. sp. for herbivores.

Experiment Number	Herbivore	Number of Sporocysts Inoculated	Number of Infectivity Cardiac	Number of Infectivity Striated	Xenodiagnosis in Dogs
7	White-tailed deer 199	5×10^5	.6	105.6	+
	White-tailed deer 139	1×10^6	3.3	28.9	+
8	Calf 1647	5×10^5	.9	1.6	+
	Calf 1648	5×10^5	.5	1.3	+
	Calf 1649	control	0	0	-
	Calf 1650	control	0	0	-
9	Sheep 55	1×10^5	0	0	-
	White-tailed deer 332	1×10^5	.7	60.1	+
10	Lamb 449	N.D.*	0	0	N.D.
	Lamb 608	N.D.	26.2	29.3	N.D.
	Lamb 448	control	0	0	N.D.
11	Lamb 779	1×10^6	79.7	127.1	+
	Lamb 782	1×10^6	58.4	191.7	+
	Lamb 804	control	1.4	1.5	N.D.
	Lamb 811	control	0	2.1	N.D.

*N.D.=Not Determined

Sporocysts were first observed in the feces of dogs 8 to 16 days (avg. 11.6 days) after the first feeding of infected venison (Table 3). Patent periods were not determined, but sporocysts were found in the feces for at least 38 DPI. Sporocysts first observed 10 DPI in feces from one Beagle (experiment 1) were present in pairs. It was not determined if they were surrounded by an oocyst wall. Sporocysts were next shed by this dog 13 DPI, at which time only single sporocysts were found (Fig. 1). Other dogs did not shed paired sporocysts. Shedding of sporocysts by Beagles was intermittent and never occurred for more than 6 consecutive days. All other dogs shed sporocysts continuously. Sporocysts shed by all dogs were morphologically similar; each sporocyst contained four sporozoites and a compact granular residuum. Sporocysts averaged $15.2 \mu\text{m} \times 10.7 \mu\text{m}$ ($13.2\text{-}15.7 \mu\text{m} \times 8.8\text{-}12.1 \mu\text{m}$) (N=195).

Sporocysts were first detected 14 DPI in the feces of one cat fed meat of wild white-tailed deer from West Virginia. Similar to the dog in experiment 1, sporocysts first observed in feces of the cat were present in pairs and appeared to be surrounded by a very thin oocyst wall. Paired sporocysts gradually decreased in occurrence until only single sporocysts were present. From a total observation period including 17 days preinfection and 60 DPI, sporocysts were detected intermittently between 14 DPI and 38 DPI. Sporocysts contained four sporozoites and a granular residuum which varied from scattered to compact (Fig. 2). Sporocysts averaged $11.49 \mu\text{m} \times 8.09 \mu\text{m}$ ($11\text{-}13.2 \mu\text{m} \times 6.69 \mu\text{m}$) (N=35).

Statistical analysis (pooled t-test) comparing the mean measurements of the length and width of sporocysts passed by the dog and cat demonstrated a significant difference ($P < .01$).

Experiments 7-11. White-tailed deer inoculated with sporocysts in experiment 7 did not have clinical signs or necropsy lesions suggestive of disease. Each

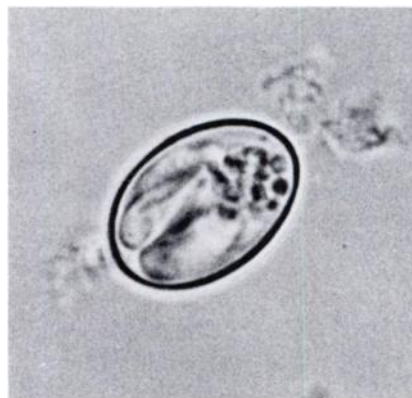

FIGURE 1. *Sarcocystis odocoileocanis* n. sp. sporocyst with 4 sporozoites and granular residuum. $\times 1850$.

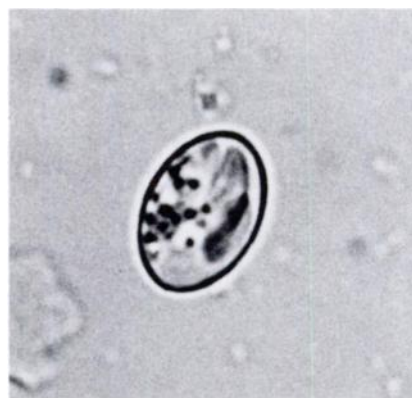

FIGURE 2. Sporocyst shed by a cat fed *Sarcocystis*-infected white-tailed deer meat. $\times 1840$.

histologic section of diaphragm, esophagus, heart, skeletal muscle and tongue contained 1 to 272 sarcocysts (Fig. 4A). Multifocal areas of inflammatory cell infiltration occurred in both skeletal and cardiac muscles and were associated mainly with sarcocysts. The esophagus and tongue were the most heavily affected. Inflammatory foci were similar in both muscle types and consisted of a central concentration of

TABLE 3. Patency range in dogs fed *Sarcocystis*-infected deer meat.

Experiment Number	Origin of Infected Meat	Dog	Patency (DPI)*	Number of Days Feces Examined (DPI)
1	Wild Deer Georgetown Co., South Carolina	Beagle 1	15-32	32
		Beagle 2	16-32	32
		Beagle 3	16-20	32
		Beagle 4	15-31	32
		Beagle 5	10-30	32
		Beagle 6	15-32	32
2	Experimentally Infected Penned Deer	Beagle 10	12-25	27
		Beagle 11	11-24	24
		Beagle 12	14-24	27
		Beagle 13	11-25	27
5	Wild Deer Nottoway Co., Virginia	D-L Dog 2931**	8-38	38
		D-L Dog 2932	9-38	38
6	Wild Deer Escambia Co., Florida	D-L Dog 1506	9-37	37

*Days post inoculation

**Doberman x Labrador pups

mononuclear cells, predominantly macrophages and lymphocytes, with a dispersion of giant cells and eosinophils. A proliferation of sarcolemma nuclei of surrounding muscle fibers was present around the foci. Dogs fed meat from these deer shed sporocysts.

Calves inoculated with sporocysts in experiment 8 had normal weight gains, temperatures and packed cell volumes. Gross lesions were not observed at post-mortem examination. Microscopic examination revealed 1 to 6 sarcocysts in each histologic section of diaphragm, esophagus, heart, ocular muscles, tongue and other skeletal muscles (Fig. 4B). Mild multifocal interstitial myocarditis was present in both experimentally infected calves. The predominant cells present in the microscopic lesions were macrophages, a lesser number of lymphocytes and a few plasma cells. Kidney sections from each calf had predominantly lymphocytic, multifocal, mononuclear cell infiltrates with a vascular distribution. Similar multifocal infiltrates were seen in the lungs and liver. Dogs fed musculature from calves shed sporocysts which were similar to sporocysts collected from dogs fed infected venison. Microscopic examination of tissues from the control calves did not reveal *Sarcocystis* or histopathologic lesions, nor did the dogs fed musculature of the control calves shed sporocysts.

In experiment 9, a sheep inoculated with sporocysts did not show clinical signs nor did histologic examination of selected tissue or xenodiagnosis reveal *Sarcocystis*. A deer, inoculated at the same time as the sheep, became infected as demonstrated histologically and by canine xenodiagnosis.

Neither of two sheep orally inoculated with sporocysts in experiment 10 showed clinical signs of infection and both appeared normal at postmortem examination. Microscopic examination revealed intramuscular cysts in one sheep. In histologic sections of diaphragm, esophagus, heart and

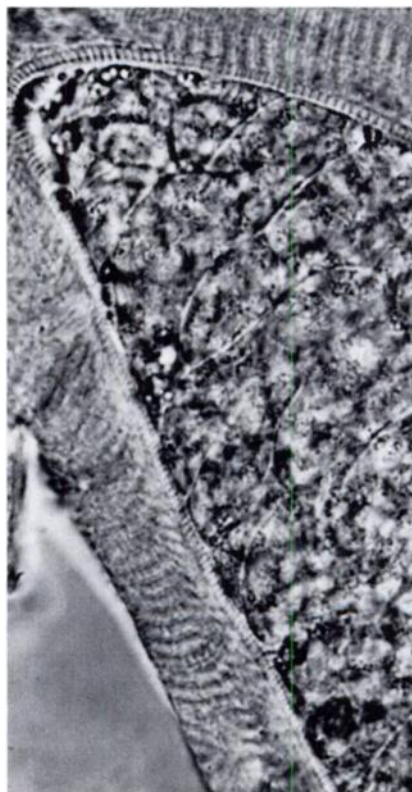


FIGURE 3. A cyst of *Sarcocystis odocoileocanis* n. sp. in skeletal muscle of experimentally infected white-tailed deer. $\times 975$.

tongue, 57, 18, 52 and 66 cysts were found, respectively. Slightly more than half the cysts contained zoites; all cysts contained metrocytes, indicating that all had developed recently. Cysts were not found in the other inoculated sheep or in a control sheep.

In experiment 11, one of the two infected lambs began to lose wool 40 DPI and by 54 DPI there was almost complete alopecia. Temperatures of both infected sheep remained normal. Microscopic examination revealed sarcocysts (Fig. 4C) in both inoculated and both control lambs, however, there were approximate-

ly 100 times the number of sarcocysts per section in the infected lambs than in the controls (Table 2). At 123 DPI, when the experiment was terminated, control lambs had gained 20.8 and 20.2 kg whereas the infected lambs had gained

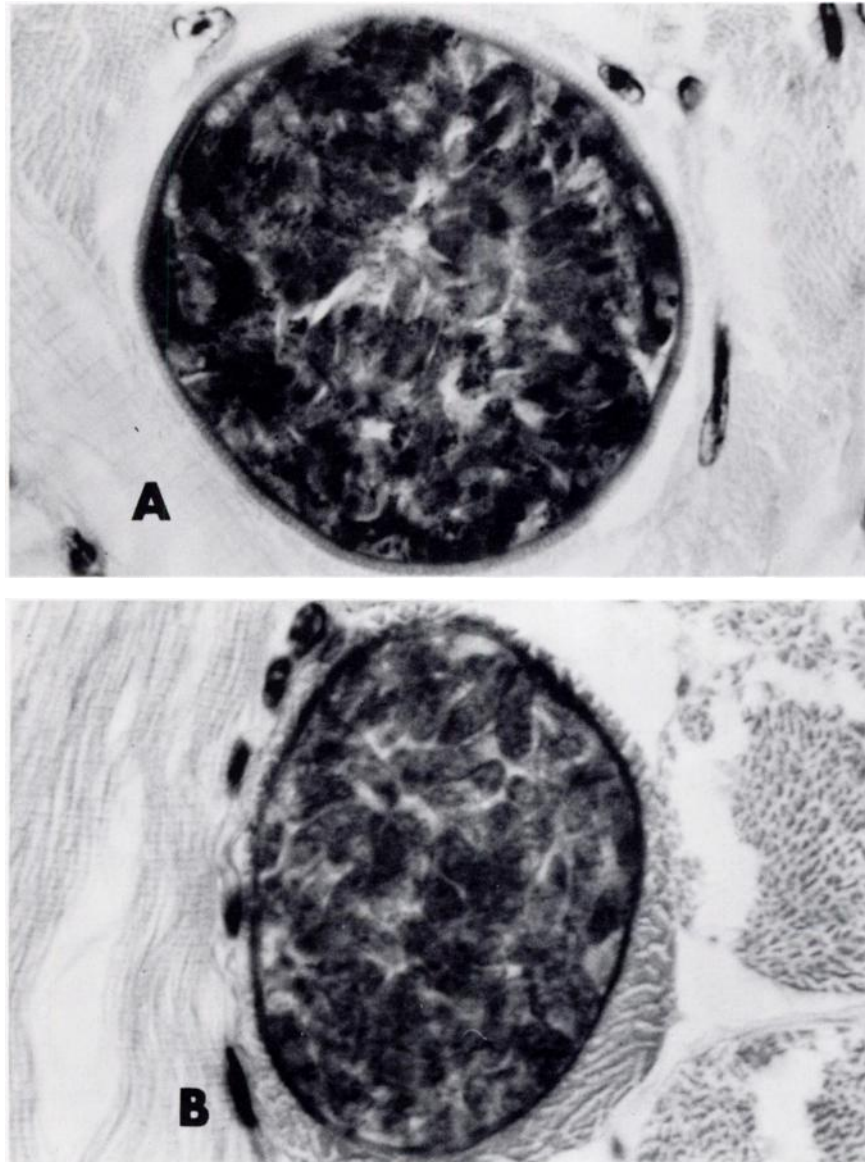


FIGURE 4A and 4B. Cysts of *Sarcocystis odocoileocanis* n. sp. in skeletal muscle of experimentally infected (A) white-tailed deer $\times 1520$, (B) calves $\times 1520$. H & E stain.

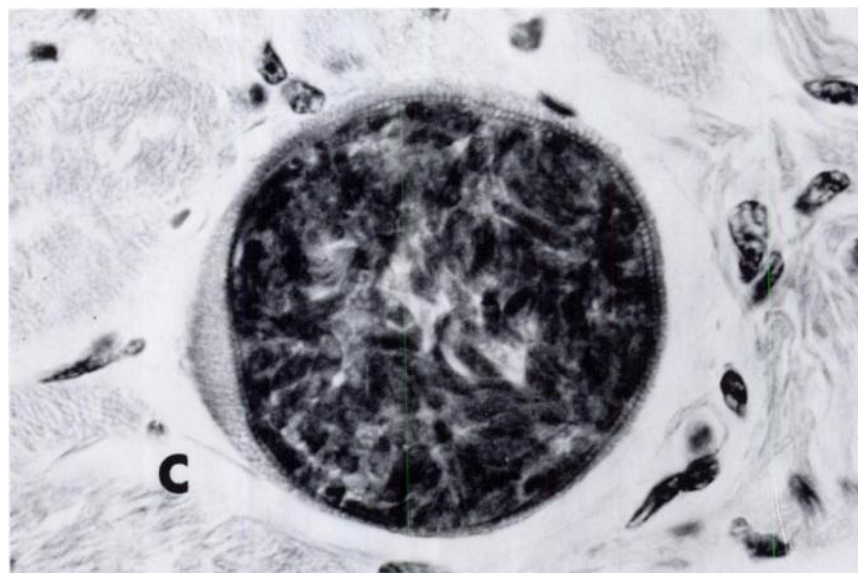


FIGURE 4C. Cysts of *Sarcocystis odocoileocanis* n. sp. in skeletal muscle of experimentally infected (C) lambs $\times 1075$. H & E stain.

only 7.7 and 8.2 kg. Two dogs fed infected lamb shed large numbers of sporocysts from 8-26 DPI and 12-27 DPI, respectively. These sporocysts were similar to those collected from dogs fed infected venison. The dogs were killed at 28 and 29 DPI, and approximately 17×10^6 sporocysts were found in mucosal scrapings from each dog.

Sarcocysts observed in all deer, calves and lambs were morphologically indistinguishable.

Description: *Sarcocystis odocoileocanis* n.sp., (Fig. 1, 3, 4).

Intramuscular cysts occur in both cardiac and skeletal muscles of white-tailed deer, cattle and sheep. Cysts in skeletal muscle of deer 104 days post inoculation measure $149.5 \mu\text{m}$ to $535.9 \mu\text{m}$ by $29.9 \mu\text{m}$ to $50.6 \mu\text{m}$ (avg. $264.0 \mu\text{m} \times 39.9 \mu\text{m}$ N=15). Prepatent period in dogs varies from 8 to 16 days (avg. 11.6 days). Patent period is ≥ 38 days. Sporocysts $13.2 \mu\text{m}$ to $15.7 \mu\text{m}$ by $8.8 \mu\text{m}$ to $12.1 \mu\text{m}$ (avg. $15.2 \mu\text{m} \times 10.7 \mu\text{m}$ N=195) contain four

sporozoites and a compact granular residuum. A stieda body is absent.

Intermediate Host: primarily white-tailed deer (*Odocoileus virginianus*); secondarily, cattle (*Bos taurus*), sheep (*Ovis aries*).

Definitive Host: Domestic dog (*Canis familiaris*)

Type Locale: South Island, Georgetown County, South Carolina. Additional Locales: Escambia County, Florida, and Nottoway County, Virginia.

Type Specimens: Tissue cysts deposited in U.S.N.M. Collection No. 76621.

DISCUSSION

The results of this study are similar to previous studies on the life cycle of *Sarcocystis* spp.⁷ As in moose,² mule deer,^{10,11,14} wapiti¹⁸ and domestic ruminants,^{5,20} the life cycle of one species of *Sarcocystis* in white-tailed deer is completed through Canidae.

Sporocysts shed by dogs in the present study are similar morphometrically to sporocysts of *S. hemionilatrantis* Hudkins and Kistner, 1977 from mule deer,^{10,11} *S. ovicanis* Heydorn, Gestrich, Mehlhorn and Rommel, 1975 from sheep^{19,20} and *S. cruzi* Hasselmann, 1926 (= *S. bovicanis* Heydorn, Gestrich, Mehlhorn and Rommel, 1975) from cattle.^{3,11} Unlike *S. hemionilatrantis*, *S. odocoileocanis* is infective for cattle and sheep and is less pathogenic for its intermediate host as compared to previously reported comparable infections of *S. hemionilatrantis*.^{10,14} *Sarcocystis odocoileocanis* differs from *S. ovicanis* in pathogenicity for sheep and infectivity for calves; it did not produce clinical signs in lambs as severe as those reported in comparable experimental infections of *S. ovicanis* in lambs¹⁵ but was infective for calves while *S. ovicanis* is not.⁶ *Sarcocystis odocoileocanis* differs from *S. cruzi* in pathogenicity and infectivity for calves; it did not produce clinical or microscopic manifestations in calves similar to those reported in comparable experimental infections of *S. cruzi* in calves.^{4,12} Infectivity for bovine heart was comparable to that for white-tailed deer heart, but infectivity for bovine striated muscle was less than infectivity for white-tailed deer striated muscle as demonstrated by the number of sarcocysts present in the calves as compared to white-tailed deer (Table 2). Previous studies revealed raccoons shed sporocysts of *S. cruzi*.⁶ This differs from the present findings in that

raccoons did not become infected with *S. odocoileocanis*.

The successful transmission of *S. odocoileocanis* to cattle and sheep parallel recent findings that avian *Sarcocystis* can infect multiple intermediate hosts.¹ However, the low infectivity and pathogenicity of this parasite for cattle and sheep as demonstrated in the present study suggest cattle and sheep are of little clinical consequence in the epizootiology of *S. odocoileocanis* in white-tailed deer and *vice versa*.

The apparent infection of the cat revealed by this study suggests that a second species of *Sarcocystis* exists in white-tailed deer. Reasons for the detection of this possible species in only one locality are unknown, but geographic differences in evolutionary developed predator-prey relationships possibly could be an explanation. Without experimental repetition it would be premature to conclusively confirm a species of *Sarcocystis* with a feline definitive host.

The wide geographic origin of infected deer utilized in this study suggests a uniformity in the deer-dog species of *Sarcocystis* in white-tailed deer throughout the southeastern United States. Additional surveys and transmission studies involving other carnivores or scavengers and deer of different locales are needed to fully understand the species and epizootiology of *Sarcocystis* infections in white-tailed deer.

Acknowledgements

The authors wish to thank personnel of the game and fish agencies of Florida, South Carolina, Virginia and West Virginia for aid in collecting animals, and members of the staff of the Southeastern Cooperative Wildlife Disease Study are acknowledged for technical assistance.

LITERATURE CITED

1. BOX, E.D. and D.W. DUSZYNSKI. 1978. Experimental transmission of *Sarcocystis* from icterid birds to sparrows and canaries by sporocysts from the opossum. *J. Parasit.* 64: 682-688.

2. DUBEY, J.P. 1980. *Sarcocystis* species in moose (*Alces alces*), Bison (*Bison bison*), and Pronghorn (*Antilocapra americana*) in Montana. *Am. J. Vet. Res.* 41: 2063-2065.
3. FAYER, R. 1974. Development of *Sarcocystis fusiformis* in the small intestine of the dog. *J. Parasit.* 60: 660-665.
4. ——— and A.J. JOHNSON. 1974. *Sarcocystis fusiformis*: Development of cysts in calves infected with sporocysts from dogs. *Proc. Helm. Soc. Wash.* 41: 105-108.
5. ——— and ———. 1975. *Sarcocystis fusiformis* infection in the coyote (*Canis latrans*). *J. Infect. Dis.* 131: 189-192.
6. ———, ——— and P.K. HILDEBRANDT. 1976. Oral infection of mammals with *Sarcocystis fusiformis* bradyzoites from cattle and sporocysts from dogs and coyotes. *J. Parasit.* 62: 10-14.
7. FRENKEL, J.K. 1974. Advances in the biology of sporozoa. *Z. Parasitenk.* 45: 125-162.
8. GESTRICH, V.R., A.O. HEYDORN and N. BAYSU. 1975. Beiträge zum Lebenszyklus der Sarkosporidien VI. Untersuchungen zur Artendifferenzierung bei *Sarcocystis fusiformis* und *Sarcocystis tenella*. *Berl. Münch. Tierärztl. Wschr.* 88: 191-197.
9. HAMMOND, D.M., B. CHOBOTAR and J.V. ERNST. 1968. Cytological observations on sporozoites of *Eimeria bovis* and *E. auburnensis*, and an *Eimeria* species from the Ord kangaroo rat. *J. Parasit.* 54: 550-558.
10. HUDKINS, G. and T.P. KISTNER. 1977. *Sarcocystis hemionilatrans* (Sp. N.) life cycle in mule deer and coyotes. *J. Wildl. Dis.* 13: 80-84.
11. HUDKINS-VIVION, G., T.P. KISTNER and R. FAYER. 1976. Possible species differences between *Sarcocystis* from mule deer and cattle. *J. Wildl. Dis.* 12: 86-87.
12. JOHNSON, A.J., P.K. HILDEBRANDT and R. FAYER. 1975. Experimentally induced *Sarcocystis* infection in calves: Pathology. *Am. J. Vet. Res.* 36: 995-999.
13. KARSTAD, L. and D.O. TRAINER. 1969. *Sarcocystis* in white-tailed deer. *Bull. Wildl. Dis. Assoc.* 5: 25-26.
14. KOLLER, L.D., T.P. KISTNER and G.G. HUDKINS. 1977. Histopathologic study of experimental *Sarcocystis hemionilatrans* infection in fawns. *Am. J. Vet. Res.* 38: 1205-1209.
15. LEEK, R.G., R. FAYER and A.J. JOHNSON. 1977. Sheep experimentally infected with *Sarcocystis* from dogs. I. Disease in young lambs. *J. Parasit.* 63: 642-650.
16. LEVINE, N.D. 1973. *Protozoan Parasites of Domestic Animals and of Man*. Burgess Publishing Co., Minneapolis. 380 pp.
17. MAHRT, J.L. and D.D. COLWELL. 1980. *Sarcocystis* in wild ungulates in Alberta. *J. Wildl. Dis.* 16: 571-576.
18. MARGOLIN, J.H. and W.R. JOLLEY. 1979. Experimental infection of dogs with *Sarcocystis* from wapiti. *J. Wildl. Dis.* 15: 259-262.
19. MUNDAY, B.L., I.K. BARKER and M.D. RICHARD. 1975. The developmental cycle of a species of *Sarcocystis* occurring in dogs and sheep, with observations on pathogenicity in the intermediate host. *Z. Parasitenk.* 46: 111-123.

20. ——— and M.D. RICHARD. 1974. Is *Sarcocystis tenella* two species? Aust. Vet. J. 50: 558-559.
21. POND, D.B. and C.A. SPEER. 1979. *Sarcocystis* in free-ranging herbivores on the National Bison Range. J. Wildl. Dis. 15: 51-53.
22. PRESTWOOD, A.K., S.R. PURSGLOVE and F.A. HAYES. 1976. Parasitism among white-tailed deer and domestic sheep on common range. J. Wildl. Dis. 12: 380-385.
23. SAYAMA, K. 1952. *Sarcocystis* in deer and elk of California. Calif. Fish and Game J. 38: 99-104.

Received for publication 1 March 1981
