



POLIOENCEPHALOMALACIA-LIKE DISEASE IN PRONGHORNS (ANTILOCAPRA AMERICANA)

Authors: Wobeser, G., Daoust, P.-Y., and Hunt, H. M.

Source: Journal of Wildlife Diseases, 19(3) : 248-252

Published By: Wildlife Disease Association

URL: <https://doi.org/10.7589/0090-3558-19.3.248>

BioOne Complete (complete.BioOne.org) is a full-text database of 200 subscribed and open-access titles in the biological, ecological, and environmental sciences published by nonprofit societies, associations, museums, institutions, and presses.

Your use of this PDF, the BioOne Complete website, and all posted and associated content indicates your acceptance of BioOne's Terms of Use, available at www.bioone.org/terms-of-use.

Usage of BioOne Complete content is strictly limited to personal, educational, and non - commercial use. Commercial inquiries or rights and permissions requests should be directed to the individual publisher as copyright holder.

BioOne sees sustainable scholarly publishing as an inherently collaborative enterprise connecting authors, nonprofit publishers, academic institutions, research libraries, and research funders in the common goal of maximizing access to critical research.

POLIOENCEPHALOMALACIA-LIKE DISEASE IN PRONGHORNS (*ANTILOCAPRA AMERICANA*)

G. Wobeser,¹ P.-Y. Daoust,^{1,3} and H. M. Hunt²

ABSTRACT: A disease resembling thiamine-responsive polioencephalomalacia of domestic ruminants is described in four wild pronghorn from Saskatchewan. One animal was found dead, two were recumbent and unable to rise and the fourth was staggering and ataxic. Lesions were confined to the brain and consisted of brain swelling with herniation, symmetrical hemorrhagic foci in the thalamus and brainstem, and laminar necrosis of cortical neurons. All animals had been eating grain prior to their death. Possible pathogenetic mechanisms including changes in rumen microflora resulting in thiamine deficiency, plant and salt intoxication are discussed.

INTRODUCTION

Polioencephalomalacia (PEM) or "cerebro-cortical necrosis" is a noninfectious degenerative disease of the central nervous system of ruminants. It was first described in cattle and sheep in the USA (Jensen et al., 1956) and is now recognized to occur in these species, as well as goats in many areas of the world. PEM has been reported in a captive fallow deer (*Dama dama*) (Markson and Giles, 1973), wild white-tailed deer (*Odocoileus virginianus*) from Minnesota (Kurtz and Karns, 1969), South Dakota (Reed et al., 1976), and Saskatchewan (Wobeser and Runge, 1979), and a wild mule deer (*Odocoileus hemionus*) from South Dakota (Reed et al., 1976). Tournut et al. (1967) identified the disease on the basis of clinical signs and response to thiamine therapy in an "antelope" of unidentified species in which the disease was not confirmed by histologic studies. This report describes cases of PEM-like disease in pronghorn from Saskatchewan.

METHODS AND MATERIALS

On 14 September 1982 case A, a male kid that was part of a band of 20 pronghorn in a grain-growing area was noted to be "staggering, getting up and falling down." It was approached and shot through the neck by a police officer and submitted to the laboratory the following day. At least one other an-

imal from this band was known to have died at about this time, but was not available for necropsy. On 26 September 1982 case B, a male kid, was found lying on its side in a grain field in another area of southern Saskatchewan. It was unable to rise or to raise its head. The animal was paddling and had been for some time, as indicated by marks at the site. It was shot in the neck and brought to the laboratory for necropsy within approximately 8 hr.

In addition to the cases reported above, we have seen two additional cases that may represent the same disease. These occurred in February and March 1979, and unfortunately, autolysis and freezing made meaningful histologic examination impossible. One of these, case C, was an adult female found alive, but unable to stand. The animal was killed and held frozen for some time before submission to the laboratory. Case D was a young animal (sex not recorded), found dead and submitted without any history of clinical signs.

A necropsy was performed on each animal and samples of all major organs, including the entire brain, from animals A and B were fixed in neutral buffered 10% formalin. After fixation for several days the brain from cases A and B was sectioned and examined under ultraviolet light (Wood's lamp). Portions of brain and other tissues were processed routinely, embedded in paraffin, sectioned at 6 μ m and stained with hematoxylin and eosin.

RESULTS

At necropsy, case A was judged to be in fair body condition, with a small amount of fat present, and weighed 19.9 kg. There was subcutaneous and intramuscular bruising over the right hip, but no lesion was found in the abdominal or thoracic organs. The rumen contained predominantly wheat and weed seeds, with a small amount of green forb material. The brain was pale, appeared swollen, and the cerebellum was markedly coned, with herniation into the foramen magnum (Fig. 1). Under ultraviolet light there were distinct areas of yellow-white fluorescence in the grey matter along the sides of some gyri, particularly about the

Received for publication 28 December 1982.

¹ Department of Veterinary Pathology, Western College of Veterinary Medicine, University of Saskatchewan, Saskatoon, Saskatchewan S7N 0W0, Canada.

² Wildlife Branch, Department of Tourism and Renewable Resources, 3211 Albert Street, Regina, Saskatchewan S4S 5W6, Canada.

³ Present address: Department of Pathology, Ontario Veterinary College, University of Guelph, Guelph, Ontario N1G 2W1, Canada.

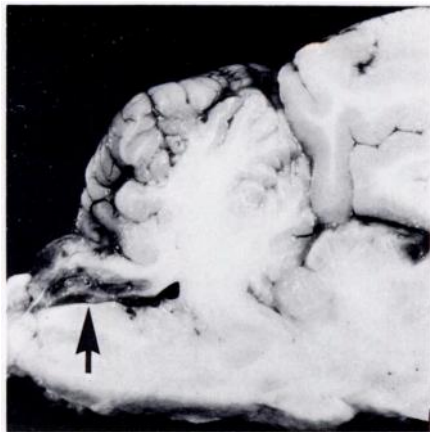


FIGURE 1. Sagittal section through cerebellum and brainstem of pronghorn with PEM-like disease (Case A). A portion of the cerebellum has been forced caudally into the foramen magnum by increased intracranial pressure (arrow).

gyrus marginalis, in the mid-dorsal aspect of the cerebrum. Small fluorescent foci were also evident in the cerebellum.

Case B was in good body condition and weighed 22 kg. No gross lesions were found other than in the brain. The rumen contained predominantly green forbs with a small volume of wheat. The brain was swollen and herniation of the cerebellum was so severe that the her-

niated portion was transected in disarticulating the atlanto-occipital joint. There was bilaterally symmetrical hemorrhage in the area of the lateral geniculate bodies (Fig. 2), as well as in the area of the rostral colliculi. There was softening of the grey matter along the sides and over the tips of gyri in the mid-dorsal area of the cerebrum and petechial hemorrhages were evident in this area (Fig. 2). Under ultraviolet light, there was fluorescence of the grey matter in these same areas of the cerebral cortex (Fig. 3).

Case C was in good body condition with lesions found only in the brain. There was symmetrical hemorrhage in the lateral thalamic area and in the caudal and rostral colliculi. The rumen contained mostly grain. Case D was also in good body condition with abundant fat. One side of the body was coated with feces, suggesting that the animal had been in lateral recumbency for some time prior to death. Lesions were restricted to the brain. The cerebellum was herniated and focal hemorrhage was present in the lateral areas of the thalamus and the central region of the cerebellum. The rumen contained a small amount of grain and fluid.

The microscopic lesions in cases A and B were very similar. Changes in the cerebral cortex were restricted to the grey matter and were somewhat focal, involving the sides and tips of the gyri, but tending to spare the depths of the

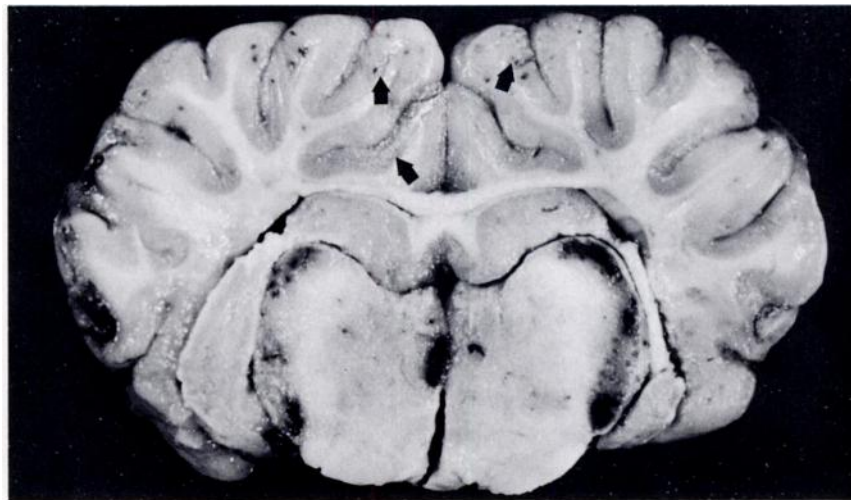

FIGURE 2. Cross-section of brain of pronghorn with PEM-like disease (Case B). There is hemorrhage in the thalamus, including the lateral geniculate nuclei, and petechiae and softening are evident in the grey matter of the cerebral cortex and thalamus (arrows).

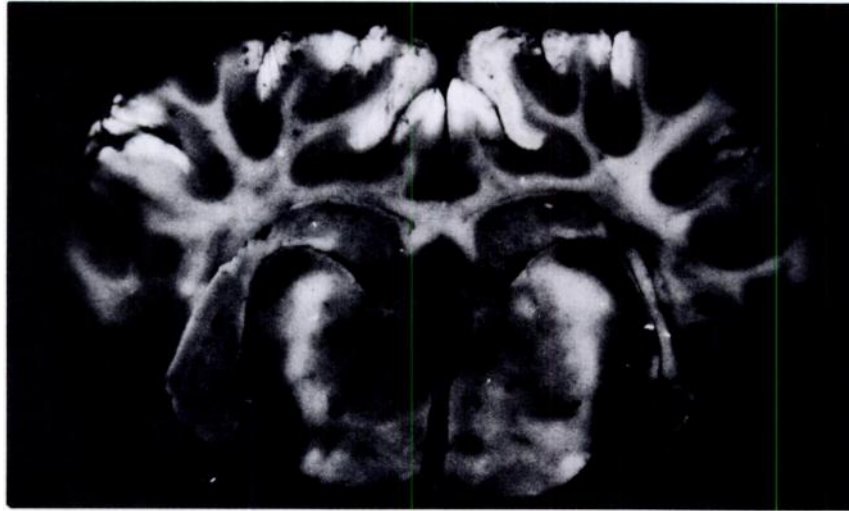


FIGURE 3. Same specimen as in Figure 2, photographed under ultraviolet light. Fluorescence is present over the tips and along the sides of some gyri.

sulci. The main lesion was laminar necrosis of neurons involving any or all laminae, but most commonly, the central or deeper layers were affected. Neurons in the affected areas were shrunken, basophilic and angular with pyknotic nuclei and were surrounded by a large vacuole. In some areas vacuolation and edema were so severe that the neuropil was spongiform. Microscopic hemorrhages were numerous in the affected areas of the cerebral cortex. No macrophages were evident and endothelial cell swelling was minimal. Hemorrhage was not visible grossly in the thalamic area in animal A, but there were many microscopic hemorrhages in the lateral geniculate bodies. Neurons in the areas of hemorrhage in the midbrain of both animals were distinctly eosinophilic, swollen, and some were undergoing chromatolysis. Capillary endothelial cells in these areas were swollen. The herniated portion of cerebellum in both animals had many small hemorrhages and the neuropil was pale-staining and vacuolated. Granule cells were pyknotic or karyorrhetic, whereas affected Purkinje cells were eosinophilic and undergoing chromatolysis. There was hemorrhage and vacuolation in the medulla underlying the herniated cerebellum.

DISCUSSION

Significant lesions in all these animals were restricted to the brain and consisted of degen-

erative changes, with evidence of brain swelling, increased intracranial pressure and herniation of the cerebellum into the foramen magnum in three of the animals. The gross and histologic changes were similar to those described in PEM of domestic animals (Jubb and Kennedy, 1970) and deer (Wobeser and Runge, 1979). Hemorrhagic foci occur in the same focal areas in domestic animals with PEM as in these pronghorn (Jubb and Kennedy, 1970), but are not a common occurrence.

Despite a large amount of research the pathogenesis of PEM is not understood completely. It may be that a single etiology will not explain all cases (Bestetti and Fankhauser, 1979). It is accepted generally that thiamine deficiency plays an important role in the disease. Adult ruminants synthesize this vitamin within the rumen; however, thiamine-destroying enzymes (thiaminases) have also been found in the rumen of some animals. One of these enzymes, thiaminase I, not only causes cleavage of thiamine, but can also create thiamine analogs that could act as anti-thiamine agents (Edwin and Jackman, 1981). A number of species of bacteria may produce thiaminases in the rumen, but attempts to reproduce the disease by introducing these bacteria into the rumen of healthy calves and lambs have been unsuccessful (Edwin and Jackman, 1981). PEM is often associated with a high concentrate ration, or with a

change to a more concentrated diet, although cases can occur under other circumstances. Brent (1976) and Sapienza (1981) established that animals changed from a low to a high concentrate ration had high levels of thiaminase and low levels of thiamine in the rumen. This was thought to be the result of proliferation of *Clostridia* spp. and other Gram-positive bacteria that produce thiaminase. The acidic pH of the rumen content in these conditions would also be favorable for thiaminase activity.

A relationship between diet and PEM is interesting, in that grain was present in the rumen of all four pronghorn examined, and in cases A and B indicated a recent change in diet. The grain harvest was occurring at the time those animals were found, and grain had not been available to pronghorn for more than a few weeks. Dirschl (1963) reported grain to be a minor item in the diet of pronghorn in Saskatchewan; however, the animals which he examined were from areas with little cultivated land. The animals reported here were all from areas in which cropland predominated. We have found grain commonly in pronghorns necropsied during fall and winter and have also seen cases of rumenitis and rumen overload related to the consumption of grain.

A number of other possible causes for PEM-like disease have been suggested. Of these, two might be considered in these cases. Polioencephalomalacia has been associated with water deprivation and hypernatremia in cattle (Trueman and Clague, 1978; Padovan, 1980), and Raisbeck (1982) suggested that PEM might be associated with diets high in sulfate salts. Raisbeck (1982) proposed several mechanisms in the latter case, including degradation of thiamine in the rumen by sulfide. Many surface waters in southern Saskatchewan are saline and contain large amounts of sulfate salts, including sodium sulfate, so it is possible that these animals might have been consuming such salts.

Some wild plants (e.g., bracken, *Pteridium aquilinum*, and horse-tail, *Equisetum arvense*) contain thiaminase I, and Evans et al. (1975) produced PEM-like disease in sheep by feeding bracken rhizomes. These particular plants are unlikely to be present in the areas where the pronghorn were found, but it is possible that other plants might produce thiaminase. *Kochia scoparia*, that is "a weed in the vicinity of most towns and cities in the Praries" (Looman and Best, 1979) has been associated with a PEM-

like disease in cattle (Dickie and Berrymann, 1979). The affected cattle had evidence of photosensitization, a lesion not seen in the pronghorn, and we have no evidence that pronghorn eat this plant.

This disease in pronghorn seems to be very similar to PEM in other ruminants, but it would be useful to have additional information, such as blood pyruvate and lactate levels and erythrocyte transketolase activity to confirm the diagnosis. The prevalence of the disease in pronghorn is unknown and the condition would be overlooked without careful examination of the brain.

Examination of brain tissue under ultraviolet light is a useful rapid technique for detecting lesions of PEM (Little, 1978); however, the test is not specific, and fluorescence occurs in other types of brain necrosis (Ziffo and Inglis, 1974; Lee and Little, 1980).

ACKNOWLEDGMENTS

We thank the resource officers of the Department of Tourism and Renewable Resources for submission of these specimens. The study was supported by funds from the Department of Tourism and Renewable Resources, Saskatchewan, for the study of diseases of wildlife.

LITERATURE CITED

- BESTETTI, V. G., AND R. FANKHAUSER. 1979. Vergleichende licht- und elektronenmikroskopische Untersuchungen zur Hirnrindennekrose der Wiederkäuser. *Schweiz. Arch. Tierheilkd.* 121: 467-477.
- BRENT, B. E. 1976. Relationship of acidosis to other feedlot ailments. *J. Anim. Sci.* 43: 930-935.
- DICKIE, C. W., AND J. R. BERRYMAN. 1979. Polioencephalomalacia and photosensitization associated with *Kochia scoparia* consumption in range cattle. *J. Am. Vet. Med. Assoc.* 175: 463-465.
- DIRSCHL, H. J. 1963. Food habits of the pronghorn in Saskatchewan. *J. Wildl. Manage.* 27: 81-93.
- EDWIN, E. E., AND R. JACKMAN. 1981. Ruminant thiamine requirements in perspective. *Vet. Res. Commun.* 5: 237-250.
- EVANS, W. G., I. A. EVANS, D. J. HUMPHREYS, B. LEWIN, W. E. J. DAVIES, AND R. F. E. ANFORD. 1975. Induction of thiamine deficiency in sheep with lesions similar to those of cerebrocortical necrosis. *J. Comp. Pathol.* 85: 253-265.
- JENSEN, R., L. A. GRINER, AND O. R. ADAMS. 1956. Polioencephalomalacia of cattle and sheep. *J. Am. Vet. Med. Assoc.* 129: 311-321.
- JUBB, K. V. F., AND P. C. KENNEDY. 1970. *Pathology of Domestic Animals*, Vol. 2 (2nd Ed.). Academic Press, New York, 697 pp.

- KURTZ, H. J., AND P. D. KARNS. 1969. Polioencephalomalacia in a white-tailed deer (*Odocoileus virginianus borealis*). *Pathol. Vet.* 6: 475-480.
- LEE, J. Y. S., AND P. B. LITTLE. 1980. Studies of autofluorescence in experimentally induced cerebral necrosis in pigs. *Vet. Pathol.* 17: 226-233.
- LITTLE, P. B. 1978. Identity of fluorescence in polioencephalomalacia. *Vet. Rec.* 103: 76.
- LOOMAN, J., AND K. F. BEST. 1979. Budd's Flora of the Canadian Prairie Provinces. *Agric. Canada Publ.* 1662. Hull, Quebec, Canada, 824 pp.
- MARKSON, L. M., AND N. GILES. 1973. Cerebrocortical necrosis in a fallow deer (*Dama dama*). *Vet. Rec.* 93: 243-246.
- PADOVAN, D. 1980. Polioencephalomalacia associated with water deprivation in cattle. *Cornell Vet.* 70: 153-159.
- RAISBECK, M. F. 1982. Is polioencephalomalacia associated with high sulfate diets? *J. Am. Vet. Med. Assoc.* 180: 1303-1304.
- REED, D. E., H. SHAVE, M. E. BERGELAND, AND C. E. GATES. 1976. Necropsy and laboratory findings in free-living deer in South Dakota. *J. Am. Vet. Med. Assoc.* 169: 975-979.
- SAPIENZA, D. A. 1981. An hypothesis for the etiology of polioencephalomalacia. Ph.D. Thesis. Kansas State Univ., Manhattan, Kansas, 167 pp.
- TOURNUT, J., C. LABIE, AND J. ESPINASSE. 1967. Identification en France, de la "nécrose du cortex central" (N.C.C.) chez plusieurs espèces de ruminants. *Rev. Med. Vet. (Lyon, Toulouse)* 118: 883-896.
- TRUEMAN, K. F., AND D. C. CLAQUE. 1978. Sodium chloride poisoning in cattle. *Aust. Vet. J.* 54: 89-91.
- WOBESER, G., AND W. RUNGE. 1979. Polioencephalomalacia in white-tailed deer in Saskatchewan. *Can. Vet. J.* 20: 323-325.
- ZIFFO, G. S., AND D. M. INGLIS. 1974. Examination of brain tissue. *Vet. Rec.* 94: 252.

Journal of Wildlife Diseases, 19(3), 1983, p. 252
© Wildlife Disease Association 1983

BOOK REVIEW . . .

Wildlife Diseases of the Pacific Basin and Other Countries, M. E. Fowler, ed. Wildlife Disease Association, Inc., P.O. Box 886, Ames, Iowa 50010, USA. 1981. 262 pp. \$19.00 US plus \$1.00 postage (soft-back).

This proceedings contains the papers presented at the Fourth International Conference of the Wildlife Disease Association (WDA) held in Sydney, Australia, on August 25-28, 1981. The major emphasis of the conference was on wildlife diseases unique to the Pacific Basin, but also included is information on wildlife disease problems in Europe, Scandinavia, Africa, North America, and Asia.

The proceedings is divided into seven major sections, the first of which includes welcoming, presidential, keynote, and overview addresses of the conference. Of particular interest is the review of the development and growth of the WDA during its first 30 years. This article traces the history and accomplishments of the organization and its leaders. Also in this section are four good reviews of wildlife disease problems in the Pacific Basin which set the stage for many of the technical papers that follow.

The second section contains articles on zoonotic diseases. Within this section are exceptionally good epidemiologic reviews on La Crosse virus, Ross River virus, and Murray Valley Encephalitis virus. Other articles cover specific aspects of certain zoonoses.

The next section deals with infectious diseases and contains a good mixture of articles dealing with different diseases, geographic locations, and wildlife species. Original research on a carrier status for duck plague virus, a bibliography on diseases of wombats, a review of the epizootiology of malignant catarrhal fever, and an article with new perspectives on anthrax highlight this section.

The fourth section on parasitic diseases contains several good papers including descriptions of *Besnoitia*-like agents in flamingos, a review of parasitism

in kiwis, and a review of anaplasmosis. The best of this section, however, is the intriguing account of the introduction and spread of sarcoptic mange in red fox populations in Sweden.

The fifth section on nutrition and toxicology is brief and limited to only five papers. The following section on special animal groups is much more varied and contains several interesting articles. Many papers in this section deal with diseases of marine species and would be of special interest to researchers in this field.

The last section relates to wildlife diseases in a general way and includes subjects such as avian rehabilitation, suggestions for preventing capture myopathy, and reference hematology values for several species of birds. These articles should be particularly useful to individuals working in these areas because they are clear, concise treatments of the subjects.

As noted by Editor Fowler, papers were neither refereed nor edited to conform to uniform style. Thus, the proceedings contains a few typographical errors, grammatical miscues, and inconsistencies, but these problems are a minor inconvenience to the reader.

This publication has an amazing number of tables (74) and figures (96) for a conference proceedings, and these add measurably to its appeal. As with most conference proceedings, it would be a rare individual who would have occasion to refer to each article, nevertheless, the varied subjects insure that there will be at least some papers of interest to every wildlife disease worker. For members of the WDA, the highlights of the history and development of their organization are alone worth the \$19.00 cost!

W. R. Davidson, Southeastern Cooperative Wildlife Disease Study, Department of Parasitology, College of Veterinary Medicine, The University of Georgia, Athens, Georgia 30602, USA.