



Cutaneous Granules Associated with Dermatophilosis in a White-tailed Deer

Authors: Salkin, I. F., Gordon, M. A., and Stone, W. B.

Source: Journal of Wildlife Diseases, 19(4) : 361-363

Published By: Wildlife Disease Association

URL: <https://doi.org/10.7589/0090-3558-19.4.361>

BioOne Complete (complete.BioOne.org) is a full-text database of 200 subscribed and open-access titles in the biological, ecological, and environmental sciences published by nonprofit societies, associations, museums, institutions, and presses.

Your use of this PDF, the BioOne Complete website, and all posted and associated content indicates your acceptance of BioOne's Terms of Use, available at www.bioone.org/terms-of-use.

Usage of BioOne Complete content is strictly limited to personal, educational, and non - commercial use. Commercial inquiries or rights and permissions requests should be directed to the individual publisher as copyright holder.

BioOne sees sustainable scholarly publishing as an inherently collaborative enterprise connecting authors, nonprofit publishers, academic institutions, research libraries, and research funders in the common goal of maximizing access to critical research.

pathological condition observed in the buzzard was an enlarged spleen. This picture can sometimes be seen in birds with other *Pasteurella* infections (Gratzl and Köhler, 1968, *In Spezielle Pathologie und Therapie der Geflügelkrankheiten*, Verlag, Stuttgart, West Germany, pp. 493–531). The absence of other pathogens indicates that tularemia was probably the primary cause of death.

The typical post-mortem picture of emaciated owls is atrophy of the pectoralis muscles,

generalized anemia and ulcers in the gizzard. The Ural owl was in very poor condition but not totally starved. The lesions observed at necropsy were typical of starving birds except for the marked congestion of the spleen. Usually the spleen is small and pale, due to loss of blood due to the ulcers. Histologic findings showing congestion in internal organs and the isolation of *F. tularensis* could indicate that death was not merely caused by starvation, but a combination of poor condition and tularemia.

Journal of Wildlife Diseases, 19(4), 1983, pp. 361–363
© Wildlife Disease Association 1983

Cutaneous Granules Associated with Dermatophilosis in a White-tailed Deer

I. F. Salkin and M. A. Gordon, Center for Laboratories and Research, New York State Department of Health, Albany, New York 12201, USA; and W. B. Stone, Wildlife Research Center, New York State Department of Environmental Conservation, Delmar, New York 12054, USA

Dermatophilosis, an exudative epidermitis caused by the aerobic actinomycete *Dermatophilus congolensis*, occurs worldwide but is more prevalent in tropical or subtropical climates. Although the disease is most frequently found in domestic animals (cattle, sheep, goats, horses), many species of wildlife have been affected (Richard, 1981, *In Infectious Diseases of Wild Mammals*, Davis et al. (eds.), Iowa State Univ. Press, Ames, Iowa, pp. 339–346). During the last 5 yr we have observed in New York State and vicinity, 27 cases of dermatophilosis in white-tailed deer (*Odocoileus virginianus*), 10 cases in raccoons (*Procyon lotor*), and one each in a woodchuck (*Marmota monax*) and a striped skunk (*Mephitis mephitis*) (Salkin et al., 1975, *J. Am. Vet. Med. Assoc.* 157: 571–573; Gordon et al., 1977, *J. Wildl. Dis.* 13: 184–190; Salkin et al., 1981, *J. Clin. Microbiol.* 14: 604–606). In all of these cases the etiologic agent was restricted to the epidermal tissue. However, Gibson and co-workers (Gibson et al., 1983, *Vet. Pathol.* 20: 120–122) recently described subcutaneous and lymph node granulomas

caused by *D. congolensis* in a steer and the presence of actinomycotic granules.

We now report a case of suspected systemic dermatophilosis in a white-tailed deer fawn. This is the first instance, in any animal, in which *D. congolensis* has been isolated from the kidney and liver and only the second in which actinomycete granules have been observed.

The frozen carcass of a severely emaciated white-tailed buck fawn was found in a field on a farm in the township of Salem, Washington County, New York in February 1981. A "mangy" appearing deer, believed to be the same animal, had been seen in the area for several months prior to the finding of the carcass. The unusual appearance of the animal prompted the farmer who found the deer to report the case to the local conservation officer.

Gross examination revealed an emaciated animal (gross weight of 23.6 kg) with hair loss over all parts of the body, but especially pronounced on both sides of the back, extending from the last four thoracic vertebrae to the sacrum. Yellow-white to cream-white encrustations covered the surface of the alopectic areas, the lateral and medial aspects of the hocks,

Received for publication 25 October 1982.



FIGURE 1. Ear of infected animal, with canal nearly obliterated by encrustations.

scapulae, snout, eyelids, periphery of the lips, and the outer and inner surfaces of the ears. The encrustations on the ears were so thick that the outer ear canal was nearly obstructed (Fig. 1).

Visceral organs appeared on gross examination to be normal, except for the liver, kidneys, and bladder. Possible necrotic lesions were noted on the surface of the liver, and small, raised lesions were observed on the inner surface of the bladder. The skeletal musculature appeared atrophic and the femur marrow was red and

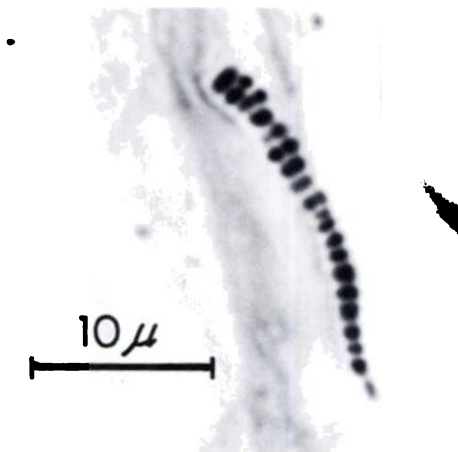

FIGURE 2. Skin section with multiseptate filament of *D. congolensis* (Giemsa stain).

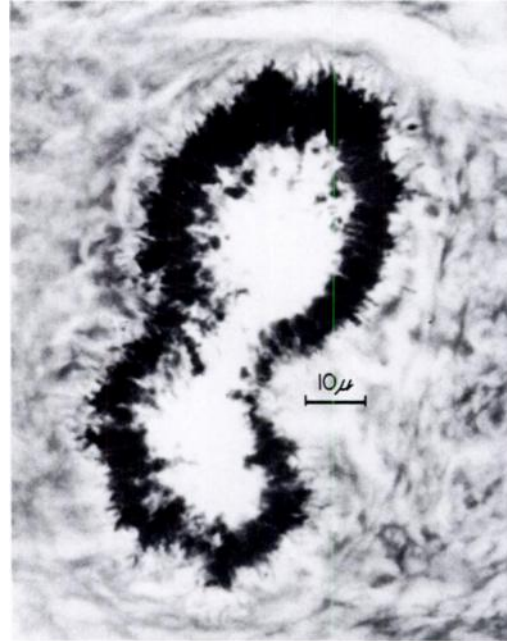


FIGURE 3. *Dermatophilus granule* in epidermal tissue at low magnification (Giemsa stain).

gelatinous. No grossly visible subcutaneous, mesenteric, or perirenal fat deposits were evident.

Encrustations from denuded areas on the back and the inner surface of the ear canal were rubbed on a microscope slide, and the adhering material was stained by the Giemsa method. Pieces of skin from the same sites and portions of the liver, kidney, and an inguinal lymph node were fixed in 10% formalin, embedded in paraffin, sectioned, and stained with hematoxylin and eosin, Giemsa, or methenamine-silver. Skin scrapings from various sites on the carcass were cleared with lactophenol to check for mites.

Encrustations from the back and outer surface of the ear and aseptically removed portions of the liver, kidney, and lymph node were rinsed in sterile water and rubbed over a small area on beef heart infusion-5.5% horse-blood agar plates. The inoculated area on each plate was then streaked for bacterial isolation and the plate incubated at 37 C. All possible precautions were taken to insure that the excised visceral organs were not contaminated through contact with the surface of the carcass.

Blood agar plates inoculated with encrusta-

tions and portions of skin from the back and ear and portions of the kidney and liver yielded colonies of *D. congolensis*. These were 1 mm in diameter, white to yellow, rough, round, raised and adherent to the surface.

Giemsa-stained smears from crusts on the back and the ear canal showed the typical filaments of *D. congolensis* (Fig. 2). Coccoid bodies as would be observed with the fragmentation of *Dermatophilus* filaments, were noted in sections of the lymph node. Methenamine silver and Giemsa-stained sections of the skin revealed several actinomycete "granules" in the epidermis and dermis (Fig. 3). The granules were composed of short, generally nonbranching, multiseptate filaments in a radiating configuration and surrounded primarily by degenerating neutrophils. Hematoxylin and eosin-stained sections showed extensive hyperkeratosis, with areas of parakeratosis and epithelial erosion. While the skin remained fairly well intact, the freezing of the carcass caused extensive autolysis which rendered the sections of the liver, kidney, and bladder microscopically uninterpretable.

While *D. congolensis* generally is associated with epidermitis, it has also been reported in subcutaneous infections. On one occasion it was isolated from a draining subcutaneous abscess near the popliteal lymph node of a cat (*Felis domesticus*) (Jones, 1976, J. Comp. Pathol. 86: 415-421). Dermatophilic granulomata of the glossal muscle, urinary bladder and tongue have also been described in that species (O'Hara and Cordes, 1963, N.Z. Vet. J. 11: 151-154; Baker et al., 1972, J. Small Anim. Pract. 13: 649-653). Subcutaneous abscesses due to *Dermatophilus*

were found in a bearded dragon lizard (*Amphibolurus barbatus*) (Simmons et al., 1972, Aust. Vet. J. 48: 465-466). As noted previously, subcutaneous and lymph node granulomas as well as granules were recently observed in a steer (Gibson et al., 1983, op. cit.).

Our present report of the isolation of the etiologic agent from the kidney and liver and the observation of coccoid bodies suggestive of *Dermatophilus* filaments in the lymph node, suggest a transient septicemia and possible systemic infection. The precautions used in excising the liver and kidney preclude, in our opinion, the contamination of these organs through contact with the surface of the carcass.

The *Dermatophilus* granules in the present case were found in the epidermis and dermis tissues whereas those formed by other actinomycetes are primarily seen in subcutaneous tissue. The granules noted in the white-tailed deer consisted simply of radiating, tightly packed, and evenly stained (Giemsa stain) *Dermatophilus* filaments while other actinomycotic granules are dense, round to irregular in shape and stain unevenly (hematoxylin and eosin) with a dark center and a light periphery.

The fawn may have acquired the infection through direct contact or by insect vectors. The lesions around the mouth and the spread of the infection to the hocks and feet may have limited the animal's ability to forage for food. This combined with the pressures of a harsh winter, the loss of hair, and loss of insulation, could have led directly to its debilitated condition. Its weakened state also may have contributed to a transient septicemia and dissemination of the etiologic agent to the kidney and liver.

Journal of Wildlife Diseases, 19(4), 1983, pp. 363-365
© Wildlife Disease Association 1983

Severe Ulcerative Dermatitis in Platypus (*Ornithorhynchus anatinus*)

B. L. Munday and B. F. Peel, Mt. Pleasant Laboratories, P.O. Box 46, Launceston South, Tasmania 7250, Australia

During the autumn of 1982, three moribund and one debilitated platypus were collected by a local resident on the banks of the Elizabeth River at Campbell Town, Tasmania. The de-

bilitated animal was returned to the river, and two of the moribund platypus, which died, were submitted for necropsy.

The collector noted that all the animals suffered from skin ulceration. The two animals examined at the laboratory were mature fe-

Received for publication 16 August 1982.