



First Record of Viral Erythrocytic Necrosis and Ceratomyxa Shasta Noble, 1950 (Myxozoa: Myxosporea) in Feral Pink Salmon (*Oncorhynchus gorbuscha* Walbaum)

Authors: Bell, Q. R., and Traxler, G. S.

Source: Journal of Wildlife Diseases, 21(2) : 169-171

Published By: Wildlife Disease Association

URL: <https://doi.org/10.7589/0090-3558-21.2.169>

BioOne Complete (complete.BioOne.org) is a full-text database of 200 subscribed and open-access titles in the biological, ecological, and environmental sciences published by nonprofit societies, associations, museums, institutions, and presses.

Your use of this PDF, the BioOne Complete website, and all posted and associated content indicates your acceptance of BioOne's Terms of Use, available at www.bioone.org/terms-of-use.

Usage of BioOne Complete content is strictly limited to personal, educational, and non - commercial use. Commercial inquiries or rights and permissions requests should be directed to the individual publisher as copyright holder.

BioOne sees sustainable scholarly publishing as an inherently collaborative enterprise connecting authors, nonprofit publishers, academic institutions, research libraries, and research funders in the common goal of maximizing access to critical research.

to isolate or transmit MCF in this case may suggest North American rather than African MCF etiology.

This deer was a free-ranging animal. No previous history of MCF on this premise or in this county could be found. Inspection of the premises and conversations with the ranchers did not reveal any contact with sheep or exotic ungulates. Until this report, MCF had not been described in free-ranging North American cervids or in black-tailed deer. The existence of

endemic North American MCF in black-tailed deer must be considered.

The author thanks R. J. Yetloutshnig (RJY) and the staff of Plum Island Animal Disease Center, Greenport, New York, and Dr. N. J. MacLachlan (NJM) and K. C. Else of the Veterinary Pathology Dept., University of California, Davis for pathologic and virologic assistance. The author was supported by Pittman-Robertson Project W-52-R, "A Wildlife Investigations Laboratory."

Journal of Wildlife Diseases, 21(2), 1985, pp. 169-171
© Wildlife Disease Association 1985

First Record of Viral Erythrocytic Necrosis and *Ceratomyxa shasta* Noble, 1950 (Myxozoa: Myxosporaea) in Feral Pink Salmon (*Oncorhynchus gorbuscha* Walbaum)

G. R. Bell and G. S. Traxler, Department of Fisheries and Oceans, Fisheries Research Branch, Pacific Biological Station, Nanaimo, British Columbia V9R 5K6, Canada

Adult, migrant pink salmon from the lower Fraser River, British Columbia, and five sites upstream were examined for certain disease agents, and for general signs of disease during autumn 1983. *Ceratomyxa shasta* Noble, 1950, was identified in these fish and evidence was obtained for the presumptive diagnosis of viral erythrocytic necrosis (VEN). These findings have not to our knowledge been reported previously in feral pink salmon, although Evelyn and Traxler (1978, J. Fish. Res. Board Can. 35: 903-907) found VEN in artificially reared pink salmon held in sea pens.

Viral erythrocytic necrosis is caused by one or more viruses tentatively assigned to the Iridoviridae and these are known to infect naturally or experimentally a diversity of species of marine and anadromous fish, and possibly certain terrestrial ectothermic vertebrates (Smail, 1982, Proc.

R. Soc. Edinb. Sect. B. (Biol.) 81: 169-176). The most obvious gross sign of disease is severe or chronic anemia. The appearance of 0.8-4.0 μm diameter amorphous, pink or magenta colored inclusion bodies (usually one per cell) in the cytoplasm of Giemsa-stained erythrocytes by light microscopy is considered pathognomonic (Evelyn and Traxler, 1978, op. cit.; MacMillan and Mulcahy, 1979, J. Fish. Res. Board Can. 36: 1097-1101). Affected salmon, that may have hematocrits of <5% instead of the usual ca. 40%, can succumb to environmental stressors such as low pO_2 , or to bacterial infections (Evelyn and Traxler, 1978, op. cit.; MacMillan et al., 1980, Can. J. Fish. Aquat. Sci. 37: 799-804).

Ceratomyxosis, the disease caused by *Ceratomyxa shasta*, is a severe illness affecting many species of cultured and wild salmonids in certain Pacific watersheds (Johnson et al., 1979, U.S. Dep. Inter. Fish. Wildl. Serv. Fish Dis. Leaflet No. 58, 11

Received for publication 12 March 1984.

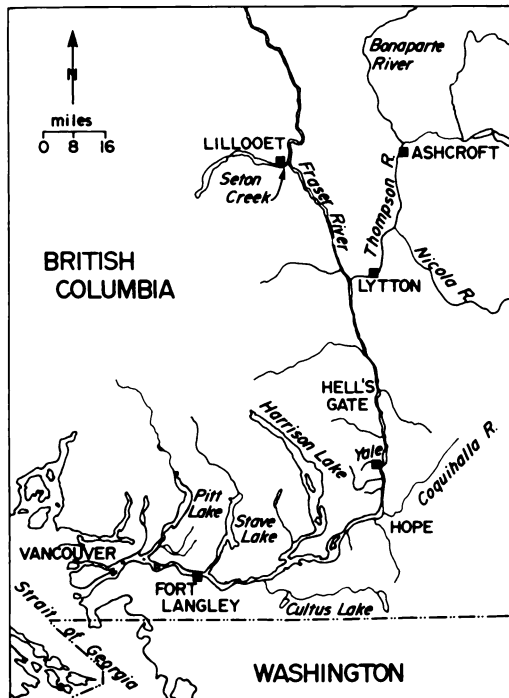


FIGURE 1. Sampling sites (■) on the Fraser and Thompson rivers. Lillooet and Seton Creek spawning channel are indicated as one site.

pp.). Of the Pacific salmon species, coho (*Oncorhynchus kisutch* Walbaum), chinook (*O. tshawytscha* Walbaum), chum (*O. keta* Walbaum), and sockeye (*O. nerka* Walbaum) are known to be susceptible to this disease. The prevalence of *C. shasta* among adult chinook, coho, steelhead (*Salmo gairdneri* Richardson), and cutthroat trout (*S. clarki* Richardson) at various sites on the Fraser River was reported recently by McDonald (1983, *Can. J. Zool.* 61: 1991-1994). No pink salmon were examined.

In the present work adult pink salmon migrants were collected at six locations on the Fraser River system (Fig. 1). To detect the presence of VEN, blood samples were taken from the caudal vessels, smeared on glass slides and stained with Diff-Quik (Dade Diagnostics, Inc., Aguada, Puerto Rico 00602). Erythrocytes were examined by light microscopy for the presence of

characteristic inclusion bodies, presumptive evidence of VEN. Virus was not confirmed by electron microscopy. To detect *C. shasta*, smears were made from scrapings of the lower intestine and stained with 1% aqueous methylene blue. At least 50 microscope fields of each smear were then examined at 400 \times magnification before designating the sample negative. *Ceratomyxa shasta* was confirmed on the basis of its principal morphological features as given by Johnson et al. (1979, op. cit.).

The prevalence of VEN and *C. shasta* in fish sampled at the various sites is given in Table 1. There was no clear trend in prevalence of VEN and interpretation of the results is speculative. If it is assumed that we were continually sampling a homogeneous population, fish appeared to acquire both diseases in the river. However, fish might have been infected subclinically (i.e., be carriers), or at low prevalence, before they entered the river. Subsequent manifestation of disease could then have been induced by the stress of migration coupled with the breakdown of host defence mechanisms associated with senescence. Again assuming a homogeneous population, variation in prevalence could result from increasing mortalities reflecting the time course of disease and/or the appearance of newly diseased fish. If, as is more likely, the populations were not homogeneous, variation in prevalence could reflect the progressive separation of stocks each having different susceptibilities to the disease agents. Such intraspecific differences in host susceptibility to ceratomyxosis have been demonstrated for chinook salmon and steelhead trout in the Columbia River where the disease is also enzootic (Zinn et al., 1977, *J. Fish. Res. Board Can.* 34: 933-936 and Buchanan et al., 1983, *Trans. Am. Fish. Soc.* 112: 541-543). Whatever the reason for the observed variations in prevalence, both ENV and *C. shasta* have the potential of causing serious losses of pink salmon in the Fraser River (MacMillan et al., 1980, op.

TABLE 1. Prevalence of viral erythrocytic necrosis and *Ceratomyxa shasta* in pink salmon collected at six sites in the Fraser River system in 1983.

Site and date collected	Water temperature (C)	Viral erythrocytic necrosis*		<i>Ceratomyxa shasta</i>	
		Prevalence (%)	Number of fish infected/number of fish examined	Prevalence (%)	Number of fish infected/number of fish examined
Fort Langley 22 Sept.	13.9	0	(0/30)	0	(0/30)
Yale 27 Sept.	13.0	13	(4/30)	0	(0/30)
Lytton 30 Sept.	12.8	40	(12/30)	0	(0/30)
Lillooet 4 Oct.	10.8	50	(15/30)	0	(0/30)
Ashcroft 5 Oct.	12.8	30	(9/30)	0	(0/30)
Seton spawning channel (Seton Creek) 14 Oct. (post-spawned)	10.8	23	(7/30)	20	(6/30)
Seton stamina tunnel ^b 14 Oct.	10.8	45	(17/38)		Not examined

* Presumptive diagnosis.

^b An additional group from the run, used for swimming stamina tests.

cit.; Rohovec and Amandi, 1981, Fish Pathol. 15: 135–141; Sanders et al., 1970, Am. Fish. Soc. Spec. Publ. No. 5, pp. 133–141).

Voucher specimens of *C. shasta*, and erythrocytes containing putative ENV inclusion bodies have been deposited in the National Museum of Natural Sciences of

Canada as NMPCPC1984-0808 and NMPCPC1984-0807, respectively.

We are very grateful for the able assistance of L. Croteau and D. Falls. We also thank Dr. L. Margolis for helpful criticism of the manuscript.

Journal of Wildlife Diseases, 21(2), 1985, pp. 171–173
© Wildlife Disease Association 1985

Cutaneous and Respiratory Tract Infection with *Mycobacterium ulcerans* in Two Koalas (*Phascolarctos cinereus*)

Steven McOrist, Ian V. Jerrett, Regional Veterinary Laboratory, Department of Agriculture, P.O. Box 483, Bairnsdale, Victoria 3875, Australia; and Mark Anderson and John Hayman, Gippsland Base Hospital, Sale, Victoria 3860, Australia

Cutaneous ulcers in man caused by *Mycobacterium ulcerans* occur in several specific localities around the world, including southeastern and northern Australia. These localities are usually centered on a river or estuarine system, and the causative organism is thought to reside in soil and water in these areas (Radford,

1975, Aust. N.Z. J. Med. 5: 162–169). The disease in humans is characterized by progressive ulceration and necrosis of the skin. Infection may occur in underlying muscle and bone, but has not been reported in the respiratory tract or other internal organs (Radford, 1975, op. cit.). In the first report of an animal other than man being infected naturally with *M. ulcerans*, Mitchell et al. (1984, Pathology 16: 256–260) described necrotizing ulceration of

Received for publication 5 July 1984.