

Diplostomiasis (Trematoda: Strigeidae) in Arctic Charr (*Salvelinus alpinus*) from Charr Lake, Northern Labrador

Authors: Bouillon, Daniel R., and Curtis, Mark A.

Source: Journal of Wildlife Diseases, 23(3) : 502-505

Published By: Wildlife Disease Association

URL: <https://doi.org/10.7589/0090-3558-23.3.502>

BioOne Complete (complete.BioOne.org) is a full-text database of 200 subscribed and open-access titles in the biological, ecological, and environmental sciences published by nonprofit societies, associations, museums, institutions, and presses.

Your use of this PDF, the BioOne Complete website, and all posted and associated content indicates your acceptance of BioOne's Terms of Use, available at www.bioone.org/terms-of-use.

Usage of BioOne Complete content is strictly limited to personal, educational, and non - commercial use. Commercial inquiries or rights and permissions requests should be directed to the individual publisher as copyright holder.

BioOne sees sustainable scholarly publishing as an inherently collaborative enterprise connecting authors, nonprofit publishers, academic institutions, research libraries, and research funders in the common goal of maximizing access to critical research.

Diplostomiasis (Trematoda: Strigeidae) in Arctic Charr (*Salvelinus alpinus*) from Charr Lake, Northern Labrador

Daniel R. Bouillon,¹ Institute of Oceanography, McGill University, Montréal, Québec, Canada H3A 2B2; and **Mark A. Curtis**, Institute of Parasitology, Macdonald College of McGill University, Ste-Anne-de-Bellevue, Québec, Canada H9X 1C0. ¹ Present address: Department of Biological Sciences, Simon Fraser University, Burnaby, British Columbia, Canada V5A 1S6

ABSTRACT: The eyes of 273 Arctic charr (*Salvelinus alpinus*) taken from Charr Lake, the Ikarut River, and Hebron Fiord in northern Labrador were examined for diplostomula. All anadromous charr taken from the Ikarut river and Hebron Fiord were uninfected. The resident fish from Charr Lake were parasitized with large numbers of diplostomula and intensity of infection increased with age and length. Infections of up to 2,852 diplostomula in one fish are the highest recorded. Such infections did not appear to affect the vision of the charr.

Key words: *Salvelinus alpinus*, Arctic charr, diplostomiasis, *Diplostomum* spp., parasite, eye, pathology, survey.

Metacercariae of the genus *Diplostomum* are parasites of the eyes of fish and are distributed widely throughout the northern hemisphere (Skrjabin, 1960; Hoffman, 1967). Impairment of vision or blindness has been observed (Betterton, 1974; Hendrickson, 1978) and in severe cases has resulted in starvation and death (Davies et al., 1973). Penetration by large numbers of cercariae in short periods of time has caused fish mortality and rendered surviving hosts more susceptible to predation (Brassard et al., 1982).

Diplostomum spathaceum is the species reported most commonly in Canada, occurring in the native salmonids *Salvelinus fontinalis*, *S. namaycush*, *S. alpinus* and *Salmo salar* (Margolis and Arthur, 1979). High intensity of infections by this parasite have been reported occasionally in fish farms or hatcheries (Hare and Frantsi, 1974; Shariff et al., 1980), especially for rainbow trout (*Salmo gairdneri*), whereas such infections in natural systems appear to be less common (Davies et al., 1973;

Wootten, 1974). *Diplostomum spathaceum* has been reported previously in Arctic charr from Canada in small numbers. Hicks (1971) found only two of 35 anadromous charr from Labrador to be infected and each fish harbored only two metacercariae.

Our general understanding of taxonomic relationships within the genus *Diplostomum* is extremely limited. *Diplostomum spathaceum* normally is considered to be a parasite of fish lenses, although Wootten (1974) found metacercariae of this species in the vitreous humor as well as in the lens of rainbow trout and brown trout (*Salmo trutta*). Brook trout (*Salvelinus fontinalis*) also are reported as having metacercariae of *D. spathaceum* in sites other than the lens (Davies et al., 1973; Hare and Frantsi, 1974; Hendrickson, 1978). Positive verification of metacercariae of *Diplostomum* spp. from fish eyes is only possible through experimental infections of final hosts.

Metazoan parasites obtained from charr stocks in northern Labrador showed that anadromous charr were entirely free of diplostomiasis whereas lake resident charr were infected commonly with large numbers of diplostomula, a feature not yet reported for other known Arctic charr populations. This paper presents a description of the pattern of *Diplostomum* spp. infection in the lake resident stock.

Arctic charr were sampled between 27 July and 29 August 1983, from sites in the Ikarut River, Hebron Fiord, and the recently named Charr Lake (58°11.5'N,

63°02.5'W; Newfoundland Geographical Names Board, St. John's, Newfoundland, Canada, 1984). Charr Lake is about 23 ha in area and harbors only Arctic charr and threespine stickleback (*Gasterosteus aculeatus*) which are landlocked by a series of waterfalls along the lake's outlet stream, draining into the Ikarut River. The river contains Arctic charr and brook trout, and empties into Hebron Fiord. Fish collections were made using a dip net, hand seine, fyke net, and gill nets of mesh sizes ranging from 19 to 114 mm. Fish were preserved in 4% buffered formalin and later transferred to 70% ethanol. Ages were determined using otoliths. Eyes were removed from the preserved fish and dissected to reveal the location and number of diplostomula present. Data were recorded separately for the left and right eyes of each sex. Histological examination was not carried out. Ecological terms (i.e., prevalence, intensity) are used as defined by Margolis et al., (1982). Representative samples of diplostomulae have been deposited with the National Museum of Natural Sciences, Invertebrate Collection, Ottawa, Canada, catalogue nos. NMCP 1986-0090 through NMCP 1986-0094.

None of the anadromous charr examined from the Ikarut River and Hebron Fiord was infected by metacercariae of *Diplostomum* spp. ($n = 110$, length range 2.6–65.5 cm, age 0–11+ yr). Diplostomula infected 95.1% of the charr taken from Charr Lake ($n = 163$, length range 3.1–61.0 cm, age 0–19+ yr). Prevalence values were 100% at all ages except 0+ and 1+ which were 69.9% and 94.4% respectively. The intensity of infection in individual fish ranged from one to 2,852 diplostomula (1,478 in one eye). An exponential increase in number of metacercariae occurred with age up to 8+ yr ($\log_{10}(\text{no. of diplostomum}) = 0.653 + 0.328(\text{age})$, $r = 0.875$) after which the increase was small and there appeared to be a leveling off of the curve (Fig. 1). A similar relationship was

seen with length instead of age since $\ln(\text{length})$ is highly correlated with age ($r = 0.902$). There was no significant difference ($P < 0.05$) between the number of metacercariae found in male and female charr at each age or between the number of metacercariae found in the left and right eyes of charr of the same age.

More than 99% of all metacercariae recovered from the eyes were located behind the retinal area in the epichorioidal lymph space, most often in close association with the ora serata, the wavy anterior end of the retina. Less than 1% of the metacercariae were found in the lens. The percentage of hosts with lens infections appeared to increase with age but the increase was only significant ($P < 0.05$) to 3+ yr. The highest infection in a single lens was four metacercariae and the highest combined lens infection in a single fish was also four. No cataracts or herniations that might affect the charr's vision were found in or on the infected lenses.

The primary difference between the infection of *Diplostomum* spp. in Arctic charr as reported here and other fish species, appears to be the positioning of the metacercariae in the epichorioidal lymph space behind the retina. Only Hendrickson (1978) provides evidence of a similar occurrence of *D. spathaceum* recovered from the choroids of brook trout and rainbow trout. Most often *Diplostomum* spp. are reported in locations within the eye that interfere with vision either by directly blocking light in the lens or vitreous humor or by disrupting the function of the retina. Davies et al. (1973) observed that for infected brown trout 28% of the metacercariae were found in the lens, 62% in the retinal tissue, 7% in the iris and 3% in the vitreous humor, while for rainbow trout 18% were in the lens, 80% in the retinal tissue and 1% each from the iris and vitreous humor. Lester and Huizinga (1977) found a new species of diplostomula (*D. adamsi*) occurring in clusters located

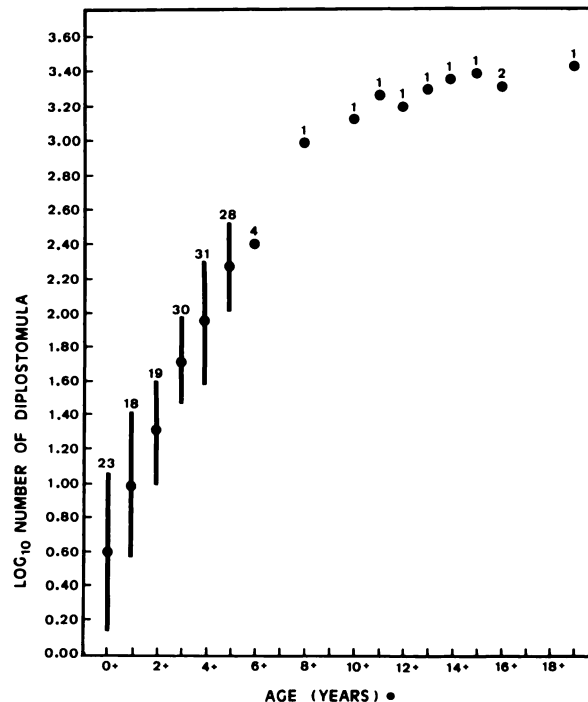


FIGURE 1. Plot of the geometric mean number of diplostomula versus age. Bars indicate one standard deviation from the mean. Values above each bar or point are sample sizes.

within the peripheral regions of the retina of perch (*Perca flavescens*). It remains possible that two species of *Diplostomum* may be present in the eyes of Arctic charr; one in the lens and another in the epichoroidal lymph space. A similar situation was reported by Dick and Rosen (1981) for lake whitefish (*Coregonus clupeaformis*) where *D. spathaceum indistinctum* inhabited the lens while *D. baeri bucculentum* occupied the vitreous humor and retina. Because only low intensities of diplostomula were found in the lens in the present study the possibility of aberrant migration must not be precluded.

The intensity of infection in some of the lake resident Arctic charr in Charr Lake is higher than previously reported for *Diplostomum* spp. in any fish species. Hendrickson (1978) considers that a continual buildup of metacercariae with increasing fish size is indicative of parasites which may live as long as their hosts. Another

plausible hypothesis is that intensity of infection is a function of the surface area of the fish.

In contrast to other locations within the eye, metacercariae in the epichoroidal lymph space do not interfere with light passing to the retina. As a result, the high infections reported here did not likely affect the vision of the fish in any direct manner. Whether their presence affects eye function in other ways is unknown, but it appears that charr under these conditions of diplostomiasis are able to tolerate higher intensities of infection than hosts in which the diplostomula occur in other locations within the eye.

We are grateful to the Department of Fisheries and Oceans, St. John's, Newfoundland for financial support, use of their field station in Hebron, Labrador and for providing laboratory space at the Northwest Atlantic Fisheries Centre, St. John's. Professor Max Dunbar and Monsieurs Brian

Dempson and Rex Porter are thanked for their assistance and advice.

LITERATURE CITED

- BETTERTON, C. 1974. Studies on the host specificity of the eyefluke, (*Diplostomum spathaceum*), in brown and rainbow trout. *Parasitology* 69: 11–29.
- BRASSARD, P., M. E. RAU, AND M. A. CURTIS. 1982. Infection dynamics of *Diplostomum spathaceum* cercariae and parasite-induced mortality of fish hosts. *Parasitology* 85: 489–493.
- DAVIES, R. B., W. T. BURKHARD, AND C. P. HIBLER. 1973. Diplostomosis in North Park, Colorado. *Journal of Wildlife Diseases* 9: 362–367.
- DICK, T. A., AND R. ROSEN. 1981. Identification of *Diplostomum* spp. from the eyes of lake whitefish, *Coregonus clupeaformis* (Mitchill), based on experimental infection of herring gull chicks, *Larus argentatus* Pontoppidan. *Canadian Journal of Zoology* 59: 1176–1179.
- HARE, G. M., AND C. FRANTSI. 1974. Abundance and potential pathology of parasites infecting Salmonids in Canadian maritime hatcheries. *Journal of the Fisheries Research Board, Canada* 31: 1031–1036.
- HENDRICKSON, G. L. 1978. Observations on strigeoid trematodes from the eyes of southeastern Wyoming fish. I. *Diplostomum spathaceum* (Rudolphi, 1819). *Proceedings of the Helminthological Society of Washington* 45: 59–64.
- HICKS, F. J. 1971. Metazoan parasites of Salmonids and Coregonids from coastal Labrador. M.Sc. Thesis. Memorial University of Newfoundland, St. John's, Newfoundland, Canada, 96 pp.
- HOFFMAN, G. L. 1967. Parasites of North American freshwater fishes. University of California Press, Los Angeles, California, 486 pp.
- LESTER, R. J. G., AND W. HUIZINGA. 1977. *Diplostomum adamsi* sp. n.: Description, life cycle, and pathogenesis in the retina of *Perca flavescens*. *Canadian Journal of Zoology* 55: 64–73.
- MARGOLIS, L., AND J. R. ARTHUR. 1979. Synopsis of the parasites of fishes of Canada. *Bulletin of the Fisheries Research Board, Canada* 199: 1–269.
- , G. E. ESCH, J. C. HOLMES, A. M. KURIS, AND G. A. SCHAD. 1982. The use of ecological terms in parasitology (report of an ad hoc committee of the American Society of Parasitologists). *Journal of Parasitology* 68: 131–133.
- SHARIFF, M., R. H. RICHARDS, AND C. SOMMERVILLE. 1980. The histopathology of acute and chronic infections of rainbow trout *Salmo gairdneri* Richardson with eye flukes, *Diplostomum* spp. *Journal of Fish Diseases* 3: 455–465.
- SKRJABIN, K. I. 1960. [Trematodes of animals and man.] *Essentials of trematodology*, Vol. XVII. Acad. Sci. USSR, Moscow, USSR, 640 pp. [In Russian, English translation by Israel Program for Scientific Translations, Jerusalem, 1964.]
- WOOTTEN, R. 1974. Observations on strigeid metacercariae in the eyes of fish from Hanningfield Reservoir, Essex, England. *Journal of Helminthology* 48: 73–83.

Received for publication 14 February 1985.