



## **Mesocestoides sp. Tetrathyridia (Cestoidea: Cyclophyllidea) in the Iguanid Lizards, *Cophosaurus texanus texanus* and *Sceloporus olivaceous*, from Texas**

Author: McAllister, Chris T.

Source: Journal of Wildlife Diseases, 24(1) : 160-163

Published By: Wildlife Disease Association

URL: <https://doi.org/10.7589/0090-3558-24.1.160>

---

BioOne Complete ([complete.BioOne.org](https://complete.BioOne.org)) is a full-text database of 200 subscribed and open-access titles in the biological, ecological, and environmental sciences published by nonprofit societies, associations, museums, institutions, and presses.

Your use of this PDF, the BioOne Complete website, and all posted and associated content indicates your acceptance of BioOne's Terms of Use, available at [www.bioone.org/terms-of-use](https://www.bioone.org/terms-of-use).

Usage of BioOne Complete content is strictly limited to personal, educational, and non - commercial use. Commercial inquiries or rights and permissions requests should be directed to the individual publisher as copyright holder.

---

BioOne sees sustainable scholarly publishing as an inherently collaborative enterprise connecting authors, nonprofit publishers, academic institutions, research libraries, and research funders in the common goal of maximizing access to critical research.

## ***Mesocestoides* sp. Tetrathyridia (Cestoidea: Cyclophyllidea) in the Iguanid Lizards, *Cophosaurus texanus texanus* and *Sceloporus olivaceus*, from Texas**

**Chris T. McAllister**, Renal-Metabolic Lab, Veterans Administration Medical Center, 4500 S. Lancaster Road, Dallas, Texas 75216, USA and Department of Biological Sciences, North Texas State University, Denton, Texas 76203, USA

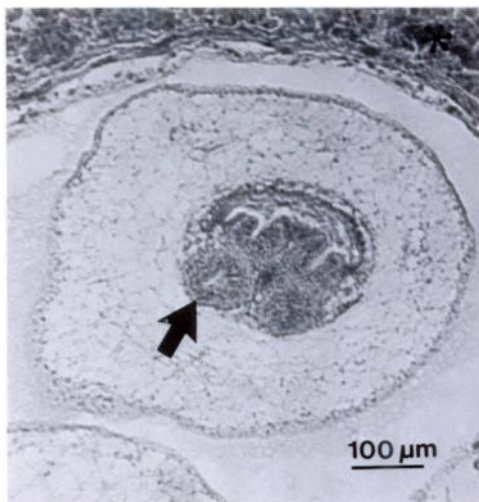
**ABSTRACT:** New host records are reported for *Mesocestoides* sp. tetrathyridia in two species of iguanid lizards (*Cophosaurus texanus* and *Sceloporus olivaceus*) from Texas. Tetrathyridia were found free within the body cavity or encapsulated in the liver of the hosts. Prevalence of infection was generally low, with intensities ranging from 90 to over 200 tetrathyridia per host. In addition, a summary of North American lizard species reported as hosts of *Mesocestoides* sp. tetrathyridia is presented.

**Key words:** Cestoidea, *Cophosaurus texanus*, Cyclophyllidea, encapsulated, lizards, *Mesocestoides* sp., parenchyma, *Sceloporus olivaceus*, tetrathyridia.

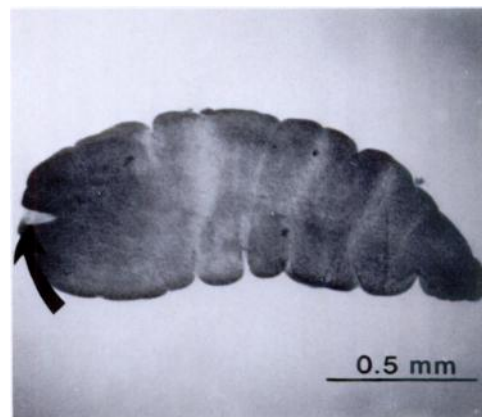
The metacestode stage (tetrathyridium) of the cyclophyllidean cestode, *Mesocestoides* sp., is often found in the coelomic cavity, liver, cardiac musculature, and mesenteries of vertebrate intermediate hosts (usually anuran amphibians and squamate reptiles) and reaches sexual maturity if ingested by definitive hosts such

as carnivorous birds or mammals (Williams and Conn, 1985). Presumably, the first intermediate host in the life cycle is an arthropod (probably an insect); however, this is not proven (Webster, 1949; James, 1969). Vertebrate hosts which harbor tetrathyridia cannot be infected directly with oncospheres of *Mesocestoides* sp. Specht and Voge (1965) and Hanson and Widmer (1985) demonstrated asexual multiplication of tetrathyridia in laboratory mice and prairie rattlesnakes (*Crotalus viridis*), respectively.

Mankau and Widmer (1977) suggested that data on the range, distribution, food habits and natural history of the second intermediate host may provide important information which could lead to better understanding the life cycle of this enigmatic tapeworm. The purposes of this note are to report, for the first time, the occurrence of *Mesocestoides* sp. tetrathyridia in the Texas earless lizard (*Cophosaurus texanus*



**FIGURE 1.** Encapsulated *Mesocestoides* sp. tetrathyridia in the liver of *Cophosaurus t. texanus*. Note sucker (arrow) and normal liver parenchyma (\*). H&E.



**FIGURE 2.** *Mesocestoides* sp. tetrathyridia removed from the body cavity of *Sceloporus olivaceus*. Note appearance of the invaginated holdfast (arrow).

TABLE 1. Lacertilid reptiles reported as hosts of *Mesocestoides* sp. tetrathyridia.

Lizard species	Locality	Reference
<b>Gekkonidae</b>		
<i>Coleonyx variegatus</i>	California	Mankau and Widmer, 1977
<b>Xantusiidae</b>		
<i>Xantusia riversiana</i>	California	Telford, 1970; Goldberg, 1985
<b>Iguanidae</b>		
<i>Anolis carolinensis</i>	Louisiana	Conn and Etges, 1984
<i>Callisaurus draconoides</i>	California	Mankau and Widmer, 1977
<i>Cophosaurus texanus</i>	Texas	McAllister, this report
<i>Crotaphytus collaris</i>	Arkansas; New Mexico	McAllister, 1985; Pfaffenberger et al., 1986
<i>Dipsosaurus dorsalis</i>	California	Mankau and Widmer, 1977
<i>Phrynosoma mcallii</i>	California	Mankau and Widmer, 1977
<i>P. platyrhinos</i> *	California; Nevada	Mankau and Widmer, 1977; Babero and Kay, 1967
<i>Sceloporus graciosus</i>	California	Telford, 1970
<i>S. magister</i>	Arizona	Benes, 1985
<i>S. occidentalis</i>	California	Voge, 1953; Specht and Voge, 1965
<i>S. olivaceus</i>	Texas	McAllister, this report
<i>Uma notata</i>	California	Telford, 1970
<i>Urosaurus graciosus</i>	California	Telford, 1970
<i>U. ornatus</i> *	Arizona	Benes, 1985
<i>Uta stansburiana</i> *	California; Arizona	Telford, 1970; Benes, 1985
<b>Teiidae</b>		
<i>Cnemidophorus tigris</i>	California	Mankau and Widmer, 1977
<i>C. t. septentrionalis</i> *	Arizona	Babero and Matthias, 1967; Benes, 1985
<i>C. sexlineatus</i>	South Dakota	Dyer, 1971
<b>Scincidae</b>		
<i>Eumeces fasciatus</i> *	Texas; California	Harwood, 1932; Voge, 1953
<i>E. skiltonianus</i>	California	Telford, 1970
<i>Scincella lateralis</i> *	Texas	Harwood, 1932
<b>Anguidae</b>		
<i>Elgaria coerulea</i>	California	Voge, 1953
<i>E. multicarinata</i>	California	Telford, 1970

\* Possibly *Mesocestoides* sp.

*texanus*) and Texas spiny lizard (*Sceloporus olivaceus*), and to provide a summary of North American lizards known to be hosts of this cestode.

Lizards were captured alive by stunning with rubber bands and euthanized by overdose with sodium pentobarbital (Nembutal®, Abbott Laboratories, North Chicago, Illinois 60064, USA). Tetrathyridia were recovered from the body cavity of two hosts and placed in warm alcohol-formalin-acetic acid mixture, transferred to 70% ethanol, stained with Semichon's acetocarmine or Mayer's hematoxylin, de-

hydrated in a graded series of alcohols, cleared in xylene and mounted in Permount® mounting medium (Fisher Scientific, Pittsburgh, Pennsylvania 15219, USA). Tissues containing encapsulated tetrathyridia were fixed in 10% formalin, embedded in paraffin, sectioned at 8 µm and stained with Mayer's hematoxylin and eosin counterstain.

One of 21 (5%) *C. texanus texanus* (adult female, snout-vent length (SVL) = 60 mm) collected on 4 May 1986 in Johnson County, Texas (32°15'N, 97°35'W) was infected with a total of 90 *Mesocestoides* sp. tetra-

thyridia in its body cavity. In addition, the liver contained numerous encapsulated tetrathyridia, which resulted in minimal compression of the parenchyma, with no fibrosis or necrosis (Fig. 1). Total length of the worms ranged from 1.5 to 2.1 mm ( $\bar{x} \pm SE = 1.78 \pm 0.12$ ) and greatest width from 0.55 to 0.65 mm ( $0.62 \pm 0.02$ ).

The other case involved one of seven (14%) *S. olivaceous* (adult male, 81 mm SVL) collected on 22 June 1986, also in Johnson County. This lizard contained over 200 *Mesocestoides* sp. tetrathyridia free within the coelomic cavity (Fig. 2). The liver did not contain any encapsulated forms. Tetrathyridia from this host were slightly smaller, ranging from 1.0 to 1.8 mm ( $1.35 \pm 0.08$ ) by 0.45 to 0.55 mm ( $0.52 \pm 0.01$ ).

Twenty-four species of North American lizards of the families Gekkonidae, Xantusiidae, Iguanidae, Teiidae, Scincidae and Anguidae are reported as hosts of *Mesocestoides* sp. tetrathyridia (Table 1). Iguanids appear to be common second intermediate hosts, which suggests similarities in ecology and especially food habits. Except for the primarily herbivorous desert iguana (*Dipsosaurus dorsalis*), most of these lizards are opportunistic feeders which ingest various arthropods. In surveys which reported *Mesocestoides* sp. tetrathyridia from generous samples of lizards, prevalence usually ranged below 10%. Therefore, it appears that many factors are important in the transmission of *Mesocestoides* from the first to the second intermediate host. Further investigation will be necessary to provide specific answers to many of the unsolved problems concerned with the life cycle of *Mesocestoides*.

Lizard voucher specimens are deposited in the Arkansas State University Museum of Zoology (ASUMZ 5959, 6007). Representative specimens of tetrathyridia are deposited in the USNM Helminthological Collection (United States Department of Agriculture, Beltsville, Maryland 20705, USA; Accession Nos. 79662-79663).

#### LITERATURE CITED

- BABERO, B. B., AND F. R. KAY. 1967. Parasites of horned toads (*Phrynosoma* spp.), with records from Nevada. *The Journal of Parasitology* 53: 168-175.
- , AND D. MATTHIAS. 1967. *Thubunaea cnemidophorus* n. sp., and other helminths from lizards, *Cnemidophorus tigris* in Nevada and Arizona. *Transactions of the American Microscopical Society* 86: 173-177.
- BENES, E. S. 1985. Helminth parasitism in some central Arizona lizards. *Southwestern Naturalist* 30: 467-473.
- CONN, D. B., AND F. J. ETGES. 1984. Helminth parasites of *Anolis carolinensis* (Reptilia: Lacertilia) from southeastern Louisiana. *Proceedings of the Helminthological Society of Washington* 51: 367-369.
- DYER, W. G. 1971. Some helminths of the six-lined lizard, *Cnemidophorus sexlineatus*, in South Dakota. *Proceedings of the Helminthological Society of Washington* 38: 256.
- GOLDBERG, S. R. 1985. Larval cestodes (*Mesocestoides* sp.) in the liver of the island night lizard, *Xantusia riversiana*. *Journal of Wildlife Diseases* 21: 310-312.
- HANSON, G. B., AND E. A. WIDMER. 1985. Asexual multiplication of *Mesocestoides corti* in *Crotalus viridis viridis*. *Journal of Wildlife Diseases* 21: 20-24.
- HARWOOD, P. D. 1932. The helminths parasitic in the Amphibia and Reptilia of Houston, Texas and vicinity. *Proceedings of the United States National Museum* 81: 1-67.
- JAMES, H. A. 1969. Studies on the genus *Mesocestoides* (Cestoda: Cyclophyllidae). *Dissertation Abstracts B, Science and Engineering* 29: 3541.
- MANKAU, S. K., AND E. A. WIDMER. 1977. Prevalence of *Mesocestoides* (Eucestoda: Mesocestoididae) tetrathyridia in southern California reptiles with notes on the pathology in the Crotalidae. *Japanese Journal of Parasitology* 26: 256-259.
- MCALLISTER, C. T. 1985. Endoparasites of *Crotaphytus collaris collaris* (Sauria: Iguanidae) from Arkansas. *Southwestern Naturalist* 30: 363-370.
- PFÄFFENBERGER, G. S., T. L. BEST, AND D. DE BRUIN. 1986. Helminths of collared lizards (*Crotaphytus collaris*) from the Pedro Armendariz Lava Field, New Mexico. *The Journal of Parasitology* 72: 803-806.
- SPECHT, D., AND M. VOGEL. 1965. Asexual multiplication of *Mesocestoides* tetrathyridia in laboratory animals. *The Journal of Parasitology* 51: 268-272.
- TELFORD, S. R., JR. 1970. A comparative study of endoparasitism among some California lizard populations. *American Midland Naturalist* 83: 516-554.

- VOGE, M. 1953. New host records for *Mesocestoides* (Cestoda: Cyclophyllidea) in California. *American Midland Naturalist* 49: 249-251.
- WEBSTER, J. P. 1949. Fragmentary studies on the life cycle of the cestode *Mesocestoides latus*. *The Journal of Parasitology* 35: 83-90.
- WILLIAMS, C. A., AND D. B. CONN. 1985. Localization and associated histopathology of asexually proliferative *Mesocestoides corti* tetrathyridia (Cestoda) infecting mouse mammary glands. *International Journal for Parasitology* 15: 245-248.

*Received for publication 16 April 1987.*