

MYCOBACTERIOSIS IN YELLOW PERCH (PERCA FLAVESCENS) FROM TWO LAKES IN ALBERTA

Authors: Daoust, P.-Y., Larson, B. E., and Johnson, G. R.

Source: Journal of Wildlife Diseases, 25(1) : 31-37

Published By: Wildlife Disease Association

URL: <https://doi.org/10.7589/0090-3558-25.1.31>

BioOne Complete (complete.BioOne.org) is a full-text database of 200 subscribed and open-access titles in the biological, ecological, and environmental sciences published by nonprofit societies, associations, museums, institutions, and presses.

Your use of this PDF, the BioOne Complete website, and all posted and associated content indicates your acceptance of BioOne's Terms of Use, available at www.bioone.org/terms-of-use.

Usage of BioOne Complete content is strictly limited to personal, educational, and non - commercial use. Commercial inquiries or rights and permissions requests should be directed to the individual publisher as copyright holder.

BioOne sees sustainable scholarly publishing as an inherently collaborative enterprise connecting authors, nonprofit publishers, academic institutions, research libraries, and research funders in the common goal of maximizing access to critical research.

MYCOBACTERIOSIS IN YELLOW PERCH (*PERCA FLAVESCENS*) FROM TWO LAKES IN ALBERTA

P.-Y. Daoust,^{1,3} B. E. Larson,² and G. R. Johnson^{1,3}

¹ Pathology Branch, Animal Health Division, Alberta Agriculture, P.O. Box 8070, Edmonton, Alberta, Canada T6H 4P2

² Fish Disease Laboratory, Fish & Wildlife Division, Alberta Energy and Natural Resources, P.O. Box 8070, Edmonton, Alberta, Canada T6H 4P2

³ Present address: Department of Pathology and Microbiology, Atlantic Veterinary College, University of Prince Edward Island, Charlottetown, Prince Edward Island, Canada C1A 4P3

ABSTRACT: Granulomatous skin lesions were identified in a population of yellow perch (*Perca flavescens*) from Sandy Lake (Alberta, Canada) in 1985. Severe granulomatous peritonitis and hepatitis was identified subsequently in a separate population of yellow perch from Wolf Lake (Alberta, Canada). *Mycobacterium chelonae* was isolated from affected fish in both epizootics. The source and route of infection were not determined in either case. The nature of the inflammatory reaction in both cases suggested a depressed immunity.

Key words: *Mycobacterium chelonae*, mycobacteriosis, yellow perch, *Perca flavescens*, skin lesions, peritonitis, case report.

INTRODUCTION

Systemic mycobacteriosis is commonly diagnosed in aquarium fish and occasionally results in skin lesions. Also, it was a serious problem in the 1950's in hatchery-raised salmon and trout in Oregon (USA); the cause was traced to the practice of feeding to young fish untreated carcasses and viscera of affected fish (Wood and Ordal, 1958; Ross, 1970). Reports of infection by *Mycobacterium* sp. in natural populations of wild fish are less common (Abernethy and Lund, 1978; Sakanari et al., 1983; Peterson, 1986; MacKenzie, 1988). Infections of feral crustaceans by acid-fast bacteria were recently described (Alderman et al., 1986; Lightner and Redman, 1986). Herein, we describe mycobacterial infections, different in their manifestations, in two separate populations of yellow perch (*Perca flavescens*) from Alberta (Canada).

MATERIALS AND METHODS

Case histories

The first epizootic occurred January through March 1985 in Sandy Lake, a small shallow lake (972 ha; maximum depth of 4.6 m) located about 40 km northwest of Edmonton, Alberta, Canada (53°47'N, 114°02'W). The water temperature and dissolved oxygen, measured in February 1985 at 2 m below the surface, were 2.75 C and 3.2 mg/liter (maximum), respectively. In January

1985, an angler submitted a few fish with skin lesions to the Veterinary Laboratory (Alberta Agriculture, Edmonton, Alberta, Canada T6H 4P2) for postmortem examination. Further specimens were obtained from anglers again in February and March 1985. The prevalence of skin lesions in the population, as estimated by anglers, varied from about 25% in January to about 5% in February and March. The progression of the disease in the population was not determined by further collections, and no further submissions were received from anglers. A total of nine fish were examined in the laboratory. The fork length of these fish varied from 18 to 22 cm.

The second epizootic occurred in the summer 1986 in Wolf Lake, another small shallow lake (220 ha; maximum depth of 5.5 m) located about 170 km southwest of Edmonton, Alberta, Canada (53°20'N, 116°05'W). The temperature and dissolved oxygen, measured in shallow water in early July, were 18 C and 8.0 mg/liter, respectively. Following reports by anglers of several dead perch in this lake in the previous 3 wk, provincial fish biologists conducted a field investigation in July. Approximately 100 dead perch were seen at the site of investigation. Numerous live perch also were observed, although several of these appeared sluggish. Thirty-seven perch were collected by gill net from Wolf Lake and submitted to the Veterinary Laboratory in Edmonton. The fork length of these fish varied from 10 to 14.5 cm.

Laboratory examination

Tissues were fixed in 10% buffered formalin, processed routinely for histology, and stained with hematoxylin and eosin and with regular

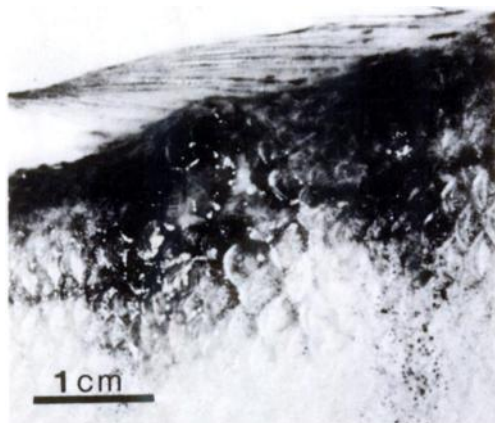


FIGURE 1. Skin granuloma below the dorsal fin of a yellow perch from which *Mycobacterium chelonae* was isolated. The epidermis is partly ulcerated. The edges of the lesion are raised because of an accumulation of exudate.

(Ziehl-Neelsen method) and modified (Fite's method) acid-fast stains (Luna, 1968). Tissues were cultured on trypticase soy agar (Difco, BDH Chemicals, Edmonton, Alberta, Canada T6B 2L8), blood agar (5% sheep blood in trypticase soy agar) and Ordal's medium (Anacker and Ordal, 1959), and incubated at room temperature (22 to 25 C).

RESULTS

Gross lesions in all fish from Sandy Lake consisted of one or a few areas of hemorrhage in the dermis usually associated with ulceration of the epidermis and loss of scales (Fig. 1). Microscopically, these lesions consisted of an almost pure population of macrophages, with occasional small groups of lymphocytes, within the dermis (Figs. 2, 3). In all lesions, a regular acid-fast stain revealed many faintly staining coccoid structures within macrophages. By comparison, a modified acid-fast stain, the Fite's method, showed large numbers of densely staining long beaded bacilli (Fig. 4). The use of peanut oil and elimination of alcohol from the hydration and dehydration processes in this method reduce the risk of extraction of bacterial capsular lipids during the staining procedure (Luna, 1968). Following culture of the skin lesions on artificial media numerous pin-point colonies became visible within 5 days; after 12 days growth was heavy and pure, even from open lesions. The cultured bacterium was identified independently by the Marine Science Center of




FIGURE 2. Accumulation of cellular exudate within the dermis of a yellow perch. The arrows indicate the margins of this exudate. One of the scales (S) is embedded within the exudate. Only part of the epidermis (E) overlying the lesion is intact. H&E.

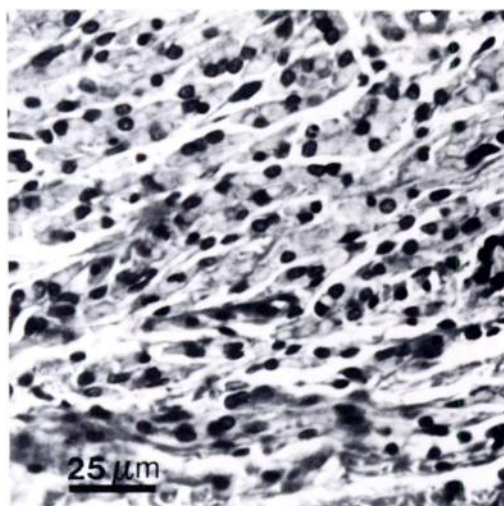


FIGURE 3. Higher magnification of Figure 2 showing an accumulation of macrophages in the dermis. Dermal collagen is in the lower part of the figure. H&E.

Oregon State University (Newport, Oregon 97365, USA) and by the Provincial Laboratory of Public Health (University of Alberta, Edmonton, Alberta, Canada T6G 2J2) as *Mycobacterium chelonae*; formerly *M. chelonae* (Hill et al., 1984) (Table 1). *Mycobacterium chelonae* was isolated consistently from skin lesions of all nine fish examined but from the spleen and/or kidney of only three of these fish. Of these three fish, lesions were present in the spleen of only one fish and consisted of multiple aggregates of macrophages filled with acid-fast bacteria.

Gross lesions were found in 14 of the 37 fish from Wolf Lake. These lesions consisted of moderate to severe diffuse granulomatous peritonitis and hepatitis (Fig. 5). Skin lesions were not evident, except in one fish in which two white nodules associated with loss of the epidermis were within the ventral region of the body wall and were continuous with the exudate in the body cavity. Microscopically, the exudate in all fish consisted of an abundance of macrophages, a lesser number of lymphocytes that occasionally formed small aggregates, and in a few cases, thin strands of fibrocytes. Irregular areas of necrosis




FIGURE 4. Several clusters of beaded acid-fast bacilli. These clusters are located within macrophages, although the margins of the cells are indistinct. Modified acid-fast stain (Fite's method).

were common within the exudate. Multifocal areas of granulomatous inflammation were seen also in some fish in the kidney, spleen, gills and wall of the digestive tract. A modified acid-fast stain revealed numerous acid-fast bacilli within a large proportion of the macrophages; these bacteria did not have the beaded appearance of those seen in fish from Sandy Lake. By comparison, a regular acid-fast stain revealed only a few macrophages containing similar bacteria. The body cavities of eight

TABLE 1. Main biochemical tests used in the identification of *Mycobacterium chelonae* isolated from yellow perch. All tests were performed at 25 C.

	Sandy Lake ^a	Wolf Lake ^b
Pigmentation in dark	—	—
Pigmentation under light	—	—
Nitrate reduction	—	—
Niacin production	—	—
Iron uptake	—	—
Urease	+	+
Pyrazinamidase	+	+
Arylsulfatase (after 14 days)	+	+
Susceptibility to isoniazid	HR ^c	HR

^a Two isolates tested.

^b Four isolates tested.

^c Highly resistant.

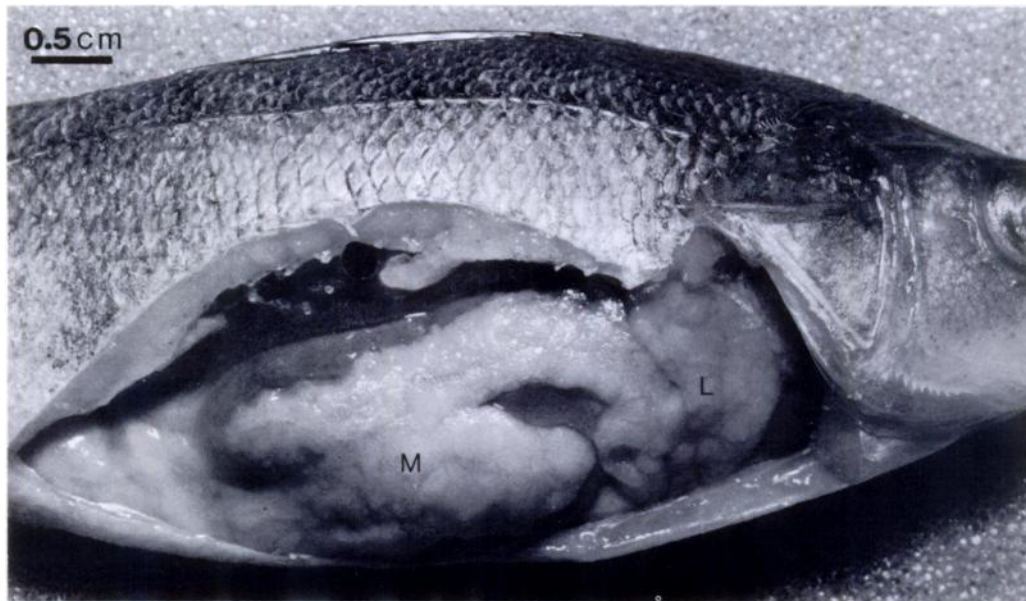


FIGURE 5. Severe diffuse granulomatous peritonitis and hepatitis caused by *Mycobacterium chelonae* in a yellow perch. The mesentery (M) is greatly distended and the liver (L) diffusely infiltrated by the exudate.

affected fish and of six fish showing no gross lesions were cultured. *Mycobacterium* sp. was isolated in pure culture from all these fish. This bacterium was identified as *M. chelonae* by the Provincial Laboratory of Public Health at Edmonton (Table 1).

The ability of both isolates of *M. chelonae* to grow at various temperatures was studied. Temperatures tested were 4 C, 15 C, room temperature, 28 C and 35 C. Both isolates grew best at 28 C (heavy growth after 7 days). Their growth was inhibited at 4 C and 35 C. The organisms remained viable at 4 C for at least 5 wk (maximum time tested) and resumed growth following transfer to room temperature. At 35 C, they remained viable for 18 days but not for 28 days, the next time period tested.

DISCUSSION

Infections by *Mycobacterium* sp. in populations of wild fish have been reported infrequently. Abernethy and Lund (1978) described lesions of systemic mycobacteriosis in mountain whitefish (*Prosopium williamsoni*) taken from the Yakima River (Washington, USA). The disease

affected about 8% of the population sampled. Signs of disease were not observed in these fish at the time of collection, but mortalities occurred several weeks later in fish that had been kept in holding tanks. The kidney and liver were the organs most commonly affected grossly; skin lesions were not described. Microscopically, lesions consisted of multifocal accumulations of macrophages and a small to moderate number of lymphocytes; large numbers of acid-fast bacilli were within macrophages (Lund and Abernethy, 1978). The *Mycobacterium* sp. tentatively was ascribed to Runyon's group III. Mountain whitefish showing similar gross and microscopic lesions of systemic mycobacteriosis were collected from the Missouri River (Montana, USA) in 1982, 1983 and 1985 (C. E. Smith, pers. comm.; Peterson, 1986). Thirty-six to 49% of the fish in this population had lesions. The bacterium was isolated after passage of infected tissues in steelhead trout (*Salmo gairdneri*) and was identified as *M. chelonae* (Arakawa and Fryer, 1984; Arakawa et al., 1986). Lesions caused by an unidentified *Mycobacterium* sp. were reported in wild populations of

striped bass (*Morone saxatilis*) from the Pacific Coast (USA) (Sakanari et al., 1983). Microscopically, these lesions consisted of tubercles composed of necrotic centers often filled with acid-fast bacilli and surrounded by layers of collagen and epithelioid cells. Lesions were most prevalent in the liver but also occurred in the kidney and spleen.

Mycobacterium chelonae belongs, together with *M. fortuitum*, to Runyon's group IV of atypical mycobacteria which is a group of fast-growing bacteria (Binford and Connor, 1976). Atypical mycobacteria include numerous species that normally exist as environmental saprophytes but that sporadically can cause disease in humans and other mammals (Ward, 1975). *Mycobacterium chelonae* is widely distributed in soil and water. In humans, it has been isolated from cutaneous abscesses and granulomatous lesions following injection, trauma or surgery and occasionally from disseminated granulomatous lesions in immunosuppressed individuals (Ward, 1975; Wolinsky, 1979). It also was responsible for a systemic infection characterized by multiple cutaneous and pulmonary abscesses in a captive natterer manatee (*Trichechus inunguis*) (Boever et al., 1976).

The source and route of infection were not determined in either of the two epizootics described herein. In particular, it is not clear whether skin lesions in fish from Sandy Lake resulted from a primary infection of the skin or from a systemic infection. In mammals, the nature of the inflammatory reaction associated with infection by *Mycobacterium* spp. is greatly influenced by the degree of cell-mediated immunity. This is most evident in the tuberculoid and lepromatous forms of human and feline leprosy (von Lichtenberg, 1984; Yager and Scott, 1985). Tuberculoid leprosy, which is associated with a strong T cell-mediated immunity, is characterized by the formation of discrete granulomas that are composed of numerous macrophages and an equally large number

of lymphocytes; few surviving acid-fast bacteria can be seen, and the granulomas may contain central areas of caseous necrosis. In contrast, lepromatous leprosy is associated with a profound depression of T cell-mediated immunity which, at least in humans, is selective for the lepra bacilli. This form of leprosy is characterized by a diffuse granulomatous inflammatory reaction in which macrophages predominate, with relatively few lymphocytes; massive numbers of acid-fast bacteria can be seen within macrophages. In both epizootics reported in our study, the pattern of microscopic lesions resembled that of lepromatous leprosy. It was similar to that seen in whitefish collected in Washington (Lund and Abernethy, 1978) and Montana (C. E. Smith, pers. comm.) but different from that in striped bass collected from the Pacific coast (Sakanari et al., 1983), in which lesions were in the form of tubercles. Tubercle formation also is a common finding in aquarium fish with mycobacteriosis (Richards and Roberts, 1978).

As with endotherms, environmental stress can cause immunosuppression in fish (Wedemeyer, 1970; Roberts, 1978), thus predisposing them to infectious diseases. However, no obvious stressful environmental factor was identified in either epizootic. As is the case with infectious diseases in any ectotherm, ambient temperature probably influenced the response of these fish to bacterial invasion. Humoral and cell-mediated immune responses in fish are depressed at low temperatures (Corbel, 1975), although the critical temperature below which the immune response fails to develop varies among species and is proportional to the temperature range of their natural environment (Ellis, 1978). Temperature preference in yellow perch has been determined experimentally to be from 21 to 24 C (Scott and Crossman, 1973). Warm water temperature improves the defense mechanisms of fish but also generally favors bacterial growth. Rainbow trout given an intraperitoneal injection of various isolates of *M. chelonae* died in

larger number and more rapidly at 18 versus 12 C (Arakawa and Fryer, 1984). *Mycobacterium chelonae* isolated from perch from Sandy Lake and Wolf Lake grew best at 28 C, and its growth was suppressed at 4 C. This influence of temperature on bacterial growth might explain what seemed to be a different outcome of the infection in fish from these two lakes. Sluggishness and actual mortality were seen in perch from Wolf Lake in summer; mortality or significant systemic infection was not seen in perch from Sandy Lake in winter, and affected fish in this lake were still responding to baits from anglers.

ACKNOWLEDGMENTS

The essential cooperation of Sylvia Chomyc, Tuberculosis Laboratory, Provincial Laboratory of Public Health, Edmonton, Alberta, and of Cindy Arakawa, Department of Microbiology, Oregon State University, Corvallis, in identifying *Mycobacterium chelonae* was greatly appreciated. David Berry, Fisheries biologist, and Daryl Watters and Don Hildebrandt, Fisheries technicians, collected the fish samples and graciously provided information on Sandy Lake and Wolf Lake. Shawna White performed much of the bacteriological examination on fish from Wolf Lake.

LITERATURE CITED

- ABERNETHY, C. S., AND J. E. LUND. 1978. Mycobacteriosis in mountain whitefish (*Prosopium williamsoni*) from the Yakima River, Washington. *Journal of Wildlife Diseases* 14: 333-336.
- ALDERMAN, D. J., S. W. FEIST, AND J. L. POLGLASE. 1986. Possible nocardiosis of crayfish, *Austropotamobius pallipes*. *Journal of Fish Diseases* 9: 345-347.
- ANACKER, R. L., AND E. J. ORDAL. 1959. Studies on the mycobacterium *Chondrococcus columnaris*. 1. Serological typing. *Journal of Bacteriology* 78: 25-32.
- ARAKAWA, C. K., AND J. L. FRYER. 1984. Isolation and characterization of a new subspecies of *Mycobacterium chelonae* infectious for salmonid fish. *Helgolander Meeresuntersuchungen* 37: 329-342.
- , ———, AND J. E. SANDERS. 1986. Serology of *Mycobacterium chelonae* isolated from salmonid fish. *Journal of Fish Diseases* 9: 269-271.
- BINFORD, C. H., AND D. H. CONNOR (editors). 1976. Pathology of tropical and extraordinary diseases, Vol. 1. Armed Forces Institute of Pathology, Washington D.C., 339 pp.
- BOEVER, W. J., C. O. THOEN, AND J. D. WALLACH. 1976. *Mycobacterium chelonae* infection in a natterer manatee. *Journal of the American Veterinary Medical Association* 169: 927-929.
- CORBEL, M. J. 1975. The immune response in fish: A review. *Journal of Fish Biology* 7: 539-563.
- ELLIS, A. E. 1978. The immunology of teleosts. In *Fish pathology*, R. J. Roberts (ed.). Bailliere Tindall, London, England, pp. 92-104.
- HILL, L. R., V. B. D. SKERMAN, AND P. H. A. SNEATH. 1984. Corrigenda to the approved list of bacterial names. *International Journal of Systematic Bacteriology* 34: 508-511.
- LIGHTNER, D. V., AND R. M. REDMAN. 1986. A probable *Mycobacterium* sp. infection of the marine shrimp *Penaeus vannamei* (Crustacea: Decapoda). *Journal of Fish Diseases* 9: 357-359.
- LUNA, L. G. (EDITOR). 1968. *Manual of histologic staining methods of the Armed Forces Institute of Pathology*. McGraw-Hill Book Co., New York, New York, 258 pp.
- LUND, J. E., AND C. S. ABERNETHY. 1978. Lesions of tuberculosis in mountain whitefish (*Prosopium williamsoni*). *Journal of Wildlife Diseases* 14: 222-228.
- MACKENZIE, K. 1988. Presumptive mycobacteriosis in North-east Atlantic mackerel, *Scomber scombrus* L. *Journal of Fish Biology* 32: 263-275.
- PETERSON, J. 1986. Mycobacteriosis in Montana whitefish. *Fish Health Section Newsletter, American Fisheries Society* 14: 7.
- RICHARDS, R. H., AND R. J. ROBERTS. 1978. The bacteriology of teleosts. In *Fish pathology*, R. J. Roberts (ed.). Bailliere Tindall, London, England, pp. 183-204.
- ROBERTS, R. J. 1978. The pathophysiology and systematic pathology of teleosts. In *Fish pathology*, R. J. Roberts (ed.). Bailliere Tindall, London, England, pp. 55-91.
- ROSS, A. J. 1970. Mycobacteriosis among Pacific salmonid fishes. In *A symposium on diseases of fishes and shellfishes*, S. F. Snieszko (ed.). Special publication No. 5, American Fisheries Society, Washington D.C., pp. 279-283.
- SAKANARI, J. A., C. A. REILLY, AND M. MOSER. 1983. Tubercular lesions in Pacific coast populations of striped bass. *Transactions of the American Fisheries Society* 112: 565-566.
- SCOTT, W. B., AND E. J. CROSSMAN. 1973. Freshwater fishes of Canada. *Bulletin* 184, Fisheries Research Board of Canada, Ottawa, Ontario, Canada, pp. 755-761.
- VON LICHTENBERG, F. 1984. Infectious diseases. In *Pathologic basis of disease*. 3rd ed., S. L. Robbins, R. S. Cotran and V. Kumar (eds.). W. B. Saunders Co., Philadelphia, Pennsylvania, pp. 273-398.
- WARD, J. M. 1975. *M. fortuitum* and *M. chelonae*—Fast growing mycobacteria. *British Journal of Dermatology* 92: 453-459.
- WEDEMEYER, G. 1970. The role of stress in the disease resistance of fishes. In *A symposium on*

- diseases of fishes and shellfishes, S. F. Snieszko (ed.). Special publication No. 5, American Fisheries Society, Washington D.C., pp. 30-35.
- WOLINSKY, E. 1979. Nontuberculous mycobacteria and associated diseases. *American Review of Respiratory Disease* 119: 107-159.
- WOOD, J. W., AND E. J. ORDAL. 1958. Tuberculosis in Pacific salmon and steelhead trout. Fish Commission of Oregon, Portland. Contribution No. 25, Corvallis, Oregon, 38 pp.
- YAGER, J. A., AND D. W. SCOTT. 1985. The skin and appendages. *In Pathology of domestic animals*, 3rd ed., Vol. 1, K. V. F. Jubb, P. C. Kennedy and N. Palmer (eds.). Academic Press, Inc., New York, New York, pp. 407-549.

Received for publication 20 July 1987.