



EFFICACY OF TRICLABENDAZOLE AGAINST FASCIOLOIDIASIS (FASCIOLOIDES MAGNA) IN NATURALLY INFECTED WHITE-TAILED DEER (ODOCOILEUS VIRGINIANUS)

Authors: Qureshi, Tariq, Craig, Thomas M., Drawe, D. Lynn, and Davis, Donald S.

Source: Journal of Wildlife Diseases, 25(3) : 378-383

Published By: Wildlife Disease Association

URL: <https://doi.org/10.7589/0090-3558-25.3.378>

BioOne Complete (complete.BioOne.org) is a full-text database of 200 subscribed and open-access titles in the biological, ecological, and environmental sciences published by nonprofit societies, associations, museums, institutions, and presses.

Your use of this PDF, the BioOne Complete website, and all posted and associated content indicates your acceptance of BioOne's Terms of Use, available at www.bioone.org/terms-of-use.

Usage of BioOne Complete content is strictly limited to personal, educational, and non - commercial use. Commercial inquiries or rights and permissions requests should be directed to the individual publisher as copyright holder.

BioOne sees sustainable scholarly publishing as an inherently collaborative enterprise connecting authors, nonprofit publishers, academic institutions, research libraries, and research funders in the common goal of maximizing access to critical research.

EFFICACY OF TRICLABENDAZOLE AGAINST FASCIOLIDIASIS (*FASCIOLIDES MAGNA*) IN NATURALLY INFECTED WHITE-TAILED DEER (*ODOCOILEUS VIRGINIANUS*)

Tariq Qureshi,¹ Thomas M. Craig,¹ D. Lynn Drawe,² and Donald S. Davis³

¹ Department of Veterinary Microbiology and Parasitology, College of Veterinary Medicine, Texas A&M University, College Station, Texas 77843, USA

² Rob and Bessie Welder Wildlife Foundation, P.O. Drawer 1400, Sinton, Texas 78387, USA

³ Department of Veterinary Pathology, College of Veterinary Medicine, Texas A&M University, College Station, Texas 77843, USA

ABSTRACT: The efficacy of triclabendazole was evaluated in the treatment of naturally acquired *Fascioloides magna* infections in white-tailed deer (*Odocoileus virginianus*). Twenty white-tailed deer were captured on the Welder Wildlife Refuge (Sinton, San Patricio County, Texas, USA) and maintained in a 64 × 64 m deer enclosure. Ten deer were given a 5% suspension of triclabendazole orally at a dosage of 10 mg/kg body weight and 10 deer were given a placebo. Three wk later the deer were euthanized and examined for parasites. At necropsy 19 deer were infected. All specimens of *F. magna* from the tissues of the triclabendazole treated deer were dead or severely affected by the drug as indicated by changes in their size, color, movement and texture relative to those from control deer. The drug was considered 100% effective against this parasite. Adverse reactions of the deer to the drug were not observed.

Key words: Triclabendazole, fascioloidiasis, *Fascioloides magna*, white-tailed deer, *Odocoileus virginianus*, parasitology, anthelmintic.

INTRODUCTION

Fascioloides magna (Platyhelminthes: Digenea) is a common parasite of white-tailed deer (*Odocoileus virginianus*) along the Gulf Coast plains of Texas (USA). It was present in 67% of male and 47% of female white-tailed deer examined at the Welder Wildlife Refuge in eastern Texas (Glazner and Knowlton, 1967). Data from clay soil sites of the refuge have shown a 100% prevalence of the infection in deer of >3-yr-old (Qureshi, 1985). In deer, the parasite may cause liver damage, abscesses, anemia, and may reduce the probability of winter survival (Cheatum, 1951). The parasite can infect domestic livestock leading to economic losses from fatal infections, chronic disease and condemnation of livers at slaughter (Foreyt and Todd, 1976a, b). Treatment of the reservoir host, white-tailed deer, with an effective drug could theoretically reduce parasite populations by reducing pasture contamination with *F. magna* eggs. Treating wild deer could potentially ameliorate the adverse effects of parasitism to the individual animal as well as decreasing the potential for

transmission of *F. magna* to domestic livestock.

Triclabendazole is effective against both immature and mature stages of *Fasciola hepatica* in sheep (Boray et al., 1983; Smeal and Hall, 1983) and goats (Wolff et al., 1983). Also it is highly effective in reducing numbers of *F. hepatica* and *F. magna* in calves (Craig and Huey, 1984). This study tested the effects of triclabendazole in treatment of naturally acquired *F. magna* infections in white-tailed deer.

MATERIALS AND METHODS

Twenty adult (>2 yr as determined by tooth eruption and wear) white-tailed deer were captured from clay soil sites (biotope of intermediate host) on the Welder Wildlife Refuge (Sinton, San Patricio County, Texas, USA; 28°06'N, 97°25'W) by using the helicopter drive-net technique (Beasom et al., 1980). Immediately after capture the deer were sedated with a mixture of ketamine hydrochloride (150 mg; Ketaset, Bristol Laboratories, Syracuse, New York, New York 13201, USA) and xylazine hydrochloride (10 mg; Rompun, Bayvet Division, Miles Laboratory Inc., Shawnee, Kansas 66201, USA) given intravenously. They also were given antibiotic (oxytetracycline 10 mg/kg; Liquamycin 100, Pfizer Inc., New York, New York 10017,

USA), corticosteroid (dexamethasone 2 mg; Dexamethasone, Beecham Laboratories, Bristol, Tennessee 37620, USA) and a preparation of selenium and vitamin E (BO-SE, Burns-Biotec Laboratories Inc., Omaha, Nebraska 68127, USA; a dose of 1 mg selenium and 50 mg vitamin E). Each deer was weighed, ear-tagged, and blood and fecal samples were collected. Ten deer (3 males, 7 females) were treated orally with a 5% solution of triclabendazole (Fasinex 5%, Ciba-Giegy Corporation, Greensboro, North Carolina 27419, USA) at a dose of 10 mg/kg body weight. Ten control deer (also 3 males, 7 females) were given equivalent volumes of placebo. All the deer were kept in a 64 × 64 m deer enclosure and fed a 16% protein commercial deer pelleted ration (Purina Chow, Purina Mills, Inc., St. Louis, Missouri 63166, USA), whole corn and water ad libitum from a common source. Three wk after treatment deer were euthanized with a single rifle shot and necropsied. A fecal sample was collected from each deer and parasite eggs/g feces were determined using the McMaster technique (Dunn, 1978) with saturated zinc sulfate solution.

Livers were sliced in 10 mm sections to recover specimens of *F. magna*. Liver sections were kept in physiological saline baths at 37°C for 12 hr, then washed and the wash filtered through a number 70 mesh screen (212 µm opening) to recover immature flukes. Viability of the parasites was determined by examining their movement, color, texture, size and tegument integrity. Tegument integrity was further evaluated by examination with scanning electron microscopy (SEM). For SEM, six flukes (four from treated deer and two from control deer) which represented the various changes observed above were washed three times in 0.1 M Millonig's buffer (Millonig, 1964) at pH 7.4 for 10 min. They were then fixed in 1% PFA, (2.5% paraformaldehyde, 1% glutaraldehyde, 1% sucrose and 1% dimethylsulfoxide) in 0.1 M Millonig's buffer for 105 min. They were washed again as before and then incubated in 1% tannic acid in 0.1 M Millonig's buffer at room temperature. Following another wash the parasites were post fixed in 1% osmium tetroxide in 0.1 M Millonig's buffer at room temperature. The specimens were then dehydrated in a graded series of ethanol (25% v/v–100% v/v) and dried in a Denton DCP-1 critical point drier (Denton Vaculam, Inc., Cherry Hill, New Jersey 08003, USA). They were placed on aluminum stubs, coated with approximately 850 Å gold-palladium, and observed on a Joel-JSM-25 S II scanning electron microscope (Joel Ltd., Tokyo, Japan) at 12.5kV at 48 mm working distance. Photographs were taken at four to eight different locations on each fluke.

RESULTS

The number of *F. magna* eggs varied greatly at the time of capture and at necropsy (Table 1). At capture, fecal examination indicated 59% (10 of 17) of deer were infected, while at necropsy liver examinations showed that 95% (19 of 20) of deer were infected. Some deer passing parasite eggs in the feces contained dead flukes in their livers. One deer, number 85 (Table 1), in the treated group had calcified cysts containing degenerated parasites that could not be recovered and parasite eggs which were not detected in the feces. In the control group, lesions resulting from parasite infections were observed in nine of 10 deer, and healthy specimens of *F. magna* were recovered in all of them (Table 1). In the treatment group, lesions suggestive of fluke infections were observed in all of 10 deer, but healthy parasites were not recovered from any deer. Normal *F. magna* from the control deer were brown, translucent, and internal structures were easily distinguished. All affected specimens from the treated deer were immobile, black to greyish-yellow, and their internal structures were unrecognizable. Parasites from treated deer were smaller ($P < 0.05$) in size than those from control deer. The mean length of the parasites in control deer was 46 ± 8 mm while in treated deer it was 34 ± 7 mm. Some parasites had apparently disintegrated because of the presence of cysts in the liver that contained what appeared to be tegumental tissue. Immature specimens of *F. magna* were not recovered from treated deer, while one immature fluke each from five deer were recovered from control deer.

Scanning electron microscopy revealed numerous spines on the tegumental surface of normal *F. magna* (Fig. 1). The spines were conical and of different sizes. The tegumental surface between the spines was smooth and shiny. Flukes from the treated group showed extensive damage to the tegumental surface; it was rough, swollen and had erosions. Also, the spines were

TABLE 1. Number of *Fascioloides magna* eggs/g of feces at the time of capture and at necropsy and the number of parasites recovered at necropsy from white-tailed deer on the Welder Wildlife Refuge (USA).

Deer number	Fecal analysis		Parasites recovered at necropsy			
			Healthy		Affected	
	Capture	Necropsy	Adult	Immature	Adult	Immature
Control						
133	200 ^a	550 ^a	2	0	0	0
134	550	250	12	1	0	0
135	— ^b	1,300	47	1	0	0
136	— ^b	300	24	0	0	0
137	200	200	6	1	0	0
138	0	150	5	0	0	0
139	150	1,000	6	0	0	0
141	0	0	4	1	0	0
143	0	— ^b	0	0	0	0
144	800	1,900	14	1	0	0
\bar{x} (SE)	190 (261)	628 (603)	12 (13)	0.5 (0.5)		
Treatment						
76	50	0	0	0	6	0
77	600	0	0	0	0 ^c	0
78	50	0	0	0	21 ^c	0
79	50	0	0	0	3 ^c	0
80	0	700	0	0	2 ^c	0
81	0	0	0	0	4	0
82	200	0	0	0	14 ^c	0
83	— ^b	1,000	0	0	0 ^c	0
84	0	400	0	0	0 ^c	0
85	0	0	0	0	0 ^c	0
\bar{x} (SE)	105 (185)	210 (348)			5.2 (6.8)	

^a Eggs/g feces.^b Fecal sample was not available.^c Lesions and cysts of *F. magna* were present containing disintegrated parasites.

lost and pitted areas were visible. Regeneration of the tegument was not observed.

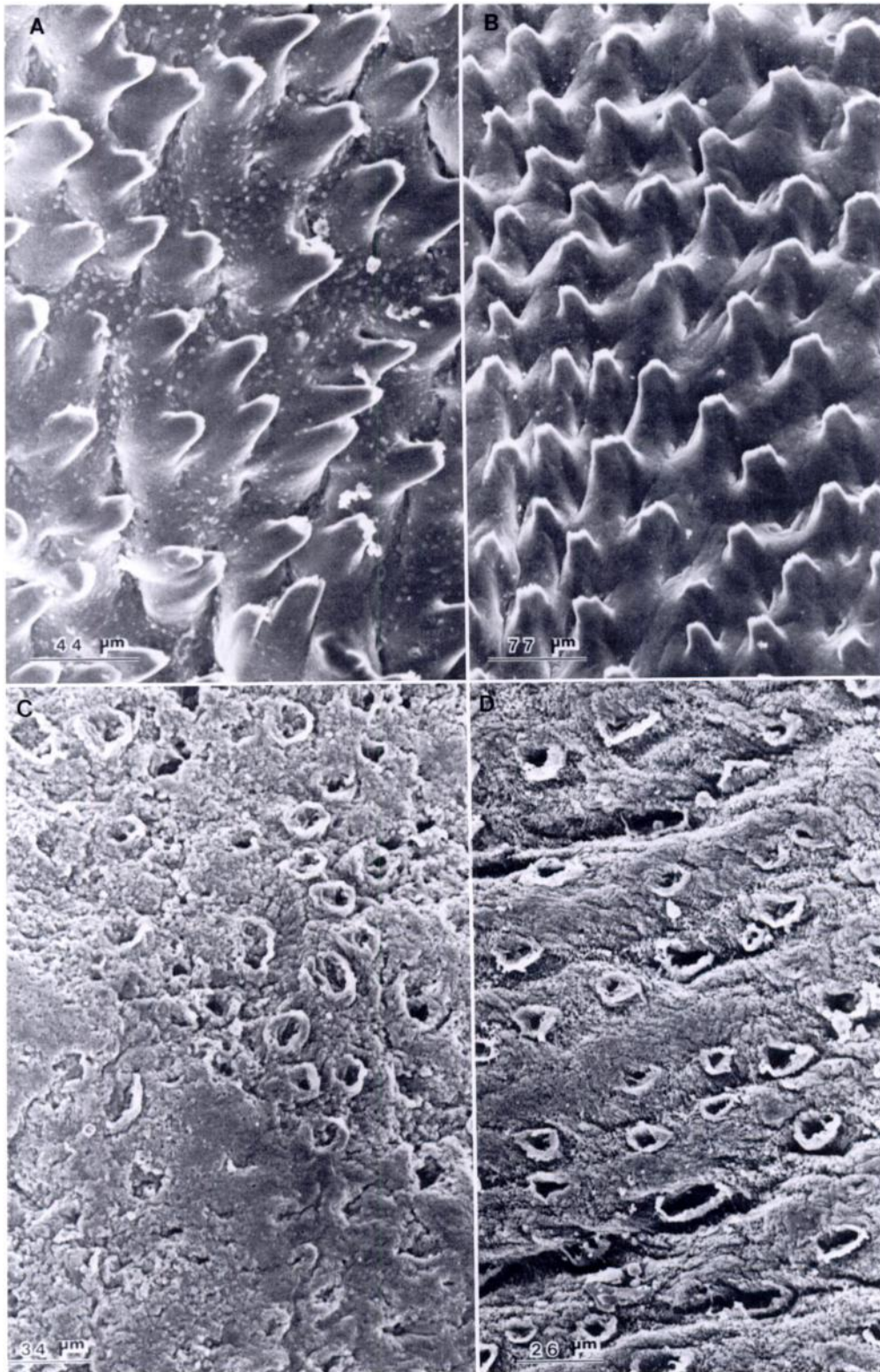
DISCUSSION

Mature *F. magna* occur in cysts with the liver parenchyma and in order to reach the external environment their eggs have to pass from the cyst and to the digestive system via the bile ducts. This may be one of the reasons for the variability in the egg counts at capture and at necropsy. Two

deer from the treated group had zero egg counts at capture and high counts at necropsy, but these deer had cysts containing necrotic and disintegrated flukes. It was concluded that following treatment all the eggs had not been flushed out of the alimentary tract in the 3 wk of the experiment.

All the parasites that could be recovered from the treated deer were either dead or affected while those recovered from the

→
FIGURE 1. Scanning electron micrographs of *Fascioloides magna* tegument from untreated (A and B) and triclabendazole treated (C and D) white-tailed deer. The tegument of normal parasite (A and B) was smooth, shiny and had numerous spines while that from affected flukes (C and D) was rough, swollen and possessed numerous pits. Erosions occurred in the tegument of parasite from treated deer (C).



control group were healthy. Immature parasites were only recovered from deer in the control group. Scanning electron microscopy revealed changes of the tegument of affected parasites. Bennett (1975) emphasized the importance of tegumental spines in trematodes as a target for anthelmintics and suggested that inhibition of spine formation in juvenile digeneans could prevent establishment of infection. Fairweather et al. (1987) described the appearance of blebs, loss of spines and sloughing of the tegument as the sequence of the damage caused to *F. hepatica* by the deacetylated (amine) metabolite of the drug diamphenathide. In this study, similar effects of triclabendazole on the tegument of *F. magna* in white-tailed deer were observed. Regeneration of the tegument of affected flukes was not observed and it was believed that the affected flukes could not recover from the effects of the drug. Therefore, efficacy of triclabendazole was considered to be 100% against naturally acquired *F. magna* infections. This effectiveness of triclabendazole against *F. magna* observed in this study was comparable to the efficacy of this drug against *F. hepatica* observed in other studies. Boray et al. (1983) found an efficacy of 100% of triclabendazole at 10 mg/kg body weight for 6-wk-old *F. hepatica* infections in sheep. Smeal and Hall (1983) observed an efficacy of 99% of triclabendazole at 10 mg/kg body weight in the treatment of 1- to 12-wk-old infections of *F. hepatica* in sheep. Also, Wolff et al. (1983) observed 100% efficacy of triclabendazole at a dosage of 10 mg/kg in the treatment of experimental infections of *F. hepatica* in sheep. Eckert et al. (1984) were able to reduce *F. hepatica* infections and mortality in sheep by repeated treatments with triclabendazole.

Control of *F. magna* can be achieved by treating the reservoir host, white-tailed deer, with an effective drug to reduce the pasture contamination with eggs. Bait or supplement feed containing the drug can be used to administer treatment to free

ranging deer at the time of peak transmission of the parasite. In south Texas this occurs at the end of winter and in spring. The 100% effectiveness of triclabendazole in treating *F. magna* makes the drug a candidate for liver-fluke control programs of the parasite in endemic areas.

ACKNOWLEDGMENTS

Financial support of this study was provided by the Rob and Bessie Welder Wildlife Foundation. This paper is Welder Wildlife Foundation contribution No. 330. Triclabendazole was provided by Ciba-Giegy Corporation. We thank P. H. Welder for kindly providing his helicopter for the deer capture, J. G. Teer and G. G. Wagner for their support and encouragement, and C. De Young of Caesar Kleberg Wildlife Research Institute, Texas A&I University, for his assistance and the use of their deer net. The assistance of K. Waldrup and D. Cruz is greatly appreciated. A special acknowledgment is owed to M. Suderman for the scanning electron microscopy. The authors also thank all those who helped in the capture of the deer, N. Silvy and his students from the Department of Wildlife and Fisheries and students from the College of Veterinary Medicine, Texas A&M University and to the staff of the Welder Wildlife Refuge.

LITERATURE CITED

- BEASOM, S. L., W. EVANS, AND L. TEMPLE. 1980. The drive net for capturing western big game. *The Journal of Wildlife Management* 44: 478-480.
- BENNETT, C. E. 1975. Scanning electron microscopy of *Fasciola hepatica* L. during growth and maturation in the mouse. *The Journal of Parasitology* 61: 892-898.
- BORAY, J. C., P. D. CROWFOOT, M. B. STRONG, J. R. ALLISON, M. SCHELLENBAUM, M. VON ORELLI, AND G. SARASIN. 1983. Treatment of immature and mature *Fasciola hepatica* infections in sheep with triclabendazole. *Veterinary Record* 113: 315-317.
- CHEATUM, E. L. 1951. Disease in relation to winter mortality of deer in New York. *The Journal of Wildlife Management* 15: 216-220.
- CRAIG, T. M., AND R. L. HUEY. 1984. Efficacy of triclabendazole against *Fasciola hepatica* and *Fascioloides magna* in naturally infected calves. *American Journal of Veterinary Research* 45: 1644-1645.
- DUNN, A. M. 1978. *Veterinary helminthology*, 2nd ed. William Heinemann Medical Books Ltd., London, England, 323 pp.
- ECKERT, J., G. SCHNEITER, AND K. WOLFF. 1984. Fasinx (triclabendazole)—ein neues Fasziolizid.

- Berliner und Muenchener Tierarztliche Wschrift 91: 349-356.
- FAIRWEATHER, I., H. R. ANDERSON, AND T. M. A. BALDWIN. 1987. *Fasciola hepatica*: Tegumental surface alterations following treatment *in vitro* with the deacetylated (amine) metabolite of diamphenethide. *Parasitology Research* 73: 99-106.
- FOREYT, W. J., AND A. C. TODD. 1976a. Liver flukes in cattle. Prevalence, distribution and experimental treatment. *Veterinary Medicine/Small Animal Clinician* 71: 815-822.
- , AND ———. 1976b. Development of the large American liver fluke, *Fascioloides magna*, in white-tailed deer, cattle and sheep. *The Journal of Parasitology* 62: 26-32.
- GLAZNER, W. C., AND F. F. KNOWLTON. 1967. Some endoparasites found in Welder deer. *The Journal of Wildlife Management* 31: 595-597.
- MILLONIG, G. 1964. Study on the factors which influence preservation of fine structure. In Symposium on electron microscopy, P. Buffa (ed.). Consiglio Nazionale delle Riccrche, Rome, Italy, p. 347.
- QURESHI, T. 1985. Use of albendazole treated feed to control *Fascioloides magna* infections in captive white-tailed deer. M.S. Thesis. Texas A&I University, Kingsville, Texas, 72 pp.
- SMEAL, M. G., AND C. A. HALL. 1983. The activity of triclabendazole against immature and adult *Fasciola hepatica* infections in sheep. *Australian Veterinary Journal* 60: 329-331.
- WOLFF, K., J. ECKERT, G. SCHNEITER, AND H. LUTZ. 1983. Efficacy of triclabendazole against *Fasciola hepatica* in sheep and goats. *Veterinary Parasitology* 13: 145-150.

Received for publication 11 August 1988.