

## **Caryospora uptoni and Frenkelia sp.-like Coccidial Infections in Red-tailed Hawks (*Buteo borealis*)**

Authors: Lindsay, David S., and Blagburn, Byron L.

Source: Journal of Wildlife Diseases, 25(3) : 407-409

Published By: Wildlife Disease Association

URL: <https://doi.org/10.7589/0090-3558-25.3.407>

---

BioOne Complete ([complete.BioOne.org](https://complete.BioOne.org)) is a full-text database of 200 subscribed and open-access titles in the biological, ecological, and environmental sciences published by nonprofit societies, associations, museums, institutions, and presses.

Your use of this PDF, the BioOne Complete website, and all posted and associated content indicates your acceptance of BioOne's Terms of Use, available at [www.bioone.org/terms-of-use](https://www.bioone.org/terms-of-use).

Usage of BioOne Complete content is strictly limited to personal, educational, and non - commercial use. Commercial inquiries or rights and permissions requests should be directed to the individual publisher as copyright holder.

---

BioOne sees sustainable scholarly publishing as an inherently collaborative enterprise connecting authors, nonprofit publishers, academic institutions, research libraries, and research funders in the common goal of maximizing access to critical research.

## ***Caryospora uptoni* and *Frenkelia* sp.-like Coccidial Infections in Red-tailed Hawks (*Buteo borealis*)**

**David S. Lindsay,<sup>1,2</sup> and Byron L. Blagburn,<sup>1</sup>** <sup>1</sup> Department of Pathobiology, College of Veterinary Medicine, Auburn University, Alabama 36849, USA. <sup>2</sup> Present address: U.S. Department of Agriculture, Agricultural Research Service, Livestock and Poultry Sciences Institute, Zoonotic Diseases Laboratory, Bldg. 1040, BARC-East, Beltsville, Maryland 20705, USA

**ABSTRACT:** The feces from 16 red-tailed hawks (*Buteo borealis*) were examined by fecal flotation for the presence of coccidial oocysts or sporocysts. Oocysts of *Caryospora uptoni* were found in five (31%), sporocysts of a *Frenkelia* sp.-like coccidium were found in eight (50%), and mixed infections with both species of coccidia were found in three (19%) red-tailed hawks. Neither oocysts nor sporocysts were found in six (38%) red-tailed hawks. Sexual stages of *C. uptoni* were found in the duodenum and jejunum of a naturally infected red-tailed hawk. Sexual stages were located in enterocytes on the distal three-fourths of the villi. This study shows that over 60% of red-tailed hawks may be passing coccidial oocysts/sporocysts in their feces and provides morphological information for diagnosing *C. uptoni* infections in histological sections.

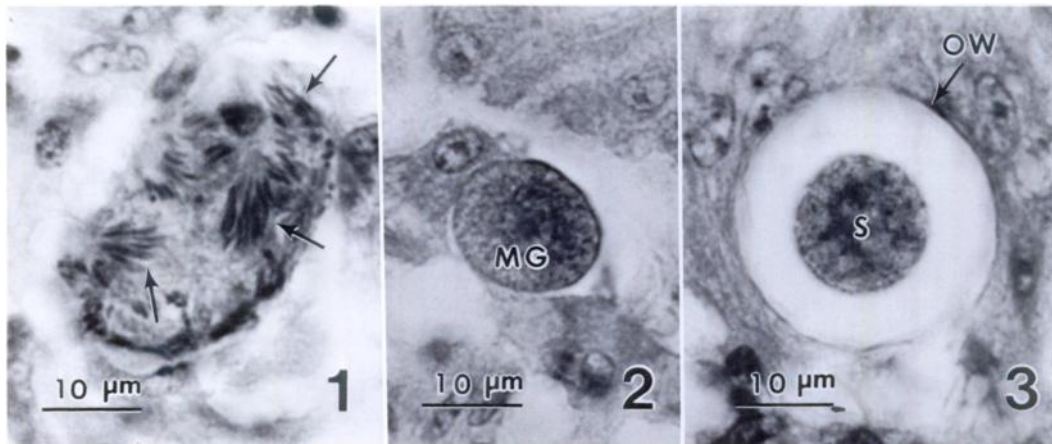
**Key words:** *Caryospora uptoni*, *Frenkelia* sp., coccidia, Apicomplexa, red-tailed hawk, *Buteo borealis*, survey.

Little is known concerning the coccidia found in red-tailed hawks, *Buteo borealis*. The sporulated sporocysts of a *Frenkelia* sp.-like coccidium (Henry, 1932, synonym *Isospora buteonis*; Lindsay et al., 1987) have been found in the intestines of red-tailed hawks. Species of *Sarcocystis* have not been reported from these birds (Cawthorn et al., 1984; Levine, 1986; Dubey et al., 1988). The definitive host for the *Frenkelia* spp. occurring in North America is not known (Dubey et al., 1988). For these reasons we refer to the sporulated sporocysts found in red-tailed hawks as being those of a *Frenkelia* sp.-like coccidium (see Lindsay et al., 1987). Oocysts of *Caryospora uptoni* have been described from red-tailed hawks (Lindsay and Blagburn, 1986). Nothing is known of the life cycles or prevalence of these species in red-tailed hawks. We report the prevalence of these two species and the location and structure of

the sexual stages and oocysts of *C. uptoni* in the intestine of a naturally infected red-tailed hawk.

All red-tailed hawks examined in this study were patients at the Auburn University Raptor Rehabilitation Center (College of Veterinary Medicine, Auburn University, Alabama 36849, USA). The sex, age and location from which each red-tailed hawk was obtained were not available. Red-tailed hawks examined in this study arrived at the center from January 1986 to May 1987 and had been in captivity for <1 wk. Birds were housed separately in cages and fed commercially purchased chicken necks once daily. Feces were examined using coverslip flotation in Sheather's sugar solution (Ernst and Benz, 1981).

A red-tailed hawk passing oocysts of both *C. uptoni* and a *Frenkelia* sp.-like coccidium was euthanized by intravenous injection of an overdose of pentobarbital (Beuthanasia-D, Schering Corporation, Kenilworth, New Jersey 07033, USA). The animal was suffering from a severe gunshot wound and could not be rehabilitated. The intestinal tract was removed, infused with, and fixed in 10% neutral buffered formalin solution. Smears were made of unfixed portions of the duodenum, jejunum and ileum; these were examined with Nomarski interference contrast (NIC) microscopy. Sections of fixed intestine were taken every 1 cm and processed for routine histologic examination after staining with hematoxylin and eosin (H&E). Selected intestinal sections were stained with PAS or trichrome stains. Developmental stages were measured with a calibrated ocular micrometer. Measurements are expressed



FIGURES 1-3. Sexual stages and oocyst of *Caryospora uptoni* in histological sections of the small intestine of a naturally infected red-tailed hawk. H&E. 1. Microgamont and microgametes (arrows). 2. Macrogamont (MG). 3. Oocyst with contracted sporont (S). Note oocyst wall (OW).

as means  $\pm$  standard error of the mean followed by the ranges in parentheses. Twenty-five stages of each developmental type were measured.

Oocysts of *C. uptoni* were found in five (31%) and sporocysts of a *Frenkelia* sp.-like coccidium were found in eight (50%) red-tailed hawks. Mixed infections of both species occurred in three (19%) red-tailed hawks. Neither oocysts nor sporocysts were observed in six (38%) red-tailed hawks. Oocysts of *C. uptoni* were passed unsporulated in the feces and were structurally similar to those previously described (Lindsay and Blagburn, 1986). *Frenkelia* sp.-like sporocysts observed in the feces of red-tailed hawks were  $11.2 \pm 0.10$  by  $8.5 \pm 0.12$   $\mu\text{m}$  (10 to 12 by 7 to 9  $\mu\text{m}$ ) and had a compact or dispersed sporocyst residuum. Fully sporulated oocysts with two sporocysts were occasionally seen in the feces of hawks passing the *Frenkelia* sp.-like coccidium.

Asexual stages of *C. uptoni* were not observed. Sexual stages of *C. uptoni* were found in all small intestinal sections examined except the last seven (about 7 cm from the ileocecal junction). Stages of the parasite were not seen in the cecae, large intestine or cloaca. Sexual stages were located in enterocytes along the distal three-

fourths of the villi and were usually located beneath the host cell nucleus. Immature microgamonts were elongate or slightly spherical and measured  $24.4 \pm 1.03$  by  $18.3 \pm 0.77$   $\mu\text{m}$  (16 to 35 by 10 to 24  $\mu\text{m}$ ). Mature microgamonts contained many microgametes (Fig. 1) and measured  $29.1 \pm 0.68$  by  $20.6 \pm 0.78$   $\mu\text{m}$  (25 to 37 by 14 to 32  $\mu\text{m}$ ). Macrogamonts were ovoid, elongate, or spherical (Fig. 2) and measured  $17.4 \pm 0.46$  by  $13.8 \pm 0.40$   $\mu\text{m}$  (14 to 21 by 10 to 17  $\mu\text{m}$ ). Oocysts were spherical or subspherical, contained a contracted sporont (Fig. 3) and were  $27.0 \pm 0.39$  by  $24.2 \pm 0.47$   $\mu\text{m}$  (23 to 30 by 20 to 29  $\mu\text{m}$ ). The oocyst wall was approximately 1  $\mu\text{m}$  thick. Sporonts were spherical and measured  $16.2 \pm 0.20$  by  $15.7 \pm 0.21$   $\mu\text{m}$  (15 to 18 by 14 to 18  $\mu\text{m}$ ).

The *Frenkelia* sp.-like coccidium was found in all small intestinal sections examined. It was not seen in the cecae, colon or cloaca. In living smears observed with NIC microscopy, the sporocysts of this species were found to have a sporocyst residuum but none was observed in H&E, PAS or trichrome stained tissue sections.

The distribution and location of sexual stages of *C. uptoni* in the small intestine of the red-tailed hawk examined in our study are similar to that reported for *C.*

*bubonis* in experimentally infected great horned owls (*Bubo virginianus*) by Cawthorn and Stockdale (1982). However, oocysts observed in tissue sections in that study were much smaller than *C. uptoni* oocysts and did not have a contracted sporont.

The distribution and location of the *Frenkelia* sp.-like coccidium seen in this study was similar to what we have previously reported (Lindsay et al., 1987). However, in that study we did not examine fresh tissues or feces and failed to find a sporocyst residuum in the sporocysts of this coccidium. Results of our study indicate that the residuum is present but it is lost during histological processing.

The present study was supported in part by a grant from the College of Veterinary Medicine (FAHDR-AL-V-155) to the authors. We thank Rhonda Buxton, David Suarez, and Joy Vaughan for technical assistance. This is College of Veterinary Medicine publication 2061.

#### LITERATURE CITED

- CAWTHORN, R. J., A. A. GAJADHAR, AND R. J. BROOKS. 1984. Description of *Sarcocystis rauschorum* sp. n. (Protozoa: Sarcocystidae) with experimental cyclic transmission between varying lemmings (*Dicrostonyx richardsoni*) and snowy owls (*Nyctea scandiaca*). Canadian Journal of Zoology 62: 217-225.
- , AND P. H. G. STOCKDALE. 1982. The developmental cycle of *Caryospora bubonis* Cawthorn and Stockdale, 1981 (Protozoa: Eimeriidae) in the great horned owl, *Bubo virginianus* (Gmelin). Canadian Journal of Zoology 60: 152-157.
- DUBEY, J. P., C. A. SPEER, AND R. FAYER. 1988. *Sarcocystis* of animals and man. CRC Press, Boca Raton, Florida, USA. 215 pp.
- ERNST, J. V., AND G. W. BENZ. 1981. Coccidiosis. In Diseases of cattle in the tropics, M. Ristic and I. McIntyre (eds.). Martinus Nijhoff, The Hague, The Netherlands, pp. 337-392.
- HENRY, D. P. 1932. *Isospora buteonis* sp. nov. from the hawk and owl, and notes on *Isospora lacazii* (Labbe) in birds. University of California Publications in Zoology 37: 291-299.
- LEVINE, N. D. 1986. The taxonomy of *Sarcocystis* (Protozoa, Apicomplexa) species. The Journal of Parasitology 72: 372-382.
- LINDSAY, D. S., S. I. AMBRUS, AND B. L. BLAGBURN. 1987. *Frenkelia* sp.-like infection in the small intestine of a red-tailed hawk. Journal of Wildlife Diseases 23: 677-679.
- , AND B. L. BLAGBURN. 1986. *Caryospora uptoni* n. sp. (Apicomplexa: Eimeriidae) from red-tailed hawks (*Buteo jamaicensis borealis*). The Journal of Parasitology 72: 762-765.

Received for publication 26 September 1988.